




3

54


 भारत सरकार
 Government of India



 हर्ष आनन्द
 HARSH ANAND
 पिता : केशव आनन्द
 Father : KESHAV ANAND
 जन्म वर्ष / Year of Birth : 1969
 पुरुष / Male



8233 6344 2817

आधार - आम आदमी का अधिकार


MALIK RADIX HEALTH CARE PVT. LTD.
 C-217, C-218, Nirman Vihar,
 Delhi-110092
 Ph.: 011-49287456, 011-61381379
 Regd. No. 607



 आरक्षण अधिकार
 Unique Identification Authority of India


पता: 26, ए 4 सी, जनकपुरी,
 जनकपुरी बी-1, जनकपुरी बी-1,
 पश्चिम दिल्ली, दिल्ली, 110058

Address: 26, A 4 C, JANAKPURI,
 Janakpuri B-1, Janakpuri B-1, West Delhi,
 Delhi, 110058

8233 6344 2817

 1947
 1800 300 1947

 help@uidai.gov.in

 www.uidai.gov.in



Echocardiogram Report

Patient Name	MR. HARSH ANAND
Date of Test	07/03/2024
Age	54 YRS/ MALE
Ref. by	MEDIWHEEL

Dimensions	Result	Normal Range
AO (ed)	2.8 cm	(2.1 -3.7cm)
LA (es)	3.0 cm	(2.1 -3.7cm)
RVID (ed)	1.9 cm	(1.1-3.0cm)
LVID (ed)	5.2 cm	(3.6 – 5.5 cm)
LVID (es)	3.6 cm	(2.3-3.9cm)
IVS (ed)	1.1 cm	(0.6 – 1-2 cm)
LVPW (ed)	1.1 cm	(0.6 – 1-2 cm)
EF	58 %	
FS	30 %	(28 % - 42 %)

Impression

- NO REGIONAL WALL MOTION ABNORMALITY SEEN.
- LVEF= 58 %
- NORMAL CHAMBER DIMENSIONS.
- STAGE I LV DISTOLIC DYSFUCTION.
- NORMAL COLOR FLOW.
- NO INTRA CARDIAC CLOT/MASS/ VEGETATION/PERICARDIAL EFFUSION SEEN.

Dr. Sheikh Nazir Ahmed
M.D. "Physician" PGDCC
(Consultant Non – Invasive Cardiologist)

Facilities Available

- Multispeciality Hospital - 24 Hours Emergency - X-Ray/ ECG/ Ultrasound/ CT Scan - Dental- Fully Equipped Operation Theatre
- Fully Functional Lab - 24/7 Casualty/ ICU-Nursery 24/7 Pharmacy - Labour Room - All Speciality OPD - Laproscopic Surgery - ECHO - Plastic Surgery



CONSULTANTS ON PANEL

PAEDIATRICS

Dr Ravi Malik (MBBS, MD)
Dr Harit Prasad (MBBS, MD, Pfd)
Dr Ritu Jain (MBBS, MD)

GYNAECOLOGY

Dr Renu Malik (MBBS, MD)
Dr Meena Malhotra (MBBS, MD)
Dr Rajni (MBBS, MD)
Dr Manju Gupta (MBBS, MS)
Dr Vaishali Saini (MBBS, DGO)
Dr Rupam Arora (MBBS, MD)

DENTAL

Dr Shruti Malik (BDS, MDS)
Dr Annu Saini (BDS, MDS)
Dr Rachit Thukral (BDS, MDS)
Dr Mohit Mangla (BDS, MDS)
Dr Tarun Mittal (BDS, MDS)
Dr Geetika Sharma (BDS)
Dr Shilpa Verma (BDS)

CHILD GASTROENTEROLOGY

Dr S. K Mittal (MBBS, MD)

MEDICINE

Dr A S Talwar (MBBS, MD)
Dr Sunny Uppal (MBBS, MD)
Dr Surendra Rajpal (MBBS, MD)

RESPIRATORY MEDICINE /PULMONOLOGY

Dr Abhinav Bhanot (MBBS, DNB)

LAPAROSCOPY SURGERY

Dr Ajay Jain (MBBS, MS)
Dr Deepak Saran (MBBS, MS)
Dr Pradeep Saini (MBBS, MS)
Dr G. S Garg (MBBS, MS)

ORTHOPAEDICS

Dr Vikas Bhardwaj (MBBS, MS ORTHO, DNB)
Dr Prabhat Aggarwal (MBBS, MS ORTHO)
Dr KB Tiwari (MBBS, MS ORTHO)
Dr Deepak Kumar Arora (MBBS, MS ORTHO)

EYE/OPTHALMOLOGY

Dr Nidhi Gupta (MBBS, MS, DNB, PGDM)
Dr Himanshu Singh Pundir (MBBS, MS)

ENT

Dr Sharad Kumar Singhi (MBBS, MS)
Dr Prateek Sharma (MBBS, MS)
Dr Ashok Singh (MBBS, MS)
Dr A K Lahiri (MBBS, MS)

RADIOLOGY(ULTRASOUND)

Dr K K Sinha (MBBS DNRB)
Dr T K Vohra (MBBS, MD)
Dr Rajesh Malhotra (MBBS, MD)
Dr Ashish Tomar (MBBS, MD)

PATHOLOGY

Dr Reema Dahiya (MBBS, MD PATH)
Dr Meenu Aggarwal (MBBS, MD PATH)

ANAESTHESIA

Dr Rajesh Dhall (MBBS, MD)
Dr Rakesh Atrey (MBBS, MD)
Dr R K Arora (MBBS, MD)
Dr Swaraj Garg (MBBS, MD)

DERMATOLOGY

Dr Nihanika Jha (MBBS, MD)

PLASTIC & COSMETIC SURGERY

Dr Ayush Jain (MBBS, MS, MCh)

PAEDIATRIC SURGERY

Dr Dharmendra Singh (MBBS, MS, M.Ch)
Dr Satish Aggarwal (MBBS, MS, M.Ch)

PAEDIATRIC NEPHROLOGY

Dr A S Vasudev (MD, Dip.in. Paed.)

NEPHROLOGY

Dr Javed (MBBS, MD, Nephro)

CARDIOLOGY

Dr Nishant Tyagi (MBBS, MD)

NEUROLOGY

Dr Amit Batra (MBBS, MD)

GASTROENTEROLOGY

Dr Deepak Lahoti (MBBS, MD)
Dr Naresh Aggarwal (MBBS, MD)
Dr Ashok Goyal (MBBS, MD)
Dr Ankur Singhal (MBBS, MD)

UROLOGY

Dr Nikhil Sharma (MBBS, Mch)
Dr Ankur Singhal (MBBS, MD)

PSYCHIATRY

Dr Mohit Sharma (MBBS, MD)

PHYSIOTHERAPY

Dr Kirti Dwivedi

Dr Ravi Kumar

NUTRITIONIST

Dr Deepika Kohli

Dr Sakshi Rana

CLINICAL PSYCHOLOGIST

Dr. Sarika Singh

Dr. Shruti Malik

BDS, MDS (Endodontics)

(+91-9899561092)

Name : Haush Anand

Age/Sex : 54 M.

Date : 7/3/24.

**Timings : 10:00 am. to 2:00 pm.
6:00 pm. to 8:30 pm.**

For Appointment

**011-45152510
+91-9999254639**

CLINICAL EXAMINATION:-

Routine dental check up

1. TMJ:-

2. DENTAL STATUS:

M/H - Diabetes - on medication since 3 years

- a. Caries Teeth :
- b. Fracture Teeth :
- c. Root Stumps :
- d. Gingivitis :
- e. Periodontitis :
- f. Impacted Teeth :
- g. Malaligned Teeth :

e/e

*- Calculus ++
- Stains ++*

- Gingival recession in lower anterior

3. ORAL LESIONS:-

4. DIAGNOSIS:-

- Caries - 17/7

5. TREATMENT PLANNING:

*- Cervical abrasion 6543 / 456
54 / 45*

6. FOLLOW UP:-

Referral To Other Consultant: Yes/ No Adv

If Yes, please mention the Name:

*- Restoration
- oral prophylaxis
- Riti*

** Ultra soft tooth brush.*

Doctor's Signature

Facilities Available :

- ★ MULTI-SPECIALITY HOSPITAL ★ MODULAR FULLY EQUIPPED OT ★ NURSERY ★ LAPROSCOPIC SURGERY
- ★ 24X7 EMERGENCY ★ OPG ★ DENTAL ★ 24X7 DIAGNOSTICS ★ LABOUR ROOM ★ ECHO ★ EEG ★ DIGITAL X-RAY ★ CT SCAN
- ★ ECG ★ ULTRASOUND ★ RICU/ICU ★ ALL SPECIALITY OPD ★ PLASTIC & COSMETIC SURGERY ★ DIALYSIS ★ PHARMACY

MAC600 1.02

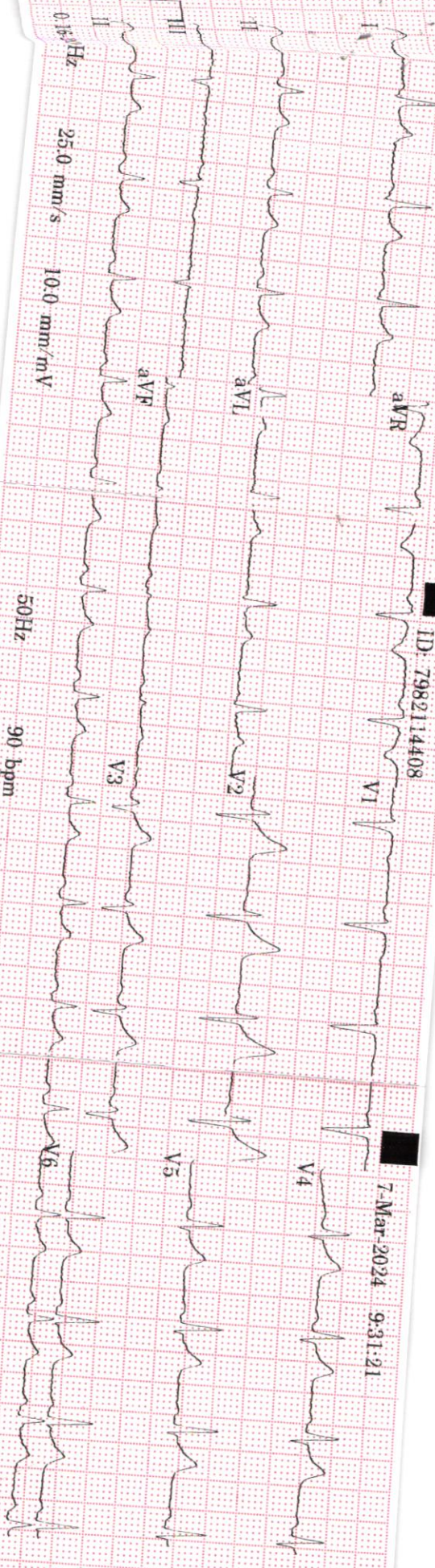
ID: 7982114408

7-Mar-2024 9:31:21

ID: 7982114408

Harsh Anand

54 years Male



4 by 2.5s + 1 rhythm 1d

Vent. rate	90 bpm
QRS duration	74 ms
QT/QTc	338/413 ms
PR interval	138 ms
P duration	96 ms
RR interval	666 ms
P-R-T axes	63 10 27

MAC600 1.02

12SL™ V239

Malik Radix HealthCare.

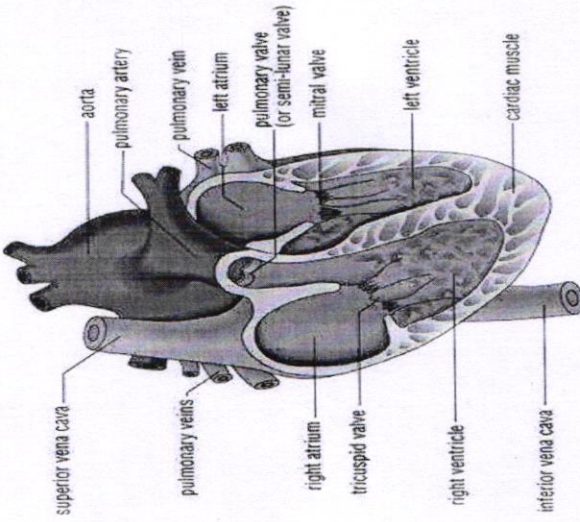
ELECTROCARDIOGRAM

Name: MR. HARSH ANAND

Age & Sex: 54 YR/ MALE

Ref By: MEDIWHEEL

Date: 07/03/2024



ECG FINDINGS:


Rate 90 bpm Rhythm Sinus Mechanism Normal

Axis Normal P Wave Normal PR Interval 0.13/Sec

QRS Complex Normal QT Interval Normal Q Wave Normal

ST Segment Normal T Wave Normal

Conclusion Sinus Rhythm, Normal Axis, WNL.

Doctors Signature:  Dr. SHEIKH NAZIR AHMED
M.D. "Physician"
PGDCC
DMC-46499



LAB REPORT

Reg. Date	07/03/2024	Patient Id	2403070003	DOB.	
Name	MR. HARSH ANAND	Gender	M	Perm. ID	
Age	54 Yrs.	Panel	MEDIWHEEL	Reported	07/03/2024 17:47:15
Ref. By	BOB				

Test Name	Result	Units	Ref. Range
MEDIWHEEL ANNU PLUS VITAMIN			

HAEMATOLOGY

COMPLETE HAEMOGRAM

HAEMOGLOBIN (HB%)	13.9	gm/dl	13 - 18
TOTAL LEUCOCYTE COUNT (TLC)	8,900	/cumm	4000 - 11000

DIFFERENTIAL LEUCOCYTE COUNT (DLC)

NEUTROPHIL	60	%	40 - 80
LYMPHOCYTE	33	%	28 - 55
MONOCYTE	05	%	02 - 10
EOSINOPHIL	02	%	01 - 06
BASOPHIL	00	%	0 - 0
ESR (WESTEGREN'S METHOD)	16	mm/Ist hr.	0 - 10
R B C COUNT	5.15	Millions/cmm	4.247 - 5.4
P.C.V / HAEMATOCRIT	44.5	%	40 - 54
M C V	86.4	fl.	80 - 100
M C H	27.0	Picogram	27.0 - 31.0
M C H C	31.2	gm/dl	33 - 37
PLATELET COUNT	1.63	Lakh/cu mm	1.50 - 4.50
BLOOD GROUP ABO	" A "		
RH TYPING	Positive		
BLOOD SUGAR FASTING	154.58	mg/dl	70 - 100

THYROID PROFILE

Free T3 ELFA	3.16	ng/ml	02 - 04
Free T4 ELFA	1.73	ug/dl	0.8 - 2.7

LIPID PROFILE

Checked by : _____
Page 1 Contd...2

If test results are alarming or unexpected, patient is advised to contact the laboratory immediately for possible remedial action.

Facilities Available

- Multispeciality Hospital - 24 Hours Emergency - X-Ray/ ECG/ Ultrasound/ CT Scan - Dental- Fully Equipped Operation Theatre
- Fully Functional Lab - 24/7 Casualty/ ICU-Nursery 24/7 Pharmacy - Labour Room - All Speciality OPD - Laproscopic Surgery - ECHO - Plastic Surgery



LAB REPORT

Reg. Date	07/03/2024	Patient Id	2403070003	DOB.	
Name	MR. HARSH ANAND	Gender	M	Perm. ID	
Age	54 Yrs.	Panel	MEDIWHEEL	Reported	07/03/2024 17:47:15
Ref. By	BOB				

Test Name	Result	Units	Ref. Range
TOTAL CHOLESTEROL	132.10	mg/dL	130.0 - 200.0 (<200)
TRIGLYCERIDES	129.00	mg/dL	80.5 - 150.0 (<150)
H D L CHOLESTEROL DIRECT	37.31	mg/dL	35.0 - 60.0 (<40->59)
V L D L	25.8	mg/dL	4.0 - 30. (23-45)
L D L CHOLESTEROL	69.0	mg/dL	50.0 - 150.0 (50-150)
TOTAL CHOLESTEROL / HDL RATIO	3.5		3.3 - 5.1
LDL / HDL CHOLESTEROL RATIO	1.8		1.5 - 3.5
<u>LIVER FUNCTION TEST (LFT)</u>			
BILIRUBIN TOTAL	0.43	mg/dl	0.2 - 1.2
CONJUGATED (D. BILIRUBIN)	0.10	mg/dl	0.00 - 0.3
UNCONJUGATED (I.D.BILIRUBIN)	0.33	mg/dl	0.2 - 0.9
SGOT / AST	54.50	IU/L	0 - 35
SGPT / ALT	56.9	IU/L	0 - 35
ALKALINE PHOSPHATASE	71.80	U/L	64 - 306
TOTAL PROTEIN	8.19	gm/dl	6.0 - 8.3
ALBUMIN	4.46	gm/dl	3.2 - 5.0
GLOBULIN	3.73	gm/dl	2.5 - 5.6
A/G RATIO	1.20		0.9 - 2.0
GAMMA GT	22.70	IU/L	0.0 - 45.0
SERUM CREATININE	1.00	mg/dl	0.7 - 1.4
SERUM URIC ACID	6.53	mg/dl	3.4 - 7.0
BLOOD UREA NITROGEN (BUN)	14.19	mg/dl	6.0 - 21.0
BUN/CREAT RATIO	14.19	mg/dl	
VITAMIN D 25 HYDROXY CLIA	10.0	ng/ml	

10 - 20

Checked by : -----
Page 2 Contd...3

If test results are alarming or unexpected, patient is advised to contact the laboratory immediately for possible remedial action.

Facilities Available

- Multispeciality Hospital - 24 Hours Emergency - X-Ray/ ECG/ Ultrasound/ CT Scan - Dental- Fully Equipped Operation Theatre
- Fully Functional Lab - 24/7 Casualty/ ICU-Nursery 24/7 Pharmacy - Labour Room - All Speciality OPD - Laproscopic Surgery - ECHO - Plastic Surgery



LAB REPORT

Reg. Date	07/03/2024	Patient Id	2403070003	DOB.	
Name	MR. HARSH ANAND	Gender	M	Perm. ID	
Age	54 Yrs.	Panel	MEDIWHEEL	Reported	07/03/2024 17:47:15
Ref. By	BOB				

TOTAL PSA 0.91 ng/ml
Chemiluminescence

INTERPRETATION :
Expected Values :

99%	:	of Healthy males	0.0-4.0 ng/ml
80%	:	of Benign prostatic hypertrophy	0.0-4.0 ng/ml
81%	:	of Prostatic Carcinomas	Above 4.0 ng/ml

PSA is reliable tumour marker for already diagnosed prostatic carcinomas. It is uniquely associated only with prostatic tissue, and therefore is specific for it. Baseline levels measured prior to therapeutic intervention and followed later by serial periodical measurements will predict the outcome of therapy. It also helps in early discovery of recurrences, relapses and metastases.

Urine Routine Examination

PHYSICAL EXAMINATION

QUANTITY	20	ml.	
COLOUR	Pale Yellow		Pale Yellow
TRANSPARENCY	Clear		
SPECIFIC GRAVITY	1.015		
PH	6.0		

CHEMICAL EXAMINATION

ALBUMIN	Nil
SUGAR	Nil

MICROSCOPIC EXAMINATION

PUS CELLS	1-2	/HPF
RBC'S	Nil	/HPF
CASTS	Nil	
CRYSTALS	NIL	

Checked by : _____
Page 3 Contd...4

If test results are alarming or unexpected, patient is advised to contact the laboratory immediately for possible remedial action.

Facilities Available

- Multispeciality Hospital - 24 Hours Emergency - X-Ray/ ECG/ Ultrasound/ CT Scan - Dental- Fully Equipped Operation Theatre
- Fully Functional Lab - 24/7 Casualty/ ICU-Nursery 24/7 Pharmacy - Labour Room - All Speciality OPD - Laproscopic Surgery - ECHO - Plastic Surgery



LAB REPORT

Reg. Date	07/03/2024	Patient Id	2403070003	DOB.	
Name	MR. HARSH ANAND	Gender	M	Perm. ID	
Age	54 Yrs.	Panel	MEDIWHEEL	Reported	07/03/2024 17:47:15
Ref. By	BOB				

Test Name	Result	Units	Ref. Range
EPITHELIAL CELLS	1-2	/HPF	
BACTERIA	Nil		
OTHERS	Nil		

IMMUNOLOGY

TSH	10.790	uIU/ml	0.25 - 5.50 uIU/ml
Serum/ELFA			


Interpretation**Clinical Use**

- Diagnose Hypothyroidism and Hyperthyroidism
- Monitor T4 replacement or T4 suppressive Therapy
- Quantify TSH levels in the subnormal range

Increased Levels : Primary Hypothyroidism Subclinical Hypothyroidism, TSH dependent, Thyroid Hormone Resistance.

Decreased Levels : Grave's Disease, Autonomous Thyroid Hormone Secretion, TSH Deficiency

MEDIWHEEL ANNU PLUS VITAMIN


Dr. REEMA DAHIYA
M.B.B.S, MD (Path.)
Checked by _____
Page 4 of 4
Malik Radix Healthcare Pvt. Ltd.
C-217, C-218, Nirman Vihar,
Delhi-92

DR. REEMA DAHIYA
M.B.B.S, MD (Path.)

If test results are alarming or unexpected, patient is advised to contact the laboratory immediately for possible remedial action.

Facilities Available

- Multispeciality Hospital - 24 Hours Emergency - X-Ray/ ECG/ Ultrasound/ CT Scan - Dental- Fully Equipped Operation Theatre
- Fully Functional Lab - 24/7 Casualty/ ICU-Nursery 24/7 Pharmacy - Labour Room - All Speciality OPD - Laproscopic Surgery -
ECHO - Plastic Surgery

R

HARSH ANAND 54YIM PT208219

CHEST PA 07.03.2024 09:32 AM



UHID	PT208219	LAB No.	XRY2310528
Name	Mr. HARSH ANAND	Regn. No.	GEN2341570
Age / Sex	54 Yrs / M	Receiving Dt/Time	07-Mar-2024 09:37
		Reporting Dt/Time	07-Mar-2024 09:49 AM



XRAY

CHEST (PA)

Both lung fields are normal.

Cp angles are clear.

Hila are normal...

Heart size appears within normal limits.

Soft tissue shadows and bony thorax are normal.

Advised....please correlate clinically.

***** END OF REPORT *****

DR. K.K. SINHA
 M.B.B.S. D.M.R.D.
 SENIOR CONSULTANT
 Reg. No. 25437 (DMC)

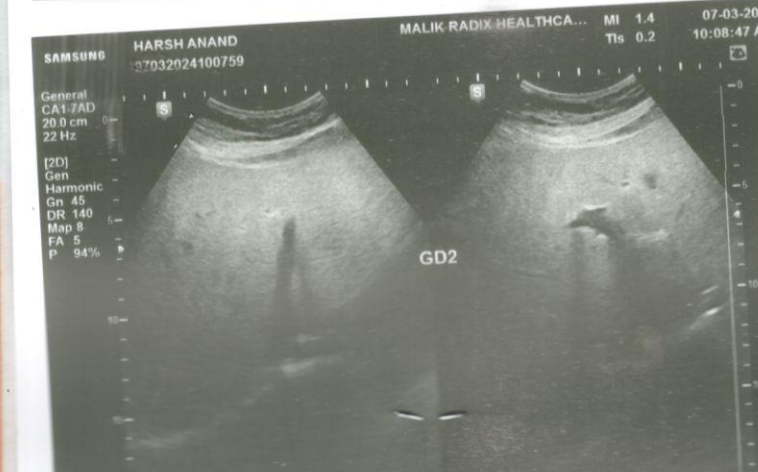
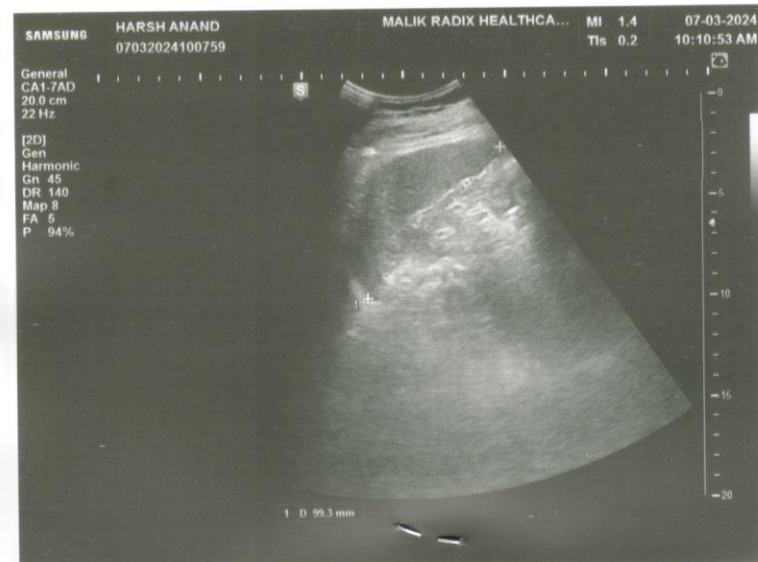
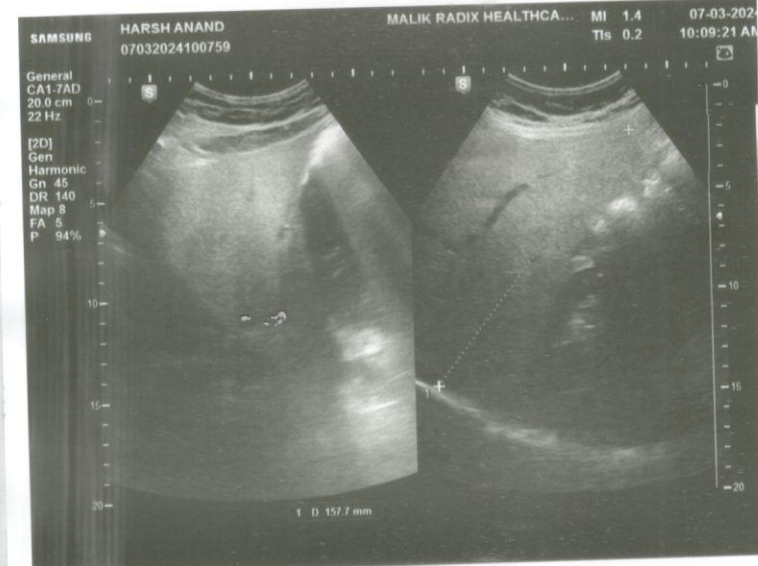
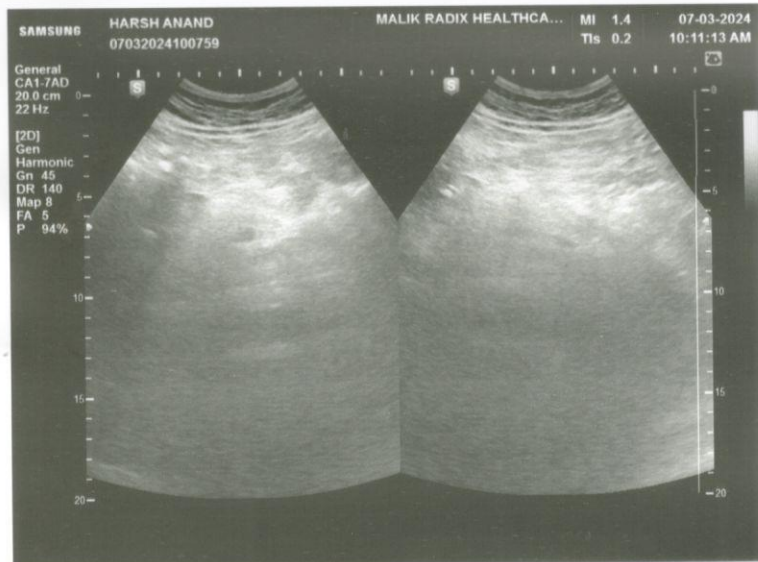
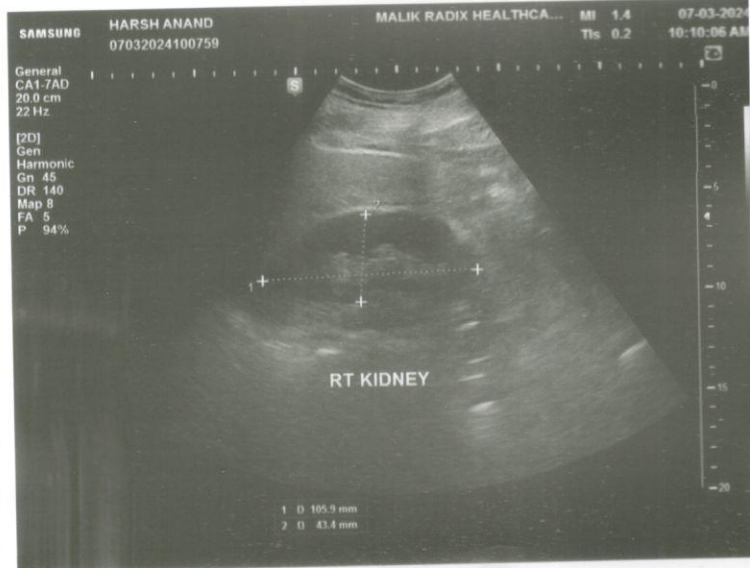
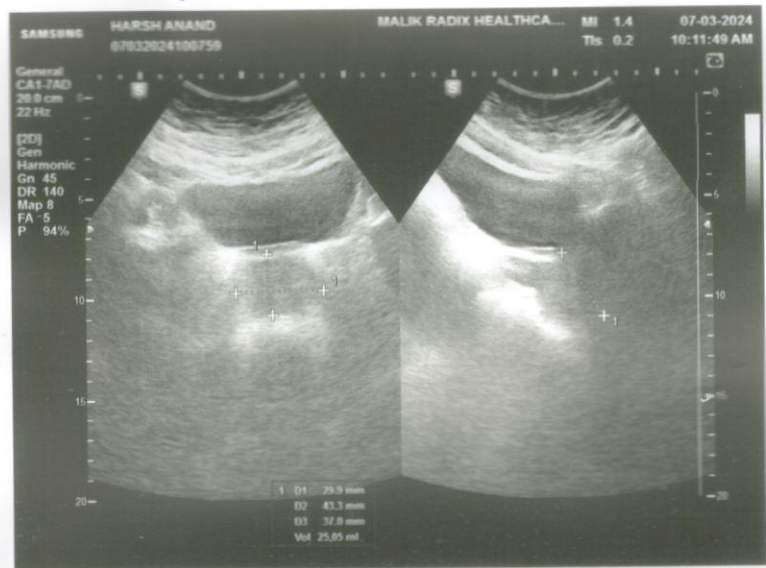
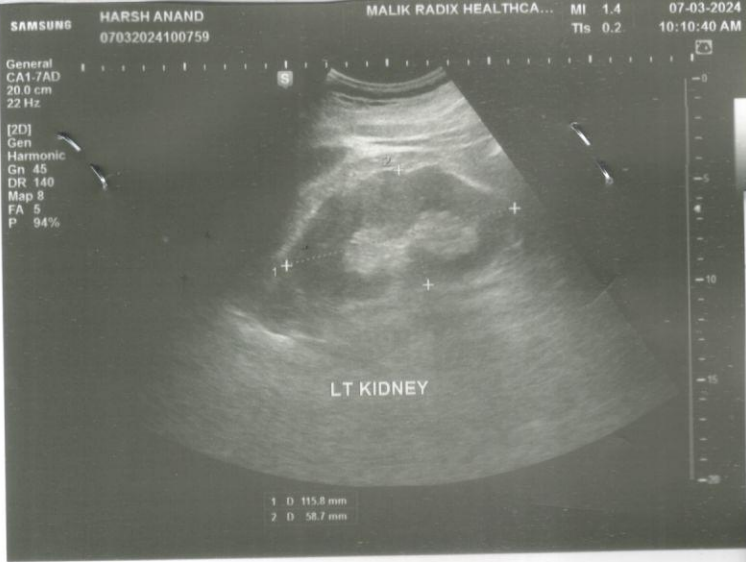DR. RAJESH MALHOTRA
 MBBS, MD (RADIOLOGY)
 CONSULTANT RADIOLOGY
 Reg.No.DMC9299

DR. T. K VOHRA
 MD (RADIODIAGNOSIS)
 SENIOR CONSULTANT
 Reg. No. 3272 (DMC)

DR. MUKESH KOSHAL
 MBBS, MD (RADIOLOGY)
 CONSULTANT RADIOLOGY
 Reg.No.DMC10407

DR. SHREYASH TIWARY
 MBBS, MD (RADIOLOGY)
 CONSULTANT RADIOLOGY
 Reg.No.DMC85802

Facilities Available



RADIX
HEALTH
care



Malik Radix Healthcare

C/217, C/218, Vikas Marg, Nirman Vihar, New Delhi-110092
A Unit of Malik Radix Healthcare
Toll Free - 1800-120-5457
Whatsapp No. - 9811550650
E-mail: info@radixhealthcare.org
Website: www.radixhealthcare.org



NAME	MR HARSH ANAND	AGE	54 YRS/M
REFD. BY.	HEALTH CHCEK UP	DATE	07.03.24

Ultrasound Examination of Whole Abdomen & Pelvis:

Liver: Liver appears enlarged in size (15.7 cm) with normal outlines and shows increased parenchymal echotexture. No focal SOL is seen in liver. IHBR & portal radicles are normal.

Gallbladder: Gallbladder is well distended. No evidence of cholecystitis or cholelithiasis seen. Common bile duct is normal in course & caliber.

Pancreas: Pancreas shows normal size, outlines & echotexture. No focal lesion is seen. MPD is not dilated.

Spleen: Spleen shows normal size (9.9 cm), outline & echotexture.

Kidneys: Kidneys show normal size, shape, position & echotexture. No calculus/ hydronephrosis or SOL is seen in kidneys. Cortico- medullary differentiation and cortical thickness is normal on both sides.

Right kidney measures –10.6 x 4.3 cm

Left kidney measures –11.5 x 5.8 cm

Great abdominal vessels are normal.

No ascites seen.

No para-aortic lymph nodes seen.

Urinary bladder Urinary bladder is well distended. Walls and lumen appear normal.

Prostate is normal in size (25.0 cc) with normal outline and echotexture. No focal lesion is seen.

IMPRESSION:

Hepatomegaly with Grade II Fatty Changes

Dr Shreyash Tiwary/MD (Rad- diag)

Regn. No. DMC 85802

RADIOLOGIST :

Facilities Available

- Multispeciality Hospital - 24 Hours Emergency - X-Ray/ ECG/ Ultrasound/ CT Scan - Dental - Fully Equipped Operation Theatre
- Fully Functional Lab - 24/7 Casualty/ ICU-Nursery 24/7 Pharmacy - Labour Room - All Speciality OPD - Laproscopic Surgery -