

Reg. No.	AP
Date :	15/06/2024

Blood
 Urine
 Stool
 Vaccine
 ECG
 2D Echo
 TMT
 X-Ray
 PFT
 Audio
 USG
 OPT
 Dr.

Employee's Name : LALIT SHROTRIYA

With Glass / Without Glasses

Blood Group : B+

Age/Sex : 21/M

Contact No. : 9917470146

	Rt.	Lt.
NEAR	N/G	N/G
DISTANT	6/6	6/6
COLOUR VISION	Normal	

PHYSIOLOGIC PARAMETERS :
 Ht. (Cms.) 182 Wt. (Kgs.) 74.20 BMI 22.4 kg/m²
 (Normal)

GENERAL EXAMINATION SpO₂ : 100%
 Pulse (Min) : 77/m BP (mm Hg) : 120/80
 R.R. (Min) : 20 cpm Temp. : Afebr
 Pallor : NAD Icterus : NAD
 Clubbing : NAD

COMPLAINTS : (Specify if any)
No fresh complaints.

ENT EXAMINATION (Specify if Abnormal)
 Ear _____ Nose _____ Tongue (N)
 Teeth _____ Tonsils _____ Gums _____

PAST HISTORY : NAD

SYSTEMIC EXAMINATION
 LOCOMOTOR SYSTEM NAD
 RESPIRATORY SYSTEM ACBF clear
 CARDIOVASCULAR SYSTEM SS 2+
 CENTRAL NERVOUS SYSTEM cons. oriented
 ABDOMEN Soft
 GENITAL SYSTEM NAD
 MUSCULOSKELETAL SYSTEM NAD

FAMILY HISTORY : Father - DM
Mother - hypothyroidism

SURGICAL HISTORY : NAD

PERSONAL HISTORY (Addiction if any)
 Chronic / Frequent / Occasional : No
 Smoker / Tobacco Chewer / Alcoholic : No

PFT	MEANS	PRED	% PRED
SVC			
FVC			
FEV1 / FVC			
Remark			

Audiometry	Frequency in Hz					
	500	1000	2000	4000	6000	8000
Right Ear						
Left Ear						
Remark						

pt is fit and can resume his normal duties.

DOCTOR SIGNATURE
DR. VISHAL DALVI
 MBBS, MD (Medicine)
 Consultant Physician
 Reg. No. 2011/09/3121

ID: 1536 **Lalit Shrivastava**

15-06-2024 09:36:50 AM

Diagnosis Information:
Sinus Arrhythmia

NSR

Male Years **21M.**

HR : 71 bpm
P : 104 ms
PR : 135 ms

Req. No. :

QRS : 96 ms

BP: **120/80**

QT/QTcBz : 354/387 ms

PR: **77.1m**

ST/QTcBz : 69/86.61 ms

SpO2: **100%**

P/QRST

: 69/86.61

mV

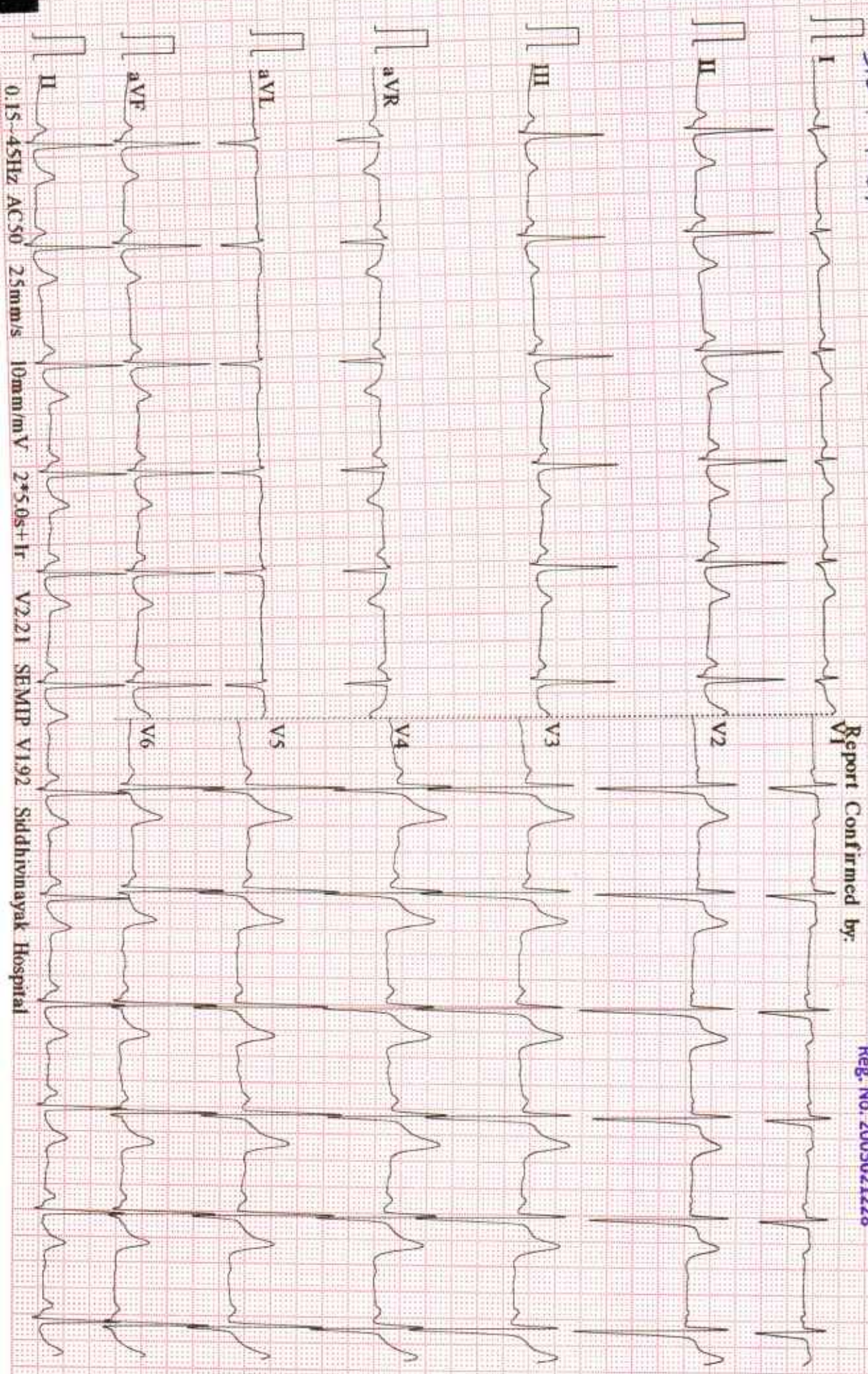
RV5/SV1

: 1.843/0.885

mV

Report Confirmed by:

Dr. Anant Rameshwarrao Munde
MBBS, DNB, DM (Cardiology)
Reg. No. 2005021228



0.15-45Hz AC50 25mm/s 10mm/mV 2*5.0s+1r V221 SEMIP V192 Siddhivinayak Hospital

OPHTHAL CHECK UP SCREENING

NAME OF EMPLOYEE

Lalit Shrotrya

AGE

21

DATE:

15-06-2024

Specs : Without Glasses

	RT Eye	Lt Eye
NEAR	N/6	N/6
DISTANT	6/6	6/6
Color Blind Test	NORMAL	

SIDDHIVINAYAK HOSPITALS





Name - Mr. LALIT SHIROTRIYA	Age - 21 Y/M
Ref by Dr:- Siddhivinayak Hospital	Date- 15/06/2024

X- Ray chest (PA VIEW)

No obvious active parenchymal lesion seen in both lungs.
Cardiac and aortic shadows appear normal
No evidence of pleural of effusion is seen.
Both domes of diaphragm appear normal.
No obvious bony lesion is seen.

IMPRESSION:

- No significant abnormality seen.

Adv.: Clinical and lab correlation.

DR. AMOL BENDRE
MBBS; DMRE
CONSULTANT RADIOLOGIST

Note: The above report represents interpretation of various radiographic / sonographic shadows, and hence has its own limitations. This report has to be co-related clinic-pathologically by the referring / physician and it does NOT represent the sole diagnosis.

DR. AMOL BENDRE
MBBS DMRE
Reg. No. 2015/08/4412

