



## ECHO REPORT

Name of the patient: MR. IMTIYAZ ANSARI Age: 40 Sex:  Male  Female  
 UHID No: 22859 IPD No: 23054386 Date: 04/10/2023  
 Refer By Doctor: DR. RAKESH ARORA

LVEF% 66%

### 2D ECHO

> Mitral Value Normal Pulmonary Value N Pulm  
 > Artery N  
 > Aortic avive N Tricuspid valve N

### 2D RWMA

> NO RWMA (Regional wall motion abnormality) at rest

### COLD DOPPLER

> NO Significant Vavular stenosis / Regurgiation

### COMMENTS AND SUMMARY

> All cardiac chambers of N size and shape NO dilatation or hypertrophy.  
 > NO RWMA (Regional wall motion abnormality) at rest  
 > NO Cloth / Vegetation/ pericardial effusion  
 > LV 66% Systolic function  
 > NO Significant Vavular stenosis / Regurgiation

### Final Impression

> EF at Rest 66%

### COMMENTS

2D ECHO & Color Doppler study work

### Consultant Cardiology

Doctor Name : Dr.  
 Date :

Dr. Rakesh Kumar Arora  
 MBBS, MD, DM (Cardiology)  
 Reg. No. DMC - 18090  
 Consultant - Cardiology  
 Park Hospital, Faridabad

Signature :  
 Time :



**DEPARTMENT OF RADIOLOGY**

|                     |                                  |                          |                  |          |
|---------------------|----------------------------------|--------------------------|------------------|----------|
| <b>Patient Name</b> | Mr IMTIAZ ANSARI                 | <b>Billed Date</b>       | : 26/09/2023     | 8.46 AM. |
| <b>Reg No</b>       | 27859                            | <b>Reported Date</b>     | : 26/09/2023     |          |
| <b>Age/Sex</b>      | 40 Years 10 Months 31Days / Male | <b>Req. No.</b>          | : 23054386       |          |
| <b>Type</b>         | OPD                              | <b>Consultant Doctor</b> | : Dr. CONSULTANT |          |

**X-RAY CHEST AP/PA**

Bilateral lungs appears normal.  
Both hila are normal in size, have equal density and bear normal relationship.  
The heart and trachea are central in position and no mediastinal abnormality is visible.  
The cardiac size is normal for patient age and view.  
The domes of the diaphragms are normal in position, and show smooth outline.

To be correlated clinically

DR BINOD KR CHAUDHARY  
MBBS, MD  
CONSULTANT RADIOLOGIST

(This is only professional opinion and not the diagnosis, Please correlate clinically)

J-Block, Sector-10, Near Court, Faridabad - 121004, Haryana  
Tel.: 0129-4200000 E-mail : parkfaridabad@gmail.com





**DEPARTMENT OF RADIOLOGY**

|              |                                  |                   |                  |         |
|--------------|----------------------------------|-------------------|------------------|---------|
| Patient Name | Mr IMTIAZ ANSARI                 | Billed Date       | : 26/09/2023     | 8.46 AM |
| Reg No       | 27859                            | Reported Date     | : 26/09/2023     |         |
| Age/Sex      | 40 Years 10 Months 31Days / Male | Req. No.          | : 23054386       |         |
| Type         | OPD                              | Consultant Doctor | : Dr. CONSULTANT |         |

**USG WHOLE ABDOMEN**

**LIVER** : The liver is normal in size, shape and echotexture. No evidence of any focal lesion. IHBR is NOT dilated. Portal vein is normal.

**GALL BLADDER** :The gall bladder is well distended. No evidence any calculus or mass seen. GB wall thickness with in normal limits. No evidence of pericholecystic fluid is seen. The common bile duct is normal.

**SPLEEN** :The spleen is normal in size and shape. Its echotexture is homogeneous. No evidence of focal lesion is noted. Splenic vein is normal.

**PANCREAS** :The pancreas is normal in size, shape, contours and echotexture.

**BILATERAL KIDNEYS** : The bilateral kidneys are normal in size and echotexture. Cortico-medullary differentiation is maintained. There is no evidence of obvious calculus or hydronephrosis seen.

**URINARY BLADDER** :The urinary bladder is well distended. Wall thickness within normal limits. No evidence of calculus is seen. No evidence of mass or diverticulum is noted.


**PROSTATE**: Prostate appears normal in size, shape and echotexture.

No free fluid is seen in peritoneal cavity.

No evidence of obvious retroperitoneal or mesenteric lymphadenopathy is seen.

**IMPRESSION: - USG WHOLE ABDOMEN REVEALS NO OBVIOUS ABNORMALITY.**

**TO BE CORRELATED CLINICALLY.**

  
DR BINOD KR CHAUDHARY  
MBBS, MD  
CONSULTANT RADIOLOGIST

(This is only professional opinion and not the diagnosis, Please correlate clinically)

J-Block, Sector-10, Near Court, Faridabad - 121004, Haryana

Tel.: 0129-4200000 E-mail : parkfaridabad@gmail.com



## OPD PRESCRIPTION

|             |   |           |                          |
|-------------|---|-----------|--------------------------|
| MR.NO       | : 27859   | Date&Time | : 04/10/2023 11.51 AM    |
| Name        | : Mr. IMTIAZ ANSARI   | Sex       | : Male                   |
| Doctor Name | : Dr. VAIJINATH DHAPASE   | Age       | : 40Years 11Months 8Days |
| Speciality  | : MEDICINE  | Mobile No | : 9969927787             |
| Address     | : HNO-52, BLB, FBD, HARYANA, Faridabad<br>City Faridabad, Haryana | Panel     | : MEDIWHEEL FOC          |

BH 110180mmHg  
wt 78kg  
SBP=98  
HR 90b/min

for health check up

No complaints  
occ. smoker

R 9 Thrombolytic  
Repeat CBC - after 5 days.

ASA - 0, 10

TFT - WNL

RBS - 124

LFT - WNL

KFT - WNL

Lipids - WNL

CBC - pH - 1.35

urine - R/M - WNL

2DEcho - WNL

TMT Neg - for IHD.

CXR - WNL

USG Abd - WNL

T. Caripil

1 - 1 - 1

Q

Dr. Rajeev

J-Block, Sector-10, Near Court, Faridabad - 121004, Haryana Tel.: 0129-4200000 E-mail : parkfaridabad@gmail.com

PARK GROUP OF HOSPITALS : West Delhi • South Delhi • Gurugram • Karnal • Panipat • Hodal • Ambala • Behr

the health care providers

the health care providers

DELHI GOVT CGHS, ECHS, MTNL, DJB, DTC NDPL MCD, NAFED, HUDCO, TRADE FAIR AUTHORITY OF INDIA, DDA, NDMC, PAWAN H



## DEPARTMENT OF PATHOLOGY

Patient Name : Mr. IMTIAZ ANSARI  
 MR No : 27859  
 Age/Sex : 40 Years 10 Months 31 Days / Male  
 Type : OPD  
 TPA/Corporate : MEDIWHEEL

Bill Date : 26/09/2023  
 Reporting Date : 26/09/2023  
 Sample ID : 40489  
 Bill/Req. No. : 23054386  
 Ref Doctor : Dr.CONULTANT

| Test | Result | Bio. Ref. Interval | Units |
|------|--------|--------------------|-------|
|------|--------|--------------------|-------|

### URINE ROUTINE AND MICROSCOPY

#### PHYSICAL CHARACTERISTICS

|                  |             |               |    |
|------------------|-------------|---------------|----|
| QUANTITY         | 20.0 ML     | 5 - 100       | ML |
| COLOUR           | Pale Yellow |               |    |
| TURBIDITY        | TURBID      | clear         |    |
| SPECIFIC GRAVITY | 1.010       | 1.003 - 1.030 |    |
| PH               | 6.5         | Acidic        |    |

#### CHEMICAL EXAMINATION-1

|               |     |     |  |
|---------------|-----|-----|--|
| URINE PROTEIN | NIL | NIL |  |
| GLUCOSE       | NIL | NIL |  |

#### MICRO.EXAMINATION

|                  |             |     |           |
|------------------|-------------|-----|-----------|
| PUS CELL         | 2 - 3/HPF   |     | CELLS/HPF |
| RED BLOOD CELLS  | Nil         | 0-2 | CELLS/HPF |
| EPITHELIAL CELLS | 10 - 12/HPF | 0-5 | CELLS/HPF |
| CASTS            | NIL         | NIL | CELLS/HPF |
| CRYSTALS         | NIL         | NIL | CELLS/HPF |
| OTHER            | NIL         |     |           |

\*\*\*\*\* END OF THE REPORT \*\*\*\*\*



Sample no.

Dr. VAISHALI YADAV    Dr.REETU JADHAV    Dr. PARDIP KUMAR    S.C.GAUR  
 CONS.PATHOLOGIST    CONS.PATHOLOGIST    MICROBIOLOGIST & ICO    LAB INCHARGE    USER NM    SEHDEV

(This is only professional opinion and not the diagnosis, Please correlate clinically)

J-Block, Sector-10, Near Court, Faridabad - 121004, Haryana

Tel.: 0129-4200000 E-mail : parkfaridabad@gmail.com





## DEPARTMENT OF PATHOLOGY

Patient Name : Mr. IMTIAZ ANSARI

MR No : 27859

Age/Sex : 40 Years 10 Months 31 Days / Male

Type : OPD

TPA/Corporate : MEDIWHEEL

Bill Date : 26/09/2023

Reporting Date : 26/09/2023

Sample ID : 40489

Bill/Req. No. : 23054386

Ref Doctor : Dr. CONSULTANT

| Test                         | Result        | Bio. Ref. Interval | Units             |
|------------------------------|---------------|--------------------|-------------------|
| <b>CBC</b>                   |               |                    |                   |
| HAEMOGLOBIN                  | 15.0          | 12 - 16            | gm/dL             |
| PACKED CELL VOLUME           | 49.5          | 35.0 - 50.0        | %                 |
| RED BLOOD CELL COUNT         | 5.27          | 3.5 - 5.5          | millions/ $\mu$ L |
| MEAN CORPUSCULAR VOLUME      | 93.9          | 83 - 101           | fL                |
| MEAN CORPUSCULAR HAEMOGLOBIN | 28.5          | 27 - 31            | pg                |
| MEAN CORPUSCULAR HB CONC     | <b>30.3 L</b> | 33 - 37            | g/dl              |
| RDW                          | 12.9          | 11.6 - 14.5        | %                 |
| TOTAL LEUCOCYTE COUNT        | 6380          | 4000-11000         | / $\mu$ L         |
| <b>DIFFERENTIAL COUNT</b>    |               |                    |                   |
| NEUTROPHILS                  | 60            | 40.0 - 80.0        | %                 |
| LYMPHOCYTES                  | 35            | 20 - 40            | %                 |
| MONOCYTES                    | 02            | 2.0 - 10.0         | %                 |
| EOSINOPHILS                  | 03            | 0.0 - 5.0          | %                 |
| BASOPHILS                    | 00            | 0.0 - 2.0          | %                 |
| PLATELET COUNT               | <b>1.35 L</b> | 1.50 - 4.50        | lac/cumm          |

\*\*\*\*\* END OF THE REPORT \*\*\*\*\*



Sample no.

Dr. VAISHALI YADAV

Dr. REETU JADHAV

Dr. PARDIP KUMAR

S.C. GAUR

CONS. PATHOLOGIST

CONS. PATHOLOGIST

MICROBIOLOGIST & ICO LAB INCHARGE

USER NM PRIYANKA

(This is only professional opinion and not the diagnosis, Please correlate clinically)

J-Block, Sector-10, Near Court, Faridabad - 121004, Haryana

Tel.: 0129-4200000 E-mail : parkfaridabad@gmail.com



**DEPARTMENT OF PATHOLOGY**

Patient Name : Mr. IMTIAZ ANSARI

MR No : 27859

Age/Sex : 40 Years 10 Months 31 Days / Male

Type : OPD

TPA/Corporate : MEDIWHEEL

Bill Date : 26/09/2023

Reporting Date : 26/09/2023

Sample ID : 40489

Bill/Req. No. : 23054386

Ref Doctor : Dr.CONSULTANT

Test

Result

Bio. Ref. Interval

Units

**BLOOD GROUPING AND RH FACTOR**

BLOOD GROUP

"AB" RH POSITIVE

\*\*\*\*\* END OF THE REPORT \*\*\*\*\*



Sample no.

Dr. VAISHALI YADAV

Dr. REETU JADHAV

Dr. PARDIP KUMAR

S.C.GAUR

CONS.PATHOLOGIST

CONS.PATHOLOGIST

MICROBIOLOGIST & ICO LAB INCHARGE

USER NM PRIYANKA

(This is only professional opinion and not the diagnosis, Please correlate clinically)

J-Block, Sector-10, Near Court, Faridabad - 121004, Haryana

Tel.: 0129-4200000 E-mail : parkfaridabad@gmail.com



**DEPARTMENT OF PATHOLOGY**

|  |                                    |
|--|------------------------------------|
| <b>Patient Name</b> : Mr. IMTIAZ ANSARI            | <b>Bill Date</b> : 26/09/2023      |
| <b>MR No</b> : 27859                               | <b>Reporting Date</b> : 26/09/2023 |
| <b>Age/Sex</b> : 40 Years 10 Months 31 Days / Male | <b>Sample ID</b> : 40489           |
| <b>Type</b> : OPD                                  | <b>Bill/Req. No.</b> : 23054386    |
| <b>TPA/Corporate</b> : MEDIWHEEL                   | <b>Ref Doctor</b> : Dr.CONSULTANT  |

| Test                       | Result | Bio. Ref. Interval | Units |
|----------------------------|--------|--------------------|-------|
| <b>BLOOD SUGAR FASTING</b> |        |                    |       |
| PLASMA GLUCOSE FASTING     | 94.11  | 60 - 110           | mg/dl |

\*\*\*\*\* END OF THE REPORT \*\*\*\*\*



Sample no.

Dr. VAISHALI YADAV    Dr.REETU JADHAV    Dr. PARDIP KUMAR    S.C.GAUR  
CONS.PATHOLOGIST    CONS.PATHOLOGIST    MICROBIOLOGIST & ICO LAB INCHARGE    USER NM SUNIL

(This is only professional opinion and not the diagnosis, Please correlate clinically)

J-Block, Sector-10, Near Court, Faridabad - 121004, Haryana

Tel.: 0129-4200000 E-mail : parkfaridabad@gmail.com





**DEPARTMENT OF PATHOLOGY**

Patient Name : Mr. IMTIAZ ANSARI  
MR No : 27859  
Age/Sex : 40 Years 10 Months 31 Days / Male  
Type : OPD  
TPA/Corporate : MEDIWHEEL

Bill Date : 26/09/2023  
Reporting Date : 26/09/2023  
Sample ID : 40489  
Bill/Req. No. : 23054386  
Ref Doctor : Dr. CONSULTANT

| Test                        | Result | Bio. Ref. Interval | Units |
|-----------------------------|--------|--------------------|-------|
| <b>LIPID PROFILE</b>        |        |                    |       |
| TOTAL CHOLESTEROL           | 186.55 | 120.0 - 200.0      | mg/dL |
| SERUM TRIGLYCERIDES         | 152.21 | 40.0 - 160.0       | mg/dl |
| HDL-CHOLESTEROL             | 43.10  | 30 - 70            | mg/dl |
| VLDL CHOLESTEROL            | 30.44  | 6 - 32             | mg/dL |
| LDL                         | 113.01 | 50 - 135           | mg/dl |
| LDL CHOLESTEROL/HDL RATIO   | 2.62   | 1.0 - 3.0          | mg/dL |
| TOTAL CHOLESTEROL/HDL RATIO | 4.33   | 2.0 - 5.0          | mg/dl |

\*\*\*\*\* END OF THE REPORT \*\*\*\*\*



Sample no.

Dr. VAISHALI YADAV    Dr. REETU JADHAV    Dr. PARDIP KUMAR    S.C. GAUR  
CONS. PATHOLOGIST    CONS. PATHOLOGIST    MICROBIOLOGIST & ICO LAB INCHARGE    USER NM    SUNIL

(This is only professional opinion and not the diagnosis, Please correlate clinically)

J-Block, Sector-10, Near Court, Faridabad - 121004, Haryana

Tel.: 0129-4200000 E-mail : parkfaridabad@gmail.com



**DEPARTMENT OF PATHOLOGY**

Patient Name : Mr. IMTIAZ ANSARI  
 MR No : 27859  
 Age/Sex : 40 Years 10 Months 31 Days / Male  
 Type : OPD  
 TPA/Corporate : MEDIWHEEL

Bill Date : 26/09/2023  
 Reporting Date : 26/09/2023  
 Sample ID : 40489  
 Bill/Req. No. : 23054386  
 Ref Doctor : Dr.CONULTANT

| Test                       | Result | Bio. Ref. Interval | Units  |
|----------------------------|--------|--------------------|--------|
| <b>KFT (RENAL PROFILE)</b> |        |                    |        |
| <b>KFT</b>                 |        |                    |        |
| SERUM UREA                 | 27     | 10 - 45            | mg/dL  |
| SERUM CREATININE           | 1.1    | 0.4 - 1.4          | mg/dL  |
| SERUM URIC ACID            | 5.8    | 2.5 - 7.0          | mg/dL  |
| SERUM SODIUM               | 139    | 136 - 148          | mmol/L |
| SERUM POTASSIUM            | 4.4    | 3.5 - 5.5          | mmol/L |
| CHLORIDE                   | 100.0  | 96 - 106           | mmol/L |

\*\*\*\*\* END OF THE REPORT \*\*\*\*\*



Sample no.

Dr. VAISHALI YADAV    Dr. REETU JADHAV    Dr. PARDIP KUMAR    S.C. GAUR  
 CONS. PATHOLOGIST    CONS. PATHOLOGIST    MICROBIOLOGIST & ICO    LAB INCHARGE    USER NM    SUNIL

(This is only professional opinion and not the diagnosis, Please correlate clinically)

J-Block, Sector-10, Near Court, Faridabad - 121004, Haryana  
 Tel.: 0129-4200000 E-mail : parkfaridabad@gmail.com



**DEPARTMENT OF PATHOLOGY**

**Patient Name** : Mr. IMTIAZ ANSARI  
**MR No** : 27859  
**Age/Sex** : 40 Years 10 Months 31 Days / Male  
**Type** : OPD  
**TPA/Corporate** : MEDIWHEEL  
**Bill Date** : 26/09/2023  
**Reporting Date** : 26/09/2023  
**Sample ID** : 40489  
**Bill/Req. No.** : 23054386  
**Ref Doctor** : Dr.CONULTANT

| Test                             | Result                | Bio. Ref. Interval | Units |
|----------------------------------|-----------------------|--------------------|-------|
| <b>LFT (LIVER FUNCTION TEST)</b> |                       |                    |       |
| <b>LFT</b>                       |                       |                    |       |
| TOTAL BILIRUBIN                  | 1.0                   | 0 - 1.2            | mg/dL |
| DIRECT BILIRUBIN                 | 0.3                   | 0 - 0.4            | mg/dL |
| INDIRECT BILIRUBIN               | <b>0.7 H</b> <i>H</i> | 0.10 - 0.6         | mg/dL |
| SGOT (AST)                       | 33                    | 0 - 45             | U/L   |
| SGPT (ALT)                       | <b>54 H</b> <i>H</i>  | 0 - 45             | U/L   |
| ALKALINE PHOSPHATASE             | 127.6                 | 30 - 170           | IU/L  |
| TOTAL PROTEIN                    | 6.5                   | 6.4 - 8.0          | g/dL  |
| ALBUMIN                          | 4.3                   | 3.3 - 5.5          | g/dL  |
| GLOBULIN                         | <b>2.2 L</b> <i>L</i> | 2.3 - 4.5          | g/dL  |
| A/G RATIO                        | 1.95                  | 1.1 - 2.2          |       |

\*\*\*\*\* END OF THE REPORT \*\*\*\*\*



Sample no.

Dr. VAISHALI YADAV    Dr.REETU JADHAV    Dr. PARDIP KUMAR    S.C.GAUR  
 CONS.PATHOLOGIST    CONS.PATHOLOGIST    MICROBIOLOGIST & ICO    LAB INCHARGE    USER NM    SUNIL

(This is only professional opinion and not the diagnosis, Please correlate clinically)

J-Block, Sector-10, Near Court, Faridabad - 121004, Haryana  
 Tel.: 0129-4200000 E-mail : parkfaridabad@gmail.com





**DEPARTMENT OF PATHOLOGY**

|  |                                    |
|--|------------------------------------|
| <b>Patient Name</b> : Mr. IMTIAZ ANSARI            | <b>Bill Date</b> : 26/09/2023      |
| <b>MR No</b> : 27859                               | <b>Reporting Date</b> : 26/09/2023 |
| <b>Age/Sex</b> : 40 Years 10 Months 31 Days / Male | <b>Sample ID</b> : 40489           |
| <b>Type</b> : OPD                                  | <b>Bill/Req. No.</b> : 23054386    |
| <b>TPA/Corporate</b> : MEDIWHEEL                   | <b>Ref Doctor</b> : Dr.CONSULTANT  |

| Test                        | Result | Bio. Ref. Interval | Units |
|-----------------------------|--------|--------------------|-------|
| <b>BLOOD SUGAR 2 HR. PP</b> |        |                    |       |
| BLOOD SUGAR P.P.            | 124.0  | 80 - 150           | mg/dl |

\*\*\*\*\* END OF THE REPORT \*\*\*\*\*



Sample no.

Dr. VAISHALI YADAV    Dr. REETU JADHAV    Dr. PARDIP KUMAR    S.C. GAUR  
CONS.PATHOLOGIST    CONS.PATHOLOGIST    MICROBIOLOGIST & ICO LAB INCHARGE    USER NM DEEPCHAND

(This is only professional opinion and not the diagnosis, Please correlate clinically)

J-Block, Sector-10, Near Court, Faridabad - 121004, Haryana

Tel.: 0129-4200000 E-mail : parkfaridabad@gmail.com

*[Handwritten signature]*



**DEPARTMENT OF PATHOLOGY**

Patient Name : Mr. IMTIAZ ANSARI  
 MR No : 27859  
 Age/Sex : 40 Years 10 Months 31 Days / Male  
 Type : OPD  
 TPA/Corporate : MEDIWHEEL

Bill Date : 26/09/2023  
 Reporting Date : 27/09/2023  
 Sample ID : 40489  
 Bill/Req. No. : 23054386  
 Ref Doctor : Dr.CONSULTANT

| Test                        | Result | Bio. Ref. Interval | Units  |
|-----------------------------|--------|--------------------|--------|
| <b>THYROID PROFILE</b>      |        |                    |        |
| TRI-iodOTHYRONINE (T3)      | 1.32   | 0.60 - 1.81        | ng/ml  |
| THYROXINE (T4)              | 9.5    | 5.01 - 12.45       | µg/dL  |
| THYROID STIMULATING HORMONE | 3.37   | 0.5-5.50           | µIU/ml |

\*\*\*\*\* END OF THE REPORT \*\*\*\*\*

OUT SOURCE  
PARK HOSPITAL  
CGN



Sample no.

Dr. VAISHALI YADAV    Dr.REETU JADHAV    Dr. PARDIP KUMAR    S.C.GAUR  
 CONS.PATHOLOGIST    CONS.PATHOLOGIST    MICROBIOLOGIST & ICO    LAB INCHARGE    USER NM    *Samay*

(This is only professional opinion and not the diagnosis, Please correlate clinically)

J-Block, Sector-10, Near Court, Faridabad - 121004, Haryana

Tel.: 0129-4200000 E-mail : parkfaridabad@gmail.com



**DEPARTMENT OF PATHOLOGY**

Patient Name : Mr. IMTIAZ ANSARI  
 MR No : 27859  
 Age/Sex : 40 Years 10 Months 31 Days / Male  
 Type : OPD  
 TPA/Corporate : MEDIWHEEL  
 Bill Date : 26/09/2023  
 Reporting Date : 27/09/2023  
 Sample ID : 40489  
 Bill/Req. No. : 23054386  
 Ref Doctor : Dr.CONULTANT

| Test  | Result | Bio. Ref. Interval | Units |
|---|--------|--------------------|-------|
| <b>PSA - TOTAL (PROSTATIC SPECIFIC ANTIGEN) - CANCER MARKER</b> |        |                    |       |
| PROSTATE SPECIFIC ANTIGEN(PSA)                                  | 0.90   | 0.0 - 4.0          | ng/ml |
| Method : chemiluminescent immunoassay                           |        |                    |       |

**Note : Clinical Use: -**

An aid in the early detection of Prostate cancer in Male. Follow up and amazement of Prostate cancer patients. Detect metastatic or persistent disease in patients following surgical or medical treatment of Prostate cancer

Note: -

False negative / positive results are observed in patients receiving mouse monoclonal antibodies for diagnosis or therapy. PSA levels may appear consistently elevated / depressed due to the interference by heterophilic antibodies & non-specific protein binding. PSA values regardless of levels should not be interpreted as absolute evidence of the presence or absence of disease. All values should be correlated with clinical findings and results of other investigations.

\*\*\*\*\* END OF THE REPORT \*\*\*\*\*

OUT SOURCE  
PARK HOSPITAL  
CGN



Sample no.

Dr. VAISHALI YADAV    Dr. REETU JADHAV    Dr. PARDIP KUMAR    S.C. GAUR  
 CONS. PATHOLOGIST    CONS. PATHOLOGIST    MICROBIOLOGIST & ICO    LAB INCHARGE    USER NM

*SAMAY*

(This is only professional opinion and not the diagnosis, Please correlate clinically)

J-Block, Sector-10, Near Court, Faridabad - 121004, Haryana

Tel.: 0129-4200000 E-mail : parkfaridabad@gmail.com



HR: 175 bpm

METS: 10.2

BP: ---/---

MpHR: 97% of 180

Speed: 3.4 mph

Grade: 14.0%

Raw ECG

BRUCE

(0.05-100)Hz

Ex Time 09:00

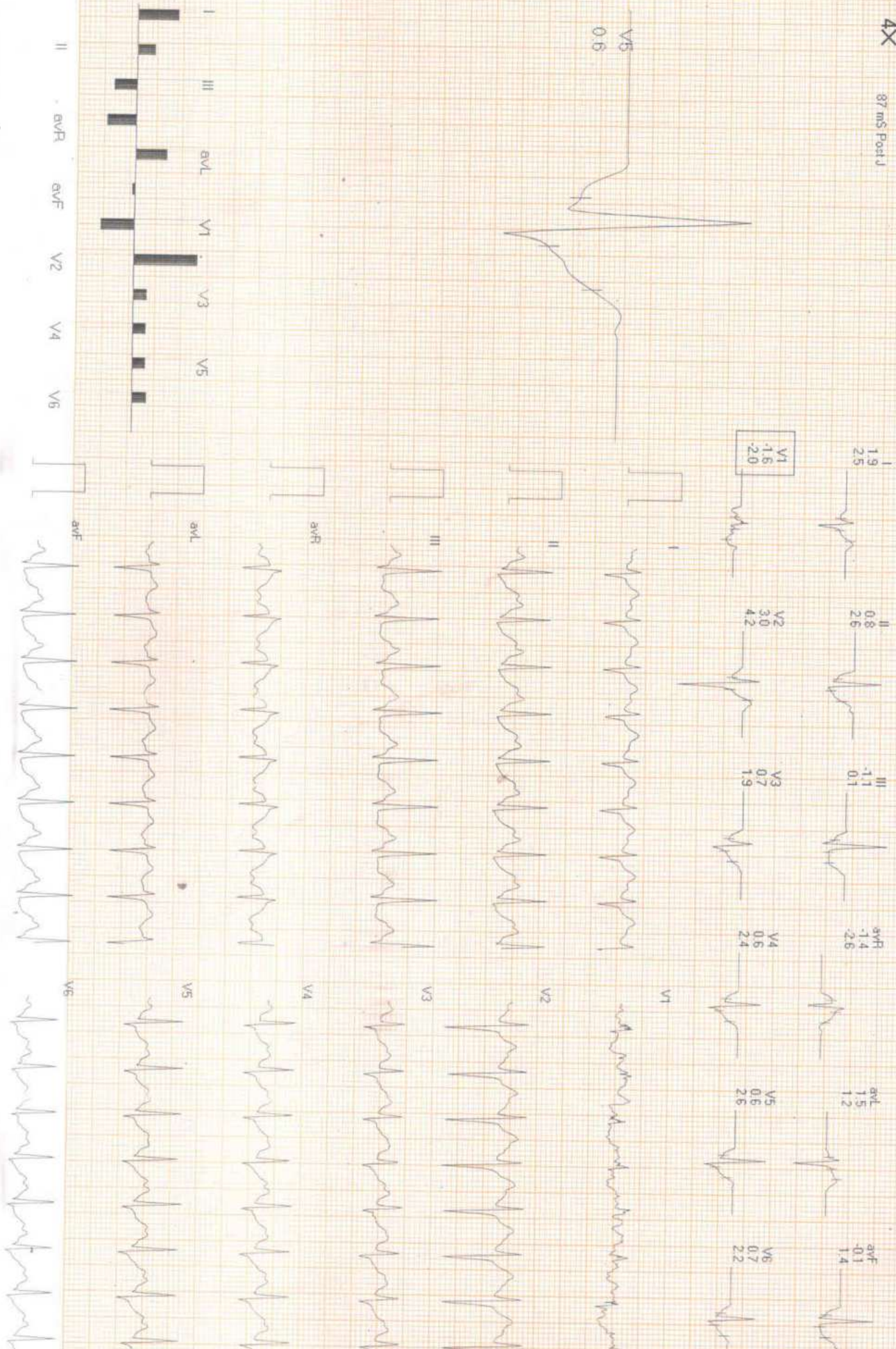
BLC: On

Notch: On

BRUCE: Stage 3

10.0 mm/mV

25 mm/Sec.





SS9/MR: IMTIAZ ANSARI 40 Yrs/Male 78 Kg/172 Cms  
 Date: 04-Oct-2023 11:13:25 AM  
 Ref. By : DR. RAKESH ARORA

04-Oct-2023 11:13:25 AM  
 Ref. By : DR. RAKESH ARORA

Protocol : BRUCE Objective :

| Stage    | Stage Time (Min:Sec) | Phase Time (Min:Sec) | Speed (mph) | Grade (%) | METS | H.R. (bpm) | B.P. (mmHg) | R.P.P. x100 | PVC | Comments |
|----------|----------------------|----------------------|-------------|-----------|------|------------|-------------|-------------|-----|----------|
| ExStart  |                      |                      |             |           |      |            |             |             |     |          |
| Stage 1  | 3:00                 | 3:01                 | 1.7         | 10.0      | 1.0  | 80         | -/-         | 0           | -   |          |
| Stage 2  | 3:00                 | 6:01                 | 2.5         | 12.0      | 4.7  | 128        | -/-         | 0           | -   |          |
| Stage 3  | 3:00                 | 9:01                 | 3.4         | 14.0      | 7.1  | 146        | -/-         | 0           | -   |          |
| PeakEx   | 0:19                 | 9:20                 | 4.2         | 16.0      | 10.2 | 175        | -/-         | 0           | -   |          |
| Recovery | 1:00                 |                      | 0.0         | 0.0       | 10.6 | 186        | -/-         | 0           | -   |          |
| Recovery | 2:21                 |                      | 0.0         | 0.0       | 4.3  | 158        | -/-         | 0           | -   |          |
| Recovery |                      |                      | 3.4         | 14.0      | 9.5  | 173        | -/-         | 0           | -   |          |

Medication:

History:

Test End Reason:

Findings:

The patient exercised according to BRUCE for 9:20, achieving a work level of Max METS 10.6. Resting heart rate initially 80 bpm, rose to a max heart rate of 186 bpm which represents 103% of maximum age predicted heart rate. Resting blood pressure 0/0 mmHg, rose to a maximum blood pressure of 0/0 mmHg. The exercise stress test was stopped due to

Parameters:

Exercise Time : 09:20  
 Max HR Attained : 186 bpm 103% of Max Predictable HR 180  
 Max BP : 0/0(mmHg)  
 Max Workload attained : 10.6(Good Effort Tolerance)

*Handwritten:* TMT is negative for inducible Aschamig  
 Good exercise Tolerance

*Signature:* Dr. Rakesh Kumar Arora  
 DM (Cardiology)  
 Registrar GMC - 16339C  
 Consultant Cardiologist  
 Path Hospital

Advice/Comments: