



Mediwheel
...Your wellness partner

Arcofemi Healthcare Pvt Ltd

(Formerly known as Arcofemi Healthcare Ltd)

F-701A, Lado Sarai, Mehrauli, New Delhi - 110030

Email: wellness@mediwheel.in, Website: www.mediwheel.in

Tel: +91-11-41195959, Fax: +91-11-29523020

CIN: U24240DL2011PTC216307

MEDICAL FITNESS CERTIFICATE

(To be signed by a registered medical practitioner holding a Medical degree)

This is to certify that **Mr. Laxmikant Kailash** aged, **31yr**. Based on the examination, I certify that he is in good mental and physical health and it is free from any physical defects such as deafness, colour blindness, and any chronic or contagious diseases.

Place: **Navi Mumbai**

Date: **24/06/2024**

Dr. Nitesh Kumar
MBBS

BCMR 47093
Name & Signature of

Medical officer

MEDICAL HEALTH CHECK- UP ASSESMENT FORM

NAME : Mr / Mrs Laxmikant Prasad. DATE: 24/06/24

AGE : 31 yrs

SEX: Male / Female

NMU: NMU00056817

DOCTOR'S NAME:
Health checkup

TEMP :	<u>97.2</u> ° f	BP :	<u>122/62</u> mmHg
PULSE :	<u>64</u> b/m	HEIGHT :	<u>165.</u> cm
RR :	<u>20</u> b/m	WEIGHT :	<u>73.8</u> kg
SPO2 :	<u>99 % RA</u>	HGT:	<u>—</u>

REMARK:



DEPARTMENT OF OPHTHALMOLOGY

MEDICOVER HOSPITALS

DATE: 24/06/24

PATIENT NAME: Mrs. Lakshmi Prasad

AGE / SEX: 31 / M

NAVI MUMBAI

UMR NO: N00005817

	RE	LE
VA (DISTANCE)	6/6	6/6p.
VA (NEAR)	NG	NG
COLOUR VISION	Normal	Normal.

V/A $\left\{ \begin{array}{l} 6/6 \\ \text{undilated} \\ 6/6p \end{array} \right.$

		SPHERE	CYLINDER	AXIS	VA
MRx	O D (R)	plano	—————		6/6, NG
	O S (L)	+	-0.50	30°	6/6, NG

HISTORY :

- H/O Squint (RE) : 2013.

- NO H/O DM or HTN thyroid.

- NO H/O Ocular trauma, Allergies & surgeries.

OCULAR FINDINGS : - H/O ? maxilla - mandibular surgery done repeatedly since 1999 upto 2012.

(BE) - lens-clear

(RE) - 15° hyperopia
(? mild restrictive dlt
(R) side maxilla surgery)

(Undilated) Disc $\left\{ \begin{array}{l} 0.2 \\ 0.2 \end{array} \right.$

ADVICE:

Refresh Tears eod qid 1777 X 1 month.

AP
DR. ANUSHREE VANLAKH





DEPARTMENT OF LABORATORY

NAVI MUMBAI

Patient Name : Mr. LAXMIKANT KAILASH PRASAD	Age / Gender : 31 Y(s)/Male
Bill No/ UMR No : NMBC75810/NMU0056817	Referred By : Dr. DMO
Received Dt : 24-Jun-24 10:42 am	Report Date : 24-Jun-24 11:44 am

FINAL REPORT

<u>Parameter</u>	<u>Specimen</u>	<u>Result Values</u>	<u>Biological Reference</u>	<u>Method</u>
COMPLETE BLOOD COUNT				
RBC				
R B C COUNT	Blood	4.08	4.5 - 5.5 10 ⁶ /μL	
HEMOGLOBIN		13.4	13.0 - 17.0 g/dl	
PCV/HCT		41.2	40 - 50 % 36 - 46 %	
MCV		101.0	83 - 101 fl 83 - 101 fl	
MCH		32.8	27 - 32 pg	
MCHC		32.5	31.5 - 34.5 g/dL	
RDW(cv)		14.5	11.6 - 14.0 %	
PLATELETS				
PLATELET COUNT	Blood	235	150 - 400 10 ³ /μL	
MPV		8.9	7.5 - 11.5 fl	
WBC				
TC (TOTAL LEUCOCYTE COUNT)	Blood	5.91	4.0 - 11.0 10 ³ /μl	
DIFFERENTIAL COUNT				
NEUTROPHILS	Blood	51	40 - 80 %	
LYMPHOCYTES		39	20 - 40 %	
MONOCYTES		05	02 - 10 %	
EOSINOPHILS		05	00 - 06 %	
BASOPHILS		00	00 - 01 %	
BLOOD GROUPING AND RH				
BLOOD GROUP	Blood	" A "		TUBE AGGLUTINATION
RH TYPE		POSITIVE		
ESR		19	0 - 10 mm/1st hour	WESTERGREN`S METHOD

*** End Of Report ***





MEDICOVER
HOSPITALS

DEPARTMENT OF LABORATORY

NAVI MUMBAI

Patient Name : Mr. LAXMIKANT KAILASH PRASAD
Age / Gender : 31 Y(s)/Male
Bill No/ UMR No : SHUKLA
: NMBC75810/NMU0056817
Referred By : Dr. DMO
Received Dt : 24-Jun-24 10:42 am
Report Date : 24-Jun-24 12:57 pm

Parameters **Specimen** **Result** **Biological Reference In Method**

Lab Incharge

Dr. PALLAVI SAXENA, MBBS MD(PATHOLOGY)
CONSULTANT PATHOLOGIST

Verified By : : 029855

Test results related only to the item tested.

No part of the report can be reproduced without written permission of the laboratory.





MEDICOVER
HOSPITALS

Patient ID:	NMU0056817	Patient Name:	LAXMIKANT KAILASH PRASAD SHUKLA
Age:	31 Years	Sex:	M
Accession Number:	NMBC75810	Modality:	DX
Referring Physician:	DR.DMO	Study:	CHEST
Study Date:	24-Jun-2024		

X RAY CHEST PA VIEW

Both lungs are clear.

The frontal cardiac dimensions are normal.

The pleural spaces are clear.

Both hilar shadows are normal in position and density.

No diaphragmatic abnormality is seen.

The soft tissues and bony thorax are normal.

Impression:

- **No significant abnormality is seen.**

Dr. Chetan S Ravi
MD, DM (Neuro-Radiology)
Consultant Radiologist

Date: 24-Jun-2024 13:04:15



DEPARTMENT OF LABORATORY

NAVI MUMBAI

Patient Name : Mr. LAXMIKANT KAILASH PRASAD	Age / Gender : 31 Y(s)/Male
Bill No/ UMR No : NMBC75810/NMU0056817	Referred By : Dr. DMO
Received Dt : 24-Jun-24 10:42 am	Report Date : 24-Jun-24 02:17 pm

FINAL REPORT

<u>Parameters</u>	<u>Specimen</u>	<u>Result</u>	<u>Biological Reference Intervals</u>	<u>Method</u>
CUE(COMPLETE URINE EXAMINATION)				
<u>PHYSICAL EXAMINATION</u>				
VOLUME	Urine	25ml		
COLOUR		PALE YELLOW	PALE YELLOW	
APPEARANCE		CLEAR	CLEAR	
DEPOSIT		ABSENT	ABSENT	
<u>CHEMICAL EXAMINATION</u>				
SPECIFIC GRAVITY	Urine	1.030	1.000 - 1.030	Dipstick
PH		5.0	5.0 - 8.0	Dipstick
PROTEIN		NEGATIVE	NEGATIVE	Dipstick/Heat coagulation test
GLUCOSE		ABSENT	ABSENT	Dipstick/Benedict's test
UROBILINOGEN		NORMAL	NORMAL	Dipstick
KETONE		NEGATIVE	NEGATIVE	Dipstick/Rothera's Nitroprusside test.
BILIRUBIN		NEGATIVE	NEGATIVE	Dipstick/Fouchet's test
BILE SALT		NEGATIVE	NEGATIVE	Hay's sulphur powder test
BILE PIGMENT		NEGATIVE	NEGATIVE	Fouchet test
NITRITE		NEGATIVE	NEGATIVE	Dipstick
LEUCOCYTE ESTERASE		NEGATIVE	NEGATIVE	
<u>MICROSCOPIC EXAMINATION</u>				
PUS CELLS	Urine	1-2	0 - 5 /hpf	MICROSCOPIC EXAMINATION
RBC		NIL	0 - 5 /hpf	MICROSCOPIC EXAMINATION
EPITHELIAL CELLS		1-2	0 - 5 /hpf	MICROSCOPIC EXAMINATION
CRYSTALS		NIL	NIL	MICROSCOPIC EXAMINATION
CASTS		NIL	NIL	MICROSCOPIC EXAMINATION
BACTERIA		ABSENT		MICROSCOPIC EXAMINATION
YEAST		ABSENT		MICROSCOPIC EXAMINATION
AMORPHOUS DEPOSITS		ABSENT		MICROSCOPIC EXAMINATION
MUCUS THREAD		ABSENT		MICROSCOPIC EXAMINATION

NOTE

Microscopic examination of urine is carried out on centrifuged urinary sediment.

*** End Of Report ***





MEDICOVER
HOSPITALS

DEPARTMENT OF LABORATORY

NAVI MUMBAI

Patient Name : Mr. LAXMIKANT KAILASH PRASAD	Age / Gender : 31 Y(s)/Male
Bill No/ UMR No : NMBC75810/NMU0056817 SHUKLA	Referred By : Dr. DMO
Received Dt : 24-Jun-24 10:42 am	Report Date : 24-Jun-24 02:17 pm

<u>Parameters</u>	<u>Specimen</u>	<u>Result</u>	<u>Biological Reference In Method</u>
-------------------	-----------------	---------------	---------------------------------------





DEPARTMENT OF LABORATORY

NAVI MUMBAI


Patient Name : Mr. LAXMIKANT KAILASH PRASAD
Age / Gender : 31 Y(s)/Male
Bill No/ UMR No : SHUKLA
NMBC75810/NMU0056817
Referred By : Dr. DMO
Received Dt : 24-Jun-24 10:42 am
Report Date : 24-Jun-24 01:18 pm

FINAL REPORT

<u>Parameters</u>	<u>Specimen</u>	<u>Result</u>	<u>Biological Reference Intervals</u>	<u>Method</u>
FBS (FASTING BLOOD GLUCOSE)				
FASTING BLOOD GLUCOSE	Plasma	98	Normal Range : 70 - 99 mg/dL	Hexokinase
SERUM CREATININE				
CREATININE		0.76	0.8 - 1.3 mg/dl	Method : jaffe
BUN(BLOOD UREA NITROGEN)				
BUN (Blood Urea Nitrogen.)		7	7.0 - 21.0 mg/dL	Calculated
SGPT (ALT)		17	<= 41 U/L	Method : UV without P5P
SERUM BILIRUBIN TOTAL		1.0	0.2 - 1.3 mg/dL	Jendrassik Grof
DIRECT BILIRUBIN		0.3	<= 0.20 mg/dL	Method: Diazo Method
INDIRECT BILIRUBIN		0.7	<= 1.0 mg/dL	
PLBS (POST LUNCH BLOOD GLUCOSE)		101	Norma Range : - < 140 mg/dL Impaired Glucose Tolerance : 140 - 199 mg/dL Diabetes Mellitus : - > 200 mg/dL	Hexokinase

*** End Of Report ***

Lab Incharge


Dr. PALLAVI SAXENA, MBBS MD(PATHOLOGY)
CONSULTANT PATHOLOGIST

Verified By : : 026560

Test results related only to the item tested.

No part of the report can be reproduced without written permission of the laboratory.



Patient ID:	NMU0056817	Patient Name:	LAXMIKANT KAILASH PRASAD SHUKLA
Age:	31 Years	Sex:	M
Accession Number:	NMBC75810	Modality:	DX
Referring Physician:	DR.DMO	Study:	CHEST
Study Date:	24-Jun-2024		

X RAY CHEST PA VIEW

Both lungs are clear.

The frontal cardiac dimensions are normal.

The pleural spaces are clear.


Both hilar shadows are normal in position and density.

No diaphragmatic abnormality is seen.

The soft tissues and bony thorax are normal.

Impression:

No significant abnormality is seen.



Dr. Chetan S Ravi
MD, DM (Neuro-Radiology)
Consultant Radiologist

Date: 24-Jun-2024 13:04:15

Rate 66 . Sinus rhythm.....normal P axis, V-rate 50- 99
. Probable inferior infarct, old.....Q>35mS, II III aVF
PR 137 . Borderline ST elevation, anterior leads.....ST >0.15mV in V1-V4
QRSD 91
QT 379
QTc 398

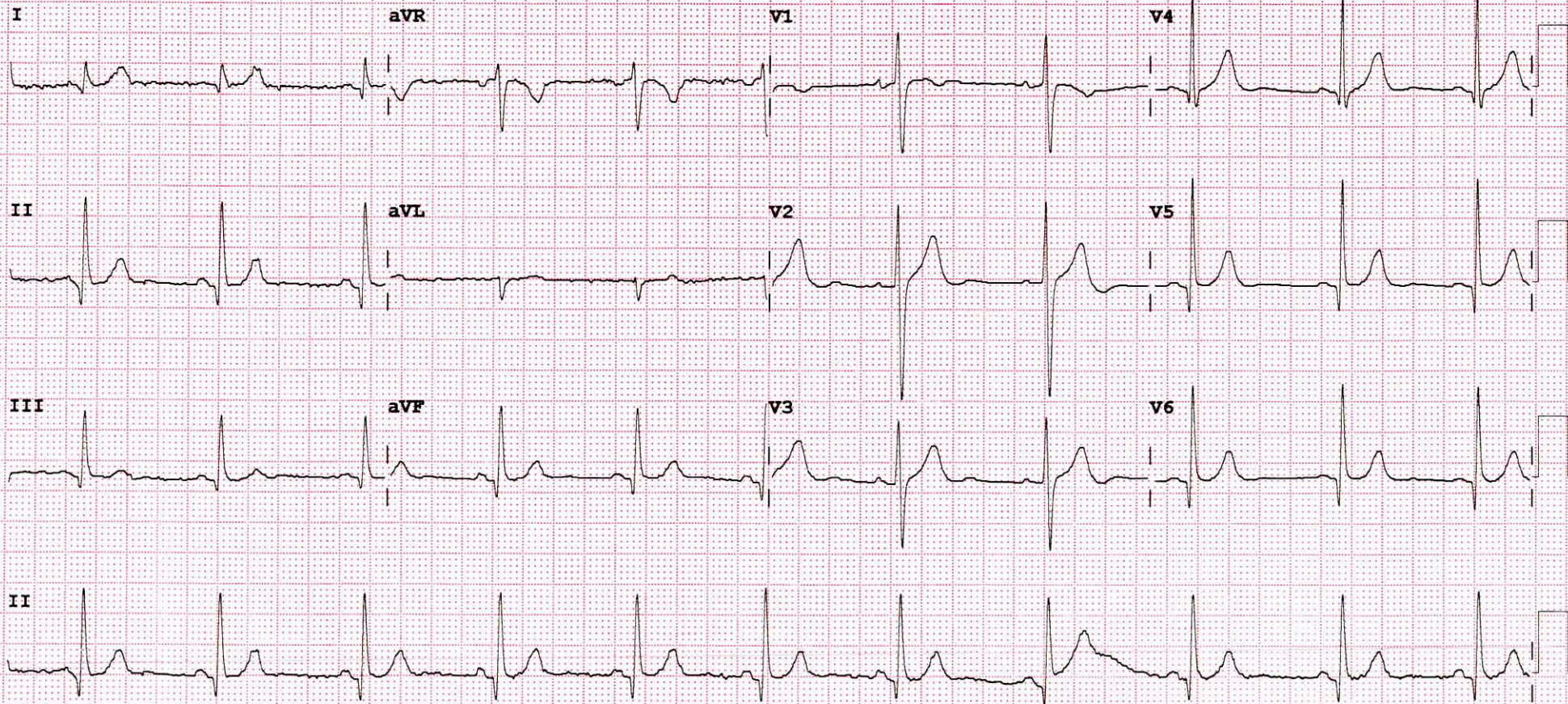
--AXIS--

P 61
QRS 75
T 50

- ABNORMAL ECG -

12 Lead; Standard Placement

Unconfirmed Diagnosis




zulbuz laxmilant marad 31/m

Routine check-up
no complaints
vital stable.



MEDICOVER
HOSPITALS

NAVI MUMBAI


Dr. Ahmed Khan
MBBS MD (Internal Medicine)
Consultant Physician & Diabetologist
Reg: 2015/01/0236

