




सत्यमेव जयते

भारत सरकार  
GOVERNMENT OF INDIA



வித்யா கோபாலகிருஷ்ணன்  
Vidhya Gopalakrishnan  
பிறந்த நாள் / DOB : 03/08/1978  
பெண் / FEMALE

7555 9770 2882



ஆதார் - சாதாரண மனிதனின் அதிகாரம்



भारतीय विशिष्ट पहचान प्राधिकरण  
UNIQUE IDENTIFICATION AUTHORITY OF INDIA

முகவரி:

கணவர் பெயர்:

கோபாலகிருஷ்ணன், பிண்டி

நோ 60 ஸ்ரீ லையா பிலா,

சந்தினிகேத்தேன் தெரு,

மாடம்பாக்கம், காஞ்சிபுரம்,

தமிழ் நாடு, 600126

Address:

W/O: Gopalakrishnan, plot no  
60 srilaya flo, santhiniketen  
street, Madambakkam,  
Kancheepuram, Tamil Nadu,  
600126



1947  
1800 300 1947



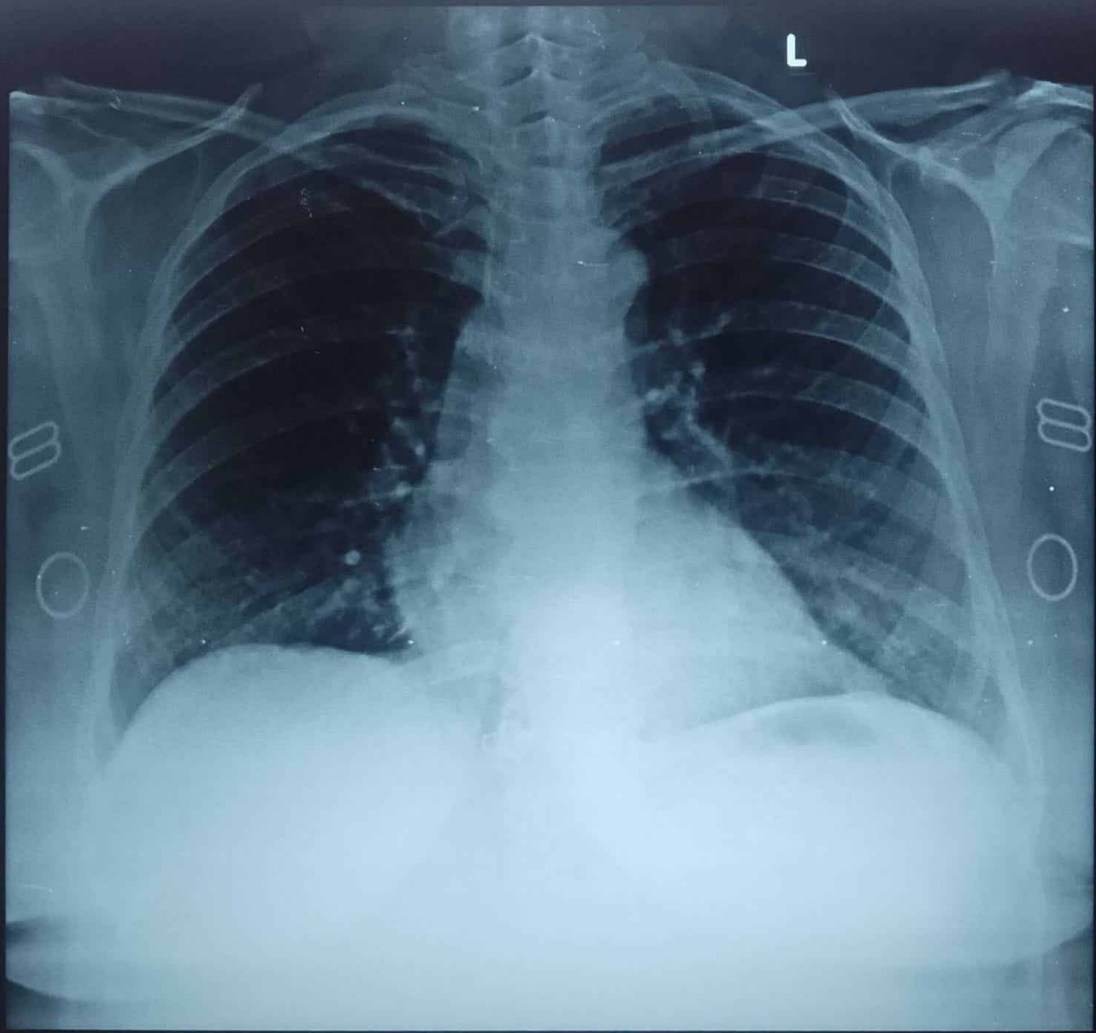
help@uidai.gov.in

WWW

www.uidai.gov.in

P.O.  
B.

1947,  
60 001



MRS.VIDHYA GOPALAKRISHNAN 46YRS 60698 CHEST-PA 28-09-2024  
MURUGAN HOSPITALS, KILPAUK,CHENNAI-10 PH NO: 7550053335 / 46448989




ID : 2409280002  
 Name :  
 Sex :  
 Divisions :  
 HR 99 bpm  
 P Dur / PR int 94 / 137ms  
 QRS Dur 92 ms  
 QT / QTc int 348 / 452 ms  
 P / QRS / T axis 65 / 33 / 26 °

Date/Time : 2024-09-28 09:11  
 Age :  
 BP : mmHg  
 Bed No. :  
 RV5-SV1 amp 1.537 / 0.808mV  
 RV5+SV1 amp 2.345mV  
 RV6/SV2 amp 1.395 / 0.558mV

Patient ID :  
 Height : cm  
 Weight : kg  
 Hospital No. :  
 Minnesota Code  
 8-7-3  
 4-5-0 (V6)  
 4-2-0 (I1)  
 5-5-0 (I1, V4, V5, V6)  
 9-4-1 (V3)

Hospital :  
 Diagnosis Info  
 812: Sinus Tachycardia  
 632: Slight ST-T Abnormality (I1)



Diagnosis for reference, ask your doctor to confirm  
 AUTO PRINT 6X2+1R 99bpm 10 mm/mV 0.05Hz 25Hz AC 50Hz 25 mm/sec Confirmed By:

**SIDHARTHAN MD**  
 Consultant Cardiologist  
 Reg. No. 62979





# MURUGAN HOSPITALS

HEALING HANDS



## ECHO CARDIOGRAM REPORT

NAME : MRS. VIDHYA GOPALAKRISHNAN PATIENT ID : MH20240060698  
AGE/SEX : 46 Years / FEMALE IP / OP NO : OP21097782  
CONSULTANT : DR. ARUN PRAKASH DATE : 28/09/2024

### 2D PLAX (mm)

RV - 24 mm  
AO - 27 mm  
LA - 22 mm

### M-Mode (mm)

IVS - 12 mm  
PW - 12 mm  
LVD - 24 mm  
LVS - 20 mm  
EF - 62 %  
FS - 31 %

### COLOR DOPPLER


Mitral regurgitation trivial

### DOPPLER (m/sec)

MITRAL E - 0.5 m/s  
MITRAL A - 0.7 m/s  
PULMONARY - 0.9 m/s  
AORTIC - 1.2 m/s  
TRICUSPID - 0.5 m/s

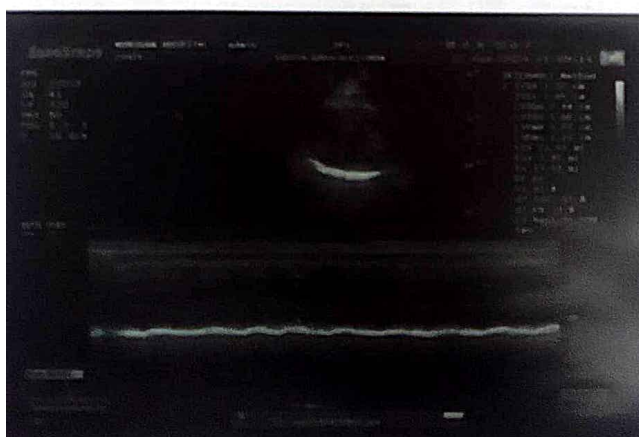
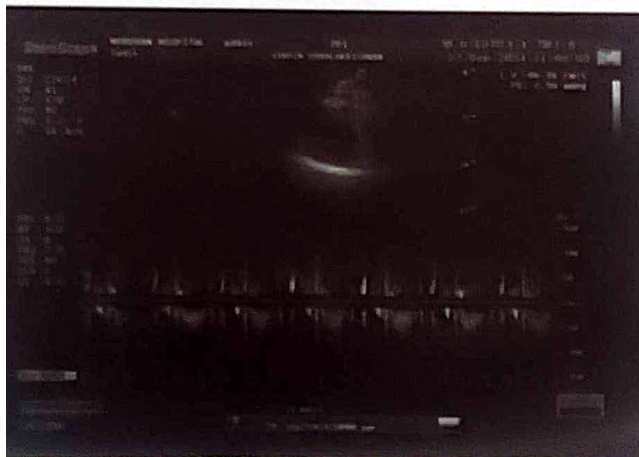
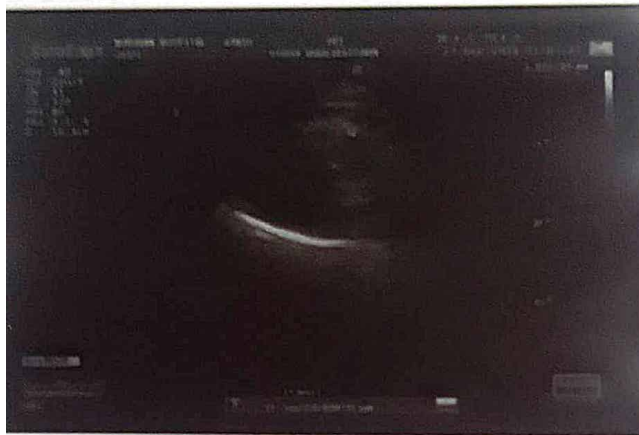### IMPRESSION:

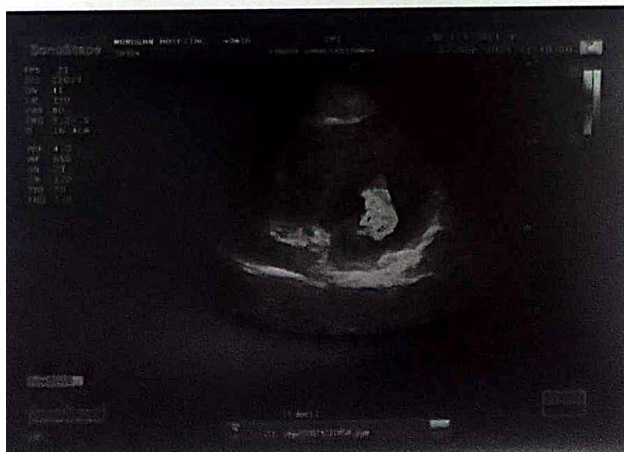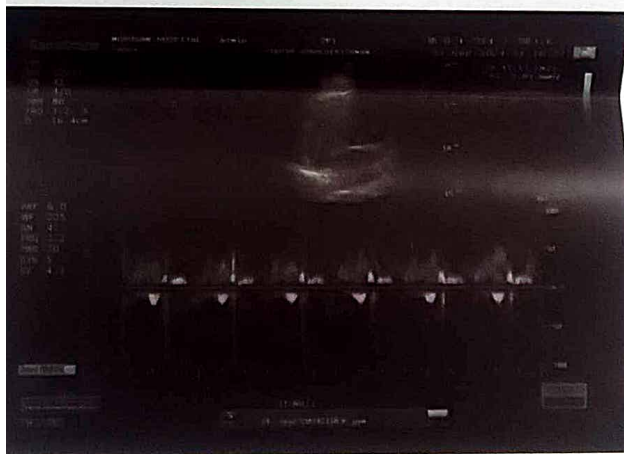
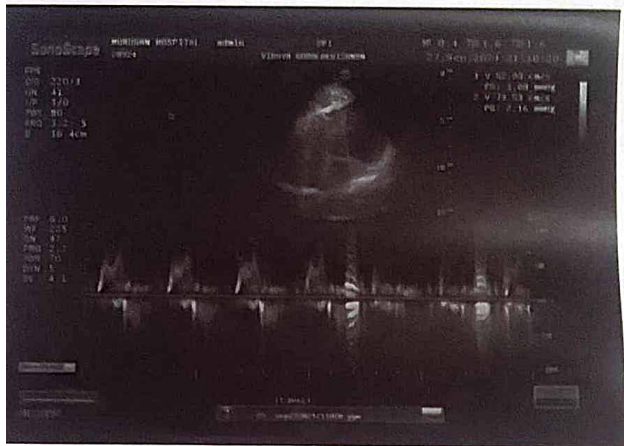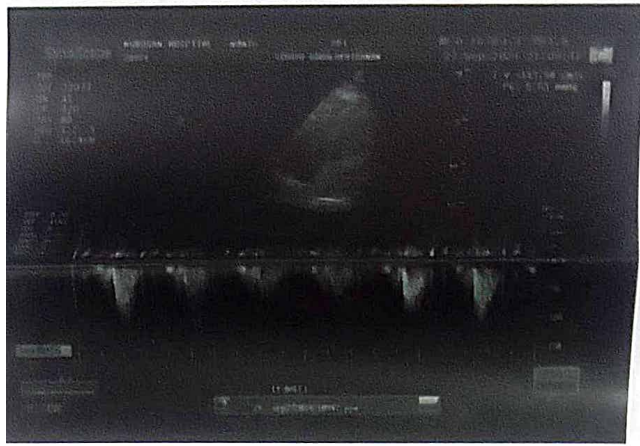No RWMA  
Normal LV Systolic function  
Grade I left ventricular diastolic dysfunction  
Normal RV function Mitral regurgitation trivial  
**Mitral regurgitation trivial**  
No pulmonary hypertension  
No pericardial effusion  
No clot/ Vegetation.

  
CONSULTANT CARDIOLOGIST

Healing Hearts and Lives

264/125, Kilpauk Garden Road, Kilpauk, Chennai - 600 010.  
Phone : +91 44 4644 8989 / 75500 53335 | Email : muruganhosp@gmail.com  
Website : www.muruganhospitals.in









# MURUGAN HOSPITALS

## HEALING HANDS



### SCAN REPORT

NAME	:MRS. VIDHYA GOPALAKRISHNAN	PATIENT ID	:MII20240060698
AGE/SEX	:46-Years / Female	IP / OP NO	:OP21097782
CONSULTANT	:DR. ARUN PRAKASH	DATE	:28/09/2024

### ULTRA SOUND SCAN OF ABDOMEN

**LIVER:** Enlarged in size and measures- 16.2 cm and **increased** in echotexture. No focal lesions are seen. No dilatation of intra-hepatic biliary radicals present. Hepatic veins and IVC appear normal. Portal vein is normal in caliber. Common bile duct is normal in caliber.

**GALL BLADDER:** Normal in size and wall thickness. No evidence of any calculus or mass present. No evidence of pericholecystic collections.

**PANCREAS:** Normal in size and echotexture. No focal lesions are seen. No evidence of calculi or calcifications. No evidence of pancreatic duct dilation.

**PARA AORTIC AREAS:** Aorta and IVC appear normal. No evidence of para aortic lymphadenopathy.

**SPLEEN:** Normal in size and measures- 8.9 cm. Normal in echotexture. No evidence of focal lesions.

**RIGHT KIDNEY:** Measures 9.7 x 3.8 cm and is normal in size and echotexture. Cortico medullary differentiation is well maintained. There is no hydronephrosis or mass.

**LEFT KIDNEY:** Measures 9.4 x 4.3 cm and is normal in size and echotexture. Cortico medullary differentiation is well maintained. There is no calculus or hydronephrosis or mass.

**Healing Hearts and Lives**

264/125, Kilpauk Garden Road, Kilpauk, Chennai - 600 010. Phone : +91 44 4644 8989 / 75500 53335  
Email : muruganhosp@gmail.com | Website : www.muruganhospitals.in



9/28/24, 10:47 AM

Preview

**URINARY BLADDER:** Normal in size, contour and wall thickness. There is no evidence of calculus or mass. No vesical diverticulum present.

**UTERUS AND OVARIES:** Post menopause status, normal in size and measures- 6.0 x 4.1 cm echotexture. ET- 4 mm

Both ovaries atrophic

No ascites present. No retroperitoneal lymphadenopathy present.

**IMPRESSION:**

- **Mild hepatomegaly with fatty infiltration**
- **No other significant abnormality detected in the visualized abdominal organs.**

  
**CONSULTANT RADIOLOGIST,**









# MURUGAN HOSPITALS

HEALING HANDS



## LAB REPORT

Patient Name : Mrs. VIDHYA GOPALAKRISHNAN  
Age / Gender : 46-Years / Female  
UHID ID : MH20240060698  
Doctor Name : Dr. ARUN PRAKASH

OP Report No. : INVA2117284  
Bill No. : INV2406789  
Sample Date : 28/09/2024 - 10:30 AM  
Report Date : 28/09/2024 - 03:14 PM

Test Name	Result	Units	Reference Interval
-----------	--------	-------	--------------------

### HAEMATOLOGY

#### COMPLETE BLOOD CELL COUNT(CBC)

HAEMOGLOBIN	13.5	gms/dl	male :13.0 - 17.0 female :12.0 - 15.0
PACKED CELL VOLUME	43.4	%	male : 40 - 50 female : 36 - 46
RBC COUNT	<u>5.25</u>	millions cells/cu.mm	female: 3.8 - 4.8 male : 4.5 - 5.5
TOTAL WBC	8,610	Cells/Cumm	4,000 - 11,000
<b>Differential Count</b>			
NEUTROPHILS	<u>68.7</u>	%	40 - 65
LYMPHOCYTES	<u>24.1</u>	%	30-50
EOSINOPHILS	3.1	%	01-06
MONOCYTES	4.1	%	1-10
BASOPHILS	00	%	0-2
ESR 60 MTS	10	mm	5 - 20
PLATELET COUNT	3.75	Lakhs/cumm	1.5 - 4.5
MCV	82.5	fL	76 - 96
MCH	<u>25.8</u>	pg	27 - 32
MCHC	31.2	gms/dl	30 - 36
BLOOD GROUPING & RH TYPING	"AB" POSITIVE		

Page 1 of 4

Healing Hearts and Lives

264/125, Kilpauk Garden Road, Kilpauk, Chennai - 600 010.  
Phone : +91 44 4644 8989 / 75500 53335 | Email : muruganhosp@gmail.com  
Website : www.muruganhospitals.in



# MURUGAN HOSPITALS

HEALING HANDS



## LAB REPORT

Patient Name : Mrs. VIDHYA GOPALAKRISHNAN  
Age / Gender : 46-Years / Female  
UHID ID : MH20240060698  
Doctor Name : Dr. ARUN PRAKASH

OP Report No. : INVA2117284  
Bill No. : INV2406789  
Sample Date : 28/09/2024 - 10:30 AM  
Report Date : 28/09/2024 - 03:14 PM

Test Name	Result	Units	Reference Interval
-----------	--------	-------	--------------------

### BIO CHEMISTRY

BLOOD SUGAR FASTING	<u>204</u>	mgs/dl	70-110
BLOOD SUGAR POST PRANDIAL	<u>295</u>	mgs/dl	80- 160
SERUM CREATININE	0.7	mg/dl	0.6-1.4
SERUM URIC ACID	5.2	mg/dl	male 3.1-7.0 , female 2.5-5.6

### LIPID PROFILE

TOTALCHOLESTEROL	<u>232</u>	mg/dl	< 200
TRIGLYCERIDE	99	mg/dl	< 150
HDL	48	mg/dl	35 - 80
VLDL	19	mg/dl	2 to 30
LDL	<u>165</u>	mg/dl	<130
CHOLESTEROL/ HDL RATIO	4.8	mg/dl	

**Healing Hearts and Lives**

264/125, Kilpauk Garden Road, Kilpauk, Chennai - 600 010.  
Phone : +91 44 4644 8989 / 75500 53335 | Email : muruganhosp@gmail.com  
Website : www.muruganhospitals.in



# MURUGAN HOSPITALS

HEALING HANDS



## LAB REPORT

Patient Name : Mrs. VIDHYA GOPALAKRISHNAN  
Age / Gender : 46-Years / Female  
UHID ID : MH20240060698  
Doctor Name : Dr. ARUN PRAKASH

OP Report No. : INVA2117284  
Bill No. : INV2406789  
Sample Date : 28/09/2024 - 10:30 AM  
Report Date : 28/09/2024 - 03:14 PM

Test Name	Result	Units	Reference Interval
<b>LIVER FUNCTION TEST</b>			
BILLIRUBIN(TOTAL)	0.8	mg/dl	0.0 -1.0
BILLIRUBIN(DIRECT)	0.2	mg/dl	0.1- 0.30
BILLIRUBIN(INDIRECT)	0.6	mg/dl	0.2-0.8
SGOT	23	IU/L	0-38
SGPT	32	IU/L	0.0-40
ALKALINE PHOSPHATASE	122	IU/L	40-140 4-6Years 93-309 13-15Years 74-390
TOTAL PROTEIN	7.8	gm/dl	6.6-8.7
ALBUMIN	4.3	gm/dl	3.5 - 5.5
GLOBULIN	3.5	gm/dl	2.0-3.5
AG RATIO	1.2		
GAMMA G T	32.0	U/L	< 55 U/ L
BLOOD UREA NITROGEN	9.3	mg/dl	7-21
HBA1C	10.5	%	normal: <6.0 good control: 6.1-7.0 fair control: 7.1- 8.0 poor control:8.1 -10.0 unsatisfactory: >10.0





# MURUGAN HOSPITALS

HEALING HANDS



## LAB REPORT

Patient Name : Mrs. VIDHYA GOPALAKRISHNAN

Age / Gender : 46-Years / Female

UHID ID : MH20240060698

Doctor Name : Dr. ARUN PRAKASH

OP Report No. : INVA2117284

Bill No. : INV2406789

Sample Date : 28/09/2024 - 10:30 AM

Report Date : 28/09/2024 - 03:14 PM

Test Name	Result	Units	Reference Interval
-----------	--------	-------	--------------------

### CLINICAL PATHOLOGY

URINE SUGAR (F)	(+)		
URINE SUGAR (PP)	(++)		
<b>URINE ROUTINE</b>			
COLOUR	PALE YELLOW		
APPEARANCE	CLEAR		
REACTION	ACIDIC		
ALBUMIN	NIL		
<b>DEPOSITES</b>			
PUS CELLS	3 - 4	/ HPF	
EPI CELLS	2 - 3	/ HPF	
RBC COUNT	NIL	/ HPF	
CAST	NIL		
CRYSTALS	NIL		
OTHERS	NIL		

SHENBAGAVALLI

Verified by

\*\*\* End of Report \*\*\*



Page 4 of 4

Healing Hearts and Lives

264/125, Kilpauk Garden Road, Kilpauk, Chennai - 600 010.

Phone : +91 44 4644 8989 / 75500 53335 | Email : muruganhosp@gmail.com

Website : www.muruganhospitals.in



# MURUGAN HOSPITALS

HEALING HANDS



## LAB REPORT

Patient Name : Mrs. VIDHYA GOPALAKRISHNAN  
Age / Gender : 46-Years / Female  
UHID ID : MH20240060698  
Doctor Name : Dr. ARUN PRAKASH

OP Report No. : INVA2117284  
Bill No. : INV2406789  
Sample Date : 28/09/2024 - 10:30 AM  
Report Date : 28/09/2024 - 07:18 PM

Test Name	Result	Units	Reference Interval
-----------	--------	-------	--------------------


### ENDOCRINOLOGY

T3	0.825	ng/ml	0.52-1.85
T4	8.832	ug/dl	5.0 -13.0 ug/dl
TSH	1.747	uIU/ml	0.39 - 6.10 uIU/ml

KAVIYARASAN

Verified by

\*\*\* End of Report \*\*\*



Healing Hearts and Lives

264/125, Kilpauk Garden Road, Kilpauk, Chennai - 600 010.  
Phone : +91 44 4644 8989 / 75500 53335 | Email : muruganhosp@gmail.com  
Website : www.muruganhospitals.in