



DEPARTMENT OF PATHOLOGY

Patient Name :	Mr. RAVI SHANKER	Bill Date :	01/04/2024
MR No :	30669	Reporting Date :	03/04/2024
Age/Sex :	47 Years 11 Months 12 Days / Male	Sample ID :	75849
Type :	OPD	Bill/Req. No. :	24099717
TPA/Corporate :	MEDIWHEEL	Ref Doctor :	Dr.CONSULTANT

Test	Result	Bio. Ref. Interval	Units
THYROID PROFILE			
TRI-IODOTHYRONINE (T3)	1.00	0.60 - 1.81	ng/ml
THYROXINE (T4)	8.5	5.01 - 12.45	µg/dL
THYROID STIMULATING HORMONE	2.54	0.5-5.50	µIU/ml

***** END OF THE REPORT *****



Sample no.

Dr. VAISHALI YADAV Dr. VIGYAN MISHRA Dr. PARDIP KUMAR S.C. GAUR
 CONS.PATHOLOGIST CONS.PATHOLOGIST MICROBIOLOGIST & ICO LAB INCHARGE USER NM SEHDEV

(This is only professional opinion and not the diagnosis, Please correlate clinically)

Block, Sector-10, Near Court, Faridabad - 121004, Haryana
 Tel.: 0129-4200000 E-mail : parkfaridabad@gmail.com



DEPARTMENT OF PATHOLOGY

Patient Name	: Mr. RAVI SHANKER	Bill Date	: 01/04/2024
MR No	: 30669	Reporting Date	: 03/04/2024
Age/Sex	: 47 Years 11 Months 12 Days / Male	Sample ID	: 75849
Type	: OPD	Bill/Req. No.	: 24099717
TPA/Corporate	: MEDIWHEEL	Ref Doctor	: Dr.CONULTANT

Test	Result	Bio. Ref. Interval	Units
------	--------	--------------------	-------

PSA - TOTAL (PROSTATIC SPECIFIC ANTIGEN) - CANCER MARKER

PROSTATE SPECIFIC ANTIGEN(PSA)	0.75	0.0 - 4.0	ng/ml
--------------------------------	------	-----------	-------

Note : Decrease in total PSA level is seen 24 to 48 hours after ejaculation. Decrease in total PSA level occurs after prostate ctomy and orchidectomy. successful radiation therapy and therapy with anti-androgen drugs result in decline in PSA levels, over a period of time.

*Results of these tests should always be interpreted in conjunction with patients medical history, clinical presentation and other findings.

*The test has been performed in Park Hospital Sector-47, Gurgaon.

***** END OF THE REPORT *****



Sample no.

Dr. VAISHALI YADAV	Dr. VIGYAN MISHRA	Dr. PARDIP KUMAR	S.C. GAUR
CONS. PATHOLOGIST	CONS. PATHOLOGIST	MICROBIOLOGIST & ICO	LAB INCHARGE .USER NM SEHDEV

(This is only professional opinion and not the diagnosis, Please correlate clinically)

J-Block, Sector-10, Near Court, Faridabad - 121004, Haryana

Tel.: 0129-4200000 E-mail : parkfaridabad@gmail.com



DEPARTMENT OF PATHOLOGY

Patient Name : Mr. RAVI SHANKER
 MR No : 30669
 Age/Sex : 47 Years 11 Months 12 Days / Male
 Type : OPD
 TPA/Corporate : MEDIWHEEL

Bill Date : 01/04/2024
 Reporting Date : 01/04/2024
 Sample ID : 75849
 Bill/Req. No. : 24099717
 Ref Doctor : Dr. CONSULTANT

Test	Result	Bio. Ref. Interval	Units
CBC			
HAEMOGLOBIN	13.6	12 - 16	gm/dL
PACKED CELL VOLUME	46.5	35.0 - 50.0	%
RED BLOOD CELL COUNT	5.19	3.5 - 5.5	millions/ μ L
MEAN CORPUSCULAR VOLUME	89.5	83 - 101	fL
MEAN CORPUSCULAR HAEMOGLOBIN	26.2 L	27 - 31	pg
MEAN CORPUSCULAR HB CONC	29.2 L	33 - 37	g/dl
RDW	13.8	11.6 - 14.5	%
TOTAL LEUCOCYTE COUNT	6690	4000-11000	/ μ L
DIFFERENTIAL COUNT			
NEUTROPHILS	50	40.0 - 80.0	%
LYMPHOCYTES	40	20 - 40	%
MONOCYTES	07	2.0 - 10.0	%
EOSINOPHILS	03	0.0 - 5.0	%
BASOPHILS	00	0.0 - 2.0	%
PLATELET COUNT	1.89	1.50 - 4.50	lac/cumm

***** END OF THE REPORT *****



Sample no

Dr. VIGYAN MISHRA
 CONS. PATHOLOGIST

Dr. VAISHALI YADAV Dr. REETU JADHAV Dr. PARDIP KUMAR S.C. GAUR
 CONS. PATHOLOGIST CONS. PATHOLOGIST MICROBIOLOGIST & ICO LAB INCHARGE USER NM SAMAY

(This is only professional opinion and not the diagnosis, Please correlate clinically)

J-Block, Sector-10, Near Court, Faridabad - 121004, Haryana

Tel.: 0129-4200000 E-mail : parkfaridabad@gmail.com



DEPARTMENT OF PATHOLOGY

Patient Name : Mr. RAVI SHANKER

MR No : 30669

Age/Sex : 47 Years 11 Months 12 Days / Male

Type : OPD

TPA/Corporate : MEDIWHEEL

Bill Date : 01/04/2024

Reporting Date : 01/04/2024

Sample ID : 75849

Bill/Req. No. : 24099717

Ref Doctor : Dr.CONSULTANT

Test	Result	Bio. Ref. Interval	Units
BLOOD SUGAR FASTING			
PLASMA GLUCOSE FASTING	89.63	60 - 110	mg/dl

***** END OF THE REPORT *****



Sample no.

Dr.VIGYAN MISHRA
CONS.PATHOLOGIST

Dr. VAISHALI YADAV Dr.REETU JADHAV Dr. PARDIP KUMAR S.C.GAUR
 CONS.PATHOLOGIST CONS.PATHOLOGIST MICROBIOLOGIST & ICO LAB INCHARGE USER NM DEEPCHAND

(This is only professional opinion and not the diagnosis, Please correlate clinically)

J-Block, Sector-10, Near Court, Faridabad - 121004, Haryana

Tel.: 0129-4200000 E-mail : parkfaridabad@gmail.com



DEPARTMENT OF PATHOLOGY

Patient Name : Mr. RAVI SHANKER
 MR No : 30669
 Age/Sex : 47 Years 11 Months 12 Days / Male
 Type : OPD
 TPA/Corporate : MEDIWHEEL

Bill Date : 01/04/2024
 Reporting Date : 01/04/2024
 Sample ID : 75849
 Bill/Req. No. : 24099717
 Ref Doctor : Dr.CONSULTANT

Test	Result	Bio. Ref. Interval	Units
LFT (LIVER FUNCTION TEST)			
LFT			
TOTAL BILIRUBIN	1.1	0 - 1.2	mg/dL
DIRECT BILIRUBIN	0.3	0 - 0.4	mg/dL
INDIRECT BILIRUBIN	0.8 H	0.10 - 0.6	mg/dL
SGOT (AST)	27	0 - 45	U/L
SGPT (ALT)	37	0 - 45	U/L
ALKALINE PHOSPHATASE	79.1	30 - 170	IU/L
TOTAL PROTEIN	6.5	6.4 - 8.0	g/dL
ALBUMIN	4.6	3.3 - 5.5	g/dL
GLOBULIN	1.9 L	2.3 - 4.5	g/dL
A/G RATIO	2.42 H	1.1 - 2.2	

***** END OF THE REPORT *****



Sample no.

Dr.VIGYAN MISHRA
CONS.PATHOLOGIST

Dr. VAISHALI YADAV Dr.REETU JADHAV Dr. PARDIP KUMAR S.C.GAUR
 CONS.PATHOLOGIST CONS.PATHOLOGIST MICROBIOLOGIST & ICO LAB INCHARGE USER NM DEEPCHAND

(This is only professional opinion and not the diagnosis, Please correlate clinically)

J-Block, Sector-10, Near Court, Faridabad - 121004, Haryana

Tel.: 0129-4200000 E-mail : parkfaridabad@gmail.com



DEPARTMENT OF PATHOLOGY

Patient Name : Mr. RAVI SHANKER

MR No : 30669

Age/Sex : 47 Years 11 Months 12 Days / Male

Type : OPD

TPA/Corporate : MEDIWHEEL

Bill Date : 01/04/2024

Reporting Date : 01/04/2024

Sample ID : 75849

Bill/Req. No. : 24099717

Ref Doctor : Dr.CONSULTANT

Test	Result	Bio. Ref. Interval	Units
KFT (RENAL PROFILE)			
KFT			
SERUM UREA	18.3	10 - 45	mg/dL
SERUM CREATININE	1.3	0.4 - 1.4	mg/dL
SERUM URIC ACID	5.7	2.5 - 7.0	mg/dL
SERUM SODIUM	140	136 - 148	mmol/L
SERUM POTASSIUM	3.8	3.5 - 5.5	mmol/L
CHLORIDE	96.0	96 - 106	mmol/L

***** END OF THE REPORT *****



Sample no.

Dr.VIGYAN MISHRA
CONS.PATHOLOGIST

Dr. VAISHALI YADAV Dr.REETU JADHAV Dr. PARDIP KUMAR S.C.GAUR
CONS.PATHOLOGIST CONS.PATHOLOGIST MICROBIOLOGIST & ICO LAB INCHARGE USER NM DEEPCHAND

(This is only professional opinion and not the diagnosis, Please correlate clinically)

J-Block, Sector-10, Near Court, Faridabad - 121004, Haryana
Tel.: 0129-4200000 E-mail : parkfaridabad@gmail.com



DEPARTMENT OF PATHOLOGY

Patient Name : Mr. RAVI SHANKER
 MR No : 30669
 Age/Sex : 47 Years 11 Months 12 Days / Male
 Type : OPD
 TPA/Corporate : MEDIWHEEL

Bill Date : 01/04/2024
 Reporting Date : 01/04/2024
 Sample ID : 75849
 Bill/Req. No. : 24099717
 Ref Doctor : Dr.CONULTANT

Test	Result	Bio. Ref. Interval	Units
LIPID PROFILE			
TOTAL CHOLESTEROL	232.46 H	120.0 - 200.0	mg/dL
SERUM TRIGLYCERIDES	102.83	40.0 - 160.0	mg/dl
HDL-CHOLESTEROL	46.65	30 - 70	mg/dl
VLDL CHOLESTEROL	20.57	6 - 32	mg/dL
LDL	165.24 H	50 - 135	mg/dl
LDL CHOLESTEROL/HDL RATIO	3.54 H	1.0 - 3.0	mg/dL
TOTAL CHOLESTEROL/HDL RATIO	4.98	2.0 - 5.0	mg/dl

***** END OF THE REPORT *****



Sample no.

Dr.VIGYAN MISHRA
CONS.PATHOLOGIST

Dr. VAISHALI YADAV Dr.REETU JADHAV Dr. PARDIP KUMAR S.C.GAUR
CONS.PATHOLOGIST CONS.PATHOLOGIST MICROBIOLOGIST & ICO LAB INCHARGE USER NM DEEPCHAND

(This is only professional opinion and not the diagnosis, Please correlate clinically)

J-Block, Sector-10, Near Court, Faridabad - 121004, Haryana

Tel.: 0129-4200000 E-mail : parkfaridabad@gmail.com



DEPARTMENT OF PATHOLOGY

Patient Name : Mr. RAVI SHANKER	Bill Date : 01/04/2024
MR No : 30669	Reporting Date : 02/04/2024
Age/Sex : 47 Years 11 Months 12 Days / Male	Sample ID : 75849
Type : OPD	Bill/Req. No. : 24099717
TPA/Corporate : MEDIWHEEL	Ref Doctor : Dr.CONSULTANT

Test	Result	Bio. Ref. Interval	Units
------	--------	--------------------	-------

HB A1C GLYCOSYLATED HAEMOGLOBIN

HBA1C	6.0		%
-------	-----	--	---

Note : Non-Diabetics 4.0 - 6.0 %

In Diabetics
 Good Control 6.1 - 6.8 %
 Fair Control 6.9 - 7.6 %
 Poor Control > 7.6 %

OUT SOURCE
PARK HOSPITAL
GGN

***** END OF THE REPORT *****



Sample no.

Dr.VIGYAN MISHRA
CONS.PATHOLOGIST

Dr. VAISHALI YADAV Dr.REETU JADHAV Dr. PARDIP KUMAR S.C.GAUR
CONS.PATHOLOGIST CONS.PATHOLOGIST MICROBIOLOGIST & ICO LAB INCHARGE USER NM SAMAY

(This is only professional opinion and not the diagnosis, Please correlate clinically)

J-Block, Sector-10, Near Court, Faridabad - 121004, Haryana
 Tel.: 0129-4200000 E-mail : parkfaridabad@gmail.com



DEPARTMENT OF PATHOLOGY

Patient Name : Mr. RAVI SHANKER

MR No : 30669

Age/Sex : 47 Years 11 Months 12 Days / Male

Type : OPD

TPA/Corporate : MEDIWHEEL

Bill Date : 01/04/2024

Reporting Date : 01/04/2024

Sample ID : 75849

Bill/Req. No. : 24099717

Ref Doctor : Dr.CONULTANT

Test	Result	Bio. Ref. Interval	Units
------	--------	--------------------	-------

URINE ROUTINE AND MICROSCOPY

PHYSICAL CHARACTERSTICS

QUANTITY	30.0 ML	5 - 100	ML
COLOUR	Pale Yellow		
TURBIDITY	Clear	clear	
SPECIFIC GRAVITY	1.025	1.003 - 1.030	
PH	5.0	Acidic	

CHEMICAL EXAMINATION-1

URINE PROTEIN	NIL	NIL	
GLUCOSE	NIL	NIL	

MICRO.EXAMINATION

PUS CELL	0 - 1/HPF		CELLS/HPF
RED BLOOD CELLS	Nil	0-2	CELLS/HPF
EPITHELIAL CELLS	1-2/HPF	0-5	CELLS/HPF
CASTS	NIL	NIL	CELLS/HPF
CRYSTALS	NIL	NIL	CELLS/HPF
OTHER	NIL		

***** END OF THE REPORT *****



Sample no.

Dr.VIGYAN MISHRA
CONS.PATHOLOGIST

Dr. VAISHALI YADAV
CONS.PATHOLOGIST

Dr.REETU JADHAV
CONS.PATHOLOGIST

Dr. PARDIP KUMAR
MICROBIOLOGIST & ICO

S.C.GAUR

LAB INCHARGE USER NM SEHDEV

(This is only professional opinion and not the diagnosis, Please correlate clinically)

J-Block, Sector-10, Near Court, Faridabad - 121004, Haryana

Tel.: 0129-4200000 E-mail : parkfaridabad@gmail.com



DEPARTMENT OF PATHOLOGY

Patient Name : Mr. RAVI SHANKER
MR No : 30669
Age/Sex : 47 Years 11 Months 12 Days / Male
Type : OPD
TPA/Corporate : MEDIWHEEL
Bill Date : 01/04/2024
Reporting Date : 01/04/2024
Sample ID : 75849
Bill/Req. No. : 24099717
Ref Doctor : Dr.CONULTANT

Test	Result	Bio. Ref. Interval	Units
------	--------	--------------------	-------

BLOOD GROUPING AND rh FACTOR

BLOOD GROUP	" B " Rh POSITIVE		
-------------	-------------------	--	--

***** END OF THE REPORT *****



Sample no.

Dr.VIGYAN MISHRA
CONS.PATHOLOGIST

Dr. VAISHALI YADAV Dr.REETU JADHAV Dr. PARDIP KUMAR S.C.GAUR
CONS.PATHOLOGIST CONS.PATHOLOGIST MICROBIOLOGIST & ICO LAB INCHARGE USER NM SUNIL

(This is only professional opinion and not the diagnosis, Please correlate clinically)

J-Block, Sector-10, Near Court, Faridabad - 121004, Haryana

Tel.: 0129-4200000 E-mail : parkfaridabad@gmail.com



DEPARTMENT OF PATHOLOGY

Patient Name : Mr. RAVI SHANKER
 MR No : 30669
 Age/Sex : 47 Years 11 Months 12 Days / Male
 Type : OPD
 TPA/Corporate : MEDIWHEEL
 Bill Date : 01/04/2024
 Reporting Date : 01/04/2024
 Sample ID : 75849
 Bill/Req. No. : 24099717
 Ref Doctor : Dr.CONSULTANT

Test	Result	Bio. Ref. Interval	Units
BLOOD SUGAR 2 HR. PP			
BLOOD SUGAR P.P.	109.23	80 - 150	mg/dl

***** END OF THE REPORT *****



Sample no.

Dr.VIGYAN MISHRA
CONS.PATHOLOGIST

Dr. VAISHALI YADAV Dr.REETU JADHAV Dr. PARDIP KUMAR S.C.GAUR
 CONS.PATHOLOGIST CONS.PATHOLOGIST MICROBIOLOGIST & ICO LAB INCHARGE USER NM SUNIL

(This is only professional opinion and not the diagnosis, Please correlate clinically)

J-Block, Sector-10, Near Court, Faridabad - 121004, Haryana
 Tel.: 0129-4200000 E-mail : parkfaridabad@gmail.com



ECHO REPORT

Name of the patient: MR: RAVI SHANKER Age: 47 Sex: Male Female

UHID No: 30669 IPD No: 24099913 Date: 01-04-2024

Refer By Doctor: DR. RAKESH ARORA

LVEF% 60%

2D ECHO

> Mitral Value Normal Pulmonary Value H Pulm

> Artery H

> Aortic avive H Tricuspid valve H

2D RWMA

> NO RWMA (Regional wall motion abnormality) at rest

COLD DOPPLER

> NO Significant Vavular stenosis / Regurgiation

COMMENTS AND SUMMARY

> All cardiac chambers of Normal size and shape NO dilatation or hypertrophy.

> NO RWMA (Regional wall motion abnormality) at rest

> NO Cloth / Vegetation/ pericardial effusion

> LV -60% Systolic function

> NO Significant Vavular stenosis / Regurgiation

Final Impression

> EF at Rest 60%

COMMENTS 2DECHO & Color Doppler study was

Consultant Cardiology

Doctor Name : Dr.

Date :

Dr. Rakesh Kumar Arora
MBBS, MD, DM (Cardiology)
Reg. No. DMC - 16395
Signature Consultant - Cardiology
Park Hospital, Faridabad

HR: 122 bpm

METS: 4.7

BP: 120/80

MPHR: 73% of 165

Speed: 1.7 mph

Grade: 10.0%

Raw ECG

BRUCE

(0.05-100)Hz

Ex Time 03:00

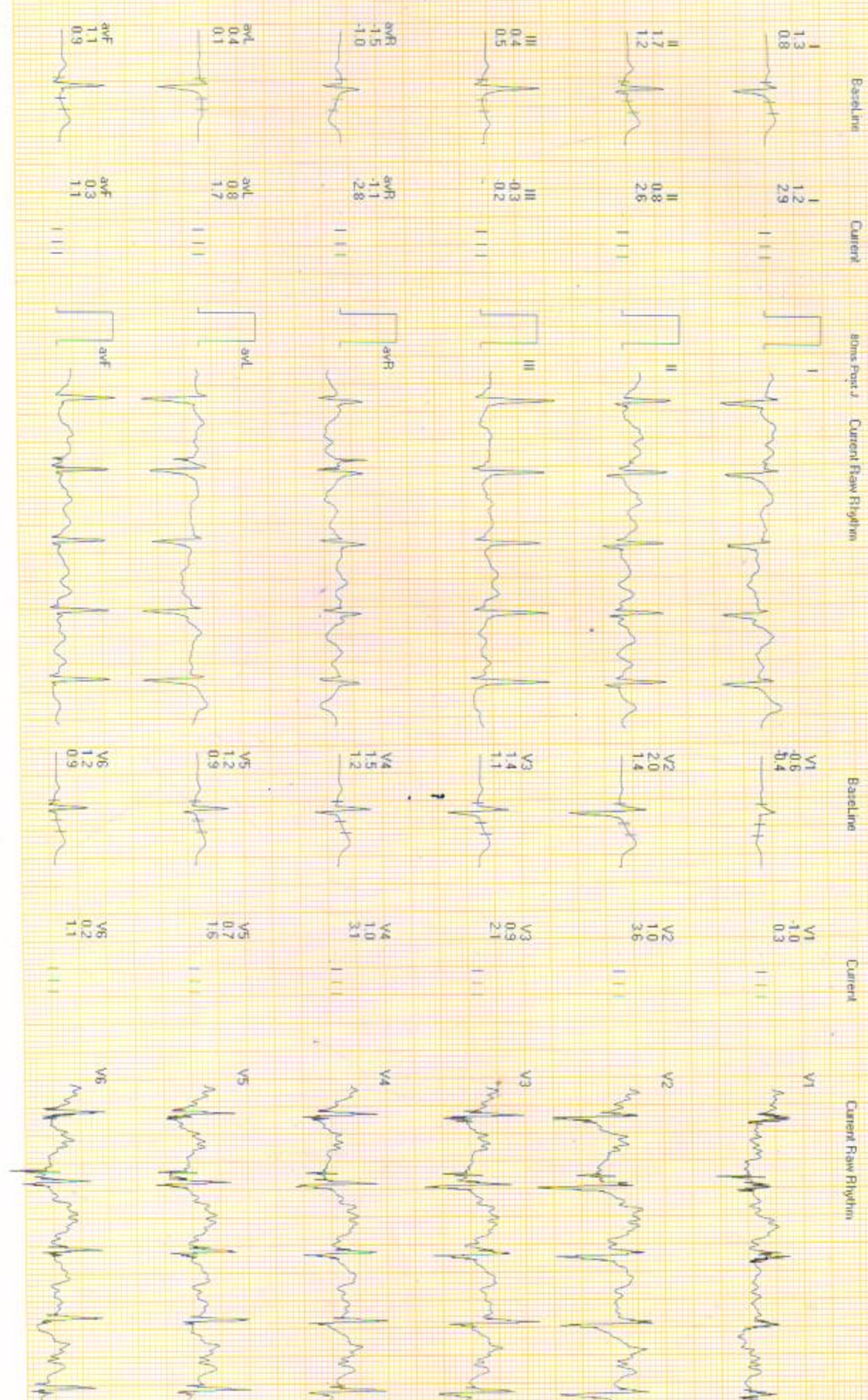BLC: On

Notch: On

Stage 1 (03:00

10.0 mm/mV

25 mm/Sec.





DEPARTMENT OF RADIOLOGY

Patient Name	Mr RAVI SHANKER	Billed Date	: 01/04/2024	10.26 AM
Reg No	30669	Reported Date	: 01/04/2024	
Age/Sex	47 Years 11 Months 12Days / Male	Req. No.	: 24099717	
Type	OPD	Consultant Doctor	: Dr. CONSULTANT	

X-RAY CHEST AP/PA

Bilateral lungs appears normal.

Both hila are normal in size, have equal density and bear normal relationship.

The heart and trachea are central in position and no mediastinal abnormality is visible.

The cardiac size is normal for patient age and view.

The domes of the diaphragms are normal in position and show smooth outline.

To be correlated clinically

DR BINOD KR CHAUDHARY
MBBS, MD
CONSULTANT RADIOLOGIST

(This is only professional opinion and not the diagnosis, Please correlate clinically)



DEPARTMENT OF RADIOLOGY

Patient Name	Mr RAVI SHANKER	Billed Date	: 01/04/2024	10.26 AM
Reg No	30669	Reported Date	: 01/04/2024	
Age/Sex	47 Years 11 Months 12Days / Male	Req. No.	: 24099717	
Type	OPD	Consultant Doctor	: Dr. CONSULTANT	

USG WHOLE ABDOMEN

LIVER : The liver is normal in size, shape and echotexture. No evidence of any focal lesion. IHBR is NOT dilated. Portal vein is normal.

GALL BLADDER :The gall bladder is well distended. No evidence any calculus or mass seen. GB wall thickness with in normal limits. No evidence of pericholecystic fluid is seen. The common bile duct is normal.

SPLEEN :The spleen is normal in size and shape. Its echotexture is homogeneous. No evidence of focal lesion is noted. Splenic vein is normal.

PANCREAS :The pancreas is normal in size, shape, contours and echotexture.

BILATERAL KIDNEYS : The bilateral kidneys are normal in size and echotexture. Cortico-medullary differentiation is maintained. There is no evidence of obvious calculus or hydronephrosis seen.

URINARY BLADDER :The urinary bladder is well distended. Wall thickness within normal limits. No evidence of calculus is seen. No evidence of mass or diverticulum is noted.
Pre void urine vol : 125cc Post void urine vol : 5cc


PROSTATE: Prostate appears normal in size (15cc), shape and echotexture.

No free fluid is seen in peritoneal cavity.

No evidence of obvious retroperitoneal or mesenteric lymphadenopathy is seen.

IMPRESSION:- USG WHOLE ABDOMEN REVEALS NO OBVIOUS ABNORMALITY.

TO BE CORRELATED CLINICALLY.


DR BINOD KR CHAUDHARY
MBBS,MD
CONSULTANT RADIOLOGIST

(This is only professional opinion and not the diagnosis, Please correlate clinically)

J-Block, Sector-10, Near Court, Faridabad - 121004, Haryana

Tel.: 0129-4200000 E-mail : parkfaridabad@gmail.com

RR : 91
 PR : 657
 P-R : 163
 QRS : 88
 QT/QTc : 332/409
 P/QRS/T : 56/97/54
 RV5/SV1 : 0.850/0.090 mV
 RV5-SV1 : 0.940 mV

ID : 4594

Name: Ravi

Sex : Shankar

Age : 47Y/H

----- Sinus Rhythm
 ----- Right Axis Deviation

10mm/mV

V4

V5

V6

SVNC

Unconfirmed report verified by:
E-CARDIOPRINT