

DAKSH HOSPITAL

396 - 397, Gandhi Nagar, Scheme No. 8, ALWAR -301001

Ref. No.

Date.....

MEDICAL EXAMINATION REPORT

Mediwheel (BOB)

Name: Mr. Devkaran Meena

Age: 57 yrs

Sex: Male

Date: 23/12/2023

General Physical Examination

Height : 163 cm

Pulse : 74 /mt

Respiration : 18 /mt

Weight : 77.3 kg

BP : 110/70 mm/hg

BMI : 29.1 kg/m²Systemic Exam:-GPs operated
NORMALDental Check up :-

NORMAL

Eye check-up :-

NORMAL, Both cataract operated

Skin Check up:-

NORMAL

ENT Check up:-

NORMAL

Impression:-DMPT 2ed
concomitant cataract
fatty liverRecommendation:-- Diabetes control
→ Eosinophilia

Vlls

Dr. Mukesh Kumar Gupta

MD Gen. Medicine

Reg. No 5423/16262

डॉ० मुकेश गुप्ता

M.D.F.C.C.S.

फिजिशियन एवं मधुमेह रोग विशेषज्ञ

दक्ष हॉस्पिटल, अलवर

रजि० नं०-5423/16262

Results

Run Date 23/12/2023 09:29:21 AM

Operator DAKSH

Last Name

Sample ID 4

First Name DEVKARAN MEENA

Department

Gender Male

Age

Physician DR. MUKESH GUPTA M.D

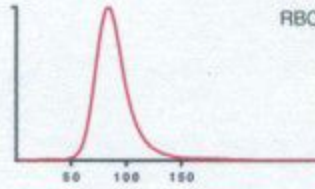
Patient ID AUTO_PID18445

Type Man

Date of birth


Sample comments

			Range
RBC	5.44	10 ⁹ /μL	3.80 - 5.50
HGB	15.7	g/dL	13.0 - 17.0
HCT	48.6	%	39.0 - 52.0
MCV	89.3	μm ³	76.0 - 100.0
MCH	28.8	pg	26.0 - 34.0
MCHC	32.2	g/dL	32.0 - 35.0
RDW-CV	16.0	%	11.0 - 16.0
RDW-SD	56.2	μm ³	37.0 - 49.0

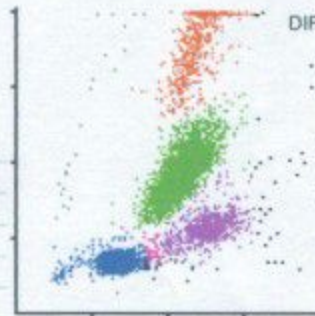


Susp. Pathologies
Eosinophilia

			Range
PLT	152	10 ³ /μL	150 - 450
PCT	0.18	%	0.15 - 0.40
MPV	11.7	μm ³	8.0 - 11.0
PDW	19.9	μm ³	11.0 - 22.0
P-LCC	68	10 ³ /μL	44 - 140
P-LCR	44.6	%	18.0 - 50.0



			Range
WBC	9.38	10 ³ /μL	3.50 - 10.00
	#	Range	%
NEU	5.27	1.60 - 7.00	56.5
LYM	2.64	1.00 - 3.00	28.4
MON	0.37	0.20 - 0.80	4.0
EOS	0.95	0.00 - 0.50	10.2
BAS	0.08	0.00 - 0.15	0.9
LIC	0.07	0.00 - 0.10	0.7



Dr. R.S. Gupta
Dr. R.S. GUPTA
 MD (Pathology) (MAHE)
 RMC No. 7924/19778


Date :-23/12/2023

Name :- MR.DEVKARAN MEENA

Age & Sex :- 57Yrs/ male

Refd. :- Dr Mukesh Gupta M.D.

	TEST NAME	RESULT	REFERENCE RANGE	
	ESR	12	00 -20 mm/hrs	
	Blood Group & Rh Factor	O' POSITIVE		
	HbA1C	5.4	4 - 5.6%	
	Blood Sugar (F)	97.6	< 70 - 100 mg/dl	
	Blood Sugar (PP)	145.4	< 140 mg/dl	
	Urine Sugar (F)	++	-	
	Urine Sugar (PP)	+++	-	
LIVER	S.Bilirubin Total	0.90	0.30 - 1.20 mg/dl	
	S.Bilirubin Direct	0.20	0.10 - 0.30 mg/dl	
	S.Bilirubin Indirect	0.70	0.30 - 0.90 mg/dl	
	S.G.O.T.	111	> 37 u/l	
	S.G.P.T.	130	> 40 u/l	
	S.Alk. Phosp.	207	80 - 306 u/l	
	G.G.T.	30	5 -40 u/l	
	Total Protein	6.8	6.5 - 8.5 gm/dl	
	Albumin	3.7	3.8 - 5.4 gm/dl	
	Globulin	3.1	2.3 - 3.5 gm/dl	
	A/G Ratio	1.1	-	
AST/ALT Ratio	0.8	-		
KIDNEY	Blood Urea	25.6	15 -45 mg/dl	
	S.Creatinine	1.0	0.60 - 1.30 mg/dl	
	BUN	16	6 -24 mg/dl	
	S.Uric Acid	5.2	M 3.1 - 7.0, F 2.5 - 5.6 mg/dl	
	BUN/Creatinine Ratio	16	-	
LIPID PROFILE	Total Cholesterol	140	Up to 200 mg/dl	
	S.HDL	42	30 - 70 mg/dl	
	S.LDL	68	Up to 170 mg/dl	
	S.VLDL	30	5.0 - 40 mg/dl	
	S. Triglycerides	150	Up to 170 mg/dl	
	LDL/HDL Ratio	1.6	-	
	Total Cholesterol/ HDL Ratio	3.3	-	
THYROID	T3	79.6	40 - 181 ng/dl	
	T4	6.2	4.6 - 10.5 µg/dl	
	TSH	2.64	0.30 - 5.0 mlu/l	
	URINE EXAMINATION		<i>Microscopic Examination:</i>	
General/Chemical Examination:	Colour	Pale Yellow	RBC	Absent
	Reaction	Acidic	WBC	1 - 2
	Specific Gravity	QNS	Epithelial Cells	Absent
	Appearance	S. TURBID	Cast	Absent
	Albumin	Nil	Crystal	Absent
	Sugar	++	Spermatozoa	Absent
			Amorphous Sediments	Absent
		Other	Absent	
X-RAY CHEST	REPORT ATTACHED			
	STOOL EXAMINATION		<i>Microscopic Examination:</i>	
General/ Chemical Examination:			RBC	-
	Colour	-	WBC	-
	Consistency	-	Ova & Parasites	-


Dr. R.S. GUPTA
 MD (Pathology) (MAHE)
 RMO No. 7924/19778

TECHNOLOGIST

All investigation have their own limitations regarding the sensitivity & specificity of individual assay procedures. Isolated laboratory investigations never confirm the final diagnosis of the disease. They only help in arriving at a diagnosis in conjunction with clinical presentation and other related investigations. Report is not valid for medico-legal purpose subject to ALWAR jurisdiction only.

DAKSH HOSPITAL

396 - 397, Gandhi Nagar, Scheme No. 8, ALWAR -301001

Ref. No.

Date.....

X-RAY REPORT

Name : Mr. Dev Karan Meena
Date of X-Ray : 23/12/2023
Part of X-Ray : Digital X-Ray Chest

- Bony cage normal.
- Both Costo Phrenic Angle normal.
- Cardiac Shadow appears normal.
- **Right lower zone homogeneous infiltration.**

Note :- Kindly correlate clinically


डॉ० मुकेश गुप्ता
M.D.F.C.C.S.
फिजिशियन एवं मधुमेह रोग विशेषज्ञ
दक्ष हॉस्पिटल, अलवर
रजि० नं०-5423/16262

Date :- 23/12/2023

Name :- Mr. Devkaran Meena

Refd. :- Dr Mukesh Gupta MD

Age & Sex :- 57Yrs/ Male

CLINICAL-BIOCHEMISTRY

<u>Test Name</u>	<u>Observation Unit</u>	<u>Biological Ref.</u>
PSA Prostate Specific Antigen. Serum by CMLA	3.17 ng/ml	0.0-4.0

Remarks:-

Measurement of serum PSA levels is not recommended as a screening procedure for the diagnosis of cancer because elevated PSA levels are also observed in patients with benign prostatic hypertrophy. PSA levels increase in men with cancer of the prostate and after radical prostatectomy PSA levels routinely fall to the undetectable range.

If prostatic tissue remains after surgery or metastasis has occurred, PSA appears to be useful in detecting residual and early recurrence of tumor.

Serial PSA levels can help determine the success of prostatectomy and the need for further treatment, such as radiation, endocrine or chemotherapy and in the monitoring of the effectiveness of therapy.

m002


Dr. R.S. GUPTA
MD (Pathology) (MAHE)
RMC No. 7924/19778

Doctor


TECHNOLOGIST

All investigation have their own limitations regarding the sensitivity & specificity of individual assay procedures, isolated laboratory investigations never confirm the final diagnosis of the disease. They only help in arriving at a diagnosis in conjunction with clinical presentation and other related investigations. Report is not valid for medico-legal purpose subject to ALWAR jurisdiction only.



दक्ष हॉस्पिटल

396, गाँधी नगर स्कीम नं.8, अलवर (राज०) ☎ 0144-2703340

Sonography / 2D Echo Cardiography / Doppler Report

2D/ ECHO REPORT

Name: - Mr Devkaran

Age: - 58 Yrs

Date: - 23-Dec-23

Reg. No.: - Alw/2009/04
BOB health checkup

PROCEDURES:


M-MODE/2D/DOPPLER/COLOR/CONTRAST B.A.S. M²

MEASUREMENT:		DOPPLER:			
AOD	28	NORMAL (20- 37mm)	MV 0.7	NORMAL (cm/sec.) (0.8- 1.3)	MR No
LA	29	(19- 40mm)	AV 1.4	(1.2- 1.8)	AR No
AVO	18	(12- 25mm)	TV 0.6	(0.3- 0.8)	TR No
RVDd.	16	(03- 09mm)	PV 0.8	(0.7- 1.1)	PR No
LVDd	50.9	(37- 56mm)	MITRAL VALVE-		
LVDs	31	(22- 40mm)	AML	Normal	
IVS d	11	(06- 12mm)	PML	Normal	
IVS s	14.8		AORTIC VALVE- mild thickened		
PWd	6.6	(05- 10mm)	TV & PV are normal.		
LV FUNCTION					
M- E- S Separation		<0.9cm			
Minor		24.42%			
LV Ejection Fraction	69%	65 +/- 12%			

MILD CONCENTRIC LVH
MITRAL A>E
LV DISTOLIC DISFUNCTION
LV WALL MOTION: NO RWMA
ALL CARDIAC CHAMBERS ARE NORMAL
ALL VALVES ARE NORMAL
NO CLOT, VEGETATION, PERICARDIAL EFFUSION

Adv: - Follow up/ review at higher center for confirmation

Note:- Please Correlate clinically. Due to technical limitations as well as inaccuracies inherent in the laboratory and statistical analysis of biological process. Diagnostic accuracy of ECHO is up to 95% only.
Report is not valid for medico-legal purpose.


Dr. **MUKESH KUMAR GUPTA**
Physician & Cardiologist
RM 5423/16262



"भ्रूण लिंग परीक्षण की शिकायत
104 टोल फ्री सेवा पर भी की
जा सकती है"

भ्रूण लिंग परीक्षण की शिकायत 104 टोल फ्री सेवा पर भी की जा सकती है।



दक्ष हॉस्पिटल

396, गाँधी नगर स्कीम नं.8, अलवर (राज०) ☎ 0144-2703340

Sonography / 2D Echo Cardiography / Doppler Report

Name: MR. DEVKARAN /M/58 YRS

Date: 23-Dec-23

BOB HEALTH CHECH UP

U.S.G. OF ABDOMEN & PELVIS

LIVER

Liver is **15.6 cm vertically with increase echogenicity**. Intra hepatic billiary radicals are not dilated.
No evidence of focal or diffuse lesion.

GALL BLADDER

Operated. CBD normal

PANCREAS

Pancreas is normal in size, shape & echo-texture.

SPLEEN

9.7 cm in size with **few calcified focus**.

BOTH KIDENY

Both kidney normal shape, size & echo texture. CMD maintained

PROSTATE is **mild enlarged measures 32 grm..**

URINARY BLADDER is partially fill & **well distended**, lumen appear clear. Wall thickness normal.

Impression:- Grade II fatty liver

Calcified focus in spleen.

Mild enlarged prostate.

Advice- X Ray KUB / URINE EXAM

Please correlate clinically. USG accuracy is 95 % due to technical limitations as well as inaccuracies inherent in the laboratory and statistical analysis biological process.

This report is not valid for medico-legal cases.


Dr. Makresh Kumar Gupta
SONOLOGIST
Physician & Sonologist
RM 5423/16262



"भ्रूण लिंग परीक्षण की शिकायत
104 टोल फ्री सेवा पर भी की
जा सकती है"

भ्रूण लिंग परीक्षण की शिकायत 104 टोल फ्री सेवा पर भी की जा सकती है।

ID: 201

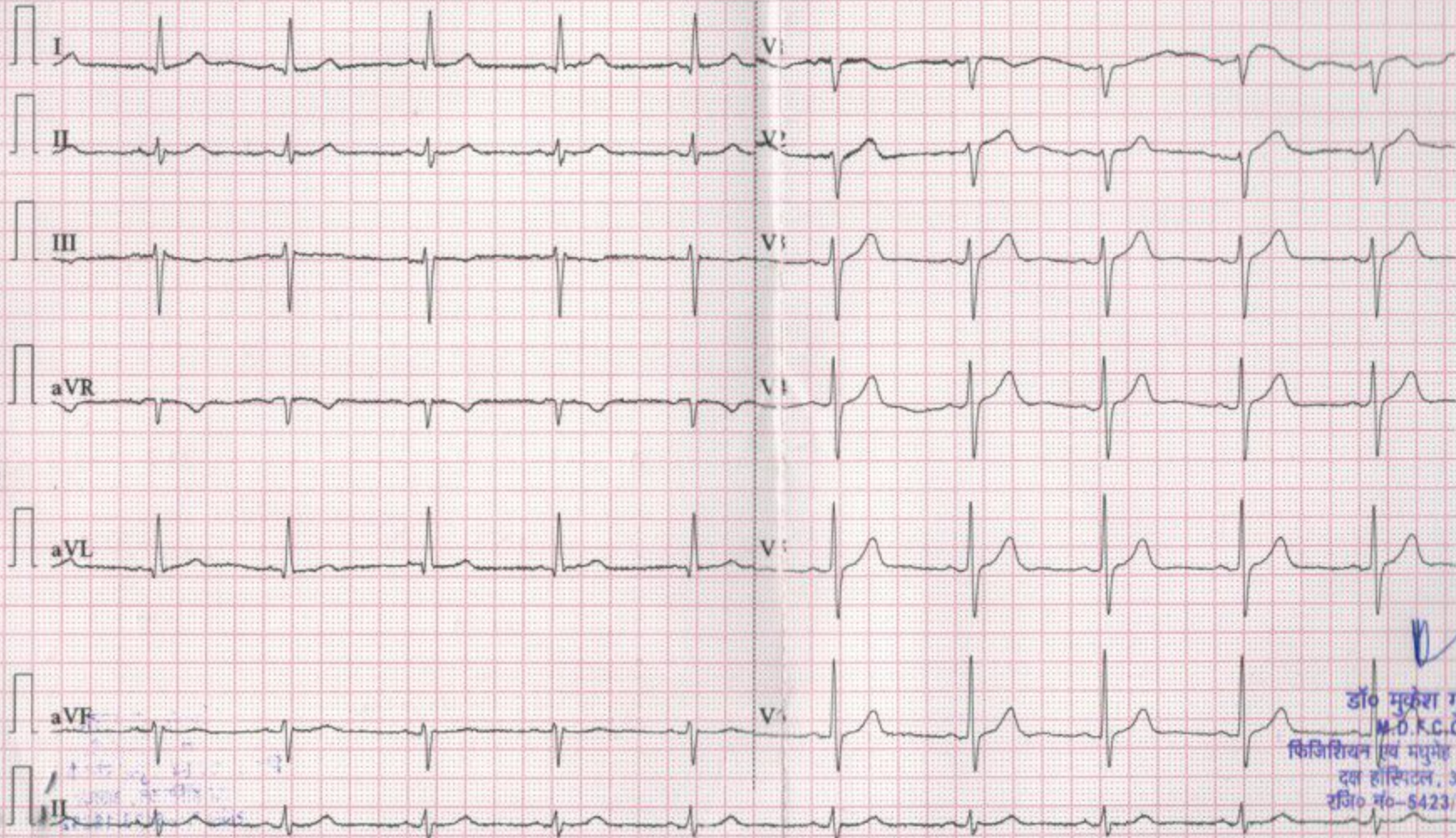
23-12-2023 12:02:22

Male Years
Req. No. :

HR : 62 bpm
P : 112 ms
PR : 158 ms
QRS : 104 ms
QT/QTcBz : 422/429 ms
P/QRS/T : 44/-19/24 °
RV5/SV1 : 1.213/0.507 mV

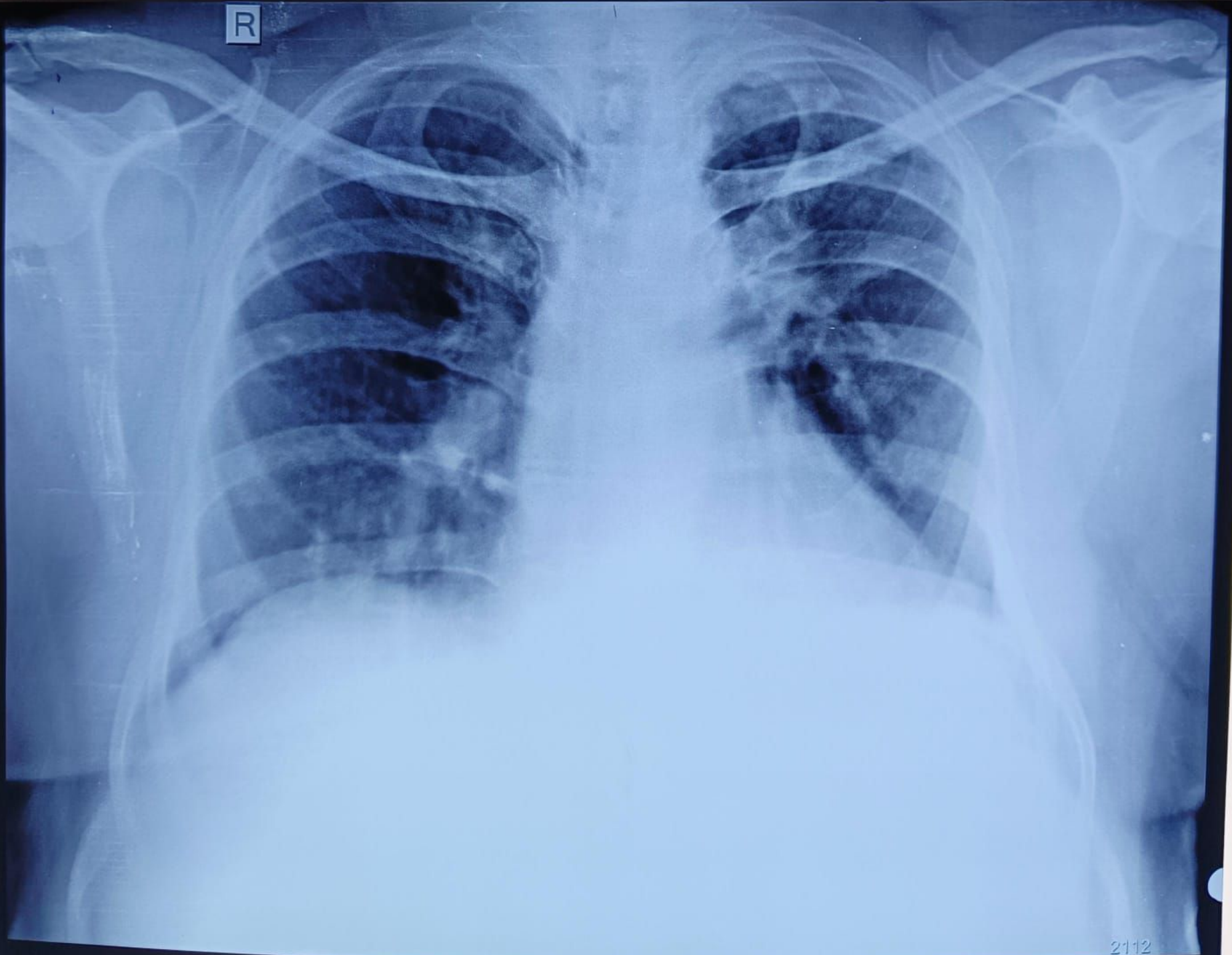
Diagnosis Information:
Sinus rhythm
Normal ECG

Report Confirmed by:



डॉ० मुकुंश गुप्ता
M.D.K.C.C.S.
फिजिशियन एवं मधुमेह रोग विशेषज्ञ
दक्ष हॉस्पिटल, अलवर
रजि० नं०-5423/16262

R



2112