


Patient : MR ABHISHEK V CHAURASIA M/24 Y 5-Aug-24  
Ref By : Dr. ARCOFEMI HEALTHCARE LTD No : 3

**COMPLETE BLOOD COUNT WITH ESR**

<u>Test</u>	<u>Value</u>	<u>Normal Range</u>	<u>Units</u>
HAEMOGLOBIN	14.3	13.5 - 18.0	gms/dl
R.B.C. COUNT	<b>3.99</b>	4.50 - 6.50	millions/cumm
PCV	41.8	40.0 - 54.0	%
MCV	<b>104.8</b>	76.0 - 96.0	u3
MCH	<b>35.8</b>	27.0 - 32.0	pg
MCHC	34.2	30.0 - 35.0	%
RDW	13.2	11.5 - 14.5	%
W.B.C. COUNT	8,430	4,000-11,000	cells/cmm
<b><u>Differential Count :</u></b>			
Neutrophils	54	45 - 70	%
Lymphocytes	41	20 - 45	%
Eosinophils	00	1 - 6	%
Monocytes	05	1 - 10	%
Basophils	00	0 - 1	%
PLATELET COUNT	319,000	150,000 - 450,000	cells/cmm
PLATELETS ON SMEAR	Adequate		
R.B.C. MORPHOLOGY	Normocytic Normochromic		
W.B.C. MORPHOLOGY	Normal		
E.S.R (Westergren)	<b>63</b>	0 - 20	mm / hr

CBC done on Fully Automated Erba H560 Cell Counter.

  
Dr Ashwini Sangvikar  
M.D. Pathology

Email ID : diagnosticradwave@gmail.com • +91 8097421555

Phone No.: +91 8097421556 / +91 8097421557 / +91 8097421558 / +91 8097421559

Address : Shop No. 2 & 3, Naya Oriental Co-Op Hus. Society Ltd., Opp. Sahakari Bhandar, LIC Colony, Next to Hotel Majestic NX, Borivali (W), Mumbai - 400 103. Maharashtra.

Patient : MR ABHISHEK V CHAURASIA M/24 Y 5-Aug-24  
Ref By: Dr ARCOFEMI HEALTHCARE LTD No : 3

**BLOOD SUGAR**

<u>Test</u>	<u>Value</u>	<u>Normal Range</u>	<u>Units</u>
FASTING BLOOD SUGAR	97	70-110	mg/dl
Urine Sugar	Absent		
Urine Ketones	Absent		
POST PRANDIAL BLOOD SUGAR	142	70-140	mg/dl
Urine Sugar (2 hrs)	No Sample		
Urine Ketones (2 Hrs)	No Sample		

METHOD : Glucose Oxidase Peroxidase ( GOD/POD )

American Diabetes Association (ADA 2013) Blood Glucose Level Criteria :

**FASTING GLUCOSE LEVEL**

Normal glucose tolerance : < 100 mg %  
Impaired Fasting Glucose : 100 - 125 mg %  
Provisional diagnosis for:  $\geq 126$  mg % (on two different occasions)  
diabetes mellitus

**POST LUNCH GLUCOSE LEVEL**

Normal glucose tolerance : < 140 mg %  
Impaired Glucose Tolerance : 140 - 199 mg %  
Provisional diagnosis for:  $\geq 200$  mg % (on two different occasions)  
diabetes mellitus

**URINE SUGAR INTERPRETATION : (Approx.)**

Trace : 0.1 g/dl  
+ : 0.25 g/dl  
++ : 0.5 g/dl  
+++ : 1.0 g/dl  
++++ : >2.0 g/dl

*Ashwini Sangvikar*

Dr Ashwini Sangvikar

M.D. Pathology



Patient : MR ABHISHEK V CHAURASIA

M/24 Y


5-Aug-24

Ref By : Dr ARCOFEMI HEALTHCARE LTD

No : 3

**BIOCHEMISTRY**

<u>Test</u>	<u>Value</u>	<u>Normal Range</u>	<u>Units</u>
Bilirubin (Total)	0.75	0.0-1.20	mg/dl
Bilirubin (Direct)	0.12	0.0-0.40	mg/dl
Bilirubin (Indirect)	0.6	0.1-1.0	mg/dl
BUN / CREATININE RATIO	13.5	5 - 23.5	
Creatinine	0.8	0.5-1.3	mg/dl
S.G.P.T	32.4	0.0-40.0	IU/L



*Ashwini Sangvikar*

Dr Ashwini Sangvikar

M.D. Pathology


Patient : MR ABHISHEK V CHAURASIA M/24 Y 5-Aug-24  
Ref By : Dr ARCOFEMI HEALTHCARE LTD No : 3


BLOOD GROUP

<u>Test</u>	<u>Value</u>
BLOOD GROUP	"B" Positive.

Method: Slide & Tube Agglutination



  
Dr Ashwini Sangvikar  
M.D. Pathology

Email ID : diagnosticradwave@gmail.com •  +91 8097421555

Phone No.: +91 8097421556 / +91 8097421557 / +91 8097421558 / +91 8097421559

Address : Shop No. 2 & 3, Naya Oriental Co-Op Hus. Society Ltd., Opp. Sahakari Bhandar,  
LIC Colony, Next to Hotel Majestic NX, Borivali (W), Mumbai - 400 103. Maharashtra.



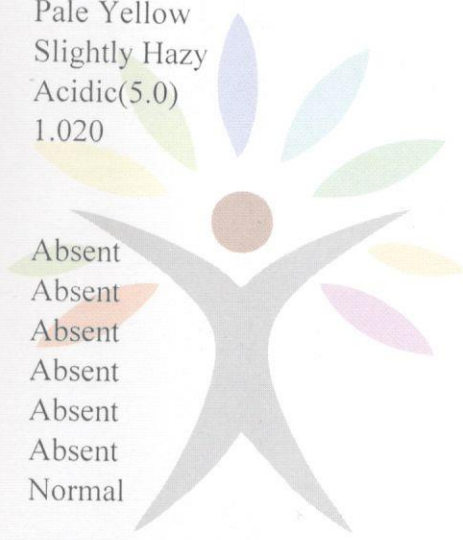
<b>Patient : MR ABHISHEK V CHAURASIA</b>	<b>M/24 Y</b>	<b>5-Aug-24</b>
<b>Ref By : Dr ARCOFEMI HEALTHCARE LTD</b>		<b>No : 3</b>

**Urine Routine**

<u>Test</u>	<u>Value</u>
<b><u>Physical Examination:</u></b>	
Quantity	30 ml
Colour	Pale Yellow
Appearance	Slightly Hazy
Reaction (pH)	Acidic(5.0)
Specific Gravity	1.020

<b><u>Chemical Examination:</u></b>	
Proteins	Absent
Glucose	Absent
Ketone Bodies	Absent
Occult Blood	Absent
Bile Salts	Absent
Bile Pigments	Absent
Urobilinogen	Normal

<b><u>Microscopic Examination:</u></b>	
Pus Cells	1 - 2 / hpf
Red Blood Cells	Absent
Epithelial Cells	2 - 3 / hpf
Casts	Absent
Crystals	Absent
Bacteria	Absent
Yeast Cells	Absent
Amorphous Deposits	Absent
Mucus	Absent
Other	----

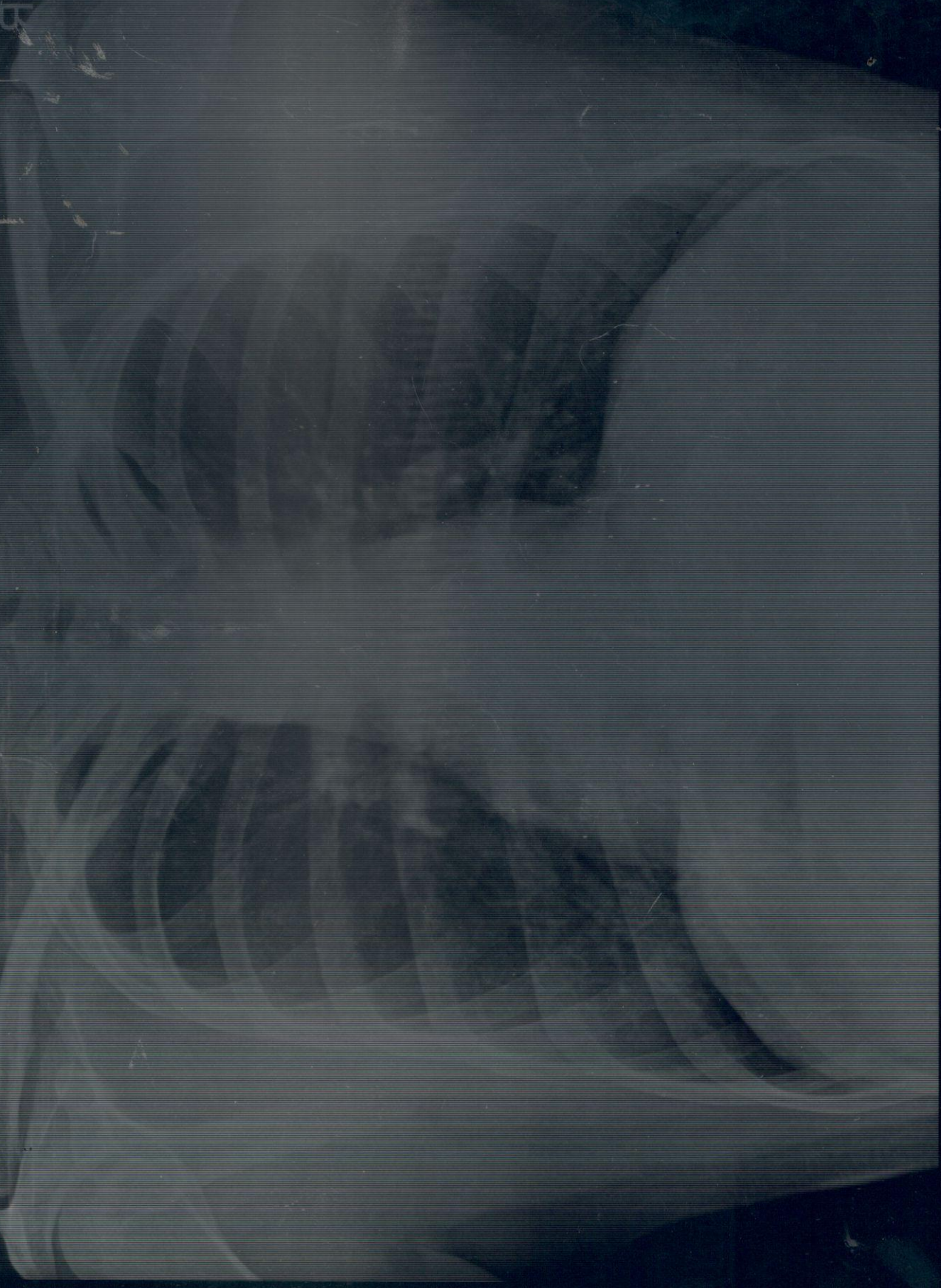


*Ashwini Sangvikar*  
Dr Ashwini Sangvikar  
M.D. Pathology



Pulse Diagnostic Centre (Psdwawe Diagnostic Pvt. Ltd), Boinvalli  
02/08/2024 2010 MR.VBHISHIEK V.CHAURASIA St Y M APOLLO-ARCOFEMI HEALTHCARE LTD CHEST PA

KM 5D-E 03/28 CB921212 B4 06520 53





PATIENT NAME : MR ABHISHEK V CHAURASIA  
AGE/ SEX : 24 YRS / MALE  
REF. CLINICIAN : APOLLO-ARCOFEMI HEALTHCARE LTD  
DATE : 05/08/2024


**X-RAY CHEST (P A VIEW)**

- Both lung fields are clear.
- Both CP angle are normal.
- Cardiac and aortic shadows are normal.
- No obvious hilar or mediastinal lesion is seen.
- Bony thorax appears normal. No evidence of fracture seen.

**CONCLUSION: X-Ray findings show...**

- No significant abnormality of note.

Please correlate clinically.  
Thanks for the referral,



Dr. Tilak Manilal Dedhia  
M.B.B.S; M.D; D.N.B.(Radio-diagnosis)  
Consultant Radiologist,



# 12 LEAD ECG REPORT



# PULSE RADWAVE

## DIAGNOSTIC

UNIT OF RADWAVE DIAGNOSTIC LLP



05/08/2024

Name: Mr. Abhishek. V. Chaurasia 24/M Apollo-Arcofeni Healthcare Ltd

- ▶ Pathology ▶ Digital X - ray ▶ Sonography ▶ 3D - 4D Sonography ▶ Color Doppler ▶ ECG
- ▶ 2D Echo ▶ EEG ▶ EMG ▶ NCV ▶ PFT ▶ Mammography ▶ FNAC ▶ USG Guided Procedures
- ▶ X-Ray Special investigations ▶ Holter Monitor ▶ Sleep Study & Others.



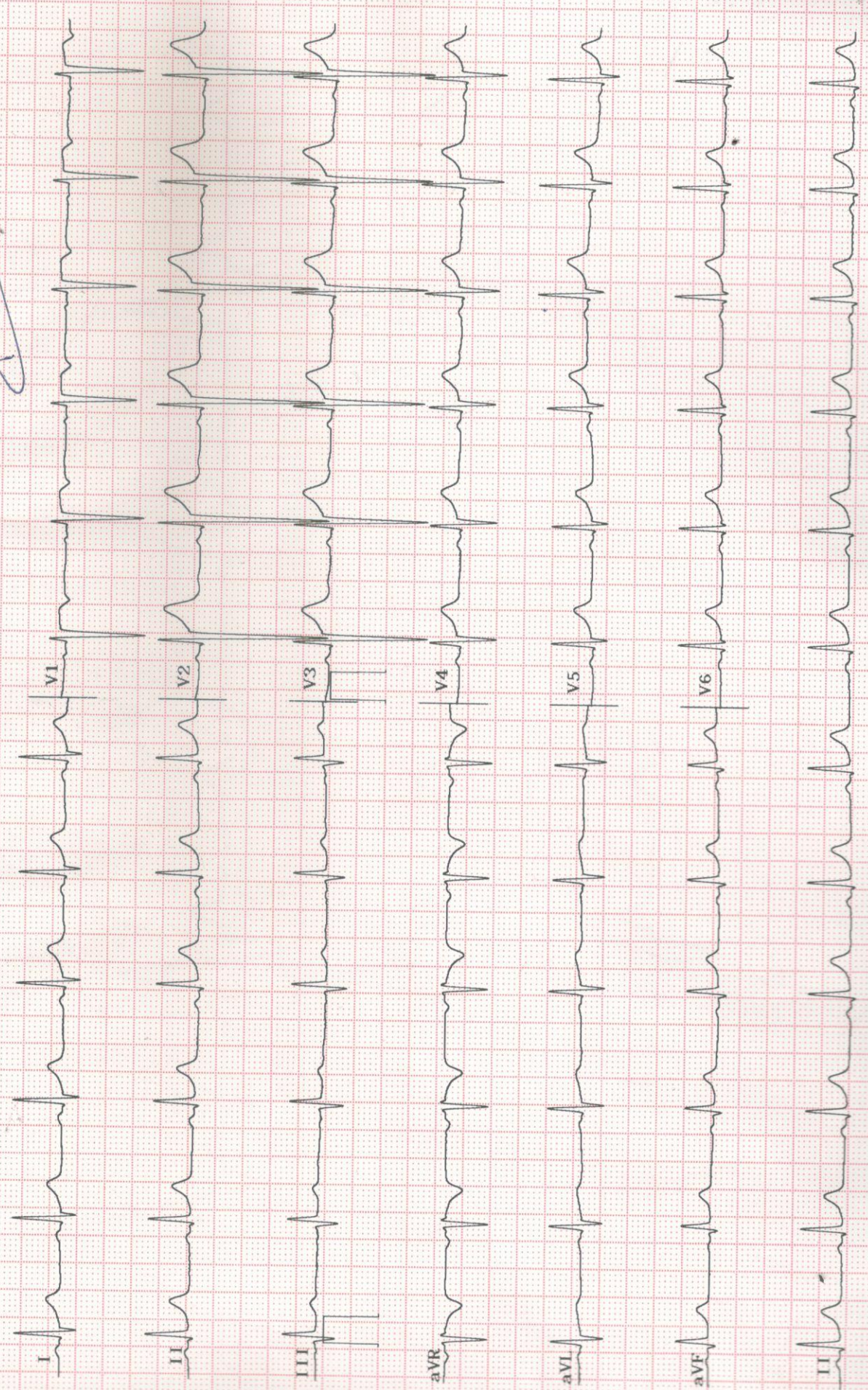
Heart Rate: 71 bpm

ID :  
Name: ABHISHEK  
Age : 24 years  
Sex : Male  
H : 0 cm / W : 0 kg

PR/RR Int.: 132/845 ms  
QRS Dur: 102 ms  
QT/QTc: 384/415 ms  
P-R-T axes: 22 65 46  
SV1/RV5/R+S: 1.43/0.81/2.24mV

Prescribed by:  
(To be finally confirmed by physician)

*Abhishek*





# ELECTROCARDIOGRAM

Please Photocopy ECG As Tracings Fades After Some Time

Name: Mr. Abhishek V. Chauhan

Date: 05/08/2024 Time:            Age / Sex: 24 / M

Heart Rate:           

Rhythm:           

Axis:           

Voltage:           

P Wave:           

PR Interval:           

Qrs Interval & Complex:           

ST Segment:           

T Wave:           

QT Interval:           

QTC:           

Impression: WLP

Signature of Physician           

for Dr. Shychi

CC DEIVAM DEAT INVAL E



Greetings from Apollo!!

Respected Sir/Madam,

Please find corporate HC appointment details scheduled for **05-08-2024** at your Pulse Radwave Diagnostics Private Limited Center.

Points to note:-


Collect photocopy of employee ID proof if health check is through an employer.  
Collect photocopy of personal ID proof if health check is for insurance.  
Collect MER as per package details & that company's format (already shared).  
By 12 noon of appointment date, share Work order number & visit status (Show/No show).  
Upload reports in Abhutam portal as per specifications given earlier.


Corporate/TPA	Agreement Name	Package name	Package Inclusions	Customer Name
ARCOFEMI HEALTHCARE LIMITED	ARCOFEMI MEDIWHEEL PMC CREDIT PAN INDIA OP AGREEMENT	ARCOFEMI - MEDIWHEEL - PMC PACK H - PAN INDIA - FY2324	Urine Routine (CUE), GLUCOSE - SERUM / PLASMA(FASTING AND POST PRANDIAL,ALT(SGPT) - Serum / Plasma,Bilirubin, Total - Serum,Creatinine - Serum / Plasma,Blood Grouping And Typing (Abo And Rh),ECG,HEMOGRAM (CBC+ESR),X-Ray Chest PA, Fitness by General Physician, Opthal by General Physician, BUN/CREATININE RATIO	Abhishhek Vinod Chaurasia

Please login to AHCN Portal for more details.

AHCN Login Url : [Click on Link](#)

Regards,  
Team Clinic Operations  
Apollo Health and Lifestyle Ltd.,

  
**DR. TILAK DEDHIA**  
M.B.B.S.  
REG. No. 3011/07/2287







भारत सरकार  
Government of India



Issue Date : 29/09/2012



Abhishek Vinod Chaurasia  
DOB : 23/07/2000  
Male

7955 3435 0125

मेरा आधार, मेरी पहचान




भारतीय विशिष्ट पहचान प्राधिकरण  
Unique Identification Authority of India



Print Date : 10/09/2022

Address: B/106, Hausa Apartment,  
Golden Nest, Goddev Gaon,  
Bhayander (East), Thane,  
Maharashtra, 401105



7955 3435 0125



1947



help@uidai.gov.in



www.uidai.gov.in

*Abhishek*

*Tilak*  
**DR. TILAK DEDHIA**  
M.B.B.S.  
REG. No 11/07/2287



MER- MEDICAL EXAMINATION REPORT

Date of Examination	05/08/2024		
NAME	Mr. Abhishek V. Chaudharia		
AGE	24	Gender	Male
HEIGHT(cm)	176	WEIGHT (kg)	83.8 kgs
B.P.	130/90 mm/hg		
ECG	WNL		
X Ray	Normal		
Vision Checkup	Ⓡ 6/6 Ⓛ 6/6 Normal Colour Vision		
Present Ailments	NO		
Details of Past ailments (If Any)	NO		
Comments / Advice : She /He is Physically Fit	He is physically fit		

*Tilak*

Signature with Stamp of Medical Examiner

**DR. TILAK DEDHIA**  
M.B.B.S.  
REG. No. 2011/07/2287