

Date: - 26-10-2024.

Rajiv Singh Parmar

Today I visit. For my Health checkup

At Date: - 26-10-2024. but for Dental checkup

The doctor is not available today so

They call me to come at Tuesday Tuesday

but From at Tuesday I am going to

office at Vikramganj. So this busy

hustle schedule I did not come

on Tuesday.



Date: 26-10-2024.

Name: Ruturajsinh Parmar

I am not in Fasting.





MER- MEDICAL EXAMINATION REPORT

Date of Examination	26-10-2024		
NAME	PARMAR RUTURAJ SINH		
AGE	27	Gender	MALE
HEIGHT(cm)	168	WEIGHT (kg)	77
B.P.	122/80/78		
X RAY	NORMAL		
ECG	NORMAL		
EYE CHECKUP	COLOUR VISION: MINOR CLOLOUR BINDNESS NEAR: 6/6 WITHOUT GLASSES FAR: 6/9 WITHOUT GLASSES		
Present Ailments	N/A		
Details of Past ailments (If Any)	N/A		
Comments / Advice : She /He is Physically Fit	PHYSICALLY FIT		

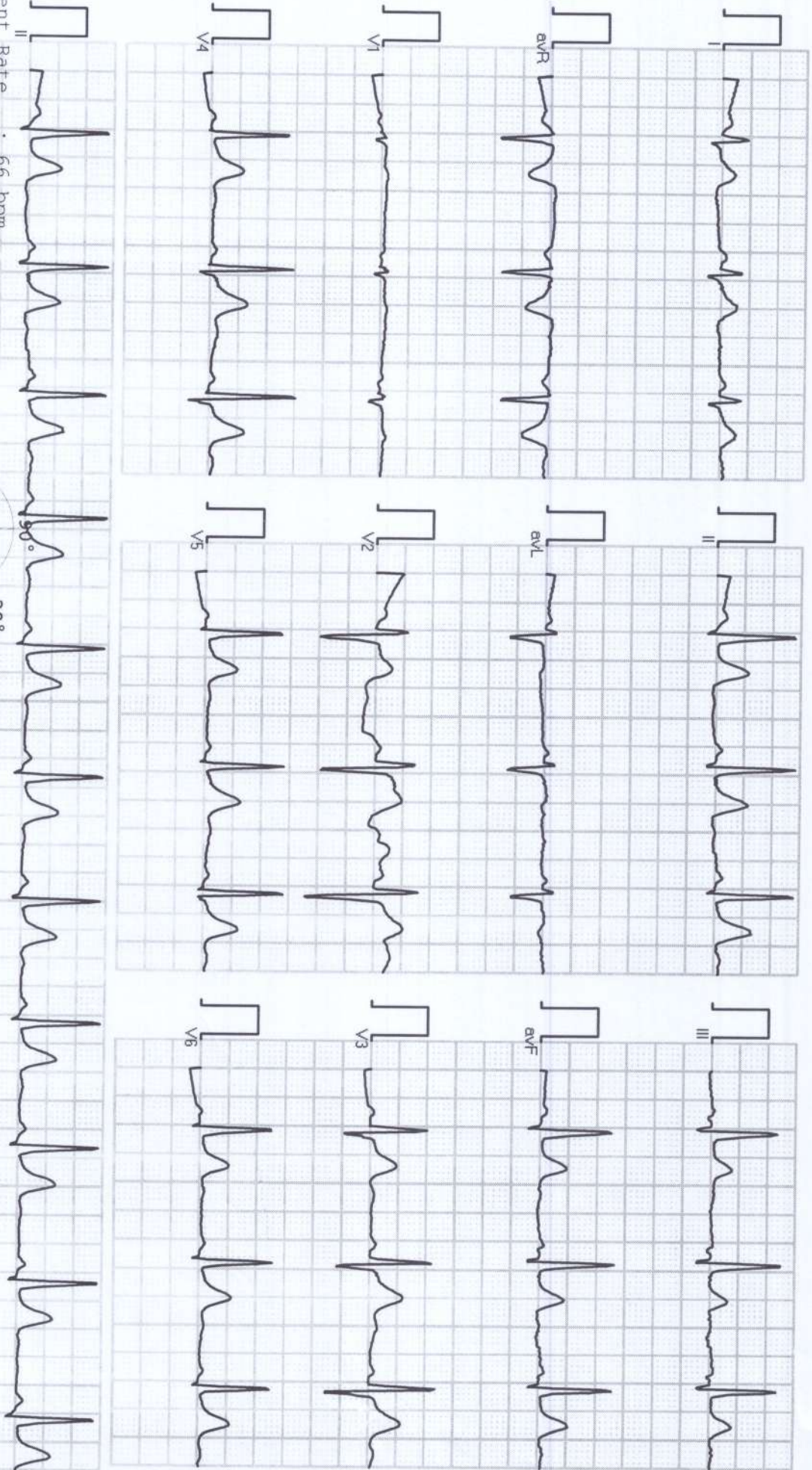
Dr. Vipul Ghavda
MD (Internal Medicine)
Reg.No. G-18004

Signature with Stamp of Medical Examiner

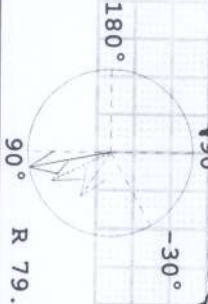
CONCEPT DIAGNOSTIC

3057 / PARMAR RUTURAJ SINH / 27 Yrs / M / 168Cms. / 77Kgs. / Non Smoker
Heart Rate : 66 bpm / Tested On : 26-Oct-24 13:04:19 / HF 0.05 Hz - LF 35 Hz / Notch 50 Hz / Sn 1.00 Cm/mV / Sw 25 mm/s

ECG



Vent Rate : 66 bpm
PR Interval : 142 ms
QRS Duration: 88 ms
QT/QTc Int : 388/399 ms
P-QRS-T axis: 34.00° 79.00° 64.00°



Axis
P 34.00°
QRS 79.00°
T 64.00°
NSR/LNL

DR. PARESH THAKKAR
MD (Med.) Dr. NB (Cardiology)
Reported By: DR. PARESH THAKKAR
G-32546



NAME :	PARMAR RUTURAJ SINH	AGE/SEX:	27Y/M
REF. BY:	HEALTH CHECK UP	DATE :	26-Oct-24

X-RAY CHEST - PA VIEW

- Both lung fields are clear.
- No evidence of consolidation or Koch's lesion seen.
- Both CP angles are clear.
- Heart size is within normal limit.
- Both dome of diaphragm appear normal.
- Bony thorax under vision appears normal.

Dr. Tejas Patel
Diplomate N. B.
G-33659

Dr. TEJAS PATEL
DNB RADIODIAGNOSIS



NAME	Parmar Ruturaj Sinh		
AGE/ SEX	27 YR /M	DATE	26-Oct-2024
REF. BY	Health Checkup	DONE BY	Dr Parth Thakkar

2D ECHO CARDIOGRAPHY & COLOR DOPPLER STUDY

FINDINGS:-

- Normal LV systolic function, LVEF= 60 %.
- No RWMA at rest.
- LV and LA are of normal size.
- RA & RV are normal.
- Normal LV compliance.
- Intact IAS & IVS
- All valves are structurally normal
- Mild MR, No AR
- Mild TR, No PAH. RVSP 25mmHg
- No clot or vegetation.
- No evidence of pericardial effusion.
- IVC normal



MEASUREMENTS:-

LVIDD	44(mm)	LA	31(mm)
LVIDS	26(mm)	AO	27(mm)
LVEF	60%	AV cusp	
IVSD / LVPWD	10/10 (mm)	EPSS	

DOPPLER STUDY:-

Valve	Velocity (M/sec)	Max gradient (MmHg)	Mean gradient (Mm Hg)	Valve area Cm ²
Aortic	1.1	5		
Mitral	E: 0.7 A: 0.5			
Pulmonary	0.8			
Tricuspid	2.0	19		

CONCLUSION:-

- Normal LV systolic function, LVEF=60%.
- No RWMA at rest.
- Normal LV compliance.
- RA & RV are normal.
- All valves are structurally normal.
- Mild MR, No AR, Mild TR, No PAH
- IVC normal

DR. PARTH THAKKAR
MD (Med.) DrNB (Cardiology)
Interventional cardiologist
G - 32946

Dr. Parth Thakkar
MD (Med.), DrNB (Cardiology)
Interventional Cardiologist
79901-79258

Dr. Abhimanyu D Kothari
MD (Med.), DM (Cardiology)
Interventional Cardiologist
9714675115

