



भारत सरकार

GOVERNMENT OF INDIA



राजेश कुमार
Rajesh Kumar
जन्म तिथि/DOB: 09/08/1977
पुरुष/ MALE
Mobile No: 9873003899

7206 1142 8660
VID : 9104 1206 0611 7776

मेरा आधार, मेरी पहचान

MS




भारतीय विशिष्ट पहचान प्राधिकरण

UNIQUE IDENTIFICATION AUTHORITY OF INDIA

पता:
S/O क्रिशन चंदर, २८, पीतमपुरा, नॉर्थवेस्ट दिल्ली,
दिल्ली - 110034

Address :
S/O Krishan Chander, 28,
PITAMPURA, North West Delhi,
Delhi - 110034



7206 1142 8660
VID : 9104 1206 0611 7776



1947



helpline@uidai.gov.in

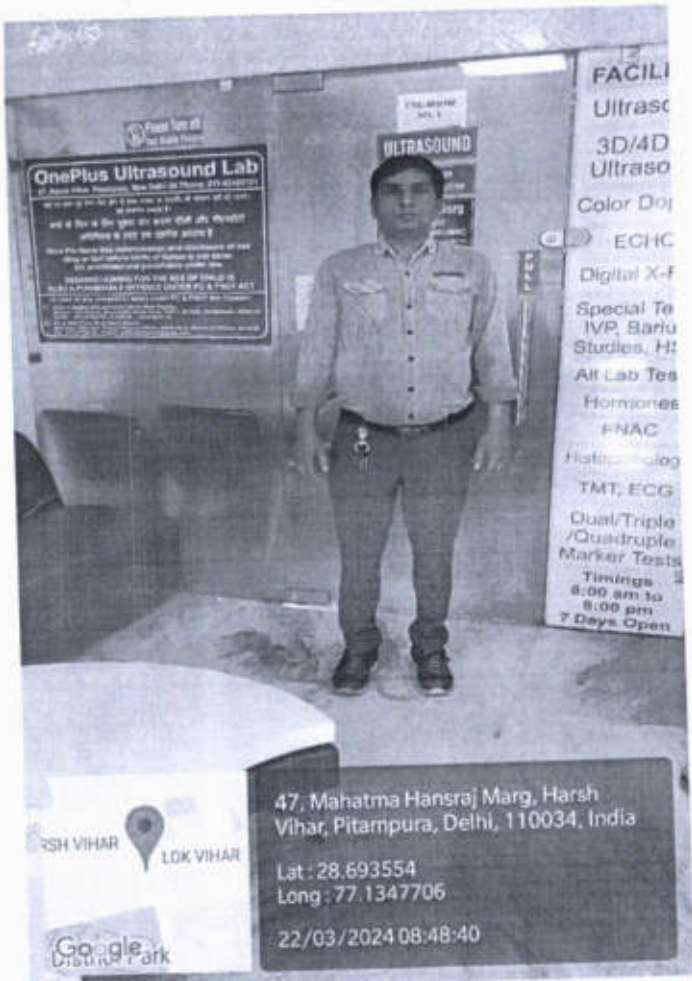


www.uidai.gov.in

UID, Box No. 150,
Bangalore - 560 081

DR. NITIN AGARWAL
MBBS, MD
Regn. No. DMC-R-1436

ONEPLUS ULTRASOUND LAB
47 Harsh Vihar, Pitam Pura,
Delhi-110034
Ph. 011-42480101, 9599913051
E-mail onepjusul@gmail.com



FACILITIES

- Ultrasound
- 3D/4D Ultrasound
- Color Doppler
- ECHOCARDIOGRAPHY
- Digital X-Ray
- Special Tests
- IVP, Barium Studies, HIDA
- All Lab Tests
- Hormones
- FNAC
- Histopathology
- TMT, ECG
- Dual/Triple/Quadruple Marker Tests
- Timings: 8:00 am to 8:00 pm
- 7 Days Open

OnePlus Ultrasound Lab
 Anand Kataria, New Delhi-110034 (011-42480101)

ULTRASOUND



47, Mahatma Hansraj Marg, Harsh Vihar, Pitampura, Delhi, 110034, India
 Lat : 28.693554
 Long : 77.1347706
 22/03/2024 08:48:40

AS

[Signature]
DR. NITIN AGARWAL
 MBBS, MD
 Regn. No. DMC-R-1436

ONEPLUS ULTRASOUND LAB
 47 Harsh Vihar, Pitam Pura,
 Delhi-110034
 Ph. 011-42480101, 9599913051
 E-mail onepiusul@gmail.com



OnePLUS
Ultrasound Lab
— QUALITY FIRST... ALWAYS! —

Dr. Nitin Agarwal

Pathologist & Director
MBBS, MD, FAGE
Ex. Chief of Lab
Dr. Lal Path labs.

Dr. Pooja (Garg) Agarwal

Radiologist & Director
MBBS (MAMC) DMRD (MAMC)
Imaging Expert In Fetal And Maternal Medicine,
University of Barcelona, Spain
Fetal Medicine Foundation (UK) Accreditation

सद्व्यवहार वादी देना चाहते हैं
सुनिश्चित वादी देना चाहते हैं

DR. NITIN AGARWAL
MBBS, MD
Regn. No. DMC-R-1436

47, Harsh Vihar, Pitampura, Delhi-34 ☎ 011-4248 0101, 9599913051

✉ Email: oneplusul@gmail.com 🌐 www.oneplusul.in

- Clinical correlation is essential for final diagnosis. • If test results are unsatisfactory please contact personally or on phone.
- This report is for perusal of doctors only. • All disputes are subject to Delhi jurisdiction only. • Not for medico legal case.
- All congenital anomalies in a foetus may not be diagnosed in routine obstetric ultrasound.



NAME	:Mr. RAJESH KUMAR	Barcode No	:10167730
AGE/GENDER	:46 YRS/Male	SPECIMEN DATE	:22/Mar/2024 08:46AM
PATIENT ID	:132429	SPECIMEN RECEIVED	:22/Mar/2024 08:58AM
REFERRED BY	:Dr. MEDIWHEEL	REPORT DATE	:22/Mar/2024 03:04PM
CENTRE NAME	:ONEPLUS ULTRASOUND LAB	LAB NO.	:012403220008

Test Name	Result	Unit	Ref. Range
-----------	--------	------	------------

HAEMATOLOGY

MediWheel Health checkup < 40 Male

Sample Type:EDTA Blood

ESR

Modified Westergrens Method

06

mm in 1st hr

upto 13.6

Comments:

Increased

- In most infections, anaemias, injection of foreign proteins, auto-immune disorders, conditions accompanied by hyperglobunemia and hypercholesterolaemia.
- A rising ESR suggests a progressive disease.

Decreased

- In polycythemia, congestive heart failure.

Glycosylated Hemoglobin (HbA1c)

HPLC

5.6

%

Non Diabetic adults <5.7
Prediabetic (at risk) 5.7-6.4
Diabetes >6.4

Estimated average blood glucose (eag)

CALCULATED


114

Reference range (mg/dl):

90 - 120:Excellent control, 121 - 150:Good Control, 151 - 180:Average Control, 181 - 210:Action Suggested

>211:Paric value

Dr NITIN AGARWAL
MBBS, MD (Path)
DMC/R/01436



DR. NITIN AGARWAL
MBBS,MD(PATHOLOGIST)

Checked By.

47, Harsh Vihar, Pitampura, Delhi-34 ☎ 011-4248 0101, 9599913051

✉ Email: oneplusul@gmail.com 🌐 www.oneplusul.in

Page 1 of 8



OnePLUS Ultrasound Lab

— QUALITY FIRST... ALWAYS! —

Dr. Nitin Agarwal

Pathologist & Director
MBBS, MD, FAGE
Ex. Chief of Lab
Dr. Lal Path labs.

Dr. Pooja (Garg) Agarwal

Radiologist & Director
MBBS (MAMC) DMRD (MAMC)
Imaging Expert In Fetal And Maternal Medicine
University of Barcelona, Spain
Fetal Medicine Foundation (UK) Accreditation



NAME	:Mr. RAJESH KUMAR	Barcode No	:10167730
AGE/GENDER	:46 YRS/Male	SPECIMEN DATE	:22/Mar/2024 08:46AM
PATIENT ID	:132429	SPECIMEN RECEIVED	:22/Mar/2024 08:58AM
REFERRED BY	:Dr. MEDIWHEEL	REPORT DATE	:22/Mar/2024 03:04PM
CENTRE NAME	:ONEPLUS ULTRASOUND LAB	LAB NO.	:012403220008

Test Name	Result	Unit	Ref. Range
-----------	--------	------	------------

HAEMATOLOGY

BLOOD GROUP (ABO)

Forward and Reverse grouping (Slide & Tube)

A

Rh typing

POSITIVE

NOTE :

- * Apart from major A,B,H antigens which are used for ABO grouping and Rh typing, many minor blood group antigens exist. Agglutination may also vary according to titre of antigen and antibody.
- * So before transfusion, reconfirmation of blood group as well as cross-matching is needed.
- * Presence of maternal antibodies in newborns, may interfere with blood grouping.
- * Auto agglutination (due to cold antibody, falciparum malaria, sepsis, internal malignancy etc.) may also cause erroneous result.

Checked By.

Dr NITIN AGARWAL
MBBS, MD
01436
DR. NITIN AGARWAL
MBBS, MD (PATHOLOGIST)

47, Harsh Vihar, Pitampura, Delhi-34 ☎ 011-4248 0101, 9599913051

✉ Email: oneplusul@gmail.com 🌐 www.oneplusul.in

Page 2 of 8

- Clinical correlation is essential for final diagnosis. • If test results are unsatisfactory please contact personally or on phone.
- This report is for perusal of doctors only. • All disputes are subject to Delhi jurisdiction only. • Not for medico legal case.
- All congenital anomalies in a foetus may not be diagnosed in routine obstetric ultrasound.



NAME	:Mr. RAJESH KUMAR	Barcode No	:10167730
AGE/GENDER	:46 YRS/Male	SPECIMEN DATE	:22/Mar/2024 08:46AM
PATIENT ID	:132429	SPECIMEN RECEIVED	:22/Mar/2024 08:58AM
REFERRED BY	:Dr. MEDIWHEEL	REPORT DATE	:22/Mar/2024 03:04PM
CENTRE NAME	:ONEPLUS ULTRASOUND LAB	LAB NO.	:012403220008

Test Name	Result	Unit	Ref. Range
-----------	--------	------	------------

HAEMATOLOGY

CBC

Haemoglobin Non cyanide Hb analysis	14.6	g/dl	13.0-17.0
Total Leucocyte Count Electrical Impedance	8200	/cumm	4000-10000
Differential leucocyte count			
Neutrophils Electrical Impedance & Microscopic	55.6	%	40-80
Lymphocyte Electrical Impedance & Microscopic	35.90	%	20-40
Monocytes Electrical Impedance & Microscopic	6.00	%	2-10
Eosinophils Electrical Impedance & Microscopic	2.0	%	1-6
Basophils Electrical Impedance & Microscopic	0.5	%	0-2
RBC Count Electrical Impedance	4.80	million/cumm	4.5 - 5.5
Hematocrit(PCV) Flow Cytometry	43.6	%	40-50
MCV Calculated	90	fl	83-101
MCH Calculated	30.1	pg	27-32
MCHC Calculated	33.4	g/dL	31.5-34.5
RDW-CV Calculated	14.4	%	11.4-14.0
Platelet count Electrical Impedance	417000	/cumm	150000-410000

BIOCHEMISTRY

Sample Type:Fluoride F

Blood sugar fasting
GOD-POD

92 mg/dl

70-100 mg/dl

Dr. NITIN AGARWAL
MBBS, MD (Path)
DMP/R/01436

DR. NITIN AGARWAL
MBBS, MD(PATHOLOGIST)

Checked By.

47, Harsh Vihar, Pitampura, Delhi-34 ☎ 011-4248 0101, 9599913051

✉ Email: oneplusul@gmail.com 🌐 www.oneplusul.in

Page 3 of 8

- Clinical correlation is essential for final diagnosis. • If test results are unsatisfactory please contact personally or on phone.
- This report is for perusal of doctors only. • All disputes are subject to Delhi jurisdiction only. • Not for medico legal case.
- All congenital anomalies in a foetus may not be diagnosed in routine obstetric ultrasound.



NAME	:Mr. RAJESH KUMAR	Barcode No	:10167730
AGE/GENDER	:46 YRS/Male	SPECIMEN DATE	:22/Mar/2024 08:46AM
PATIENT ID	:132429	SPECIMEN RECEIVED	:22/Mar/2024 08:58AM
REFERRED BY	:Dr. MEDIWHEEL	REPORT DATE	:22/Mar/2024 03:04PM
CENTRE NAME	:ONEPLUS ULTRASOUND LAB	LAB NO.	:012403220008

Test Name	Result	Unit	Ref. Range
Sample Type:Fluoride PP			
Blood sugar pp GOD-POD	121	mg/dL	70.0-140.0
Sample Type:Serum			
Bun (blood urea nitrogen) Calculated	11.20	mg/dl	8.9-21.6
Uric Acid, serum Uricase- PAP	4.0	mg/dl	3.5-7.2
Creatinine, serum Enzymatic	0.7	mg/dl	0.71-1.16
LFT(LIVER FUNCTION TEST)			
Bilirubin Total Modified tab	0.45	mg/dl	0.2-1.1
Bilirubin Conjugated Diazotied sulfanilic acid	0.21	mg/dL	0.11-0.42
Bilirubin Unconjugated Calculated	0.24	mg/dl	up to 0.7
SGOT (AST) Tris buffer	29	U/L	0-46
SGPT (ALT) Tris buffer	55	U/L	0-49
Alkaline phosphatase Amp buffer	95	U/L	40-129
GAMMA GT Szasz Method	28	U/L	10-45
Total Protein Biuret	7.2	gm/dl	6.60 - 8.70
Albumin serum BCG	4.1	g/dL	3.0-5.2
Globulin Calculated	3.10	gm/dl	1.8-3.4
Albumin/Globulin Ratio Calculated	1.32		1.10 - 2.50
LIPID PROFILE			
Cholesterol CHOD-PAP	198	mg/dl	50-200

Checked By.

Dr. NITIN AGARWAL
MBBS, MD (Path)
DR. NITIN AGARWAL
MBBS, MD (PATHOLOGIST)

47, Harsh Vihar, Pitampura, Delhi-34 ☎ 011-4248 0101, 9599913051
✉ Email: oneplusul@gmail.com 🌐 www.oneplusul.in

Page 4 of 8
Page 3 of 3

- Clinical correlation is essential for final diagnosis. • If test results are unsatisfactory please contact personally or on phone.
- This report is for perusal of doctors only. • All disputes are subject to Delhi jurisdiction only. • Not for medico legal case.
- All congenital anomalies in a foetus may not be diagnosed in routine obstetric ultrasound.



NAME	:Mr. RAJESH KUMAR	Barcode No	:10167730
AGE/GENDER	:46 YRS/Male	SPECIMEN DATE	:22/Mar/2024 08:46AM
PATIENT ID	:132429	SPECIMEN RECEIVED	:22/Mar/2024 08:58AM
REFERRED BY	:Dr. MEDIWHEEL	REPORT DATE	:22/Mar/2024 03:04PM
CENTRE NAME	:ONEPLUS ULTRASOUND LAB	LAB NO.	:012403220008


Test Name	Result	Unit	Ref. Range
Triglycerides GPO-PAP	141	mg/dL	25-150
HDL Cholesterol Selective Inhibition	45	mg/dL	40 - 60
LDL cholesterol Calculated	125	mg/dL	<100
VLDL cholesterol Calculated	28.2	mg/dL	5-40
Cholesterol/HDL Ratio Calculated	4.4		Low Risk 3.3-4.97 Average Risk 4.4-7.1 Moderate Risk 7.1-11.0 High Risk >11.0
LDL/HDL Ratio Calculated	2.8		0 - 3.55

LDL Cholesterol	Total Cholesterol	HDL Cholesterol
<100 Optimal	<200 Desirable	<40 Low
100-129 Near optimal	200-239 Borderline high	>60 High
130-159 Borderline high	>240 High	
160-189 High		
>190 Very high		

According to NCEP, ATP-III Guidelines

	BUN/Creatinine ratio		
UREA UREASE-GLDH	24.00	mg/dl	15-45
Bun (blood urea nitrogen) Calculated	11.21	mg/dl	8.9-21.6
CREATININE ENZYMATIC	0.70	mg/dl	0.30-1.10
Bun/Creatinine Ratio Calculated	16.01		10.0 - 20.0

Checked By.

Dr. NITIN AGARWAL
MBBS
DMRDC/01/136

DR. NITIN AGARWAL
MBBS,MD(PATHOLOGIST)

47, Harsh Vihar, Pitampura, Delhi-34 ☎ 011-4248 0101, 9599913051

✉ Email: oneplusul@gmail.com 🌐 www.oneplusul.in

Page 5 of 8

- Clinical correlation is essential for final diagnosis. • If test results are unsatisfactory please contact personally or on phone.
- This report is for perusal of doctors only. • All disputes are subject to Delhi jurisdiction only. • Not for medico legal case.
- All congenital anomalies in a foetus may not be diagnosed in routine obstetric ultrasound.



OnePLUS
Ultrasound Lab
— QUALITY FIRST... ALWAYS! —

Dr. Nitin Agarwal

Pathologist & Director
MBBS, MD, FAGE
Ex. Chief of Lab
Dr. Lal Path labs.

Dr. Pooja (Garg) Agarwal

Radiologist & Director
MBBS (MAMC) DMRD (MAMC)
Imaging Expert In Fetal And Maternal Medicine,
University of Barcelona, Spain
Fetal Medicine Foundation (UK) Accreditation



NAME	:Mr. RAJESH KUMAR	Barcode No	:10167730
AGE/GENDER	:46 YRS/Male	SPECIMEN DATE	:22/Mar/2024 08:46AM
PATIENT ID	:132429	SPECIMEN RECEIVED	:22/Mar/2024 08:58AM
REFERRED BY	:Dr. MEDIWHEEL	REPORT DATE	:22/Mar/2024 03:04PM
CENTRE NAME	:ONEPLUS ULTRASOUND LAB	LAB NO.	:012403220008

Test Name	Result	Unit	Ref. Range
-----------	--------	------	------------

ENDOCRINOLOGY

THYROID PROFILE(T3,T4,TSH)

Triiodothyronine total [t3] ECLIA	0.86	ng/dl	0.52-1.9
Thyroxine total [t4] ECLIA	7.50	µg/dl	4.4 - 10.8
TSH (Thyroid Stimulating Hormone) Enzyme linked fluorescent assay	4.10	µU/ml	0.25-5.0

AGE WISE VARIATION IN TSH

AGE	TSH(µU/ml)	AGE	TSH(µU/ml)
1-4 weeks	1.00 - 19.0	16-20 yrs	0.25 - 5.0
1-12 mths	1.70 - 9.1	21 - 80 yrs	0.25 - 5.0
1-5 yrs	0.80 - 8.2	I st trimester	0.25 - 5.0
6-10 yrs	0.25 - 5.0	II nd trimester	0.50 - 5.0
11-15 yrs	0.25 - 5.0	II rd trimester	0.4 - 6.0

Reference ranges - Interpretation of Diagnostic tests - (Jacques Wallach)

1. Primary hypothyroidism is accompanied by depressed serum T3 and T4 values and elevated serum TSH level.
2. Primary hyperthyroidism is accompanied by elevated serum T3 and T4 levels along with depressed TSH values.
3. Slightly elevated T3 levels may be found in pregnancy and estrogen therapy, while depressed levels may be encountered in severe illness, renal failure and during therapy with drugs like propranolol and propyl thiouracil.
4. Although elevated TSH levels are nearly always indicative of primary hypothyroidism, and may be seen in secondary thyrotoxicosis

Checked By.

Dr NITIN AGARWAL
M B B S , MD (Path)
DMC, R (Path)
DMC, R (Path)
M B B S , MD (Path)
DR. NITIN AGARWAL
MBBS,MD(PATHOLOGIST)

47, Harsh Vihar, Pitampura, Delhi-34 ☎ 011-4248 0101, 9599913051

✉ Email: oneplusul@gmail.com 🌐 www.oneplusul.in

Page 6 of 8

- Clinical correlation is essential for final diagnosis. • If test results are unsatisfactory please contact personally or on phone.
- This report is for perusal of doctors only. • All disputes are subject to Delhi jurisdiction only. • Not for medico legal case.
- All congenital anomalies in a foetus may not be diagnosed in routine obstetric ultrasound.



NAME	:Mr. RAJESH KUMAR	Barcode No	:10167730
AGE/GENDER	:46 YRS/Male	SPECIMEN DATE	:22/Mar/2024 08:46AM
PATIENT ID	:132429	SPECIMEN RECEIVED	:22/Mar/2024 08:58AM
REFERRED BY	:Dr. MEDIWHEEL	REPORT DATE	:22/Mar/2024 03:04PM
CENTRE NAME	:ONEPLUS ULTRASOUND LAB	LAB NO.	:012403220008

Test Name	Result	Unit	Ref. Range
-----------	--------	------	------------

CLINICAL PATHOLOGY

URINE ROUTINE (Strip/microscopy)

Sample Type:Urine

Physical examination

Colour	PALE YELLOW		PALE YELLOW
Transparency	CLEAR		CLEAR
Sp.gravity	1.015		1.005-1.030
BROMOTHYMOL BLUE			
pH	6.00		5.0-8.0
Double Indicators Test			
Reaction	ACIDIC		ACIDIC

Chemical examination

Urine protein	NIL		NIL
Protein Ionization			
Urine sugar	NIL		NIL
Oxidation Reaction			
Bilirubin, urine	NEGATIVE		NEGATIVE
Urobilinogen	NORMAL		NORMAL
P-Aminobenzoic Acid and Phenazopyridine Reaction			
Ketones	NEGATIVE		NEGATIVE
Acetoacetate and Dichlorobenzene Reaction			

Microscopic examination

Pus cells.	1-2	/HPF	0-2
Microscopy			
Epithelial cells	1-2	/HPF	NIL
Microscopy			
R.B.C.	NIL	/HPF	NIL
Microscopy			
Casts	NIL	/HPF	NIL
Microscopy			
Crystals	NIL	/HPF	NIL
Microscopy			
Bacteria	NIL	/HPF	NIL
Microscopy			

Checked By.

Dr. NITIN AGARWAL
MBBS, MD (Path)
MBBS, MD (PATHOLOGIST) 01436

47, Harsh Vihar, Pitampura, Delhi-34 ☎ 011-4248 0101, 9599913051

✉ Email: oneplusul@gmail.com 🌐 www.oneplusul.in

Page 7 of 8

- Clinical correlation is essential for final diagnosis. • If test results are unsatisfactory please contact personally or on phone.
- This report is for perusal of doctors only. • All disputes are subject to Delhi jurisdiction only. • Not for medico legal case.
- All congenital anomalies in a foetus may not be diagnosed in routine obstetric ultrasound.




NAME	:Mr. RAJESH KUMAR	Barcode No	:10167730
AGE/GENDER	:46 YRS/Male	SPECIMEN DATE	:22/Mar/2024 08:46AM
PATIENT ID	:132429	SPECIMEN RECEIVED	:22/Mar/2024 08:58AM
REFERRED BY	:Dr. MEDIWHEEL	REPORT DATE	:22/Mar/2024 03:04PM
CENTRE NAME	:ONEPLUS ULTRASOUND LAB	LAB NO.	:012403220008

Test Name	Result	Unit	Ref. Range
Others,	NIL	NIL	NIL

*** End Of Report ***

Checked By.

Dr NITIN AGARWAL
M B B S . MD (Path)
DMC/R/01436



DR. NITIN AGARWAL
MBBS,MD(PATHOLOGIST)

47, Harsh Vihar, Pitampura, Delhi-34 ☎ 011-4248 0101, 9599913051

✉ Email: oneplusul@gmail.com 🌐 www.oneplusul.in

Page 8 of 8

- Clinical correlation is essential for final diagnosis. • If test results are unsatisfactory please contact personally or on phone.
- This report is for perusal of doctors only. • All disputes are subject to Delhi jurisdiction only. • Not for medico legal case.
- All congenital anomalies in a foetus may not be diagnosed in routine obstetric ultrasound.



OnePLUS
Ultrasound Lab
— QUALITY FIRST... ALWAYS! —

Dr. Nitin Agarwal

Pathologist & Director
MBBS, MD, FAGE
Ex. Chief of Lab
Dr. Lal Path labs.

Dr. Pooja (Garg) Agarwal

Radiologist & Director
MBBS (MAMC) DMRD (MAMC)
Imaging Expert In Fetal And Maternal Medicine,
University of Barcelona, Spain
Fetal Medicine Foundation (UK) Accreditation

Name	: Mr. RAJESH KUMAR	Age/Sex	: 46 YRS/Male
Ref. By	: Dr. MEDIWHEEL	Lab No	: 012403220008
Date	: 22-Mar-2024	Patient ID	: LSHHI132429

ULTRASOUND EXAMINATION----WHOLE ABDOMEN

Liver is normal in size (14.6 cm) and outline with normal altered echopattern. **Diffuse increase in echogenicity of liver parenchyma is noted, suggestive of fatty infiltration (grade I).** No abscess or mass lesion seen. Hepatic veins, portal vein, IVC and aorta are normal. Intrahepatic biliary radicles are not dilated. CBD is normal in caliber.

Gall bladder is well distended with anechoic lumen. Wall thickness is normal.

Both kidneys are normal in size, shape, position, outline and echopattern. Corticomedullary differentiation is maintained. No pelvicalyceal dilation or calculus or mass lesion is seen.

Renal measurements are --

Rt. kidney – 8.9 x 3.8 cm.

Lt. kidney – 9.6 x 4.3 cm.

Spleen is normal in size (7.9 cm) and echotexture. No mass lesion seen.

Pancreas is normal in size, outline and echotexture.

Urinary bladder is normal in shape and position. No evidence of intravesical stone or mass seen.


Prostate is normal in size, shape and echopattern.

Prostate measures 3.7 x 3.2 x 2.6 cm. **Weight of prostate is 16.5 grams.**

No abnormal bowel wall thickening seen in right iliac fossa.

No free fluid seen anywhere in abdomen.

IMPRESSION: Fatty infiltration of liver (grade I) with no hepatomegaly.


DR. RASHMI BANSAL
RADIOLOGIST
REG. NO. DMC/R/10067
Dr. RASHMI BANSAL
Radiologist
Reg. No. DMC/R/10067

Type By : sangeeta
Type By : pooja

47, Harsh Vihar, Pitampura, Delhi-34 ☎ 011-4248 0101, 9599913051

✉ Email: oneplusul@gmail.com 🌐 www.oneplusul.in

- Clinical correlation is essential for final diagnosis. • If test results are unsatisfactory please contact personally or on phone.
- This report is for perusal of doctors only. • All disputes are subject to Delhi jurisdiction only. • Not for medico legal case.
- All congenital anomalies in a foetus may not be diagnosed in routine obstetric ultrasound.



OnePLUS
Ultrasound Lab
— QUALITY FIRST... ALWAYS! —

Dr. Nitin Agarwal

Pathologist & Director
MBBS, MD, FAGE
Ex. Chief of Lab
Dr. Lal Path labs.

Dr. Pooja (Garg) Agarwal

Radiologist & Director
MBBS (MAMC) DMRD (MAMC)
Imaging Expert In Fetal And Maternal Medicine,
University of Barcelona, Spain
Fetal Medicine Foundation (UK) Accreditation

Name	: Mr. RAJESH KUMAR	Age/Sex	: 46 YRS/Male
Ref. By	: Dr. MEDIWHEEL	Lab No	: 012403220008
Date	: 22-Mar-2024	Patient ID	: LSHHI132429

X-ray-Chest PA view

Bony cage and soft tissues are normal.

Cardiothoracic ratio is normal.

Mediastinum is normal.


Both hila are normal.

Both costophrenic angles are clear.

Both domes of diaphragm are normal.

Lung fields are clear. No parenchymal lesion seen.

IMPRESSION: Normal Study.


DR. POOJA GARG
RADIOLOGIST
REG NO- DMC/R/03398
Dr. POOJA GARG
M.B.B.S., D.M.R.D
Reg No DMC/R/03398
Radiologist

Type By : darshita

47, Harsh Vihar, Pitampura, Delhi-34 ☎ 011-4248 0101, 9599913051

✉ Email: oneplusul@gmail.com 🌐 www.oneplusul.in

- Clinical correlation is essential for final diagnosis. • If test results are unsatisfactory please contact personally or on phone.
- This report is for perusal of doctors only. • All disputes are subject to Delhi jurisdiction only. • Not for medico legal case.
- All congenital anomalies in a foetus may not be diagnosed in routine obstetric ultrasound.

ONEPLUS ULTRASOUND LAB

47, HARSH VIHAR, PITAMPURA, DELHI- 110034

Mr. RAJESH KUMAR
Age : 46/M
Ref. by - MEDIANHEEL
Indication1 :
Indication2 :
Indication3 :
COMMENTS :

ID : 2505
Hr/Wt : 170/77
Recorded : 22-3-2024 9:26
Medication1 :
Medication2 :
Medication3 :

BPM : 93
BP : 134/86
P Axis : 69 deg
QRS Axis : 91 deg
T Axis : 85 deg

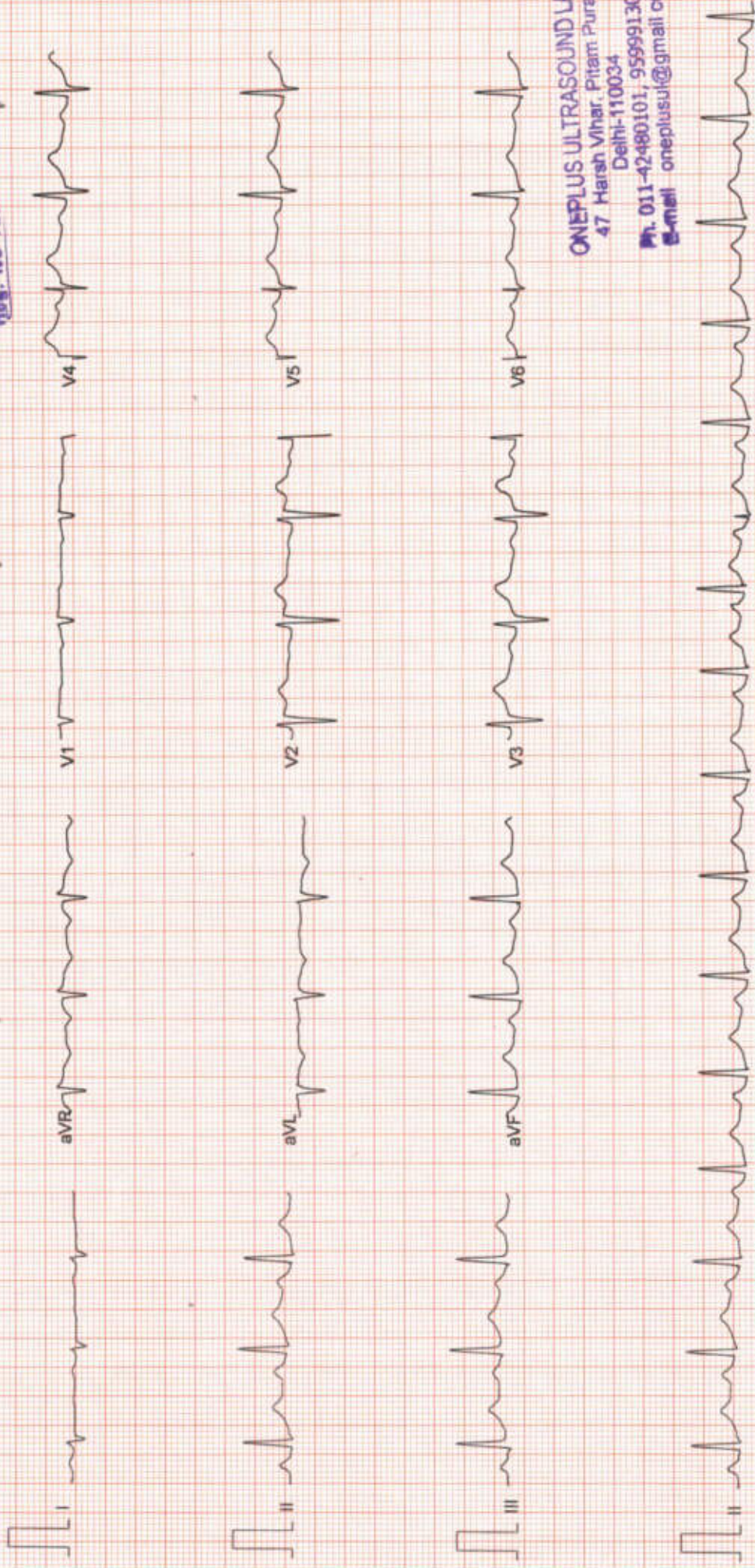
P duration : 106 msec
PR duration : 173 msec
QRS duration : 100 msec
QT interval : 320 msec
QTc interval : 377 msec

Raw E.C.G.(Seq)

Dr. P.K. GUPTA
MBBS, MD
Reg. No-1071

Unconfirmed Report Reviewed By:

Cardiologist



ONEPLUS ULTRASOUND LAB
47, Harsh Vihar, Pitam Pura,
Delhi-110034
Ph. 011-42480101, 9599913051
E-mail oneplusul@gmail.com

RS

ONEPLUS ULTRASOUND LAB

47, HARSH VIHAR PITAMPURA DELHI 110034

Mr. RAJESH KUMAR
Age/Sex : 46/M

ID : 998

Ref. by : MEDIWHEEL

H/Wt : 170/77

Indication1 :

Indication2 :

Indication3 :

TREADMILL TEST SUMMARY REPORT

Protocol: BRUCE

History:

Medication1 :

Medication2 :

Medication3 :

Recorded : 22-3-2024 9:32

PHASE	PHASE TIME	STAGE TIME	SPEED (Km./Hr.)	GRADE (%)	H.R. (BPM)	B.P. (mmHg)	RPP X100	II	ST LEVEL V2	V5	METS
SUPINE	0:01	0:01			97	134/86	129	-0.2	0.9	0.1	
STANDING					95	134/86	127	0.6	1.2	0.8	
HYPERVENT					108	134/86	144	0.6	1.0	0.7	
STAGE 1	2:59	2:59	2.70	10.00	120	134/86	160	0.1	0.4	0.4	4.80
STAGE 2	5:59	2:59	4.00	12.00	142	146/88	207	-0.4	0.0	-0.2	7.10
STAGE 3	7:44	1:44	5.40	14.00	152	160/90	243	-1.3	0.1	-0.3	8.78
PEAK EXER	7:47	1:47			154	160/90	246	-1.2	0.1	-0.4	8.83
RECOVERY	2:59	2:59	0.00	0.00	114	150/88	171	-0.4	-0.1	-0.5	
RECOVERY	4:04	4:04	0.00	0.00	113	138/86	155	-0.5	-0.1	-0.7	
RECOVERY	4:32	4:32	0.00	0.00	109	138/86	150	-0.5	-0.2	-0.4	

RESULTS

Exerose Duration : 7.47 Minutes
 Max Heart Rate : 154 bpm 88 % of target heart rate 174 bpm
 Max Blood Pressure : 160/90 mmHg
 Max Work Load : 8.83 METS

Negative for ischell etc

IMPRESSIONS

ONEPLUS ULTRASOUND LAB
 47 Harsh Vihar, Pitampura,
 Delhi-110034
 Ph. 011-42480101, 9555913038
 E-mail: oneplusul@gmail.com

Dr. P.K. GUPTA
MBBS, MD
Reg. No-1071

Cardiologist

PKS

ONEPLUS ULTRASOUND LAB

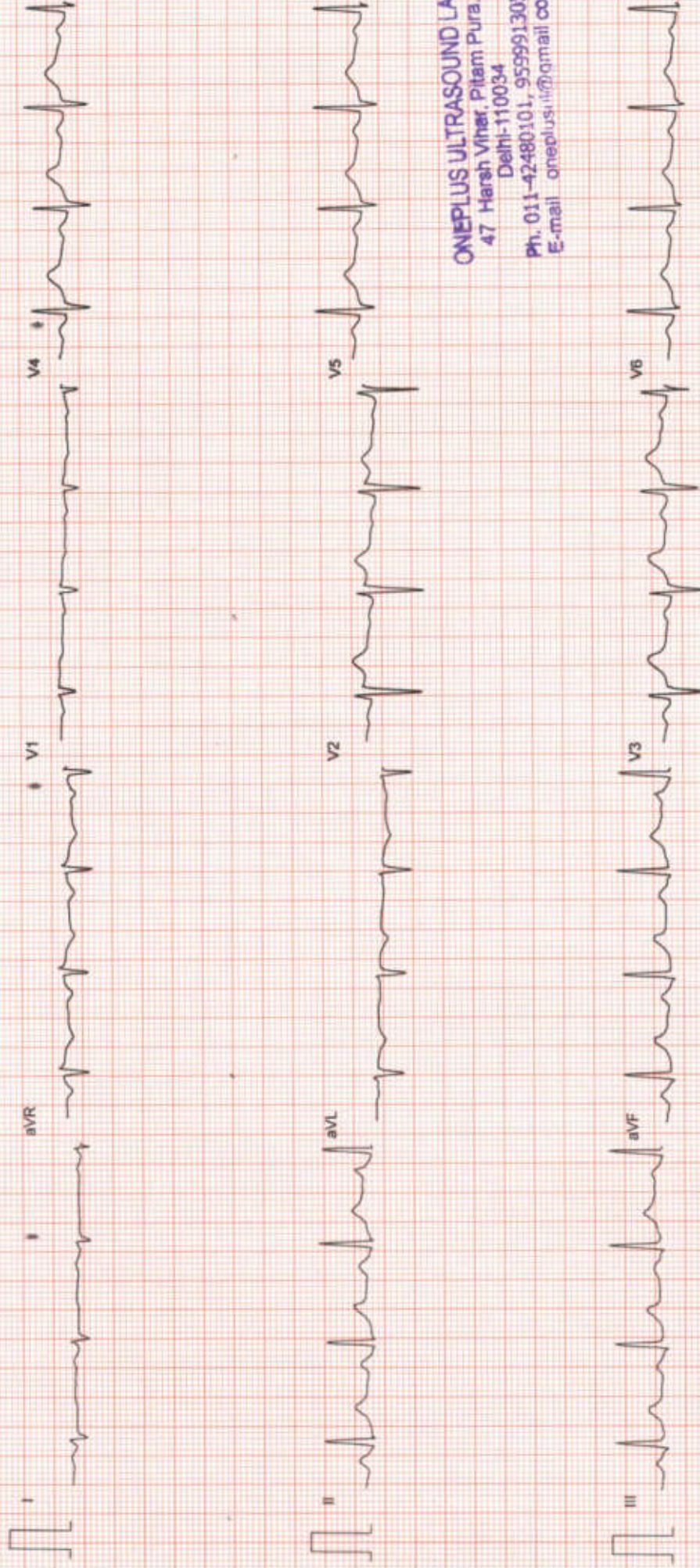
Mr. RAJESH KUMAR
I.D. : 998
AGE/SEX : 46/M
RECORDED : 22-3-2024 9:32

RATE : 97 BPM
B.P. : 134/86 mmHg

ST @ 10mm/mV
80ms PostJ

SUPINE
PRETEST

RAW E.C.G.



ONEPLUS ULTRASOUND LAB
47, Harsh Vihar, Pitam Pura,
Delhi-110034
Ph. 011-42480101, 9559913051
E-mail oneplus.ii@gmail.com

ONEPLUS ULTRASOUND LAB

Mr. RAJESH KUMAR

I.D. : 998

AGE/SEX : 46/M

RECORDED : 22-3-2024 9:32

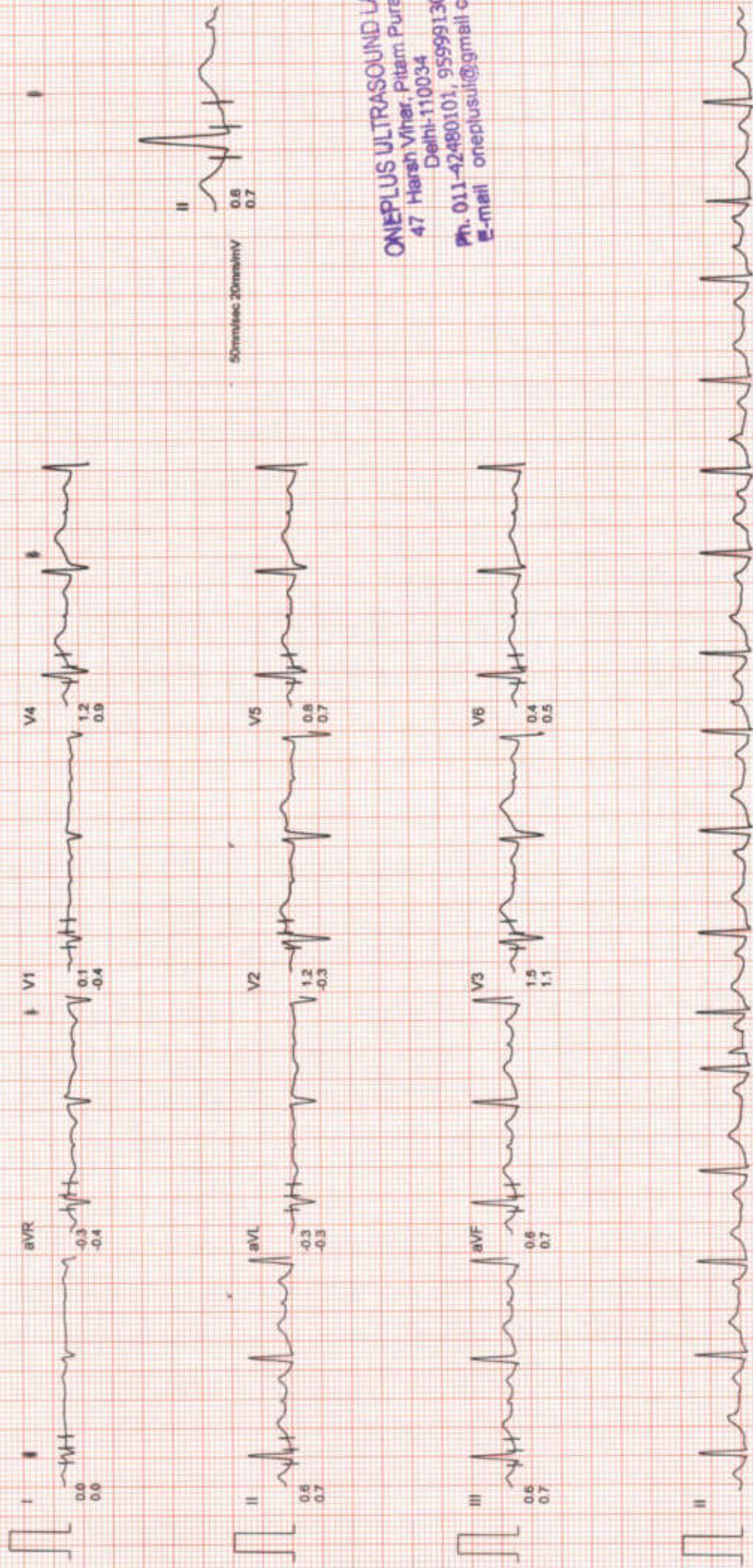
RATE : 95 BPM

B.P. : 134/86 mmHg

ST @ 10mm/mV
80ms PostJ

STANDING
PRETEST

LINKED MEDIAN



ONEPLUS ULTRASOUND LAB
47 Harsh Vihar, Pitam Pura,
Delhi-110034
Ph. 011-42480101, 9599913051
e-mail oneplusul@gmail.com

Filtered

Computer Corrected Baseline

25mm/sec 10mm/mV

CardiCom, INDIA Ph.:091-731-2620740, TeleFax:091-731-2431214

ONEPLUS ULTRASOUND LAB

HYPERVENTILATION
PRETEST

ST @ 10mm/mV
80ms PostJ

Mr. RAJESH KUMAR

I.D. : 998

AGE/SEX : 46/M

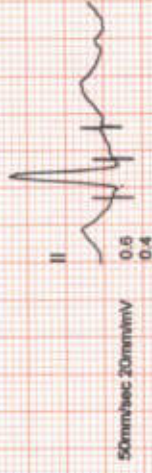
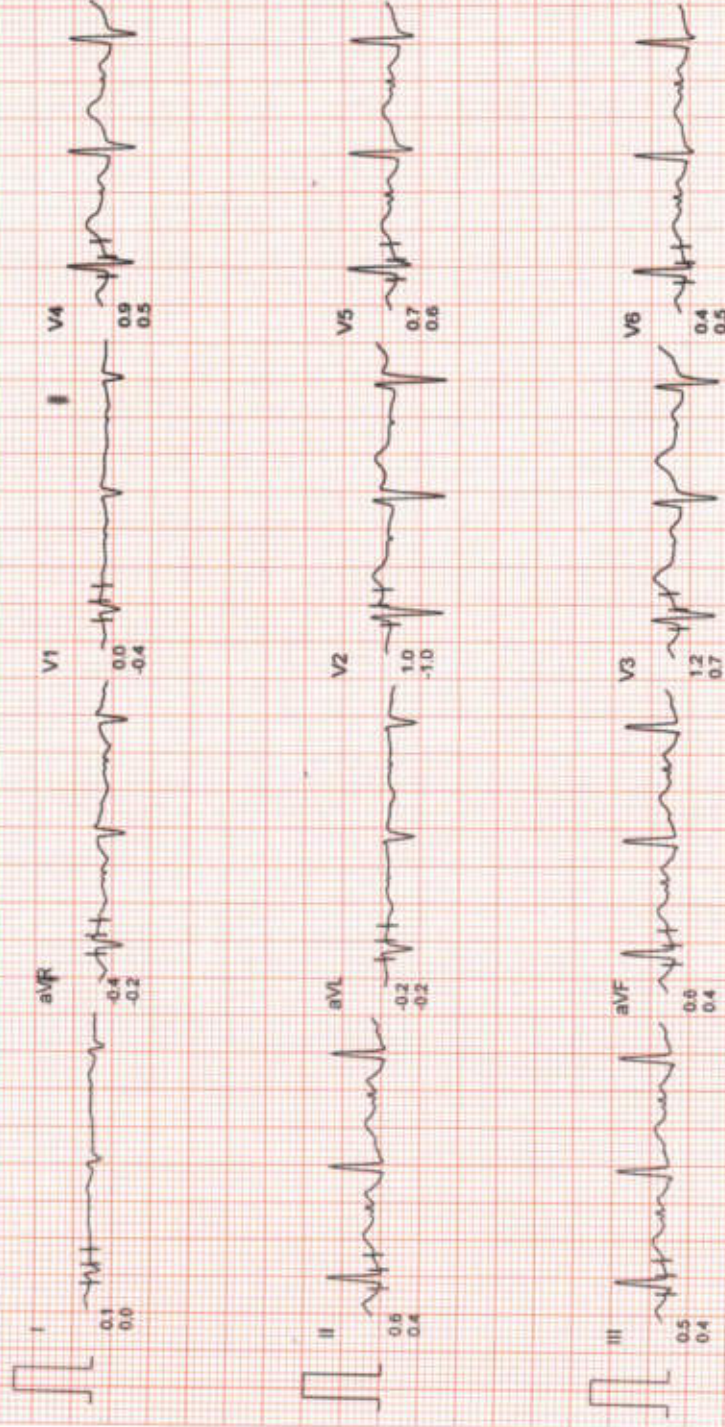
RECORDED : 22-3-2024 9:32

RATE : 108 BPM

B.P. : 134/86 mmHg

STAGE TIME : 0:01

LINKED MEDIAN



ONEPLUS ULTRASOUND LAB
47 Harsh Vihar, Pitam Pura,
Delhi-110034
Ph. 011-42480101, 9599913051
E-mail onepplusul@gmail.com

Filtered

Computer Corrected Baseline

25mm/sec 10mm/mV

CardiCom, INDIA Ph. 091-731-2620740, TeleFax: 091-731-2431214

ONEPLUS ULTRASOUND LAB

Mr. RAJESH KUMAR

I.D. : 998

AGE/SEX : 46/M

RECORDED : 22-3-2024 9:32

RATE : 120 BPM

B.P. : 134/86 mmHg

BRUCE

EXERCISE 1

PHASE TIME : 2:59

STAGE TIME : 2:59

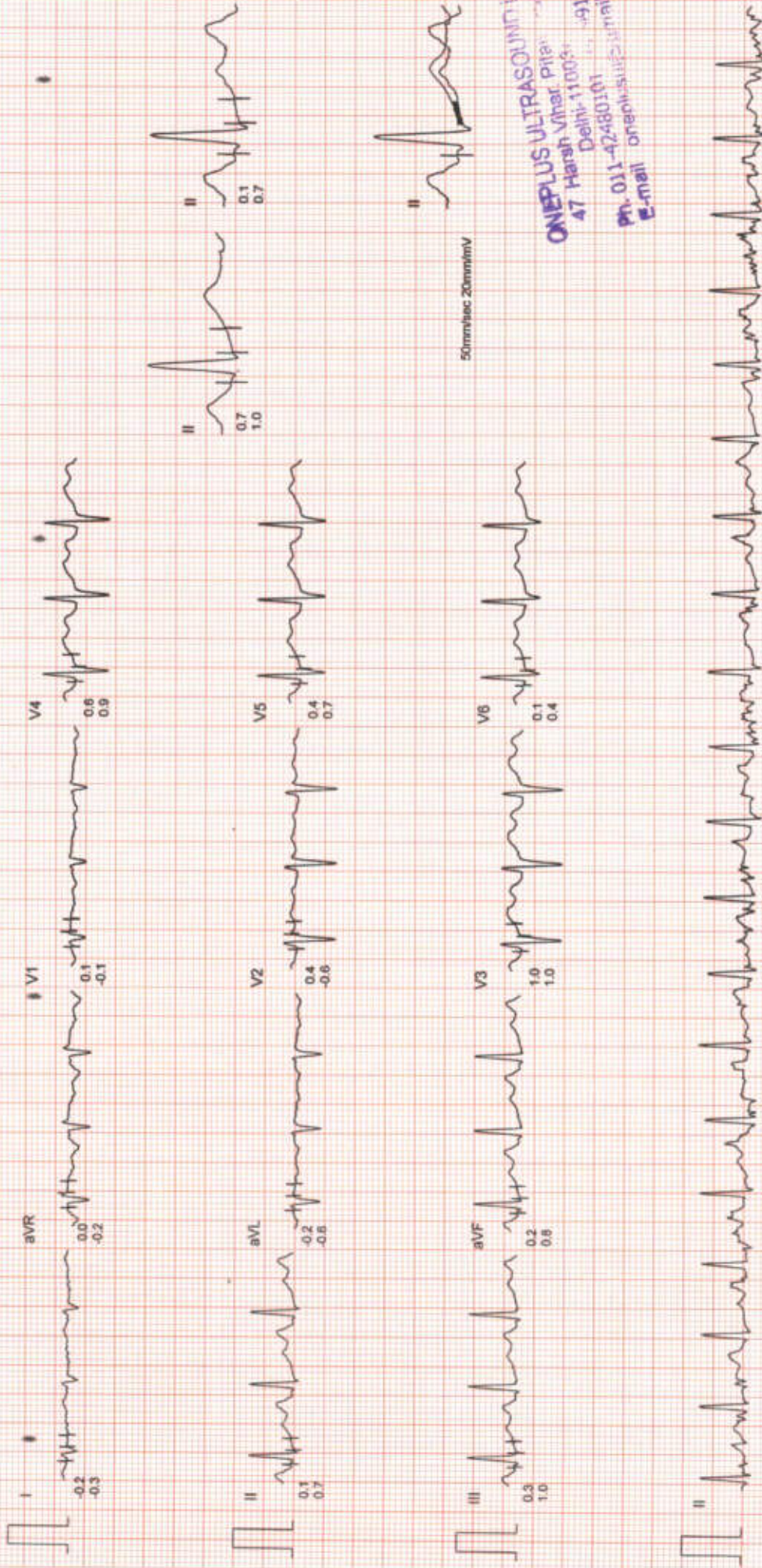
ST @ 10mm/mV

80ms PostJ

SPEED : 2.7 Km/Hr.

GRADE : 10.0 %

LINKED MEDIAN



ONEPLUS ULTRASOUND LAB
47 Harsh Vihar Pitiya, Ja.
Delhi-110031
Ph. 011-42480101, 4913058
E-mail onepplus@gmail.com

Filtered

Computer Corrected Baseline

25mm/sec 10mm/mV

CardiCom, INDIA Ph. 091-731-2620740, TeleFax 091-731-2431214

ONEPLUS ULTRASOUND LAB

Mr. RAJESH KUMAR

I.D. : 998

AGE/SEX : 46/M

RECORDED : 22-3-2024 9:32

RATE : 142 BPM

B.P. : 146/88 mmHg

BRUCE

EXERCISE 2

PHASE TIME : 5:59

STAGE TIME : 2:59

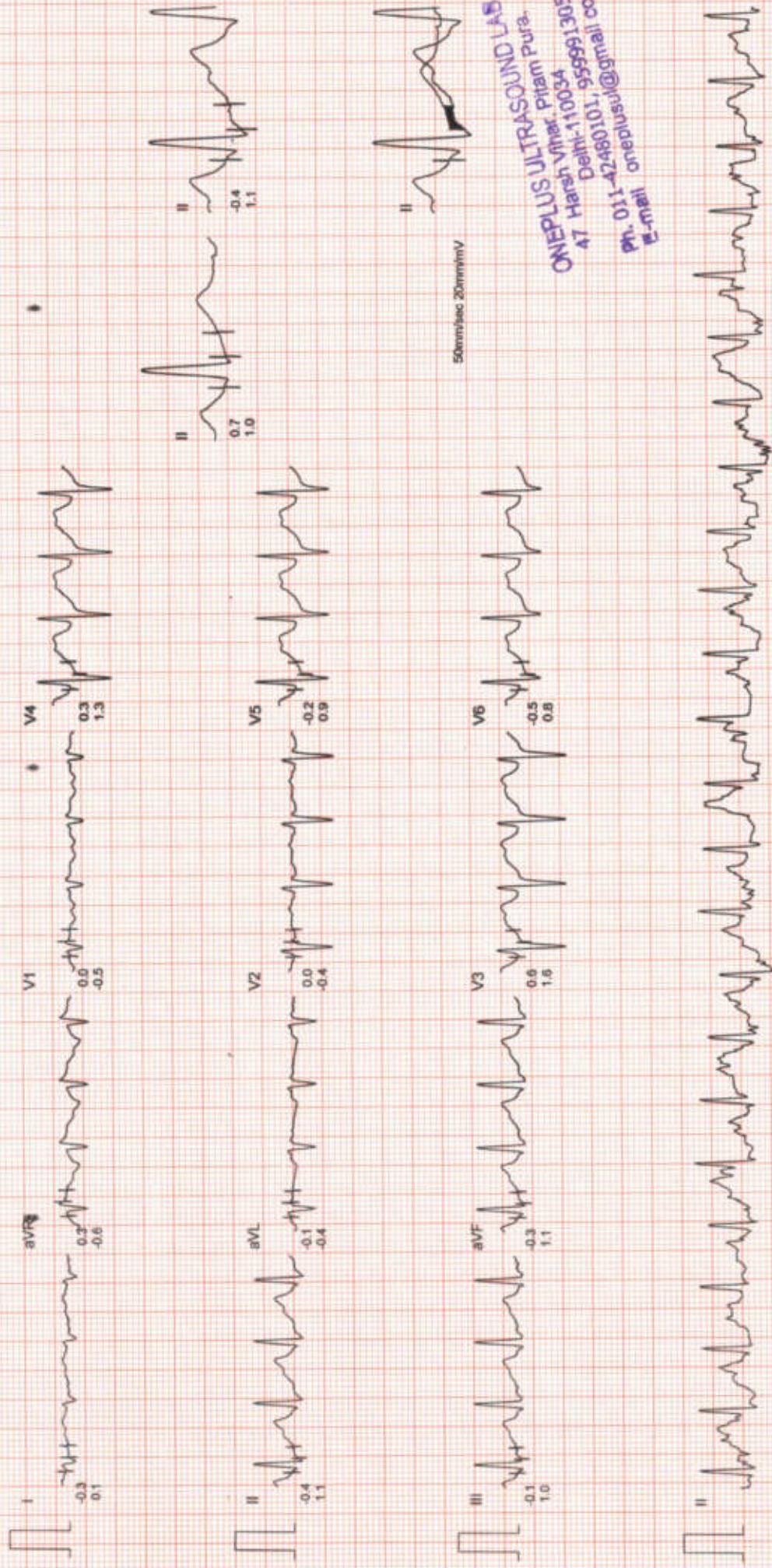
ST @ 10mm/mV

80ms PostJ

SPEED : 4.0 Km./Hr.

GRADE : 12.0 %

LINKED MEDIAN



50mm/sec 20mm/mV

ONEPLUS ULTRASOUND LAB
Dr. Harsh Vihar, Pratham P. area.
Delhi-110034
A7 Harsh Vihar, Pratham P. area.
Delhi-110034
Ph. 011-42480101, 9599913051
E-mail onepplusultrasound@gmail.com

ONEPLUS ULTRASOUND LAB

Mr. RAJESH KUMAR

I.D. : 998

AGE/SEX : 46/M

RECORDED : 22-3-2024 9:32

RATE : 152 BPM

B.P. : 160/90 mmHg

BRUCE

EXERCISE 3

PHASE TIME : 7:44

STAGE TIME : 1:44

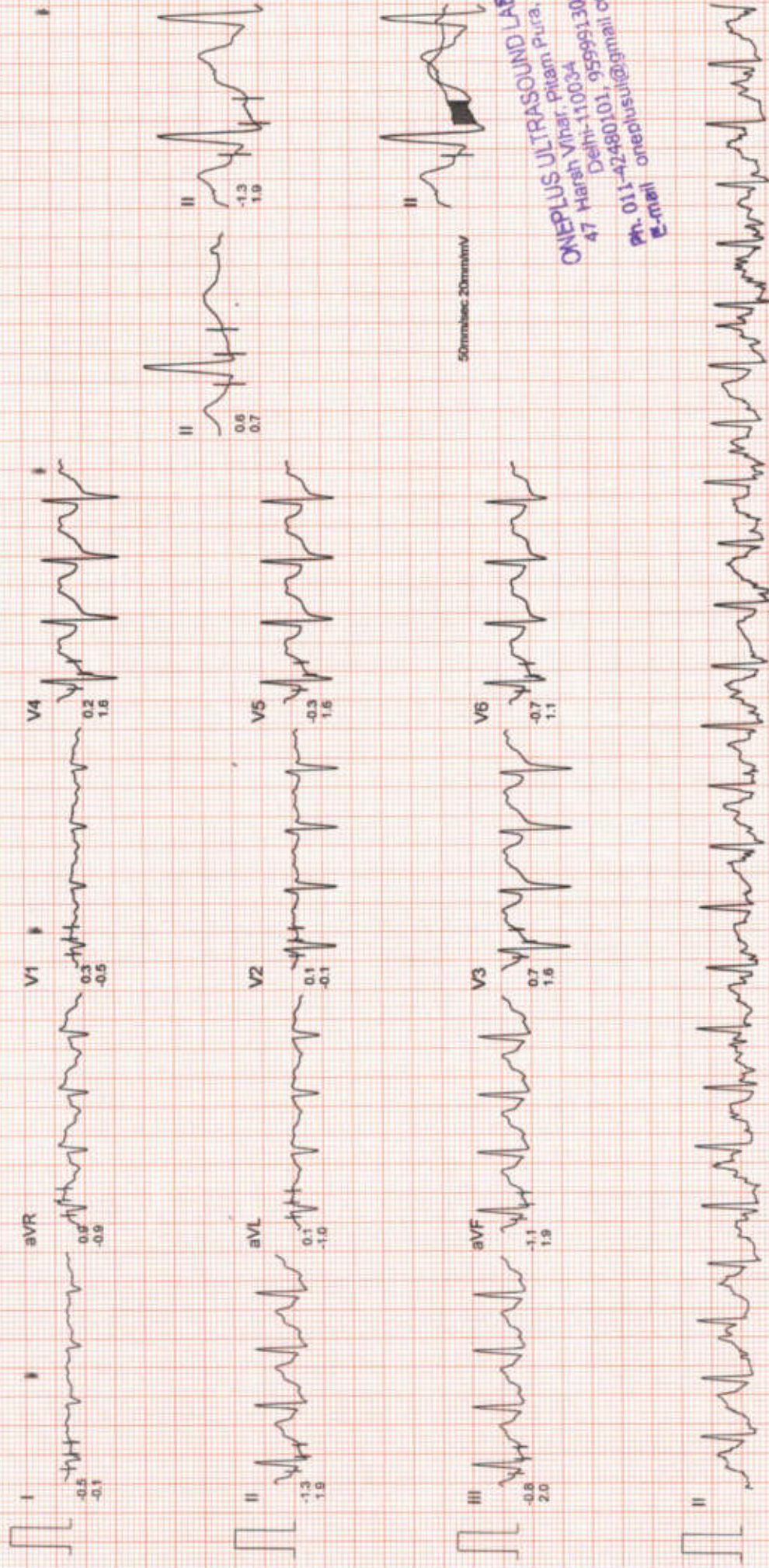
ST @ 10mm/mV

80ms PostJ

SPEED : 5.4 Km./Hr.

GRADE : 14.0 %

LINKED MEDIAN



50mm/sec 20mm/mV

ONEPLUS ULTRASOUND LAB
47 Hareh Vihar, Pitam Pura,
Delhi-110034
Ph. 011-42480101, 9559913053
E-mail onepplusul@gmail.com

ONEPLUS ULTRASOUND LAB

Mr. RAJESH KUMAR

I.D. : 998

AGE/SEX : 46/M

RECORDED : 22-3-2024 9:32

RATE : 154 BPM

B.P. : 160/90 mmHg

BRUCE

PEAK EXER

PHASE TIME : 7:47

STAGE TIME : 1:47

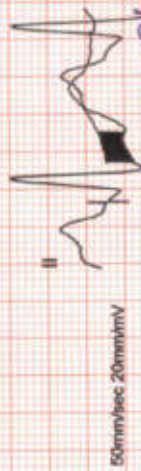
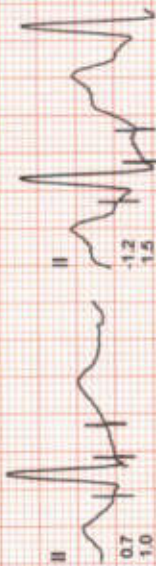
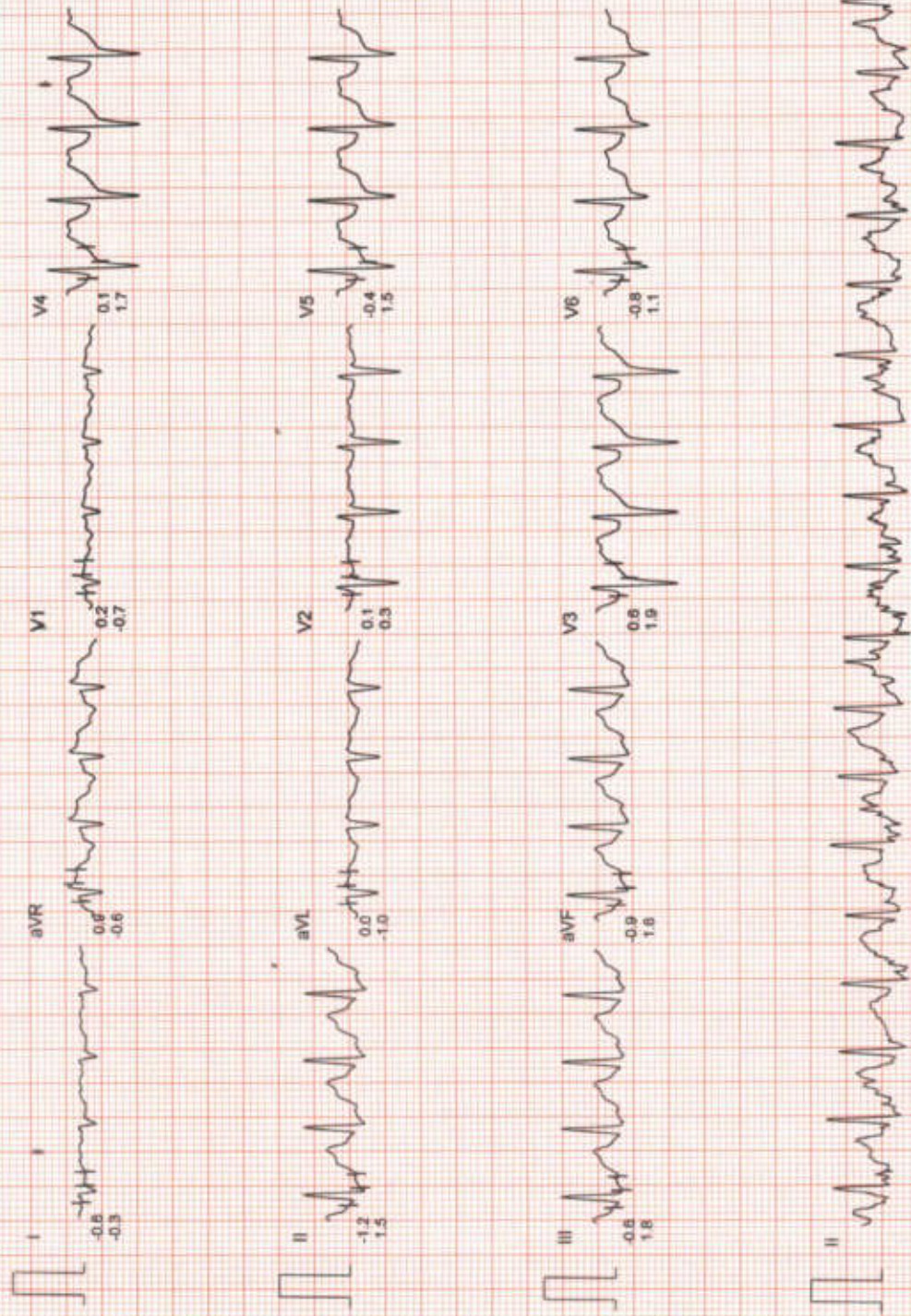
ST @ 10mm/mV

80ms PostJ

SPEED : 5.4 Km./Hr.

GRADE : 14.0 %

LINKED MEDIAN



ONEPLUS ULTRASOUND LAB
47 Harsh Vihar Pitam Pura,
Delhi-110034
Ph: 011-42480101, 9599913051
E-mail: oneplusultrasound@gmail.com

ONEPLUS ULTRASOUND LAB

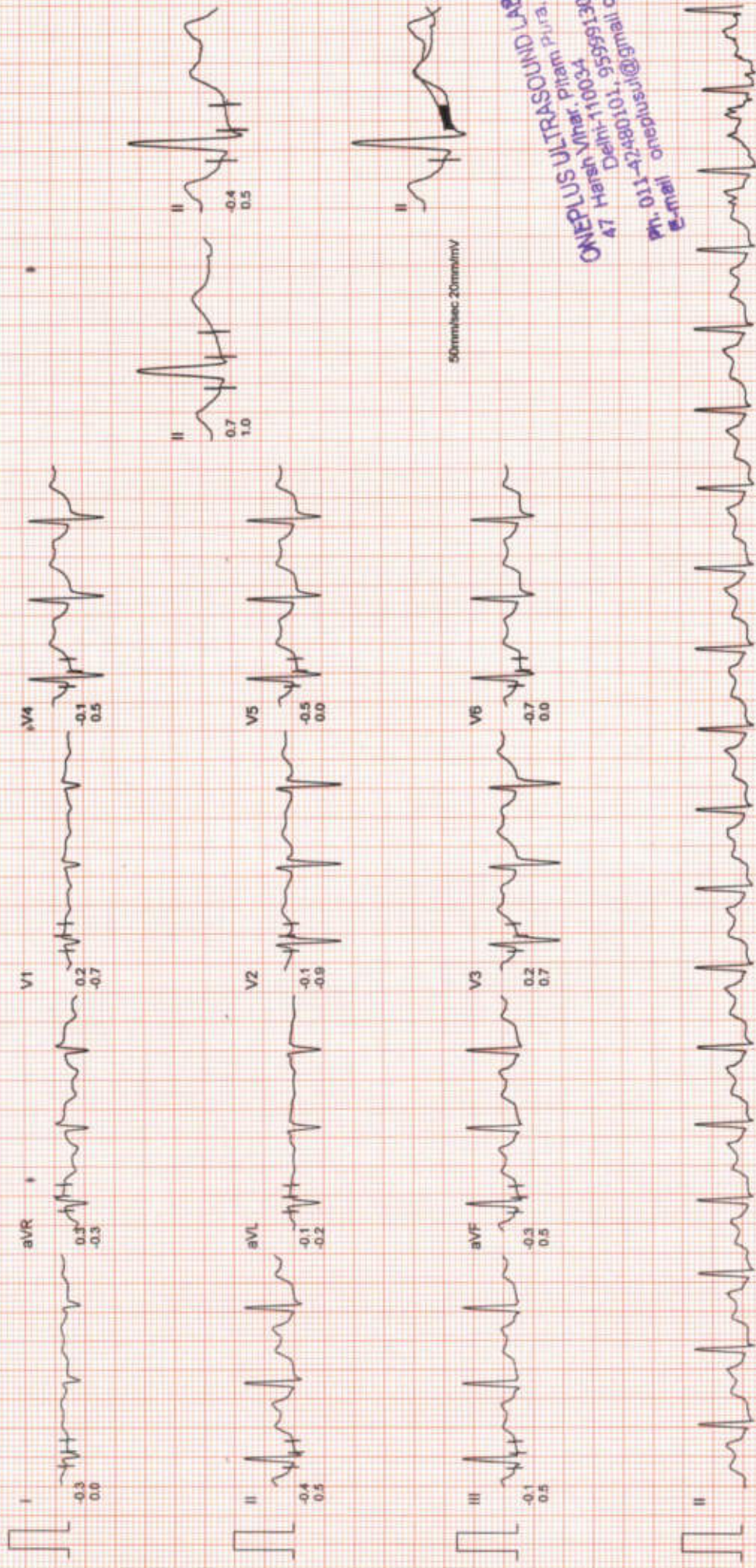
Mr. RAJESH KUMAR
I.D. : 998
AGE/SEX : 46/M
RECORDED : 22-3-2024 9:32

RATE : 114 BPM
B.P. : 150/88 mmHg

BRUCE
RECOVERY
PHASE TIME : 2:59

ST @ 10mm/mV
80ms PostJ
SPEED : 0.0 Km./Hr.
GRADE : 0.0 %

LINKED MEDIUM



ONEPLUS ULTRASOUND LAB
Dr. Hareesh Vihar, Pitambara, Ra.
Ph: 011-42481011, 9559913083
Email: oredipul@gnail.com

ONEPLUS ULTRASOUND LAB

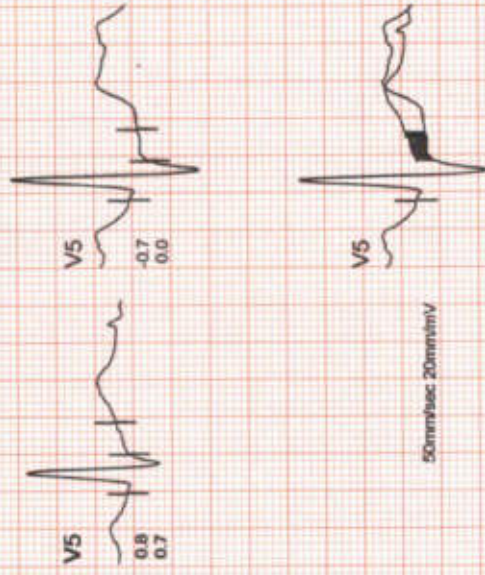
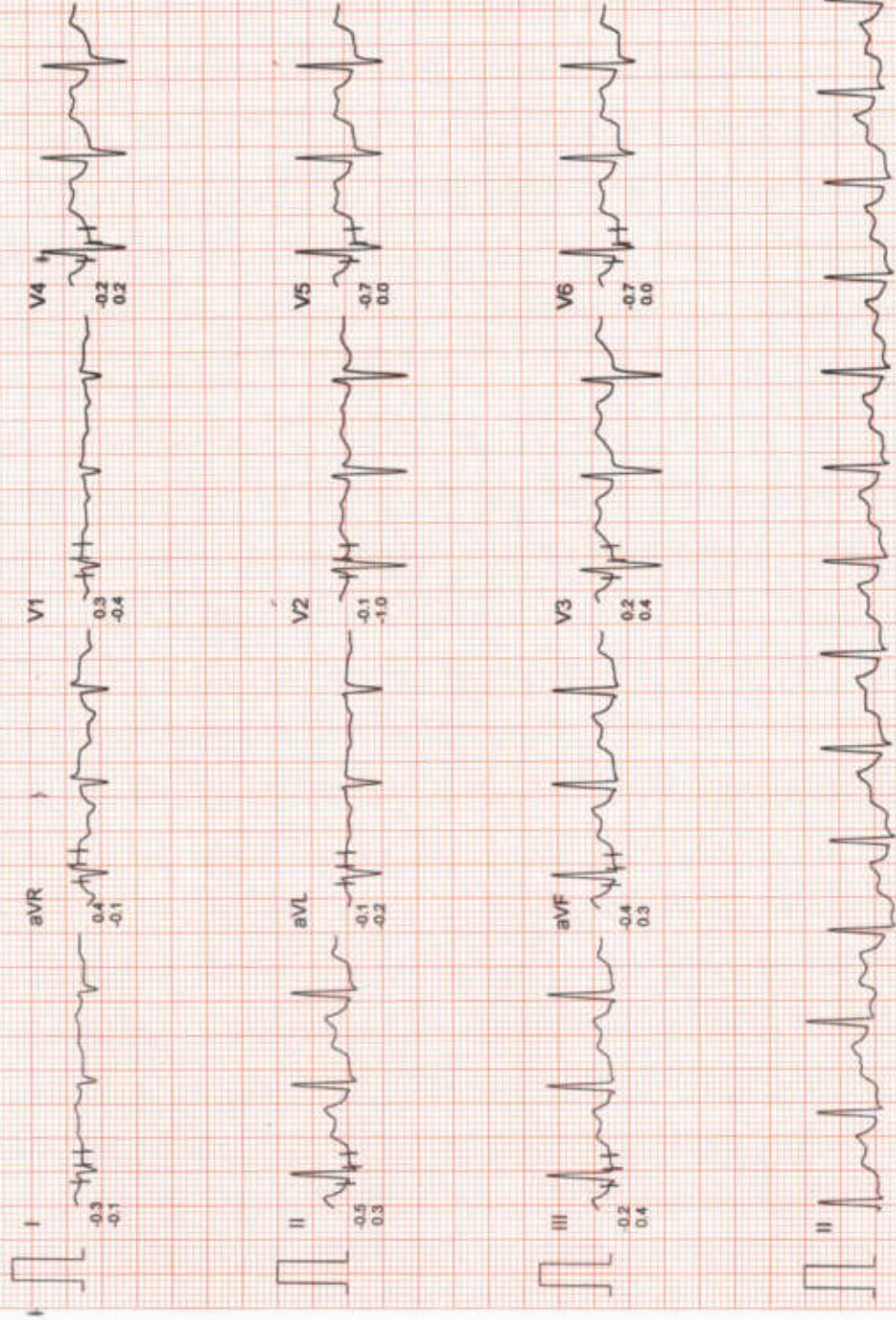
Mr. RAJESH KUMAR
I.D. : 998
AGE/SEX : 46/M
RECORDED : 22-3-2024 9:32

BRUCE
RECOVERY (RECOVERY)
PHASE TIME : 4:04

RATE : 113 BPM
B.P. : 138/86 mmHg

ST @ 10mm/mV
80ms PostJ
SPEED : 0.0 Km./Hr.
GRADE : 0.0 %

LINKED MEDIAN



ONEPLUS ULTRASOUND LAB
47 Harsu Vihar, Plot No. 110, Sector 14, Gurgaon, Haryana, India.
Ph: 01111110101, 01101081010
E-mail: info@oneplusultrasound.com

ONEPLUS ULTRASOUND LAB

Mr. RAJESH KUMAR

I.D. : 998

AGE/SEX : 46/M

RECORDED : 22-3-2024 9:32

RATE : 109 BPM

B.P. : 138/86 mmHg

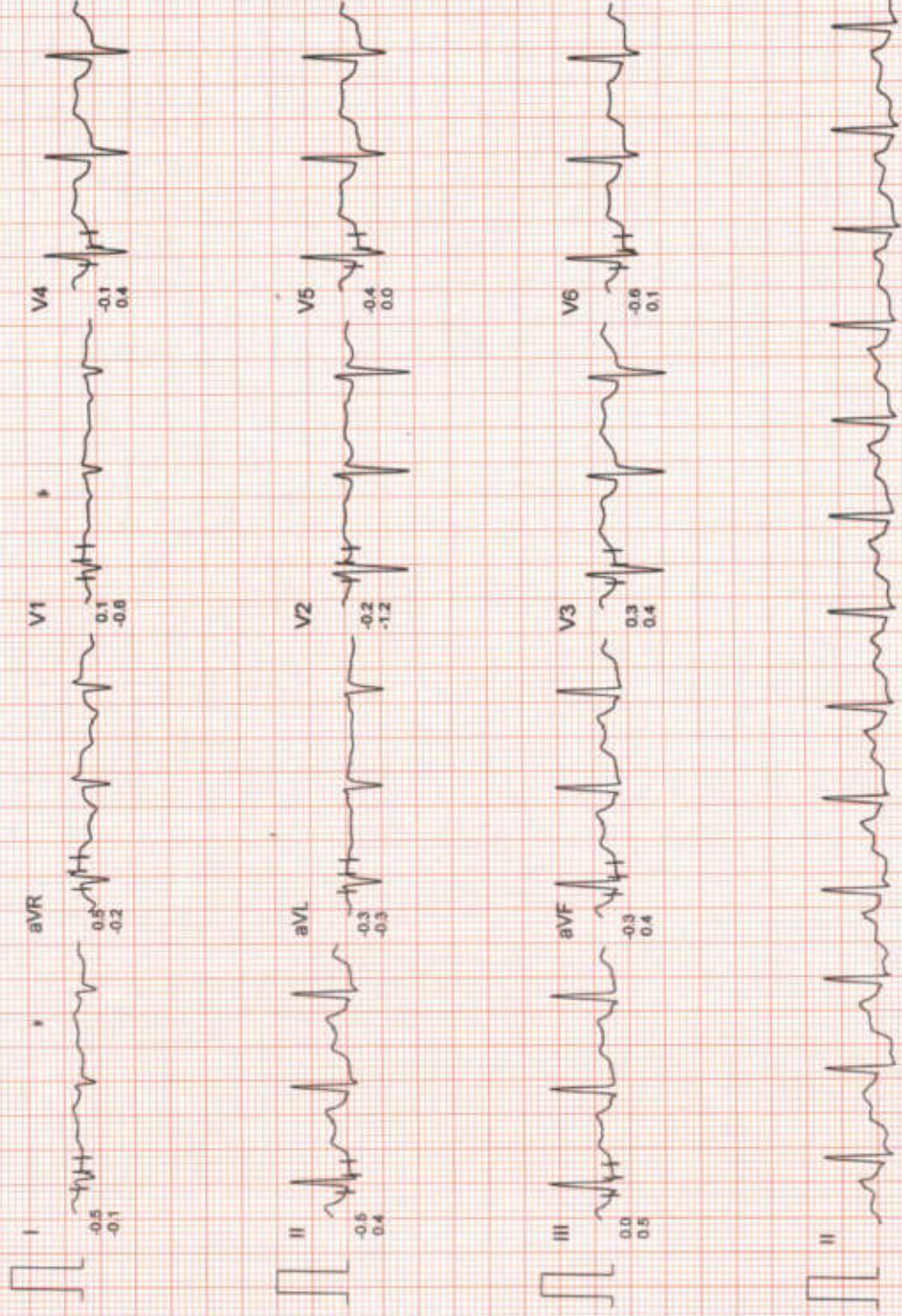
ST @ 10mm/mV

80ms PostJ

SPEED : 0.0 Km/Hr.

GRADE : 0.0 %

LINKED MEDIAN



ONEPLUS ULTRASOUND LAB
47, Harsh Vihar, Pitam Pura,
Delhi-110034
Ph: 011-42480101, 9599913051
E-mail: onepplusul@8mail.com

Filtered

Computer Corrected Baseline

25mm/sec 10mm/mV

CardiCor, INDIA Ph. 091-731-2620740, TeleFax.091-731-2431214

ONEPLUS ULTRASOUND LAB

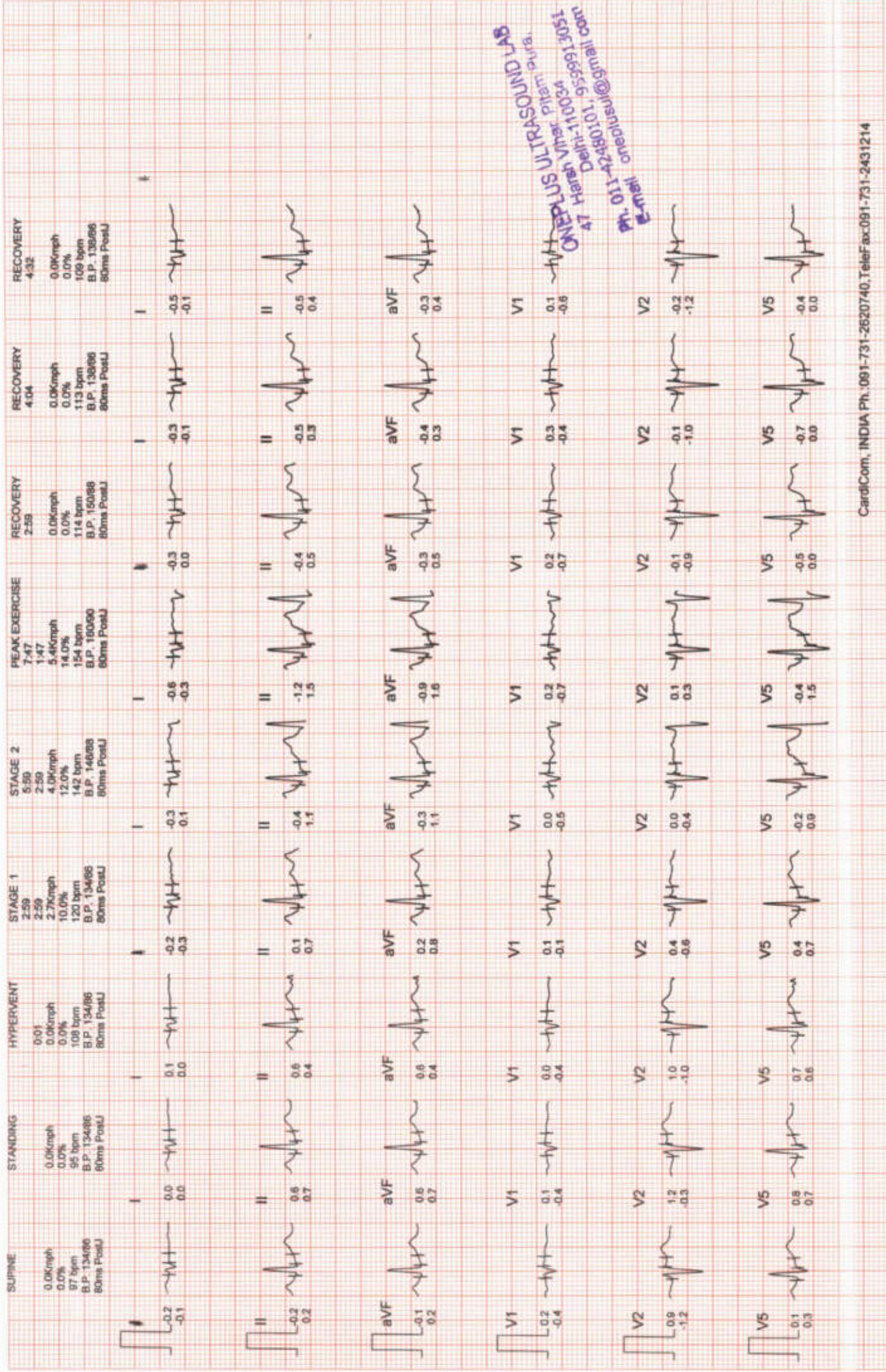
Mr. RAJESH KUMAR

I.D. : 998

AGE/SEX : 46/M

RECORDED : 22-3-2024 9:32

AVG E.C.G.



ONEPLUS ULTRASOUND LAB
 47 Haren Vihar, Patna, Bihar
 Delhi-110034
 Phone: 95599913051
 Email: onepplusultrasound@gmail.com

ONEPLUS ULTRASOUND LAB

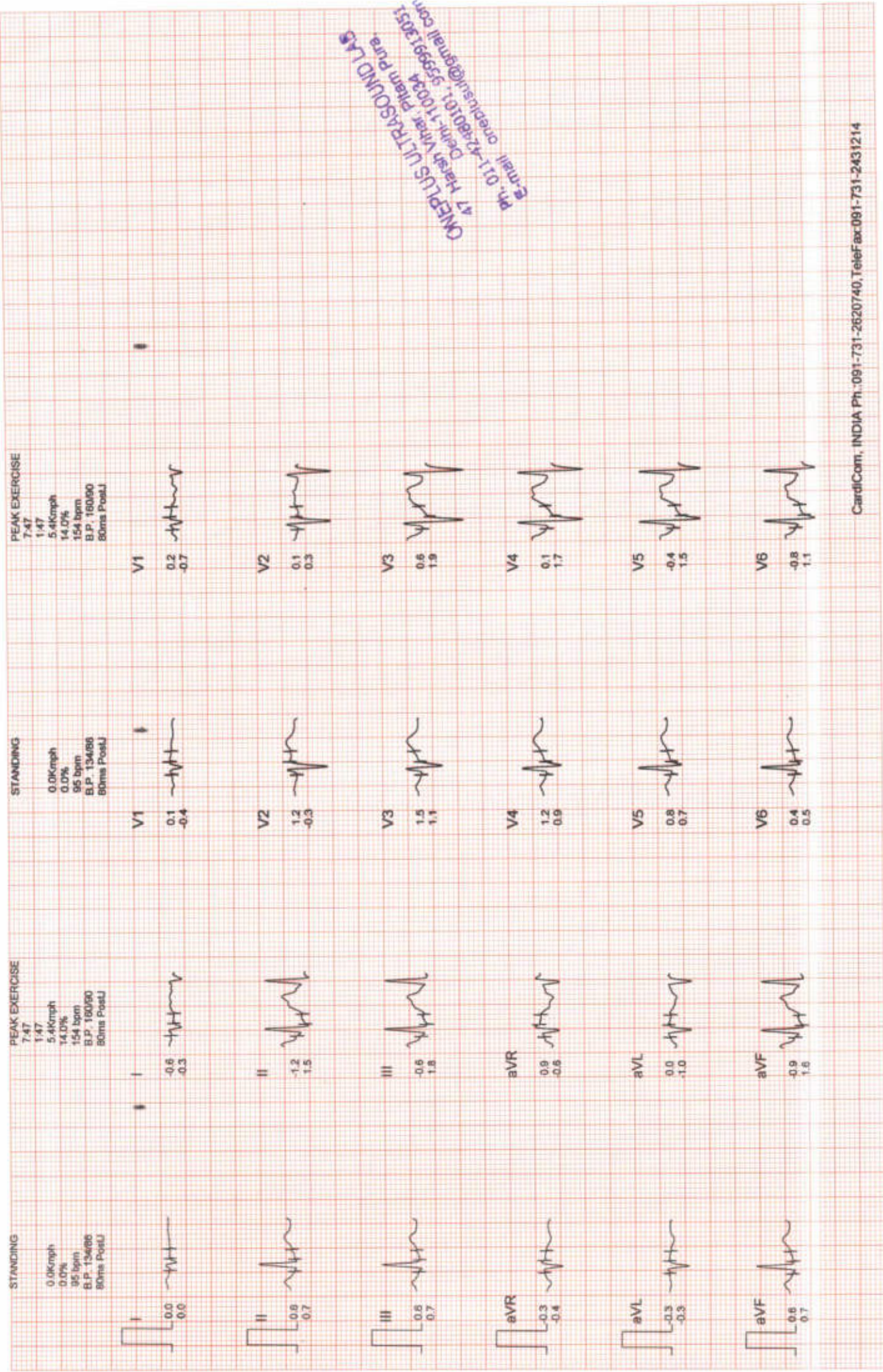
• Mr. RAJESH KUMAR

I.D. : 998

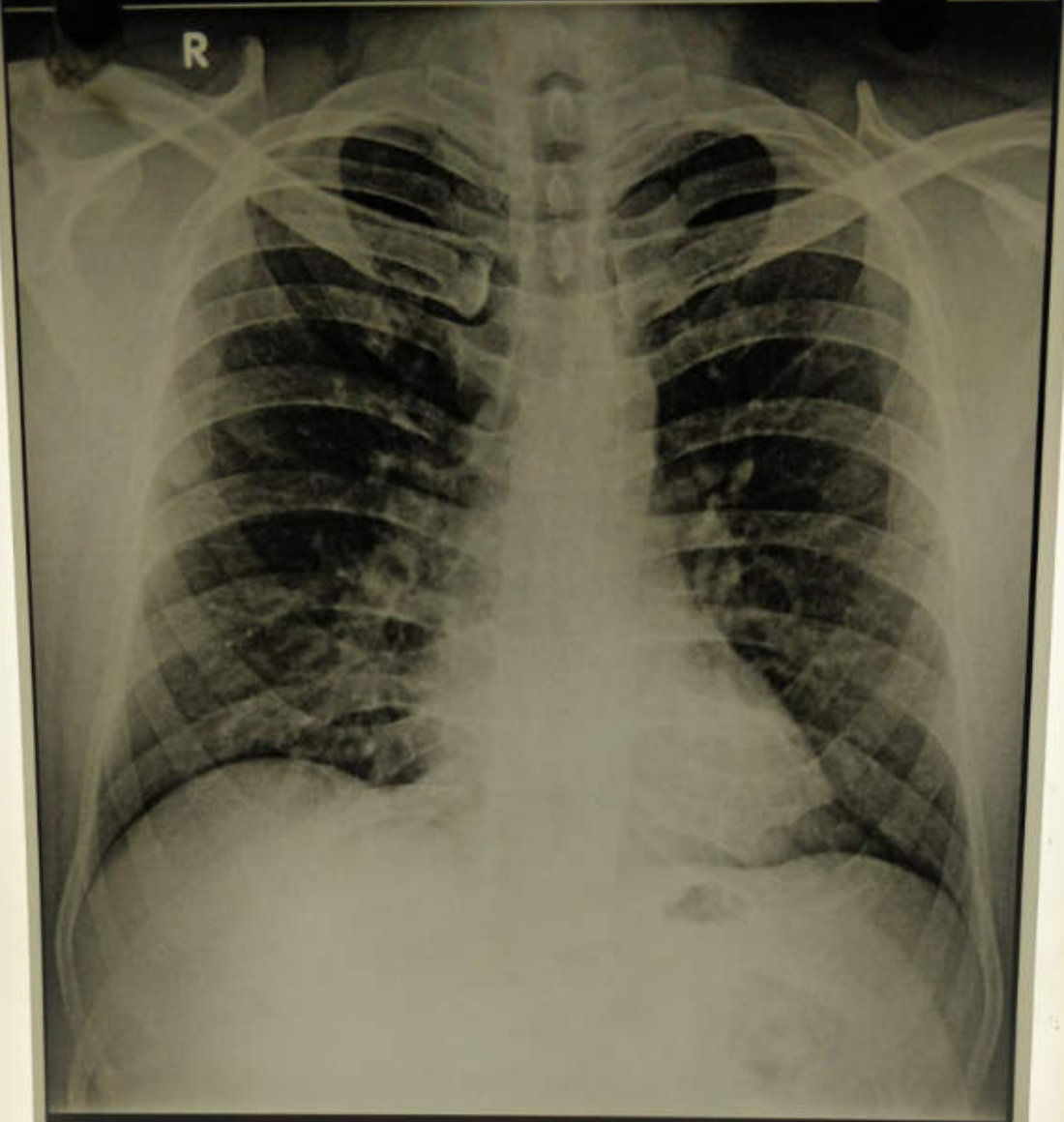AGE/SEX : 46/M

RECORDED : 22-3-2024 9:32

COMPARISON REPORT



ONEPLUS ULTRASOUND LAB
 47, Harsih Vihar, Pitam Pura,
 Delhi-110034
 Ph. 011-4248010, 9599913051
 E-mail: oneplusul@gmail.com



MR. RAJESH-KUMAR-AGE-46YRS/M 22-03-2024 CHEST PA VIEW
ONEPLUS ULTRASOUND LAB, 47-HARSH VIHAR, PITAMPURA