

Name : Mrs. B AKSHATHA

Age: 37 Y

Sex: F

UHID:CBAS.0000091212



OP Number:CBASOPV99226

Bill No :CBAS-OCR-60391

Date : 13.01.2024 10:07

Address : blr
Plan : ARCOFEMI MEDIWHEEL FEMALE AHC CREDIT PAN
INDIA OP AGREEMENT

Sno	Service Type/ServiceName	Department
1	ARCOFEMI - MEDIWHEEL - FULL BODY HEALTH ANNUAL PLUS CHECK - FEMALE - 2D ECHO - PAN INDIA - FY2324	
1	GAMMA GLUTAMYL TRANSFERASE (GGT)	
2	D ECHO	
3	LIVER FUNCTION TEST (LFT)	
4	GLUCOSE, FASTING	
5	HEMOGRAM + PERIPHERAL SMEAR	
6	GYNAECOLOGY CONSULTATION ✓	
7	DIET CONSULTATION	
8	COMPLETE URINE EXAMINATION	
9	URINE GLUCOSE(POST PRANDIAL)	
10	PERIPHERAL SMEAR	
11	ECG	
12	LBC PAP TEST- PAPSURE ✓	
13	RENAL PROFILE/RENAL FUNCTION TEST (RFT/KFT)	
14	DENTAL CONSULTATION	
15	GLUCOSE, POST PRANDIAL (PP), 2 HOURS (POST MEAL)	
16	URINE GLUCOSE(FASTING)	
17	HbA1c, GLYCATED HEMOGLOBIN	
18	X-RAY CHEST PA	
19	ENT CONSULTATION	
20	FITNESS BY GENERAL PHYSICIAN	
21	BLOOD GROUP ABO AND RH FACTOR	
22	LIPID PROFILE	
23	BODY MASS INDEX (BMI)	
24	OPHTHAL BY GENERAL PHYSICIAN	
25	ULTRASOUND - WHOLE ABDOMEN	
26	THYROID PROFILE (TOTAL T3, TOTAL T4, TSH)	

→ Physio
→ Dental
VIT D & B12

27. Sono. mano [999]

HT - 156
wt - 50.4
BP -
RR -
w.d - 82
H.P - 90

ECHOCARDIOGRAPHY REPORT

Name: MRS AKSHATA Age: 37 YEARS GENDER: FEMALE

Consultant: Dr.VISHAL KUMAR.H. Date : 13/01/2024

Findings

2D Echo cardiography

Chambers

- Left Ventricle: Normal, No RWMA'S,
- Left Atrium: Normal
- Right Ventricle: Normal
- Right Atrium: Normal

Septa

- IVS: Intact
- IAS: Intact

Valves

- Mitral Valve: Normal
- Tricuspid Valve: Normal
- Aortic Valve: Tricuspid, Normal Mobility
- Pulmonary Valve: Normal

Great Vessels

- Aorta: Normal
- Pulmonary Artery: Normal

Pericardium: Normal

Doppler echocardiography

Mitral Valve	E	0.79	m/sec	A	0.52	m/sec	No MR
Tricuspid Valve	E	0.42	m/sec	A	0.41	m/sec	No TR
Aortic Valve	Vmax	1.18	m/sec				No AR
Pulmonary Valve	Vmax	0.86	m/sec				No PR
Diastolic Dysfunction							

M-Mode Measurements

P	Parameter	Observed Value	Normal Range	
A	Aorta	2.5	2.6-3.6	cm
L	left Atrium	3.1	2.7-3.8	cm
A	Aortic Cusp Separation	1.6	1.4-1.7	cm
II	IVS - Diastole	1.0	0.9-1.1	cm
L	left Ventricle-Diastole	4.0	4.2-5.9	cm
P	Posterior wall-Diastole	1.0	0.9-1.1	cm
I	IVS-Systole	1.1	1.3-1.5	cm
LL	left Ventricle-Systole	3.1	2.1-4.0	cm
P	Posterior wall-Systole	1.0	1.3-1.5	cm
E	Ejection Fraction	60	≥ 50	%
F	Fractional shortening	30	≥ 20	%
R	Right Ventricle	2.6	2.0-3.3	cm

Impression -

- Normal Sized Cardiac Chambers
- No RWMA,S
- normal LV and RV Systolic Function, LVEF 60%
- Normal valves
- No Pericardial Effusion/Vegetation/Clot

DR. VISHAL KUMAR .H

CLINICAL CARDIOLOGIST

Date: IST: 2024-01-13 10:50:53

Personal Details
UHID: 01P3FGAT6RV0U3M
PatientID: 91212
Name: Akshaatha
Age: 37
Gender: Female
Mobile: 25896314785

**Pre-Existing Medical-
Conditions**

Vitals

Measurements
HR : 76 BPM
PR: 148 ms
PD: 107 ms
QRS: 80 ms
QRS Axis: 86 deg
QT/QTc: 359/404 ms

Interpretation

Normal sinus rhythm
Normal axis

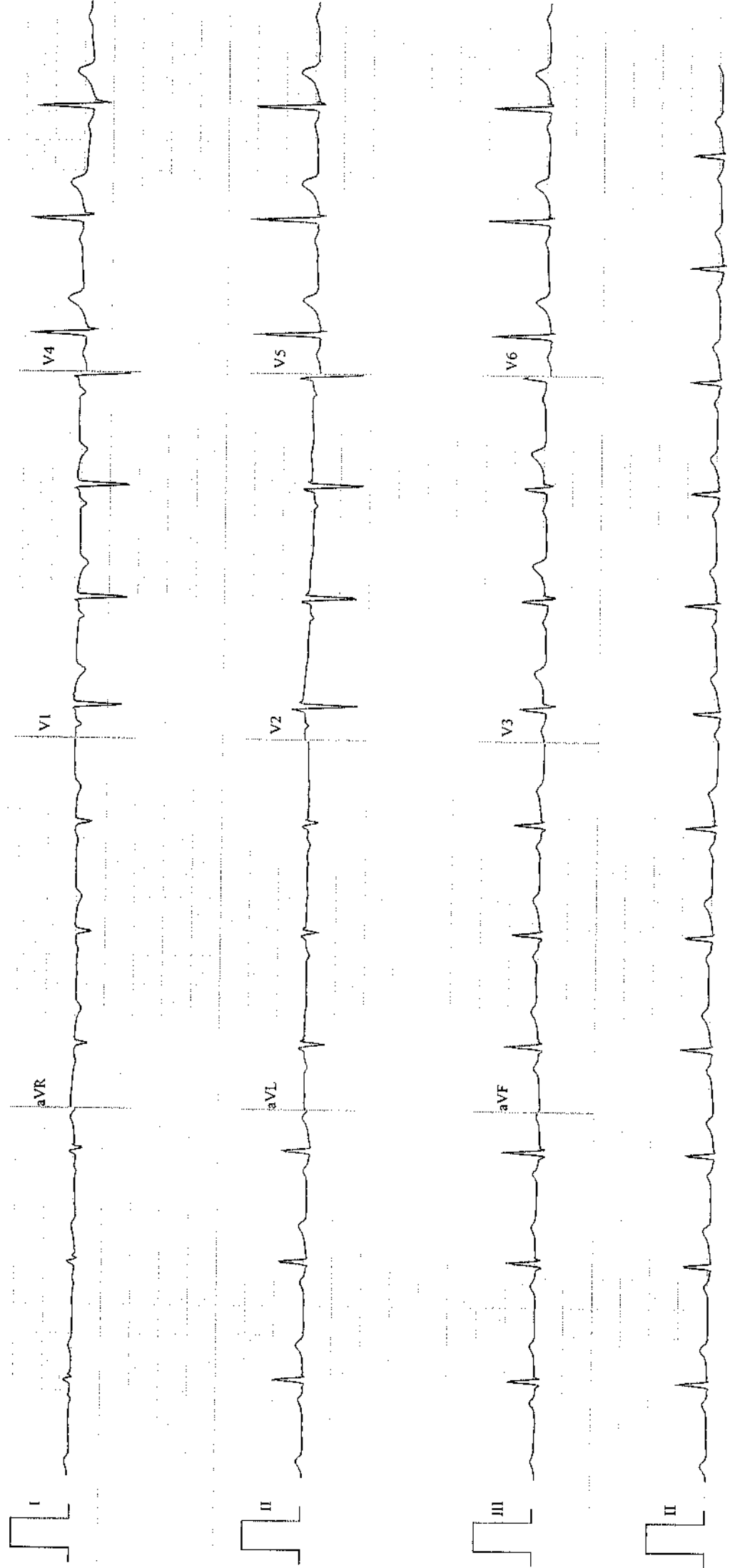
Report ID: AHLLP_01P3FGAT6RV0U3M_V6RV0U4T

Authorized by

Yogesh

Dr. Yogesh Kodhari
MD, DNB, FESC, FEP
Reg. No- KMC. 44065

This trace is generated by KardioScreen, Cloud-Connected, Portable, Digital, 6-12 Lead Scalable ECG Platform from IMEDRIX



Speed: 25 mm/sec F: 0.05 - 40 Hz Limb: 10 mm/mV Chest: 10 mm/mV

Disclaimer: Analytic in this report is based on ECG alone and should be used as an adjunct to clinical history, symptoms and results of other non-invasive tests and must be interpreted by a qualified physician.

PAP SMEAR CONSENT FORM

PATIENT NAME: Alexandra

AGE: 31

GENDER: F

DATE: 13/1/24

MENSTRUAL AND REPRODUCTIVE HISTORY

AGE OF MENARCHE : 13

AGE OF MENOPAUSAL IF APPLICABLE : _____

MENSTRUAL REGULARITY : REGULAR / IRREGULAR

FIRST DAY OF LAST MENSTRUATION PERIOD: 8-1-24

AGE AT MARRIAGE : 25

YEAR'S OF MARRIED LIFE : 12

CONTRACEPTION : YES () NO () IF YES WHAT KIND?

HORMONAL TREATMENT : YES () NO () IF YES WHAT KIND?

GRAVIDA (NO OF TIME'S CONCEIVED) : _____

PARA (NO OF CHILDBIRTH) : _____

LIVE (NO OF LIVING CHILDREN) : _____

ABORTIONS : _____

MISCARRIAGES/ABORTION : _____

AGE OF FIRST CHILD : _____

AGE OF LAST CHILD : _____

PREVIOUS PAP SMEAR REPORT : _____

4-5 / 20
P2L25 137 } both
74 } 4/D

SPECULUM EXAMINATION FINDINGS

EXTERNAL GENITALIA


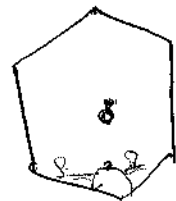
VAGINA

CERVIX

SMEAR THAKEN FROM - ENDOCERVIX

ECTOCERVIX

POSTERIOR VAGINA



Apollo Clinic

CONSENT FORM

Patient Name: Akshatha B Age: 37
UHID Number: Company Name:

I Mr/Mrs/Ms Employee of

(Company) Want to inform you that I am not interested in getting
Tests done which is a part of my routine health check package.
And I claim the above statement in my full consciousness.

*Diet consultation
Dental consultation
ENT consultation
General physician*

Patient Signature: Date: 13/1/2024

RE: Health Check-up Booking No. 2 (Annual)

Corporate Apollo Clinic <corporate@apolloclinic.com>

Fri 1/12/2024 7:18 PM

To: Wellness : Mediwheel : New Delhi <wellness@mediwheel.in>; Customer Care : Mediwheel : New Delhi <customercare@mediwheel.in>

Cc: Network : Mediwheel : New Delhi <network@mediwheel.in>; deepak <deepak.c@apolloclinic.com>; Basavanagudi Apolloclinic <basavanagudi@apolloclinic.com>

Namaste Team,

Greetings from Apollo clinics,

With regards to the below request appointments are confirmed at 9:00AM.

Thanks & Regards,

Shalini.M | Apollo Clinics | Pan India Toll No: 1860 500 7788 | Contact E-Mail: corporate@apolloclinic.com | www.apolloclinic.com |

From: Wellness : Mediwheel : New Delhi <wellness@mediwheel.in>

Sent: Friday, January 12, 2024 4:15 PM

To: Corporate Apollo Clinic <corporate@apolloclinic.com>; Customer Care : Mediwheel : New Delhi <customercare@mediwheel.in>

Cc: Network : Mediwheel : New Delhi <network@mediwheel.in>; deepak <deepak.c@apolloclinic.com>

Subject: Re: Health Check-up Booking No. 2 (Annual)


Dear Team,

Please note the following Health Check-up Booking and confirm the same.

S. No.	Appointment Details	INDIA - FY	Booking ID	Booked By	Age	Gender	Mobile No.	Appointment ID	Appointment Date	Appointment Time	Location	State
1	ARCOFEMI - MEDIWHEEL - FULL BODY ANNUAL PLUS MALE - 2D ECHO - PAN	INDIA - FY2324	bobS2832	Ganesh Prasad	38	Male	ab159205@bankofbaroda.co.in	9901637124	13-01-2024	9:00 AM	Apollo Clinic - Basavanagudi	Karnat
2	ARCOFEMI - MEDIWHEEL - FULL BODY HEALTH ANNUAL PLUS CHECK - FEMALE - 2D ECHO - PAN	INDIA - FY2324	bobE2831	MS. B AKSHATHA	37	Female	ab159205@bankofbaroda.co.in	9901637124	13-01-2024	9:00 AM	Apollo Clinic - Basavanagudi	Karnat

Thanks & Regards

Lav Gupta



Arcofemi Health Care Ltd. | F-701 A, Lado Sarai, Mehrauli | New Delhi - 110 030

M. 8800465156 Email : wellness@mediwheel.in; | Web: www.mediwheel.in

From: Corporate Apollo Clinic <corporate@apolloclinic.com>

Sent: Friday, January 12, 2024 3:43 PM

To: Customer Care : Mediwheel : New Delhi <customercare@mediwheel.in>

Cc: Wellness : Mediwheel : New Delhi <wellness@mediwheel.in>; Network : Mediwheel : New Delhi <network@mediwheel.in>; deepak <deepak.c@apolloclinic.com>

Subject: RE: Health Check-up Booking No. 2 (Annual)

Namaste Team,

Greetings from Apollo Clinics,

Please Suggest Correct Package to schedule the Appointment

Thanks & Regards,

Kumar | Apollo Clinics | Pan India Toll No: 1860 500 7788 | Contact E-Mail: corporate@apolloclinic.com | www.apolloclinic.com |



ಭಾರತೀಯ ವಿಶಿಷ್ಟ ಗುರುತು ಪ್ರಾಧಿಕಾರ

ಭಾರತ ಸರ್ಕಾರ
Unique Identification Authority of India
Government of India

ನೋಂದಣಿ ಸಂಖ್ಯೆ Enrolment No.: 1377/40405/01424


To
ಅಕ್ಷತಾ ಬಿ
Akshatha B
D/O: Harish Malliya
#39
2nd Cross
Sanjay Nagar
Venkatappa Layout
Bangalore North
R.m.v. Extension II Stage
Bangalore Karnataka - 560094
9901637124

Download Date: 17/10/2013

Generation Date: 23/06/2013

Signature valid

Doc No: 1377/40405/01424
UID: 7929 1521 6177
Date: 2013-10-18 18:10:39
03



QR Code with Photograph

ನಿಮ್ಮ ಆಧಾರ್ ಸಂಖ್ಯೆ / Your Aadhaar No. :

7929 1521 6177

VID : 9189 8386 6772 1688

ನನ್ನ ಆಧಾರ್, ನನ್ನ ಗುರುತು



ಭಾರತ ಸರ್ಕಾರ
Government of India




ಅಕ್ಷತಾ ಬಿ
Akshatha B
ಜನನ ದಿನಾಂಕ/DOB: 01/05/1986
♀/FEMALE

7929 1521 6177

VID : 9189 8386 6772 1688

ನನ್ನ ಆಧಾರ್, ನನ್ನ ಗುರುತು



Government of India



ಮಾಹಿತಿ

- ಆಧಾರ್ ಗುರುತಿನ ಪುರಾವೆಯೇ ಹೊರತು ಪೌರತ್ವದಲ್ಲ
- ನಿಮ್ಮ ಗುರುತನ್ನು ಸಾಬೀತುಪಡಿಸಲು ಆನ್ ಲೈನ್ ಮೂಲಕ ದೃಢೀಕರಿಸಿ
- ಎಲೆಕ್ಟ್ರಾನಿಕ್ ಪ್ರಕ್ರಿಯೆ ಮೂಲಕ ಮುದ್ರಿತವಾದ ವಿದ್ಯುನ್ಮಾನ ದಾಖಲೆ ಇದಾಗಿದೆ

INFORMATION

- Aadhaar is a proof of identity, not of citizenship.
- To establish identity, authenticate online.
- This is electronically generated letter.


- ಆಧಾರ್ ದೇಶವಾದ್ಯಂತ ಮಾನ್ಯತೆಯನ್ನು ಪಡೆದಿದೆ.
- ಭವಿಷ್ಯದಲ್ಲಿ ಸರ್ಕಾರಿ ಹಾಗೂ ಸರ್ಕಾರೇತರ ಸೇವೆಗಳನ್ನು ಪಡೆಯಲು ಆಧಾರ್ ನಿಮಗೆ ಸಹಾಯಕವಾಗಲಿದೆ.
- Aadhaar is valid throughout the country.
- Aadhaar will be helpful in availing Government and Non-Government services in future.



ಭಾರತೀಯ ವಿಶಿಷ್ಟ ಗುರುತು ಪ್ರಾಧಿಕಾರ
Unique Identification Authority of India

ವಿಳಾಸ:
D/O: ಹರೀಶ್ ಮಲ್ಲಾ, #39, 2ನೇ ಕ್ರಾಸ್, ಸಂಜಯ ನಗರ,
ವೆಂಕಟಪ್ಪ ಬಡಾವಣೆ, ಬೆಂಗಳೂರು ಉತ್ತರ, ಬೆಂಗಳೂರು,
ಕರ್ನಾಟಕ - 560094

Address:
D/O: Harish Malliya, #39, 2nd Cross, Sanjay
Nagar, Venkatappa Layout, Bangalore
North, Bangalore,
Karnataka - 560094



QR Code with Photograph

7929 1521 6177

VID : 9189 8386 6772 1688



www.aadhaar.gov.in



Mrs. B. Akshatha

37/P

9/2/22

13/1/24

EYE CHECK UP REPORT

Vision Acuity $\left\{ \begin{array}{l} 8/6 \\ \text{unaided} \\ 6/6 \end{array} \right.$

Digital IOP $\left\{ \begin{array}{l} 22 \\ 22 \end{array} \right.$

Near Vision $\left\{ \begin{array}{l} N6 \\ \text{unaided} \\ N6 \end{array} \right.$

Colour Vision $\left\{ \begin{array}{l} Normal \\ Normal \end{array} \right.$

• Fundus: normal @ study

• Ant. Segment :- normal

• Media: normal

• Pupil: normal

CHS

Patient Name : Mrs. B AKSHATHA

Age/Gender : 37 Y/F

UHID/MR No. : CBAS.0000091212

OP Visit No : CBASOPV99226

Sample Collected on :

Reported on : 13-01-2024 11:41

LRN# : RAD2207838

Specimen :

Ref Doctor : SELF

Emp/Auth/TPA ID : 327903

DEPARTMENT OF RADIOLOGY

ULTRASOUND - WHOLE ABDOMEN

Liver: appears normal in size (13.0 cm) and increased in echotexture. No focal lesion is seen. Portal vein and Common Bile Duct appear normal. No dilatation of the intrahepatic biliary radicals.

Gall bladder is well distended. No evidence of calculus. Wall thickness appears normal. No evidence of periGB collection. No evidence of focal lesion is seen.

Spleen appears normal. No focal lesion seen. Splenic vein appears normal.

Pancreas appears normal in echo-pattern. No focal/mass lesion/calcification. No evidence of peripancreatic free fluid or collection. Pancreatic duct appears normal.

Right kidney appear normal in size 9.8x1.3 cm, shape and echopattern. Cortical thickness and Cortico-medullary differentiation are maintained.

Left kidney appear normal in size 9.2x1.3 cm, shape and echopattern. Cortical thickness and Cortico-medullary differentiation are maintained.

Urinary Bladder is well distended and appears normal. No evidence of any wall thickening or abnormality. No evidence of any intrinsic or extrinsic bladder abnormality detected.

Uterus appears normal in size and measuring 8.8x5.1x6.2 cm. It shows normal shape & echo pattern. Endometrial echo-complex appears normal and measures 1.2 cm.

Both ovaries appear normal in size, shape and echotexture. Right ovary measuring 3.5x2.5 cm and left ovary measuring 2.5x2.0 cm. No evidence of any adnexal pathology noted.

- No thickened or tender bowel loops. No mass lesion. No ascites / pleural effusion.

IMPRESSION:-

GRADE I FATTY LIVER.

Suggested clinical correlation.

The sonography findings should always be considered in correlation with the clinical and other investigation finding where applicable.) It is only a professional opinion, Not valid for medico legal purpose.



Dr. V K PRNAV VENKATESH
MBBS,MD
Radiology



Patient Name : Mrs. B AKSHATHA

Age/Gender : 37 Y/F

Patient Name : Mrs. B AKSHATHA

Age/Gender : 37 Y/F

UHID/MR No. : CBAS.0000091212

OP Visit No : CBASOPV99226

Sample Collected on :

Reported on : 13-01-2024 13:28

LRN# : RAD2207838

Specimen :

Ref Doctor : SELF

Emp/Auth/TPA ID : 327903

DEPARTMENT OF RADIOLOGY

X-RAY CHEST PA

Both lungs fields appears normal and shows normal bronchovascular markings.

Bilateral hila appears normal.

Cardiac silhouette appears normal.


Both costophrenic and cardiophrenic angles are clear.

Both diaphragms are normal in position and contour.

Thoracic wall and soft tissues appear normal.

IMPRESSION:

No obvious abnormality seen in the present study.



Dr. V K PRANAV VENKATESH
MBBS,MD
Radiology