

## CERTIFICATE OF MEDICAL FITNESS

This is to certify that I have conducted the clinical examination

of Jyoti sharda on 24/06/2023

After reviewing the medical history and on clinical examination it has been found that he/she is

	Tick
<ul style="list-style-type: none"> <li>• Medically Fit</li> </ul>	<input type="checkbox"/>
<ul style="list-style-type: none"> <li>• Fit with restrictions/recommendations</li> </ul> <p>Though following restrictions have been revealed, in my opinion, these are not impediments to the job.</p> <p>1. <u>Recommend Iron rich diet.</u></p> <p>2. ....</p> <p>3. ....</p> <p>However the employee should follow the advice/medication that has been communicated to him/her.</p> <p>Review after _____</p>	✓
<ul style="list-style-type: none"> <li>• Currently Unfit. Review after _____ recommended</li> </ul>	<input type="checkbox"/>
<ul style="list-style-type: none"> <li>• Unfit</li> </ul>	<input type="checkbox"/>

Dr. Archana .v  
**Medical Officer**  
**The Apollo Clinic, (Location)**

*This certificate is not meant for medico-legal purposes*

Date : 24-06-2023  
 MR NO : CVIM.0000227192  
 Name : Mrs. Jyoti Sharda  
 Age/ Gender : 35 Y / Female

Department : GENERAL  
 Doctor :  
 Registration No :  
 Qualification :

Consultation Timing: 09:15

Height : 162	Weight : 48	BMI : 19	Waist Circum : 79
Temp : 97	Pulse : 70	Resp : 18	B.P : 90/60

General Examination / Allergies  
 History

Clinical Diagnosis & Management Plan

**HOME SAMPLE COLLECTION**  
 PH.: 7775870014  
 :020-26634331/32/34

Wa. BID  
 Sr. Calcium



**SYSTEMIC** :

- . CVS :
- . CVS :
- . RS :

NAD

No complaints.

**FREE CHECK UP**  
 - PHYSIOTHERAPY  
 - DENTAL  
 - AUDIO (HEARING)  
 - OPHTHAL (EYE)

Follow up date:

**Dr. Chinmay D. Naik**  
 MBBS., CDM.  
 (certificate course in treatment of  
 Diabetes Mellitus)  
 Reg. No. DCI/13/51948  
 Doctor Signature

**Apollo Clinic, Viman Nagar**

Nyati Millenium Premises, Cooperative Society Limited, Shop No. S1 & Stilt Floor,  
 Building "C", Viman Nagar, Pin: 411014 | Phone: (020) 2663 4331/32/34

Follow us [f/ApolloClinicIndia](#) [t/ApolloClinics](#)

BOOK YOUR APPOINTMENT TODAY!

Whatsapp Number : 970 100 3333

Toll Number : 1860 500 7788

Website : www.apolloclinic.com

EYE EXAMINATION

DATE:-

24/6/22

NAME:- NB Jyoti Sarda

AGE:- 25yr

CORPORATE:- Union Bank (Home)

	Right Eye	Left Eye
Distant vision	cf. 2 feet away 6/6	cf. 2 feet away 6/6
Near vision	N/5	N/6
Color vision	Unable to identify Normal	Unable to identify Normal
Fundus examination	Normal	Normal
Intraocular pressure	Normal	Normal
Slit lamp exam.	Normal	Normal

Both Total Corneal Opacity in Both eyes. H/O: Childhood Developmental Retardation are of Metabolic origin.

Impression - Normal Eye Check Up.

*[Signature]*



The Apollo Clinic  
DR. M. D. ALAVI  
MBBS, DO.MS.  
Consulting Eye Surg  
Reg. No.: 36319  
op.: 7709006404

(Ophthalmology)

*[Handwritten note:]* It is a total capped and working / and working to help of [unclear]

The Apollo Clinic  
DR. M. D. ALAVI  
MBBS, DO.MS.  
Consulting Eye Surgeon  
Reg. No.: 36319

*[Signature]*

Mrs Jyoti Sharda

No any ENT complaint

Ear (R) (L)  
7m wh was @

WAS wh

W and any day +

→ Stagnant System  
plus @ sof

S



227192  
35 Years

JYOTI SHARDA (V N CLINIC )  
Female

24-Jun-23 9:30:19 AM

Rate 64 Sinus rhythm  
PR 149 Baseline wander in lead(s) V5  
QRSD 75  
QT 405  
QTc 418  
normal P axis, V-rate 50-99

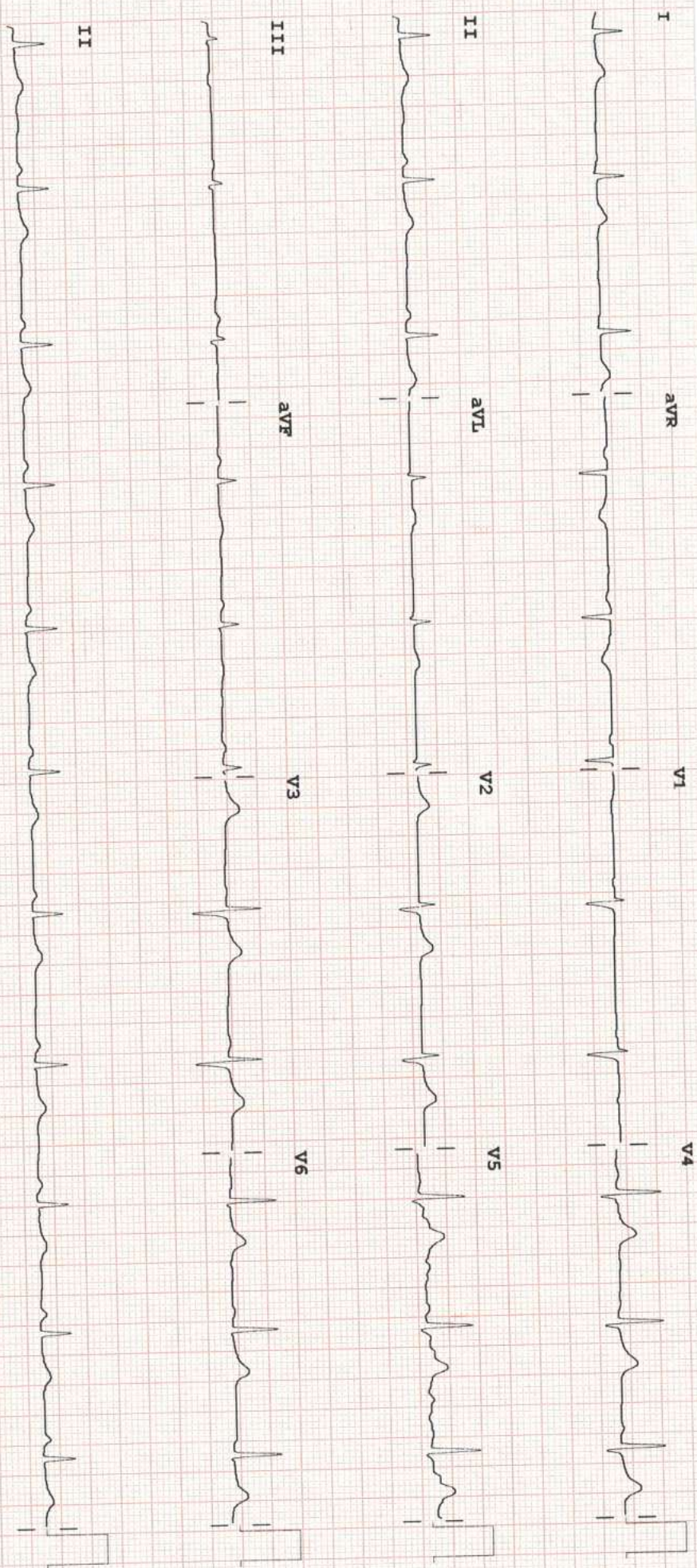
*Set to*

--AXIS--  
P 68  
QRS 37  
T 21

- NORMAL ECG -

Unconfirmed Diagnosis

12 Lead; Standard Placement



Device:

Speed: 25 mm/sec

Limb: 10 mm/mV

Chest: 10.0 mm/mV

PHILIPS

REORDER M3708A

F 50~0.50~40 Hz W

PH100B CL

P?

















Patient Name : Mrs.JYOTI SHARDA	Collected : 24/Jun/2023 09:28AM
Age/Gender : 35 Y 11 M 3 D/F	Received : 24/Jun/2023 02:04PM
UHID/MR No : CVIM.0000227192	Reported : 24/Jun/2023 03:38PM
Visit ID : CVIMOPV546769	Status : Final Report
Ref Doctor : Dr.SELF	Sponsor Name : ARCOFEMI HEALTHCARE LIMITED
Emp/Auth/TPA ID : 597544	

**DEPARTMENT OF BIOCHEMISTRY**

**ARCOFEMI - MEDIWHEEL - FULL BODY HEALTH ANNUAL PLUS CHECK - FEMALE - 2D ECHO - PAN INDIA - FY2324**

Test Name	Result	Unit	Bio. Ref. Range	Method
-----------	--------	------	-----------------	--------

**LIPID PROFILE , SERUM**

TOTAL CHOLESTEROL	148	mg/dL	<200	CHO-POD
TRIGLYCERIDES	50	mg/dL	<150	GPO-POD
HDL CHOLESTEROL	<b>62</b>	mg/dL	40-60	Enzymatic Immunoinhibition
NON-HDL CHOLESTEROL	87	mg/dL	<130	Calculated
LDL CHOLESTEROL	76.69	mg/dL	<100	Calculated
VLDL CHOLESTEROL	9.98	mg/dL	<30	Calculated
CHOL / HDL RATIO	2.41		0-4.97	Calculated

**Comment:**

Reference Interval as per National Cholesterol Education Program (NCEP) Adult Treatment Panel III Report.

	Desirable	Borderline High	High	Very High
TOTAL CHOLESTEROL	< 200	200 - 239	≥ 240	
TRIGLYCERIDES	<150	150 - 199	200 - 499	≥ 500
LDL	Optimal < 100 Near Optimal 100-129	130 - 159	160 - 189	≥ 190
HDL	≥ 60			
NON-HDL CHOLESTEROL	Optimal <130; Above Optimal 130-159	160-189	190-219	>220

Measurements in the same patient can show physiological and analytical variations.

NCEP ATP III identifies non-HDL cholesterol as a secondary target of therapy in persons with high triglycerides.





















Patient Name : Mrs. Jyoti Sharda Age : 35 Y F  
UHID : CVIM.0000227192 OP Visit No : CVIMOPV546769  
Reported on : 24-06-2023 12:57 Printed on : 26-06-2023 08:52  
Adm/Consult Doctor : Ref Doctor : SELF

## DEPARTMENT OF RADIOLOGY

### ULTRASOUND - WHOLE ABDOMEN

**Liver** appears normal in size and echotexture. No focal lesion is seen. PV and CBD normal. No dilatation of the intrahepatic biliary radicals.

**Gall bladder** is well distended. No evidence of calculus. Wall thickness appears normal. No evidence of periGB collection. No evidence of focal lesion is seen.

**Spleen** appears normal. No focal lesion seen. Splenic vein appears normal.

**Pancreas** appears normal in echopattern. No focal/mass lesion/calcification. No evidence of peripancreatic free fluid or collection. Pancreatic duct appears normal.

**Both the kidneys** appear normal in size, shape and echopattern. Cortical thickness and CM differentiation are maintained. No calculus / hydronephrosis seen on either side.

**Urinary Bladder** is well distended and appears normal. No evidence of any wall thickening or abnormality. No evidence of any intrinsic or extrinsic bladder abnormality detected.

**Uterus** appears retroverted and marginally bulky in size. It shows normal shape & echo pattern. Endometrial echo-complex appears normal and shows a IUCD in situ.

**Both ovaries** appear normal in size, shape and echotexture.

No evidence of any adnexal pathology noted.

**Bowel loops and Retroperitoneum** appear normal. Aorta and IVC appear normal. No abnormal lymphadenopathy noted.

### **IMPRESSION:-**

**No significant abnormality detected.**

### **Apollo Health and Lifestyle Limited**

(CIN - U85110TG2000PLC115819)

Regd. Office: 1-10-60/62, Ashoka Raghupathi Chambers, 5th Floor, Beglmpet, Hyderabad, Telangana - 500 016.  
Ph No: 040-4904 7777, Fax No: 4904 7744 | Email ID: enquiry@apollohl.com | www.apollohl.com

APOLLO CLINICS NETWORK MAHARASHTRA

Pune (Aundh | Kharadi | Nigdi Pradhikaran | Viman Nagar | Wanowrie)

Online appointments: www.apolloclinic.com

TO BOOK AN APPOINTMENT

 **1860 500 7788**

Patient Name	: Mrs. Jyoti Sharda	Age.	: 35 Y F
UHID	: CVIM.0000227192	OP Visit No	: CVIMOPV546769
Reported on	: 24-06-2023 12:57	Printed on	: 26-06-2023 08:52
Adm/Consult Doctor	:	Ref Doctor	: SELF

(The sonography findings should always be considered in correlation with the clinical and other investigation finding where applicable.) It is only a professional opinion, Not valid for medico legal purpose.

Printed on:24-06-2023 12:57

---End of the Report---

*Preeti*

**Dr. PREETI P KATHE**  
DMRE, MD, DNB  
Radiology

**Apollo Health and Lifestyle Limited**

(CIN - U85110TG2000PLC115819)

Regd. Office: 1-10-60/62, Ashoka Raghupathi Chambers, 5th Floor, Begumpet, Hyderabad, Telangana - 500 016  
Ph No: 040-4904 7777, Fax No: 4904 7744 | Email ID: enquiry@apollohl.com | www.apollohl.com

APOLLO CLINICS NETWORK MAHARASHTRA

Pune (Aundh | Kharadi | Nigdi Pradhikaran | Viman Nagar | Wanowrie)

Online appointments: www.apolloclinic.com

TO BOOK AN APPOINTMENT



**1860 500 7788**

Patient Name	: Mrs. Jyoti Sharda	Age	: 35 Y F
UHID	: CVIM.0000227192	OP Visit No	: CVIMOPV546769
Reported on	: 24-06-2023 14:51	Printed on	: 26-06-2023 08:52
Adm/Consult Doctor	:	Ref Doctor	: SELF

**DEPARTMENT OF RADIOLOGY**

**X-RAY CHEST PA**

Both lung fields and hila are normal .

No obvious active pleuro-parenchymal lesion seen .

Both costophrenic and cardiophrenic angles are clear .

Both diaphragms are normal in position and contour .

Thoracic wall and soft tissues appear normal.

**CONCLUSION :**

No obvious abnormality seen

Printed on:24-06-2023 14:51

---End of the Report---

*Preeti*

**Dr. PREETI P KATHE**  
DMRE, MD, DNB  
Radiology

**Apollo Health and Lifestyle Limited**

(CIN - U85110TG2000PLC115819)

Regd. Office: 1-10-60/62, Ashoka Raghupathi Chambers, 5th Floor, Begu lmpet, Hyderabad, Telangana - 500 016.

Ph No: 040-4904 7777, Fax No: 4904 7744 | Email ID: enquiry@apollohl.com | www.apollohl.com

**APOLLO CLINICS NETWORK MAHARASHTRA**

**Pune** (Aundh | Kharadi | Nigdi Pradhikaran | Viman Nagar | Wanowrie)

Online appointments: www.apolloclinic.com

TO BOOK AN APPOINTMENT

 **1860 500 7788**



# NO SAMPLE GIVEN

TO,

APOLLO CLINIC

VIMAN NAGAR

Dear sir / madam,

I am Mrs. Jyoti sharda. working at

Company Name Amcofemi medical female.


Have not given the 2 Deco, consultation. Sample do not wish given it.

I AGREE \_\_\_\_\_

UHID =

SIGN -

17

<b>Name</b> : Mrs. Jyoti Sharda  <b>Address</b> : pune  <b>Plan</b> : ARCOFEMI MEDIWHEEL FEMALE AHC CREDIT PAN INDIA OP AGREEMENT	<b>Age</b> : 35 Y  <b>Sex</b> : F	<b>UHID</b> :CVIM.0000227192  <b>OP Number</b> :CVIMOPV546769 <b>Bill No</b> :CVIM-OCR-58119 <b>Date</b> : 24.06.2023 09:15
-----------------------------------------------------------------------------------------------------------------------------------------------	-----------------------------------------	---------------------------------------------------------------------------------------------------------------------------------------------------------------------------------------------------------------------------

Sno	Service Type/ServiceName	Department
1	ARCOFEMI - MEDIWHEEL - FULL BODY HEALTH ANNUAL PLUS CHECK - FEMALE - 2D ECHO - PAN INDIA - FY2324	
1	URINE GLUCOSE(FASTING)	
2	GAMMA GLUTAMYL TRANSFERASE (GGT)	
3	HbA1c, GLYCATED HEMOGLOBIN	
4	2 D ECHO	
5	LIVER FUNCTION TEST (LFT)	
6	X-RAY CHEST PA	
7	GLUCOSE, FASTING	
8	HEMOGRAM + PERIPHERAL SMEAR	
9	ENT CONSULTATION	
10	FITNESS BY GENERAL PHYSICIAN	
11	GYNAECOLOGY CONSULTATION	
12	DIET CONSULTATION	
13	COMPLETE URINE EXAMINATION	
14	URINE GLUCOSE(POST PRANDIAL)	
15	PERIPHERAL SMEAR	
16	ECG	
17	BLOOD GROUP ABO AND RH FACTOR	
18	LIPID PROFILE	
19	BODY MASS INDEX (BMI)	
20	LBC PAP TEST- PAPSURE <i>Not done</i>	
21	OPHTHAL BY GENERAL PHYSICIAN	
22	RENAL PROFILE/RENAL FUNCTION TEST (RFT/KFT)	
23	ULTRASOUND - WHOLE ABDOMEN	
24	THYROID PROFILE (TOTAL T3, TOTAL T4, TSH)	
25	DENTAL CONSULTATION	
26	GLUCOSE, POST PRANDIAL (PP), 2 HOURS (POST MEAL) <i>— 2hrs</i>	