


Name : Mrs. KRITIKA KHANAGWAL	Age : 34 Y	UHID :SCHI.0000023921
Address : MALVIYA NAGAR	Sex : F	
Plan : ARCOFEMI MEDIWHEEL FEMALE AHC CREDIT PAN INDIA OP AGREEMENT		OP Number :SCHIOPV36556
		Bill No :SCHI-OCR-12352
		Date : 14.09.2024 10:42

Sno	Service Type/ServiceName	Department
1	ARCOFEMI - MEDIWHEEL - FULL BODY HEALTH ANNUAL PLUS CHECK - FEMALE - 2D ECHO - PAN INDIA - FY2324	
1	GAMMA GLUTAMYL TRANSFERASE (GGT) ✓	
2	D ECHO <i>pending</i>	
3	LIVER FUNCTION TEST (LFT) ✓	
4	GLUCOSE, FASTING ✓	
5	HEMOGRAM + PERIPHERAL SMEAR ✓	
6	GYNAECOLOGY CONSULTATION <i>pending</i>	
7	DIET CONSULTATION <i>pending</i>	
8	COMPLETE URINE EXAMINATION ✓	
9	URINE GLUCOSE(POST PRANDIAL)	
10	PERIPHERAL SMEAR ✓	
11	EKG ✓	
12	LBC PAP TEST- PAPSURE <i>pending</i>	
13	RENAL PROFILE/RENAL FUNCTION TEST (RFT/KFT) ✓	
14	DENTAL CONSULTATION ✓	
15	GLUCOSE, POST PRANDIAL (PP), 2 HOURS (POST MEAL) ✓	
16	URINE GLUCOSE(FASTING) ✓	
17	HbA1c, GLYCATED HEMOGLOBIN ✓	
18	X-RAY CHEST PA <i>pending</i>	
19	ENT CONSULTATION <i>pending</i>	
20	FITNESS BY GENERAL PHYSICIAN	
21	BLOOD GROUP ABO AND RH FACTOR ✓	
22	LIPID PROFILE ✓	
23	BODY MASS INDEX (BMI)	
24	OPHTHAL BY GENERAL PHYSICIAN ✓	
25	ULTRASOUND - WHOLE ABDOMEN ✓	
26	THYROID PROFILE (TOTAL T3, TOTAL T4, TSH) ✓	

(2)

Height: 152 cm
 Weight: 70.3kg
 B.P: 100/80 mmHg
 Pulse: 24/min
 SF02: 99%

From: Mediwheel <wellness@mediwheel.in>
Sent: 02 September 2024 17:36
To: phc.klc@apollospectra.com
Cc: customercare@mediwheel.in
Subject: Health Check up Booking Request(22S32519)



011-41195959

Dear **Apollo Spectra - Nehru Enclave**

We have received a booking request with the following details. Provide your confirmation by clicking on the Yes button.

You confirm this booking? Yes No

Name : MR. SINGH KUNAL

Contact Details : 9004864565

Hospital Package Name : Mediwheel Full Body Health Annual Plus Check

Location : R-2, Nehru Enclave, Near Nehru Place Flyover, New Delhi - 110019

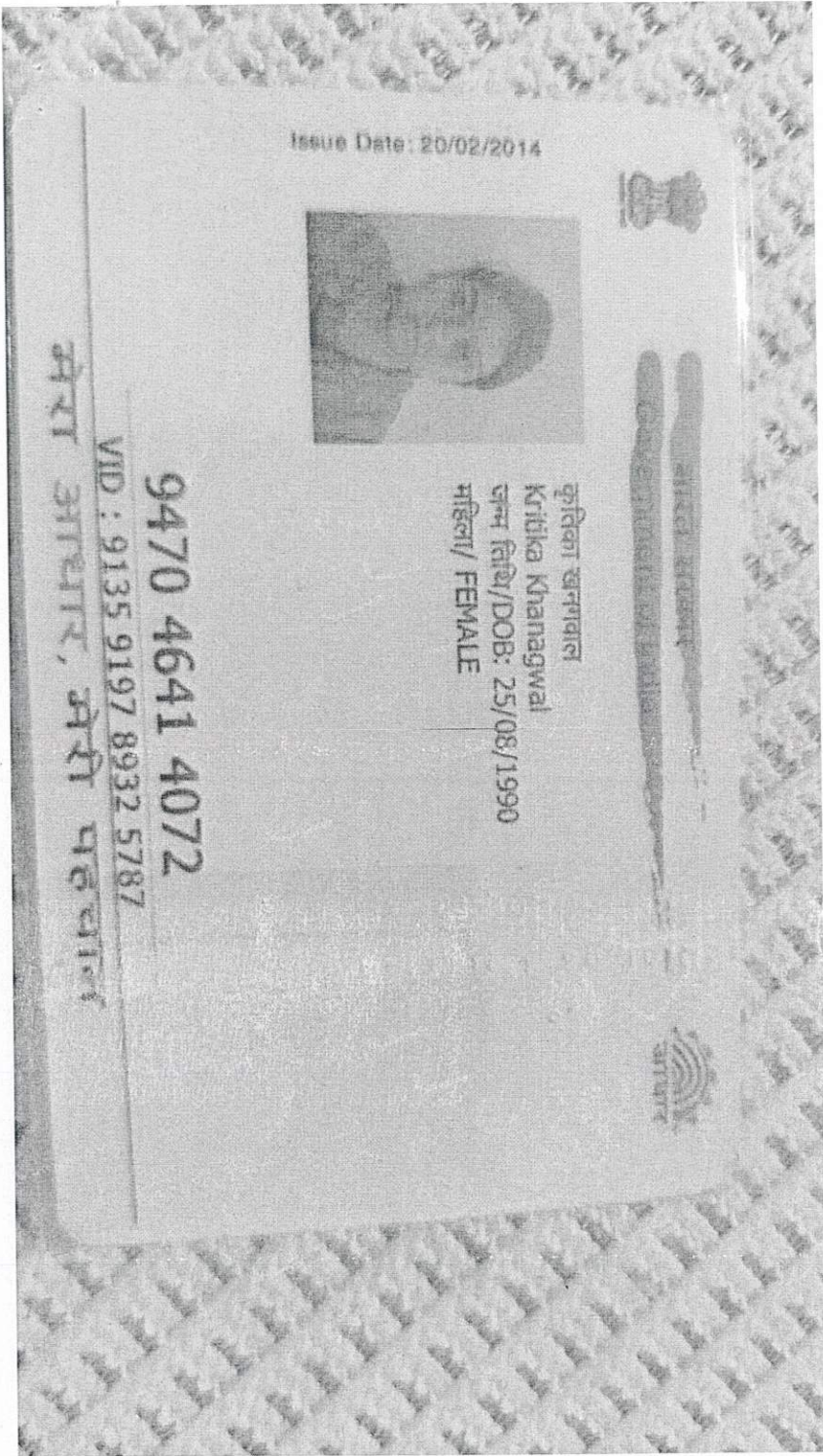
Appointment Date : 14-09-2024

Member Information

Booked Member Name	Age	Gender
Kritika khangwal	34 year	Female

Tests included in this Package

- CBC
- HbA1c
- Lipid Profile
- Kidney Profile
- Liver Profile
- Blood Glucose (Post Prandial)
- Thyroid Profile
- Pap Smear
- Urine Sugar Fasting
- ~~Urine Sugar PP~~
- ESR
- Blood Glucose (Fasting)
- TMT OR 2D ECHO (Any 1) Chosen By Candidate
- Chest X-ray





Apollo Clinic

CONSENT FORM

Patient Name: Kritika Age: 34

UHID Number: SCHL:0000023921 Company Name: ARCOFEMI

I Mr/Mrs/Ms Kritika Employee of ARCOFEMI

(Company) Want to inform you that I am not interested in getting Echo/Gynae/UBC
Tests done which is a part of my routine health check package. X-Ray/ENT Consultation

And I claim the above statement in my full consciousness.

Patient Signature: [Signature] Date: 14/09/24

Name :	KRITIKA KHANAGWAL	Age/Sex:	34	Yrs./F
UHID :	23921			
Ref By :	APOLLO SPECTRA	Date:-	14.09.2024	

ULTRASOUND WHOLE ABDOMEN

Excessive bowel gases are seen

Liver: Appears normal in size and shows increased parenchymal echogenicity which is most likely due to fatty changes. Intrahepatic biliary radicles are not dilated. CBD and portal vein are normal in calibre.

Gall Bladder: normally distended with clear lumen and normal wall thickness. No calculus or sludge is seen.

Pancreas and Spleen: Appears normal in size and echotexture.

Both Kidneys: are normal in size, shape, and echopattern. The parenchymal thickness is normal and cortico-medullary differentiation is well maintained. Pelvicalyceal systems are not dilated. No calculus or mass lesion is seen. Ureter is not dilated.

Urinary Bladder: is moderately distended and shows no obvious calculus or sediments. Bladder wall thickness is normal.

Uterus is antverted and bulky in size. It measures 9 x 4.8 cm. Outline is smooth. Myometrium is normal. Endometrial echoes are normal and measures 9.3 mm

Both ovaries are normal in size ,shape and echotexture.

Right ovary: 2.3 x 2.3 cm

Left ovary: 2.5 x 2 cm

No obvious adnexal mass is seen. No free fluid seen.

IMPRESSION: FATTY CHANGES IN LIVER GRADE 1

Please correlate clinically and with lab. Investigations.


DR. DEEPIKA AGARWAL
CONSULTANT RADIOLOGIST

Dr. DEEPIKA AGARWAL
Consultant Radiologist
DMC No. 56777
Apollo Speciality Hospitals (P) Ltd.
A-2, Chirag Enclave, Greater Kailash-1
New Delhi-110048

Apollo Spectra Hospitals: Plot No. A-2, Chirag Enclave, Greater Kailash -1, New Delhi -110048
Ph: 011-40465555, 9910995018 | www.apollospectra.com

Apollo Specialty Hospital Pvt. Ltd.

CIN - U85100TG2009PTC099414

Regd. Office: 7-1-617/A, 615 & 616, Imperial Towers, 7th Floor, Ameerpet, Hyderabad, Telangana - 500038
Ph No: 040-4904 7777 | www.apollohl.com

ID: 23921
Kritika Khandelwal
Female 34Years
Req. No. :

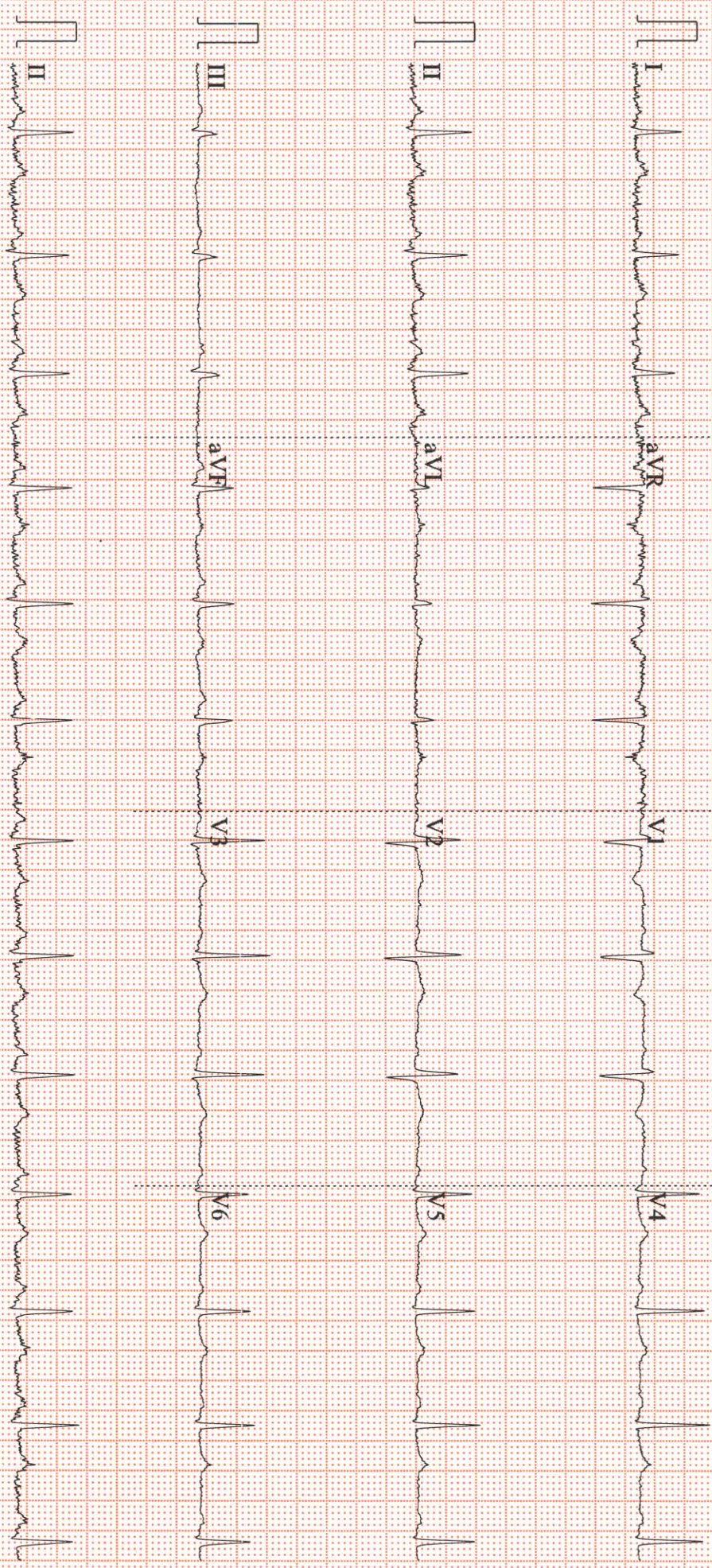
14-09-2024 15:05:29

HR : 76 bpm
P : 99 ms
PR : 156 ms
QRS : 84 ms
QT/QTcBz : 385/435 ms
P/QRS/T : 55/42/33 °
RV5/SV1 : 0.983/0.652 mV

Diagnosis Information:
Sinus Rhythm
Normal ECG

MNL

Report Confirmed by:



Mrs. Kritika Khanagwal

14/9/24

34/F

Eye checkup

no H/O myopia

no H/O systemic disease

V.A. < 6/6
6/6

MET < 14 Jumps
14 Jumps

colours < normal
B/A

BCVA < No Acceptance 6/6 B/A - MC

slit lamp exam

A/S normal B/A

pupil reaction Normal B/A

Fundus < wnl B/A

Adv

- add Refresh TDS B/A x 1 month

Danakhin

~~30/9~~

14/9/24

Dr. Prachi Sharma

BDS, MDS - Prosthodontics and Crown & Bridge
DDC No. A-14151

For Appointment : +91 11 40465555
Mob.: +91 9910995018

14/09/2024

Mrs. Kulika Khanna
34y / Female

U/C: Regular Dental Check-up

M/H: - N.R.H.

PDH: - Extraction wt 28 many years back

O/E: - Calculus +

Stains +

Spacing +

Cross Bite on ~~left~~ Right side

Deep Bite

Protrusion +

^

Assesed! -

Scaling

Occlusal Scan for Alignment

