



PANACEA HOSPITAL

B 36/44 F.K KABIR NAGAR, DURGAKUND
TOLLFREE NO-18001233070. Whatsapp No - 8795832852
www.piire.org
panaceaquery@gmail.com|panaceahospitalit@gmail.com



OP Slip

Print Date : 10-Mar-2024 09:41AM



UHID No	:- UD-23240006730	OP No	:- OP-23240020676	OP Date	:- 10 Mar 2024 9:41AM
Patient Name	:- Mrs NIRMALA KUMARI	Age/Sex	:- 30 Y/Female	Mobile No	:- 9204373372
Husband	:- DEBASHISH NANDAN	Department	:- GENERAL MEDICINE		
Pay Type	:- Cash	Consultant	:- Dr ASHUTOSH MISHRA (MBBS MD IMS BHU,MD)		
Token No	:- NOR. - 2	Paid/Bal	:- 0.00 /630.00		
Patient Type	:- Normal				
Address	:- WARD NO 34 BAWAN BIGHA CASTAIR TOWN DEOGHAR 814112,jharkhand				

110/70
BP :-
height :- 159
Weight (kg) :- 59.6
BMI :-
NC 30
WC 86
CH 89
SPR 98
PR 104
PPRR ~~200~~
560

Rx
 Δ prediabets.
 R^b f0s sq. < 0
 T₀₀ Pund one low (SRA min)
 Ta punt 500g 45 →

WSPAC
BS < F
PP

DR. ASHUTOSH MISHRA
MBBS, MD (GENERAL MEDICINE)
MCI, Reg. No. 45695

Printed By : Ms. Anjali Prajapati
Created By : Ms. Anjali Prajapati




PANACEA HOSPITAL

B 36/44 F.K KABIR NAGAR, DURGAKUND
TOLLFREE NO-18001233070. Whatsapp No - 8795832852
www.piire.org
panaceaquery@gmail.com | panceahospitalit@gmail.com



OP Slip

Print Date : 10-Mar-2024 12:15PM



UHID No :- UD-23240006730	OP No :- OP-23240020689	OP Date :- 10 Mar 2024 12:12PM
Patient Name :- Mrs NIRMALA KUMARI	Age/Sex :- 30 Y/Female	Mobile No :- 9204373372
Husband :- DEBASHISH NANDAN	Department :- OPHTHALMOLOGY	
Pay Type :- Cr	Consultant :- Dr SANTOSH VERMA (MBBS,MS)	
Token No :- NOR. - 1	Paid :- 0.00	
Patient Type :- Normal		
Address :- WARD NO 34 BAWAN BIGHA CASTAIR TOWN DEOGHAR 814112, jharkhand		

BP :-
height :-
Weight (kg) :-
BMI :-

Rx

VA { 6/6 ✕
 6/6 ✕

Near { NG
 Nb.

BE - Fundus :- WNL

d. Locally BLE

1. G. Lubstone ultra - QSD
0700

Printed By : Mr Nitin Kumar Yadav

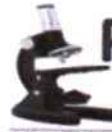Created By : Mr Nitin Kumar Yadav

Dr. SANTOSH VERMA
MBBS, MS (Ophthalmologist)
MCI Reg. No. 3934327

Facilities:

All clinical Biomedical & Hematology Investigations including Bone Marrow Examination
VPT, Podiascan & Complete Foot Care (First Time in Purvanchal)
All Hormonal Investigation by Chemiluminescent Method
Visceral Fat by (AB-140) Ambulatory BP Monitoring
CGMS & Insulin Pump Available
PFT, 2D-ECHO (Color Doppler), Holter, TMT, Cardiac-3 available
VIA, VILI, Colposcopy available
Special Endocrinological Investigation Protocols.

ISO 9001:2008 Certified
Mobile: 9389994334, 9554572190, 9453837595



Panacea Pathology

Clinical Reference Lab

Persistence, Preparedness and Precision
EQAS (CMC Vellore Attached) & IQAS System
पूर्वांचल की सर्वोत्तम गुणवत्ता वाली पैथोलॉजी

UHID No :- UD-23240006730 **Booking No/Date** :- 47 / 10-Mar-2024 12:31 PM
Patient Name :- Mrs NIRMALA KUMARI **Age/Sex** :- 30 Y/F
Husband :- DEBASHISH NANDAN **OP No** :- OP-23240020676
Address :- WARD NO 34 BAWAN BIGHA CASTAIR TOWN DEOGHAR 814112, Jharkhand **Mobile No** :- 9204373372
Consultant :- Dr ASHUTOSH MISHRA (MBBS MD IMS BHU)

Investigations	Observations	Biological Ref. Interval	Unit
HAEMATOLOGY			
CBC			
HAEMOGLOBIN <small>DefaultMethod / test Machine</small>	12.9	12.50 - 15.00	gm/dl
TLC <small>Methology / Carm</small>	6,400	4000.00 - 11000.00	Cells/cumm.
DLC DIFFERENTIAL LEUCOCYTE COUNT			
NEUTROPHILS	53	40.00 - 75.00	%
LYMPHOCYTES	41	20.00 - 45.00	%
EOSINOPHILS	02	1.00 - 6.00	%
MONOCYTES	04	2.00 - 10.00	%
BASOPHILS	00	<1-2	%
PLATELET COUNT	2.08	1.50 - 4.10	lacs /cumm
PCV	39.8	33.00 - 42.00	%
RBC <small>Methology / Carm</small>	4.48	3.50 - 4.50	million/cumm
MCV(MEAN CELL VOLUME)	89.0	83.00 - 101.00	fl
MCH(MEAN CELL HAEMOGLOBIN)	28.9	27.00 - 32.00	pg
MCHC	32.5	31.50 - 35.00	gm%
RDW-CV	13.3	11.00 - 16.00	%
RDW-SD	48.2	37.00 - 57.00	fl

Consulting Pathologist

DR. UMESH KUMAR
MBBS, MD (PATHOLOGIST)
M.D. Pathology
MCI Reg. No. 4411

Lab Technician

Timing : 24/7 hrs

This Report is not valid for medico legal purpose

Note: These tests have technical limitations. Clinico-pathological interpretation is necessary. In case of any disparity test may be repeated immediately.

Address : 36/44 FK Kabir Nagar, Durgakund, Varanasi – 221005

Email: dramishra@gmail.com, drpallaviojha@gmail.com Website: panaceahospital.org

Facilities:

All clinical Biomedical & Hematology Investigations including Bone Marrow Examination
 VPT, Podiascan & Complete Foot Care (First Time in Purvanchal)
 All Hormonal Investigation by Chemiluminescent Method
 Visceral Fat by (AB-140) Ambulatory BP Monitoring
 CGMS & Insulin Pump Available
 PFT, 2D-ECHO (Color Doppler), Holter, TMT, Cardiac-3 available
 VIA, VILI, Colposcopy available
 Special Endocrinological Investigation Protocols.

ISO 9001:2008 Certified
 Mobile: 9389994334, 9554572190, 9453837595



Panacea Pathology

Clinical Reference Lab

Persistence, Preparedness and Precision
 EQAS (CMC Vellore Attached) & IQAS System
 पूर्वांचल की सर्वोत्तम गुणवत्ता वाली पैथोलॉजी

UHID No	:- UD-23240006730	Booking No/Date	:- 47 / 10-Mar-2024 12:31 PM
Patient Name	:- Mrs NIRMALA KUMARI	Age/Sex	:- 30 Y/F
Husband	:- DEBASHISH NANDAN	OP No	:- OP-23240020676
Address	:- WARD NO 34 BAWAN BIGHA CASTAIR TOWN DEOGHAR 814112, jharkhand	Mobile No	:- 9204373372
Consultant	:- Dr ASHUTOSH MISHRA (MBBS MD IMS BHU)		

Investigations	Observations	Biological Ref. Interval	Unit
----------------	--------------	--------------------------	------

URINE EXAMINATION

URINE ROUTINE EXAMINATION

PHYSICAL EXAMINATION

QUANTITY	25		ml
COLOR <i>Methology</i>	STRAW	CLEAR YELLOW	
APPEARANCE <i>DefaultMethod</i>	CLEAR	CLEAR	

CHEMICAL EXAMINATION

SPECIFIC GRAVITY	1.015	1.01 - 1.03	
PH	5.5	4.60 - 8.00	
GLUCOSE	NIL	60.00 - 100.00	mg/dl
PROTEIN-	NIL		

MICROSCOPIC EXAMINATION

PUS CELLS	01-02	2.00 - 3.00	/HPF
RBCS (RED BLOOD CELLS)	NIL	3.50 - 4.50	/HPF
EPITHELIAL CELLS	NIL		/HPF
CASTS	ABSENT	ABSENT	
CRYSTALS	ABSENT	ABSENT	

Consulting Pathologist

DR. UMESH KUMAR
 MBBS, MD (PATHOLOGIST)
 M.D. Pathology
 MCT Reg. No. 41413

Lab Technician

Timing : 24/7 hrs

This Report is not valid for medico legal purpose

Note: These tests have technical limitations. Clinico-pathological interpretation is necessary. In case of any disparity test may be repeated immediately.

Address : 36/44 FK Kabir Nagar, Durgakund, Varanasi – 221005

Email: dramishra@gmail.com, drpallaviojha@gmail.com Website: panaceahospital.org

Facilities:

All clinical Biomedical & Hematology Investigations including Bone Marrow Examination
 VPT, Podiascan & Complete Foot Care (First Time in Purvanchal)
 All Hormonal Investigation by Chemiluminescent Method
 Visceral Fat by (AB-140) Ambulatory BP Monitoring
 CGMS & Insulin Pump Available
 PFT, 2D-ECHO (Color Doppler), Holter, TMT, Cardiac-3 available
 VIA, VILI, Colposcopy available
 Special Endocrinological Investigation Protocols.

ISO 9001:2008 Certified
 Mobile: 9389994334, 9554572190, 9453837595



Panacea Pathology

Clinical Reference Lab

Persistence, Preparedness and Precision
 EQAS (CMC Vellore Attached) & IQAS System
 पूर्वांचल की सर्वोत्तम गुणवत्ता वाली पैथोलॉजी

UHID No :- UD-23240006730 **Booking No/Date** :- 47 / 10-Mar-2024 12:31 PM
Patient Name :- Mrs NIRMALA KUMARI **Age/Sex** :- 30 Y/F
Husband :- DEBASHISH NANDAN **OP No** :- OP-23240020676
Address :- WARD NO 34 BAWAN BIGHA CASTAIR TOWN DEOGHAR 814112, jharkhand **Mobile No** :- 9204373372
Consultant :- Dr ASHUTOSH MISHRA (MBBS MD IMS BHU)

Investigations	Observations	Biological Ref. Interval	Unit
<u>HAEMATOLOGY</u>			
ESR	18.0	0.00 - 20.00	mm at 1 hr
BLOOD GROUP ABO & RH FACTOR			
BLOOD GROUP	"O"		
RH FACTOR	POSITIVE		
HBA1C -(BY GOLD STANDARD METHOD :HPLC)	6.0	Normal: 4.0 - 5.4 Prediabetic : 5.5 -6.3 Diabetes mellitus := 6.4	%
<u>BIOCHEMISTRY</u>			
LIPID PROFILE			
TOTAL CHOLESTROL	191.0	Desirable : - < 200 mg/dL Borderline: - 200 - 239 mg/dL High : - > 240mg/dL	mg/dl
TRIGLYCERIDES	146.0	35.00 - 160.00	mg/dl
HDL CHOLESTROL	44.0	42.00 - 88.00	mg/dl
LDL CHOLESTROL	77.8	<130	mg/dl
VLDL	29.20	<40	mg/dl
CHOLESTROL/ HDL RATIO	3.43	<3.0 LOW RISK, 3.0-5.0 AVG RISK, >5.0 HIGH RISK	ratio
LDL/HDL RATIO	1.77	<3	ratio

RFT (RENAL FUNCTION TESTS)

Umesh Kumar
 Consulting Pathologist

Dr. Umesh Kumar
 M.D., Pathology

Lab Technician

Timing : 24/7 hrs

This Report is not valid for medico legal purpose

Note: These tests have technical limitations. Clinico-pathological interpretation is necessary. In case of any disparity test may be repeated immediately.

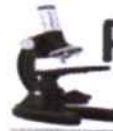Address : 36/44 FK Kabir Nagar, Durgakund, Varanasi - 221005

Email: dramishra@gmail.com, drpallaviojha@gmail.com Website: panaceahospital.org

Facilities:

All clinical Biomedical & Hematology Investigations including Bone Marrow Examination
 VPT, Podiascan & Complete Foot Care (First Time in Purvanchal)
 All Hormonal Investigation by Chemiluminescent Method
 Visceral Fat by (AB-140) Ambulatory BP Monitoring
 CGMS & Insulin Pump Available
 PFT, 2D-ECHO (Color Doppler), Holter, TMT, Cardiac-3 available
 VIA, VILI, Colposcopy available
 Special Endocrinological Investigation Protocols.

ISO 9001:2008 Certified
 Mobile: 9389994334, 9554572190, 9453837595



Panacea Pathology

Clinical Reference Lab

Persistence, Preparedness and Precision
 EQAS (CMC Vellore Attached) & IQAS System
 पूर्वांचल की सर्वोत्तम गुणवत्ता वाली पैथोलॉजी

UHID No :- UD-23240006730 **Booking No/Date** :- 47 / 10-Mar-2024 12:31 PM
Patient Name :- Mrs NIRMALA KUMARI **Age/Sex** :- 30 Y/F
Husband :- DEBASHISH NANDAN **OP No** :- OP-23240020676
Address :- WARD NO 34 BAWAN BIGHA CASTAIR TOWN DEOGHAR 814112, jharkhand **Mobile No** :- 9204373372
Consultant :- Dr ASHUTOSH MISHRA (MBBS MD IMS BHU)

Investigations	Observations	Biological Ref. Interval	Unit
SERUM CREATININE	0.71	0.60 - 1.60	mg/dl
URIC ACID	3.76	2.50 - 6.80	mg/dl
LFT (LIVER FUNCTION TESTS)			
TOTAL BILIRUBIN	0.65	0.00 - 1.20	mg/dl
DIRECT BILIRUBIN	0.21	0.00 - 0.30	
INDIRECT BILIRUBIN	0.44	0.20 - 0.70	mg/dl
SGOT	24.0	2.00 - 31.00	U/L
SGPT	30.0	10.00 - 45.00	U/L
ALKALINE PHOSPHATASE	69.0	25.00 - 140.00	U/L
TOTAL PROTIENS	7.24	6.60 - 8.70	g/dl
ALBUMIN	4.10	3.50 - 5.20	gm%
GLOBULIN	3.14	1.50 - 3.60	gms/dl
A/G RATIO	1.30	2:1	RATIO
YGGT	21.0	10.00 - 50.00	U/L
BUN	9.2	7.00 - 21.00	mg/dl

IMMUNOLOGY

THYROID PROFILE (T3,T4,TSH)

Consulting Pathologist

DR. UMESH KUMAR
 MBBS, MD (PATHOLOGIST)
 MCI Reg. No. 41413

Lab Technician

Timing : 24/7 hrs

This Report is not valid for medico legal purpose

Note: These tests have technical limitations. Clinico-pathological interpretation is necessary. In case of any disparity test may be repeated immediately.

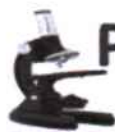Address : 36/44 FK Kabir Nagar, Durgakund, Varanasi – 221005

Email: dramishra@gmail.com, drpallaviojha@gmail.com Website: panaceahospital.org

Facilities:

All clinical Biomedical & Hematology Investigations including Bone Marrow Examination
 VPT, Podiascan & Complete Foot Care (First Time in Purvanchal)
 All Hormonal Investigation by Chemiluminescent Method
 Visceral Fat by (AB-140) Ambulatory BP Monitoring
 CGMS & Insulin Pump Available
 PFT, 2D-ECHO (Color Doppler), Holter, TMT, Cardiac-3 available
 VIA, VILI, Colposcopy available
 Special Endocrinological Investigation Protocols.

ISO 9001:2008 Certified
 Mobile: 9389994334, 9554572190, 9453837595



Panacea Pathology

Clinical Reference Lab

Persistence, Preparedness and Precision
 EQAS (CMC Vellore Attached) & IQAS System
 पूर्वांचल की सर्वोत्तम गुणवत्ता वाली पैथोलॉजी

UHID No :- UD-23240006730 **Booking No/Date** :- 47 / 10-Mar-2024 12:31 PM
Patient Name :- Mrs NIRMALA KUMARI **Age/Sex** :- 30 Y/F
Husband :- DEBASHISH NANDAN **OP No** :- OP-23240020676
Address :- WARD NO 34 BAWAN BIGHA CASTAIR TOWN DEOGHAR 814112, jharkhand **Mobile No** :- 9204373372
Consultant :- Dr ASHUTOSH MISHRA (MBBS MD IMS BHU)

Investigations	Observations	Biological Ref. Interval	Unit
T3	1.02	0.60 - 1.81	ng/ml
T4	7.3	4.50 - 10.90	ug/dl
TSH	2.51	0.39 - 6.10	uIU/mL

BIOCHEMISTRY

BLOOD SUGAR FASTING

GLUCOSE	✓ 109.0	60.00 - 100.00	mg/dl
PRE-DIABETICS(IMPAIRED FASTING TOLER)	-	100.00 - 125.00	mg/dl
DIABETICS	-	upto 126	mg/dl
TARGET IN DM	-	80.00 - 130.00	mg/dl

BIOCHEMISTRY

PPBS(POST PRANDIAL BLOOD SUGAR)

POST PRANDIAL BLOOD GLUCOSE(2 HR AFTER MEAL)	✓ 146.0	110.00 - 150	mg/dl
IGT(2 HR 75GM GLUCOSE)	-	140.00 - 199.00	mg/dl
DIABETES	-	upto200	mg/dl
TARGET IN DM	-	80.00 - 130.00	mg/dl

PARASITOLOGY

STOOL ROUTINE

Consulting Pathologist

Dr. Umesh Kumar
 DR. UMESH KUMAR
 MBBS, MD (PATHOLOGIST)
 MCI Reg. No. 41413

Lab Technician

Timing : 24/7 hrs

This Report is not valid for medico legal purpose

Note: These tests have technical limitations. Clinico-pathological interpretation is necessary. In case of any disparity test may be repeated immediately.

Address : 36/44 FK Kabir Nagar, Durgakund, Varanasi – 221005

Email: dramishra@gmail.com, drpallaviojha@gmail.com Website: panaceahospital.org

Facilities:

All clinical Biomedical & Hematology Investigations
including Bone Marrow Examination
VPT, Podiascan & Complete Foot Care (First Time in Purvanchal)
All Hormonal Investigation by Chemiluminescent Method
Visceral Fat by (AB-140) Ambulatory BP Monitoring
CGMS & Insulin Pump Available
PFT, 2D-ECHO (Color Doppler), Holter, TMT, Cardiac-3 available
VIA, VILI, Colposcopy available
Special Endocrinological Investigation Protocols.

ISO 9001:2008 Certified
Mobile: 9389994334, 9554572190, 9453837595



Panacea Pathology

Clinical Reference Lab

Persistence, Preparedness and Precision
EQAS (CMC Vellore Attached) & IQAS System
पूर्वांचल की सर्वोत्तम गुणवत्ता वाली पैथोलॉजी

UHID No :- UD-23240006730 **Booking No/Date** :- 47 / 10-Mar-2024 12:31 PM
Patient Name :- Mrs NIRMALA KUMARI **Age/Sex** :- 30 Y/F
Husband :- DEBASHISH NANDAN **OP No** :- OP-23240020676
Address :- WARD NO 34 BAWAN BIGHA CASTAIR TOWN DEOGHAR 814112 , jharkhand **Mobile No** :- 9204373372
Consultant :- Dr ASHUTOSH MISHRA (MBBS MD IMS BHU)

Investigations	Observations	Biological Ref. Interval	Unit
GROSS EXAMINATON			
COLOR <i>Methology</i>	YELLOW	CLEAR YELLOW	
CONSISTANCY	NORMAL		
BLOOD	ABSENT		
MUCUS	ABSENT		
MICROSCOPIC EXAMINATON			
OVA OR EGGS OF HELMINTHS	ABSENT		
CYST OF PROTOZOA	ABSENT		
PUS CELLS	02-03	2.00 - 3.00	/HPF
RBC <i>Methology / Cam</i>	NIL	3.50 - 4.50	million/cumm

* END OF REPORT *

Consulting Pathologist
DR. UMESH KUMAR
MBBS, MD (PATHOLOGIST)
MCI Reg. No. 41413

Lab Technician

Timing : 24/7 hrs

This Report is not valid for medico legal purpose

Note: These tests have technical limitations. Clinico-pathological interpretation is necessary. In case of any disparity test may be repeated immediately.

Address : 36/44 FK Kabir Nagar, Durgakund, Varanasi – 221005

Email: dramishra@gmail.com, drpallaviojha@gmail.com Website: panaceahospital.org



PANACEA HOSPITAL

Call Now - 1800-123-3070



A shelter for many hearts A Home for many lives

(An ISO 9001:2008 Certified Organisation)
Lab Attached with CMC Under EQAS Scheme

Dept. of Radiodiagnosis - 32 Slice CT Scan, 3D/4D USG, 2D ECHO, Colour Doppler, Intervention Procedures, Digital X-Ray

NAME: KUMARI NIRMALA
REF.DR. DR.ASHUTOSH MISHRA(MD)

AGE/SEX: 30 YRS/FEMALE
DATE: 10/03/2024

ULTRA SOUND WHOLE ABDOMEN REPORT

Liver: Normal in size(13.8cm), shape & echogenicity. Intra & extra hepatic biliary Radicals & Vascular structures are normal. Margins are smooth and regular.

Gall bladder: Normally distended with echo free lumen.

Portal vein: Normal in course and caliber.

CBD diameter: Visualized part normal in course & caliber.

Pancreas: Normal in size, shape & echogenicity. Margins are smooth & regular. No diffuse/ focal lesion seen. Pancreatic duct not visualized.

Spleen: Normal in size, shape & echogenicity. Margins are smooth & regular.
No diffuse / focal lesion seen. Splenic vessels at hilum is normal.

Kidney: Both normal in size, shape echogenicity & position. Cortical-medullary differentiation is maintained. Pelvicalyceal system normal. No evidence of any calculus/mass lesion seen
No hydronephrosis/ hydroureter seen. No suprarenal mass lesion.

Urinary bladder: Normally distended with normal wall thickness. No echogenic foci lumen or diverticula seen.
Both VUJ appears normal. No evidence of calculus / mass lesion seen.

Uterus: Uterus is normal in size, Margins are smooth & regular.
Endometrial thickness measures.

Ovary: Bilateral ovaries show normal size and morphology.

Others: No free fluid in peritoneal cavity.
No free fluid in bilateral pleural cavity.
No evidence of significantly enlarged retroperitoneal/ mesenteric lymph nodes noted.

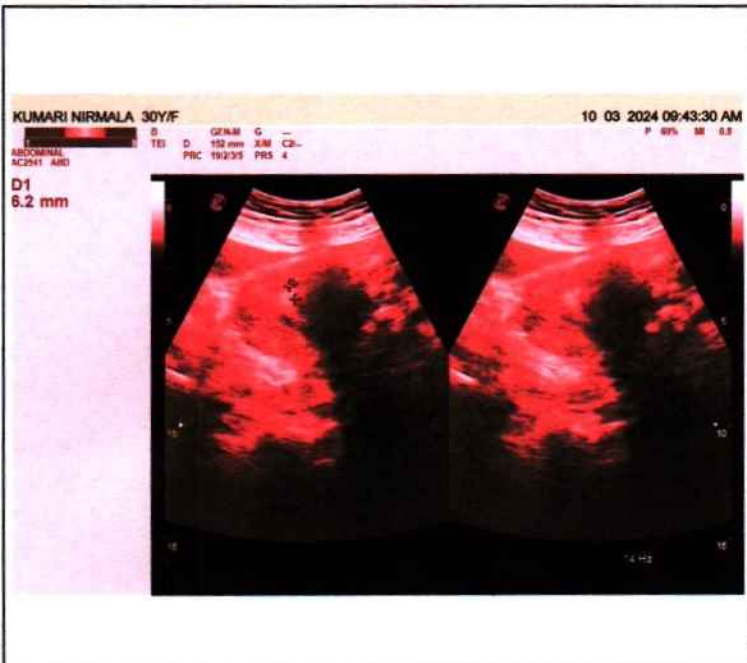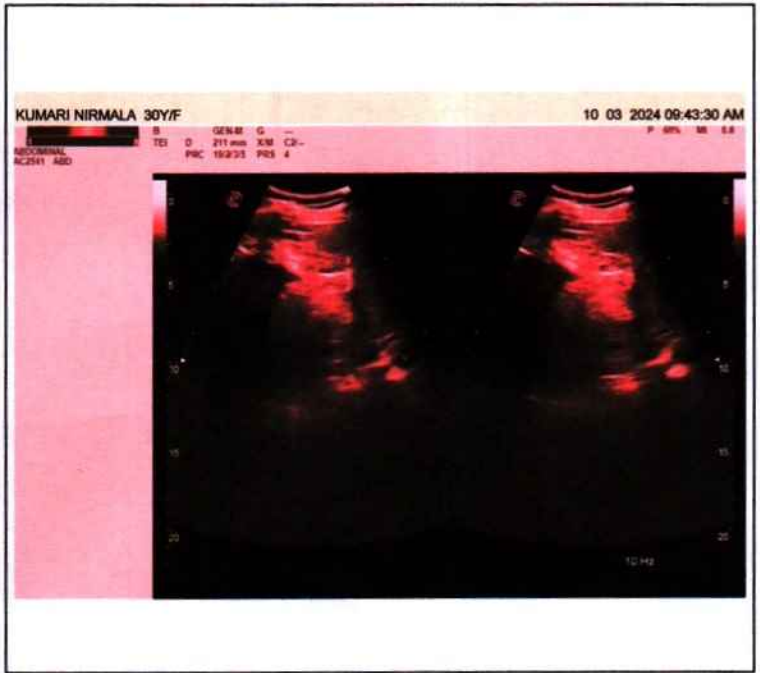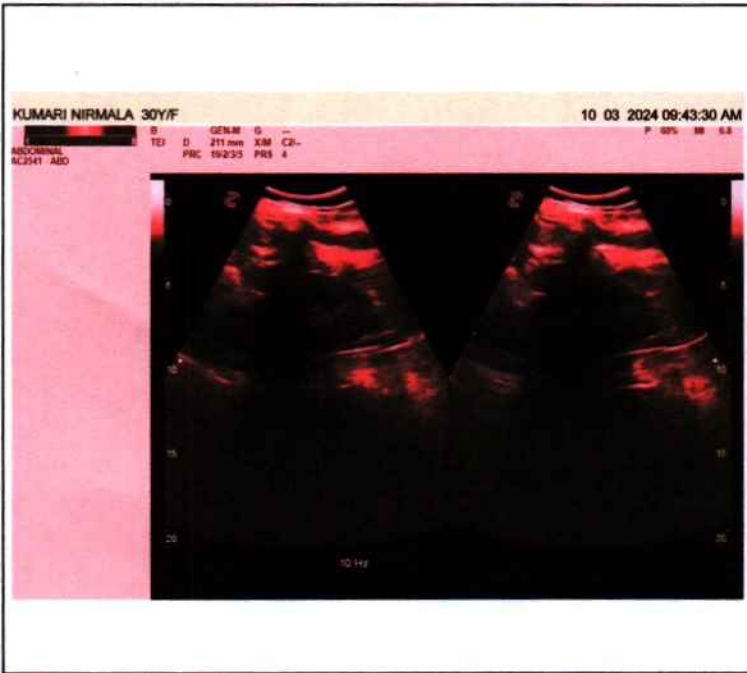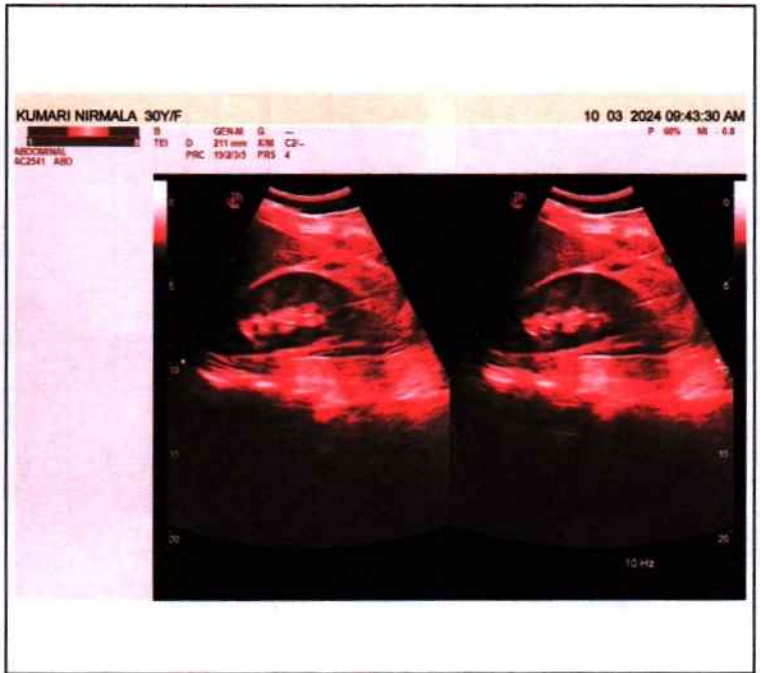
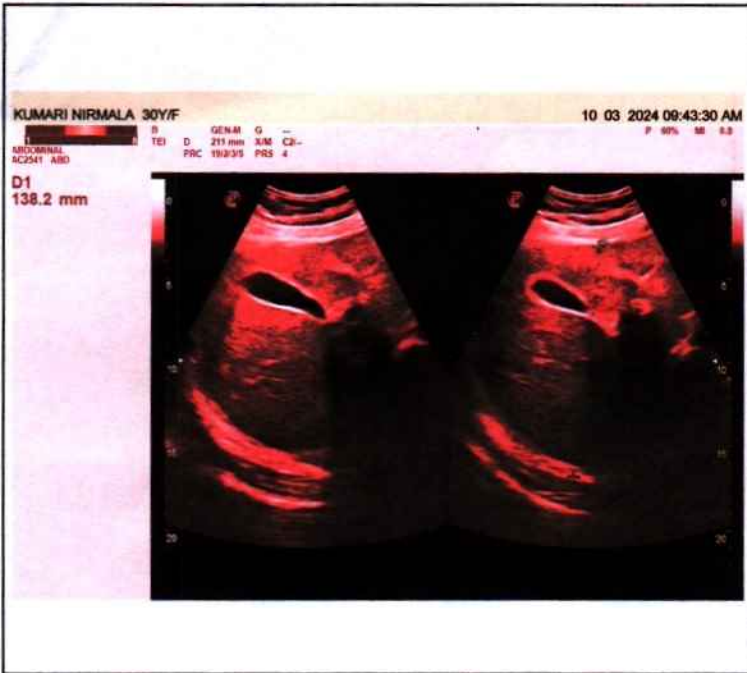IMPRESSION: - **NO OBVIOUS SONOLOGICAL ABNORMALITY SEEN.**

Please correlate clinically and further investigations.


Dr. Randeep Kumar Tiwan
MBBS, MD (Radio Diagonosis)
Reg. No. 57557

Disclaimer: This report is not valid for Madicolegal or Judicial Purpose. Radiological diagnosis is solely interpretation of images produced by tissue & may not be always conclusive.

Address : B36/44 B4 Kabir Nagar (Near Sanjay Shiksha Niketan), Durgakund, Varanasi
Mobile : 9554572190 / 9453837595 / Recpn, 9389994334
Email : dramishra@gmail.com, drpallaviojha@gmail.com, Website : www.piire.org





PANACEA HOSPITAL



A shelter for many hearts A Home for many lives
(An ISO 9001:2008 Certified Organisation)
Lab Attached with CMC Under EQAS Scheme

Dept. of Radiodiagnosis - 32 Slice CT Scan, 3D/4D USG, 2D ECHO, Colour Doppler, Intervention Procedures, Digital X-Ray

PATIENT'S NAME : KUMARI NIRMALA

AGE/SEX: 30Y/F

REF. BY : Dr. ASHUTOSH MISHRA (MD)

Sunday, March 10, 2024

Echo - Cardiography


MITRAL VALVE Doppler	AML - normal morphology MV Flow - E - 0.7 A-0.5 E/A=1.28	PML - normal morphology MVA - 3.0 cm ² Mitral Regurgitation - No
TRICUSPID VALVE Doppler	Normal TV Flow -No	Tricuspid Regurgitation -No
PULMONARY VALVE Doppler	Normal PV Flow -No	Pulmonary Regurgitation - No
AORTIC VALVE Doppler	Trileaflet-No AV Flow - no	Aortic Regurgitation - no
MEASUREMENT	Aorta - 22.3 (20-38) mm IVS ed - 10.3 (6-12) mm LVID ed -39.4 (35 - 55) mm LVPW ed - 10.3 (6-12) mm OA - 7 (> 5) mm	LA - 34.8 (24-32) mm IVS es -12.6 (6 - 12) mm LVID es - 28.0 (24 - 40) mm LVPW es -14.3 (6-12) mm EPSS - 4 (< 9) mm

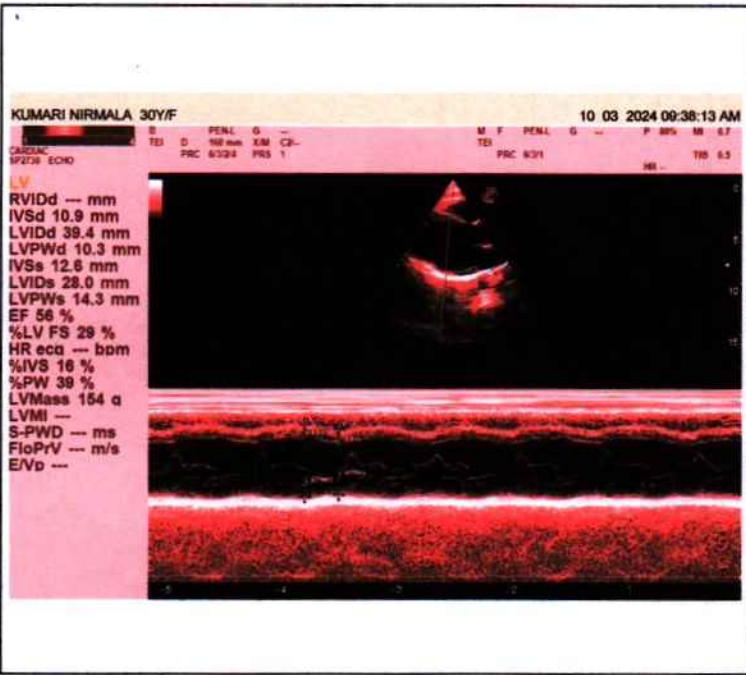
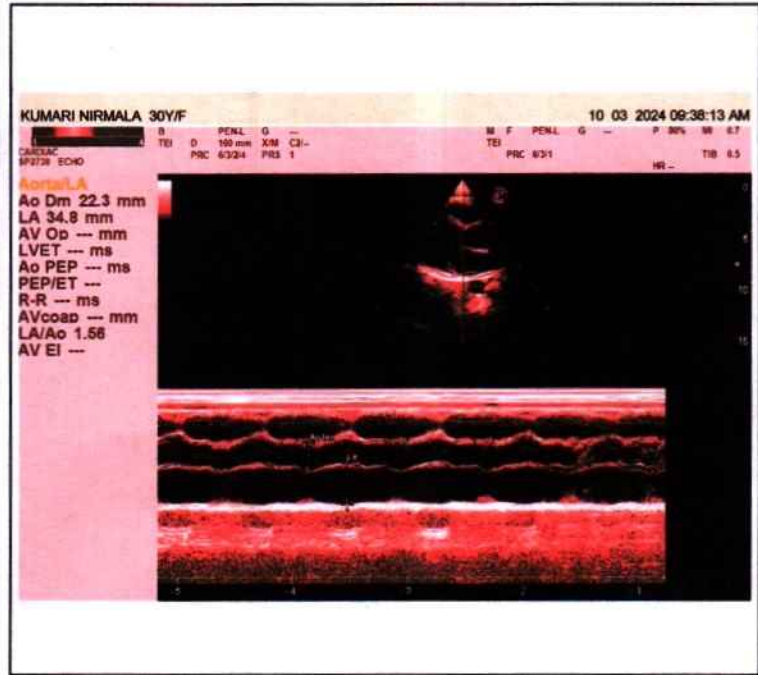
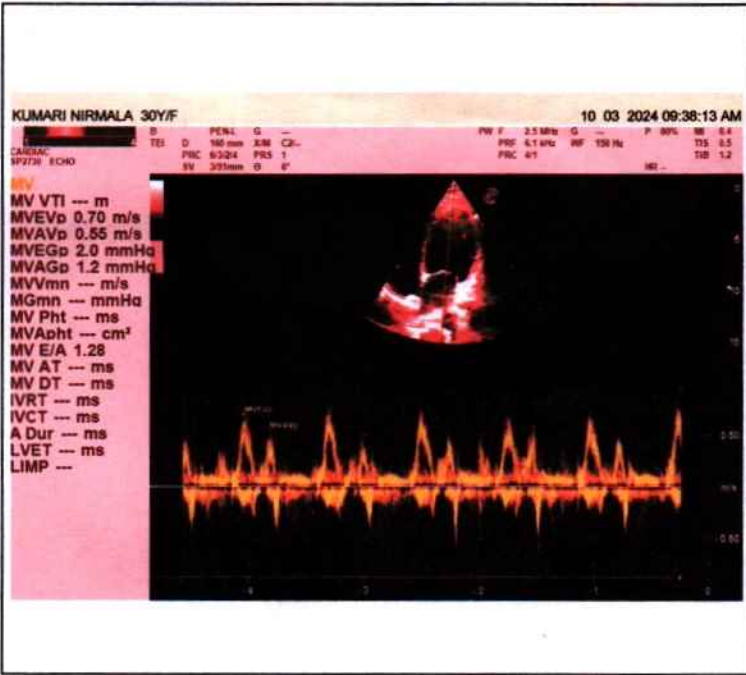CONCLUSION

All cardiac chamber dimensions are WNL
No valvular abnormalities
Good LV systolic function present Modified Simpson's method (4C, 2C) (LVEF=56%)
No diastolic dysfunction present (E/A = 1.28)
No RWMA
No pericardial effusion
Intact IAS / IV
No PAH
No intra cardiac mass /thrombus /vegetation

IMPRESSION **Normal Echocardiogram**


Nirali Mishra
Physician Assistant
(PIIRE)


DR. Pallavi Misra
MBBS, MD (GENERAL MEDICINE)
Echocardiography Specialist, MIAE
MCI Reg. No. 52033
Women Cardiologist
Diabetocardiologist





PANACEA HOSPITAL



A shelter for many hearts A Home for many lives

(An ISO 9001:2008 Certified Organisation)
Lab Attached with CMC Under EQAS Scheme

Dept. of Radiodiagnosis - 32 Slice CT Scan, 3D/4D USG, 2D ECHO, Colour Doppler, Intervention Procedures, Digital X-Ray

PATIENT'S NAME	:	NIRMALA KUMARI	AGE30Y/SEX:F
REF. BY	:	Dr. ASHUTOSH MISHRA(MD)	DATE:10/03/2024

X-RAY CHEST (PA VIEW)

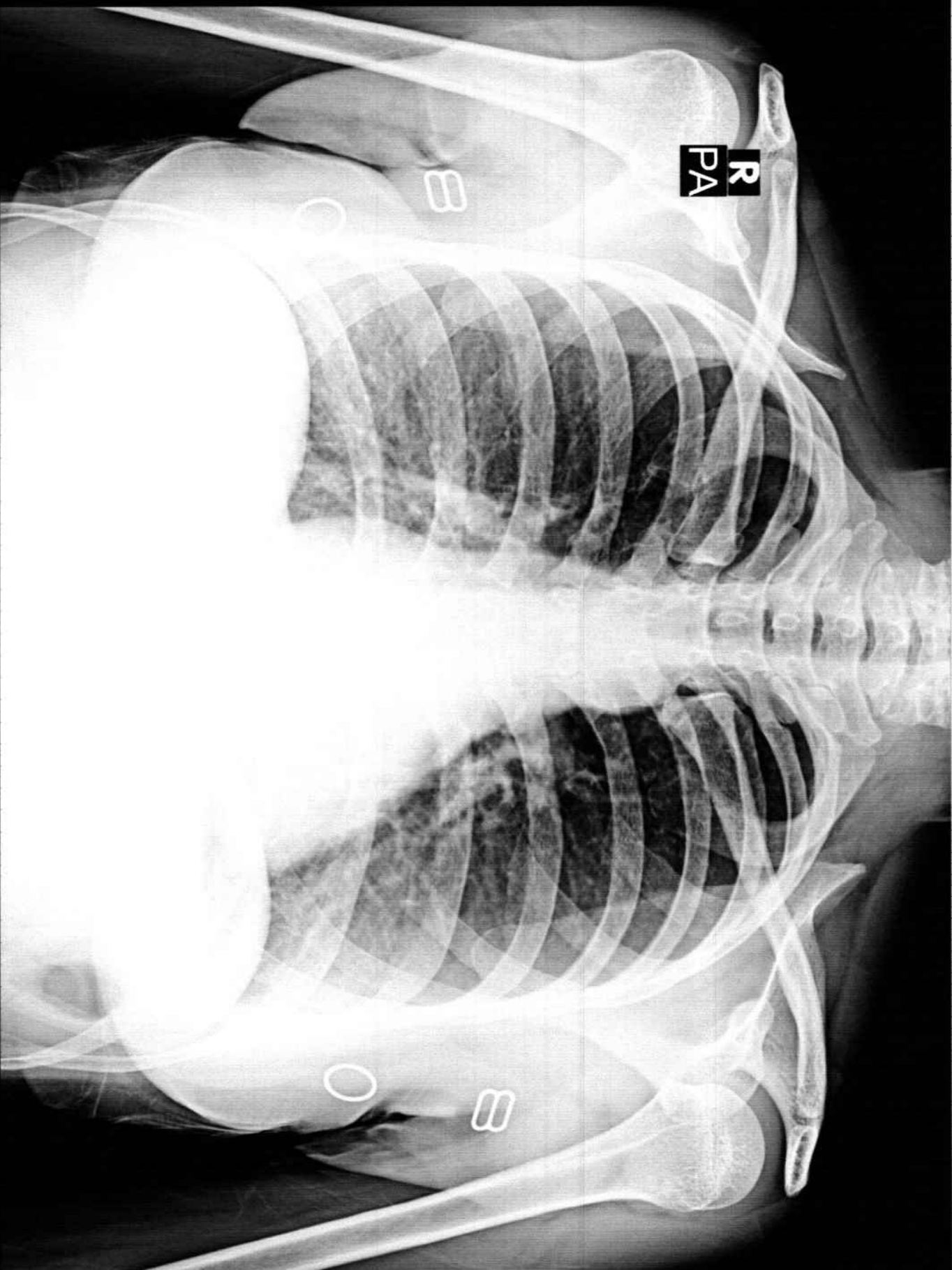
- Bilateral lung fields appear normal.
- Trachea and mediastinum appear normal in position.
- Both hila appear normal in size and are symmetrical.
- Transverse cardiac diameter is within normal limits.
- Great vessels appear normal
- Both CP angles appear clear. Normal position and contour diaphragms noted.
- Bony rib cage and soft tissue shadows appear normal.

IMPRESSION

- **No obvious abnormality noted in the chest radiograph.**

Thanks for reference.

Radiologist
Dr. Rahul Kumar Tiwan
MBBS, MD (Radio Diagonosis)
Reg. No. 57557



NIRMALA KUMARI 30Y/F 6730 F CHEST P.A. 10-Mar-24 11:12 AM

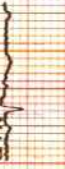
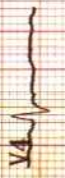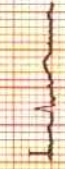PANACEA HOSPITAL, KABIR NAGAR, DURGAKUND, VARANASI

2024-03-10 11:09

5mm/mV

5mm/mV

5mm/mV



ID : _____
 Name : Nirmala Kumari
 Sex : F. Age : 30
 Height : 159 Weight : 59 kg
 SYS : _____
 DIA : _____

HR [bpm] : 95
 PR Interval [ms] : 140
 P Duration [ms] : 120
 QRS Duration [ms] : 90
 T Duration [ms] : 242
 QT/QTc [ms] : 382/479
 P/QRS/T Axis [deg] : 67.9/-3.5/-24.0
 R(V5)/S(V1) [mV] : 0.80/0.29
 R(V5)+S(V1) [mV] : 1.09

<< Conclusions >>

Normal Sinus Rhythm,
Middling Left axis deviation,

Report need physician confirm

DR. Pallavi Misra
MBBS, MD(GENERAL MEDICINE)
MCI Reg. No.52033

Physician

AUTO 5mm/mV

5mm/mV

5mm/mV



25mm/s ECG35Hz

8889966

UPKAR HEALTHCA