

Patient Name	: Mr. KUNAL KUMAR SINGH .	Age/Gender	: 34 Y/M
UHID/MR No.	: SALW.0000136919	OP Visit No	: SALWOPV204691
Sample Collected on	:	Reported on	: 27-01-2024 13:56
LRN#	: RAD2217428	Specimen	:
Ref Doctor	: DR VIJENDRA REDDY		
Emp/Auth/TPA ID	: 186500		

DEPARTMENT OF RADIOLOGY

X-RAY CHEST PA

Lung fields are clear.

Cardio thoracic ratio is normal.

Apices, costo and cardiophrenic angles are free.

Cardio vascular shadow and hila show no abnormal feature.

Bony thorax shows no significant abnormality.

Domes of diaphragm are well delineated.

IMPRESSION:

NORMAL STUDY.



Dr. ARUN KUMAR S
MBBS, DMRD, DNB
Radiology

Patient Name	: Mr. KUNAL KUMAR SINGH .	Age/Gender	: 34 Y/M
UHID/MR No.	: SALW.0000136919	OP Visit No	: SALWOPV204691
Sample Collected on	:	Reported on	: 28-01-2024 20:06
LRN#	: RAD2217428	Specimen	:
Ref Doctor	: DR VIJENDRA REDDY		
Emp/Auth/TPA ID	: 186500		

DEPARTMENT OF RADIOLOGY

ULTRASOUND - WHOLE ABDOMEN

Liver appears normal in size, Fatty liver(Grade II).
Intra and extra hepatic biliary passages are not dilated.

Gall bladder appears normal with no evidence of calculus.
Wall thickness appear normal.

Pancreas appears normal.
Spleen measures 12.1cm and shows uniform echotexture.

Visualised aorta and IVC are normal.
No evidence of ascites or lymphadenopathy.

Right kidney measures 9.9 x 4.0cm.
Left kidney measures 10.7 x 5.0cm.
Both kidneys show normal echopattern with no evidence of calculi or calyceal dilatation.

Prostate measures 3.0 x 2.7 x 3.1cm(Vol-14ml).

Bladder is normal in contour.

IMPRESSION:

Grade II - Fatty liver.

TO BE CLINICALLY CORRELATED.

Patient Name : Mr. KUNAL KUMAR SINGH .

Age/Gender : 34 Y/M

(The sonography findings should always be considered in correlation with the clinical and other investigation finding where applicable).

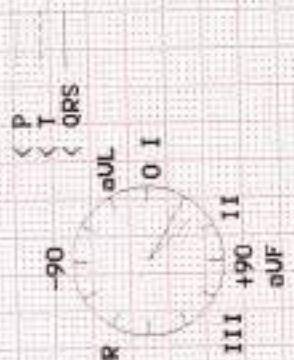


Dr. ARUN KUMAR S
MBBS, DMRD, DNB
Radiology

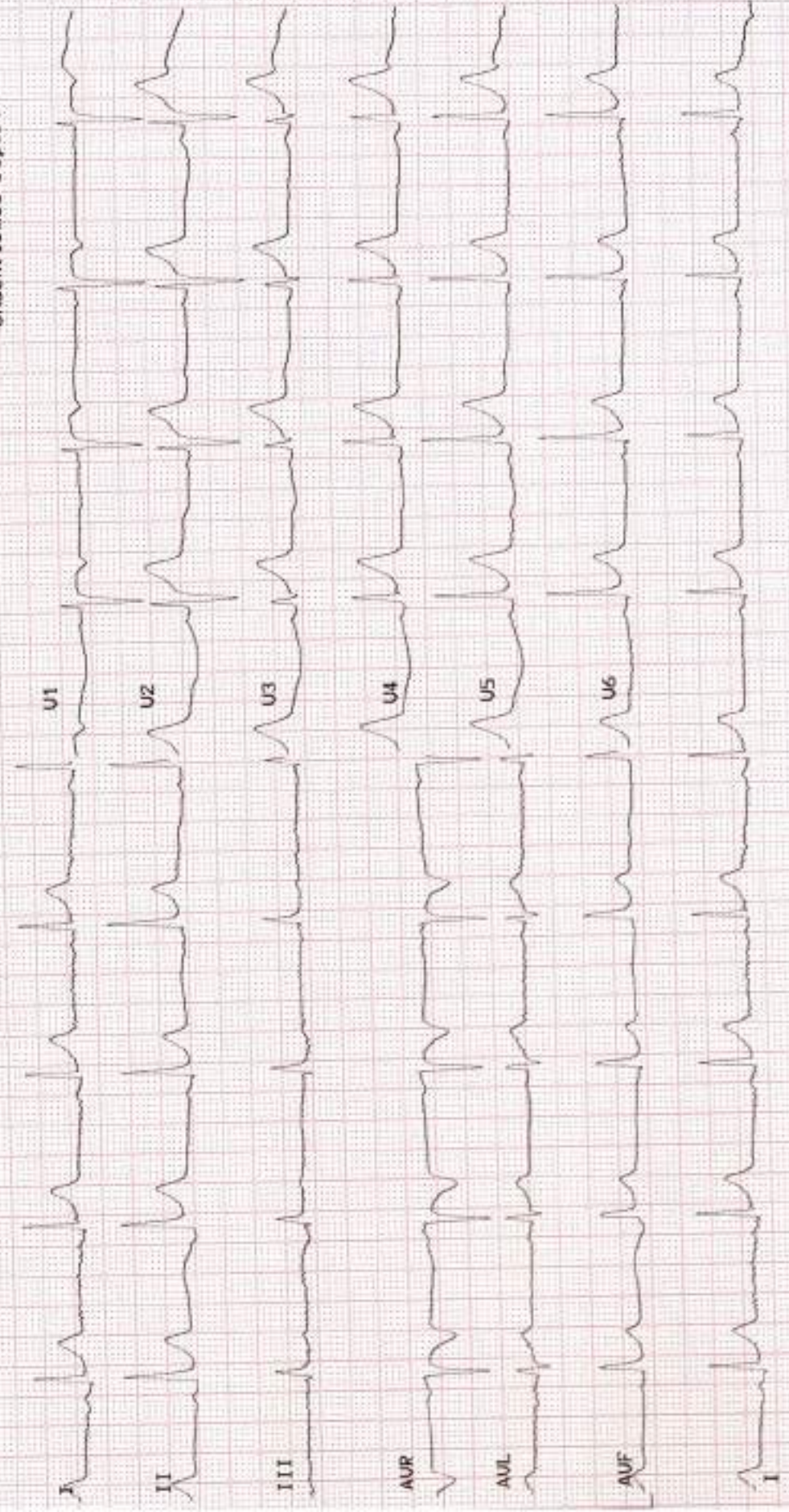
Measurement Results:

PR : 94 ms
 P/QTcB : 378 / 367 ms
 P/QTc : 160 ms
 P/QT : 86 ms
 P/QT/QTc : 1048 / 1050 ms
 S/T : 31 / 45 / 30 degrees

Interpretation:



Unconfirmed report.



27/1/2024

Dr. SUNDHARI V, MBBS., DNB., MNAMS
SENIOR ENT CONSULTANT
Ear Nose Throat Surgeon, Head & Neck Surgeon
Specialist in Endoscopic, Microscopic,
Advanced Skull Base
Phono Surgery & Snoring Surgery
Reg. No. 58764

Mr. KUNAL KUMAR SINGH,
SALW.0000136919 34/M

Health check.

No ENT symptoms

O/R. From nose

Nose. Air / Bilateral HF 85

Throat. Allergic rhinitis. Grade IV rhinitis.
General poor

D Air / 85 / S/L max.

Vella

OPHTHALMIC RECORD



NAME :

AGE : Mr. KUNAL KUMAR SINGH.

I.D. NO.: SALW.0000136919 34/M

DATE: 27.1.24

REFERRAL DETAILS :

NHe

ALLERGIES :

NOT aware of

OCULAR HISTORY :

OU: No specific ocular yo.

SYSTEMIC ILLNESS :

NHe

CURRENT MEDICATION:

NHe

INVESTIGATIONS :

NHe

MAIN DIAGNOSIS

TREATMENT GIVEN

RE

LE

PRESENT GLASSES :

 $\overline{2.00} / \overline{1.00} \times 95$ $\overline{1.00} / \overline{2.00} \times 80$

NV ADD :

Cyc 1/2yr

VN. WITH PG :

6/6 NB

6/6 NB

VISION UNAIDED :

VN WITH PH :

 $\overline{1.75} / \overline{0.75} \times 90$ $\overline{0.75} / \overline{2.25} \times 80$

RETINOSCOPY :

SUBJECTIVE :

 $\overline{1.75} / \overline{0.75} \times 90$
(6/6) NB $\overline{0.75} / \overline{2.25} \times 80$
(6/6) NB

ANTERIOR SEGMENT :

Same as old of Ap.

Colour m :

or: Normal

5/10

IOP

① 16mmHg

② 16mmHg

@ 8.30pm

FUNDUS :



CERTIFICATE OF MEDICAL FITNESS

This _____ clinical examination
of Mr. KUNAL KUMAR SINGH . on 27/01/2024
SALW.0000136919 34/M
After that _____ a clinical examination it has been found

	Tick
<ul style="list-style-type: none"> • Medically Fit 	<input type="checkbox"/>
<ul style="list-style-type: none"> • Fit with restrictions/recommendations <p>Though following restrictions have been revealed, in my opinion, these are not impediments to the job.</p> <p>1. <u>Low fat diet</u></p> <p>2. <u>Rawed sugar</u></p> <p>3.</p> <p>However the employee should follow the advice/medication that has been communicated to him/her.</p> <p>Review after _____</p>	✓
<ul style="list-style-type: none"> • Currently Unfit. Review after _____ recommended 	<input type="checkbox"/>
<ul style="list-style-type: none"> • Unfit 	<input type="checkbox"/>

Dr. RAJADHANGI .D
Medical Officer
Apollo Spectra Alwarpet
M.D. INTERNAL MEDICINE
GENERAL PHYSICIAN
APOLLO SPECTRA HOSPITALS
Alwarpet, REG No: 104481

This certificate is not meant for medico-legal purposes

Patient Name	: Mr. KUNAL KUMAR SINGH .	Age	: 34 Y/M
UHID	: SALW.9009136919	OP Visit No	: SALWOPV204691
Conducted By:	: Dr. CECILY MARY MAJELLA	Conducted Date	: 29-01-2024 13:25
Referred By	: SELF		

2D-ECHO WITH COLOUR DOPPLER

Dimensions:

Ao (ed)	2.8 CM
LA (es)	3.0 CM
LVID (ed)	5.3 CM
LVID (es)	3.4 CM
IVS (Ed)	0.8 CM
LVPW (Ed)	0.8 CM
EF	64%
%FD	35%
MITRAL VALVE :	NORMAL
AML	NORMAL
PML	NORMAL
AORTIC VALVE	NORMAL
TRICUSPID VALVE	NORMAL
RIGHT VENTRICLE	NORMAL
INTER ATRIAL SEPTUM	INTACT
INTER VENTRICULAR SEPTUM	INTACT
AORTA	NORMAL
RIGHT ATRIUM	NORMAL
LEFT ATRIUM	NORMAL
Pulmonary Valve	NORMAL
PERICARDIUM	NORMAL
LEFT VENTRICLE:	

NO REGIONAL WALL MOTION ABNORMALITY

NORMAL LEFT VENTRICULAR SYSTOLIC FUNCTION

COLOUR AND DOPPLER STUDIES

PWD: A<E AT MITRAL INFLOW

E/A-E: 0.9m/sec A: 0.5m/sec

VELOCITY ACROSS THE PULMONIC VALVE UPTO
0.8m/sec

VELOCITY ACROSS THE AV UPTO 1.0m/sec

TR VELOCITY UPTO 1.9m/sec 15mmHg

IMPRESSION

NO REGIONAL WALL MOTION ABNORMALITY
LEFT VENTRICLE NORMAL IN SIZE
NORMAL LEFT VENTRICULAR SYSTOLIC FUNCTION(LVEF-64%)
TRIVIAL MITRAL REGURGITATION
TRIVIAL TRICUSPID REGURGITATION
NO PULMONARY ARTERY HYPERTENSION
NO PERICARDIAL EFFUSION / CLOT.

Done By Mrs. KALAIYARASI


DR J CECILY MARY MAJELLA MD,DM (Cardio)