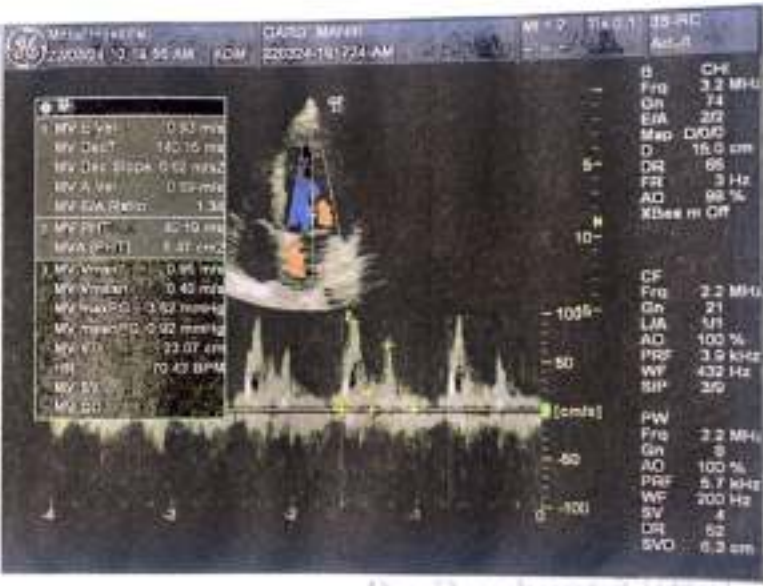
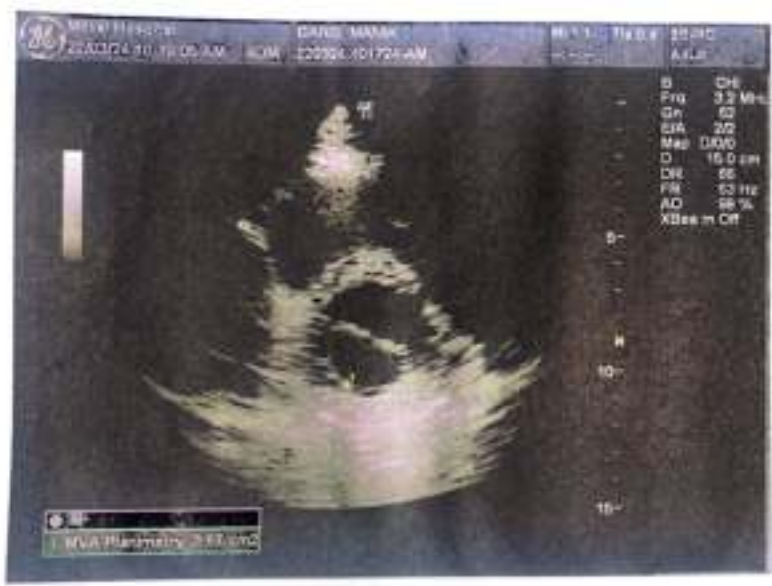
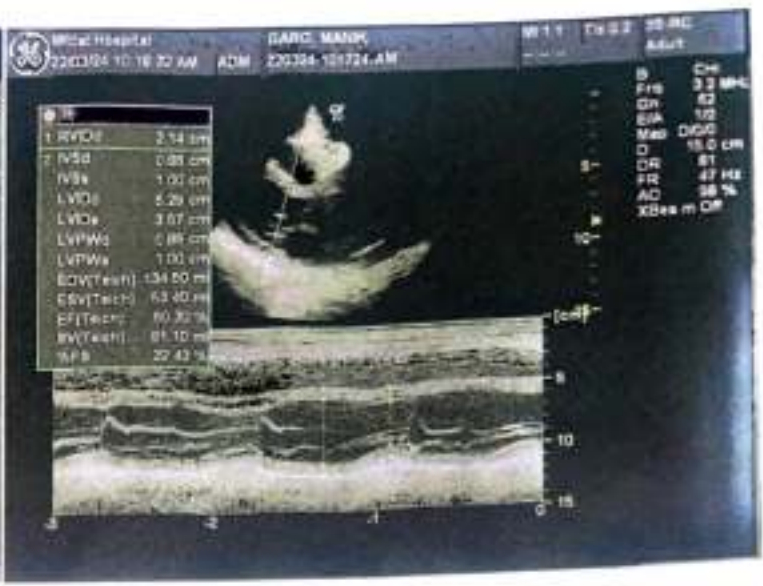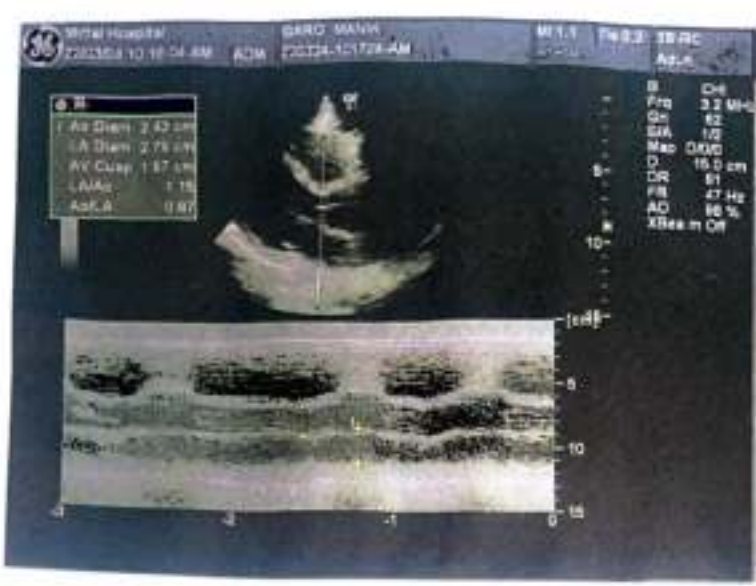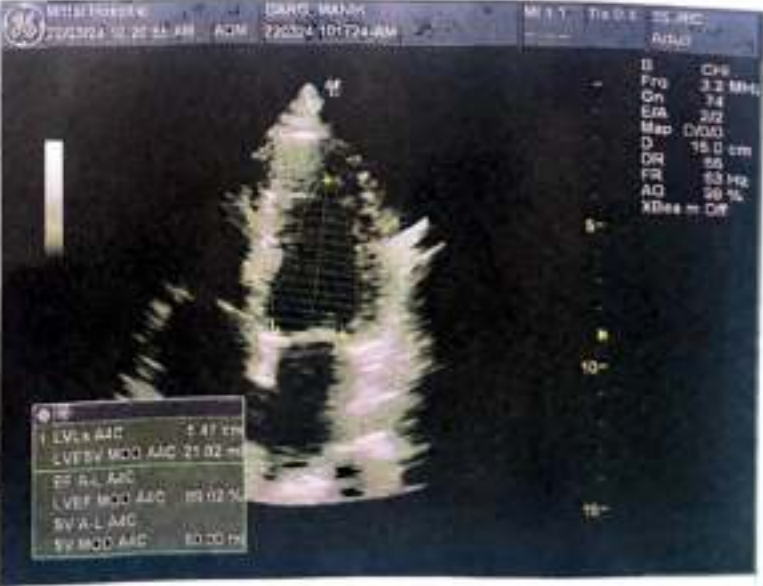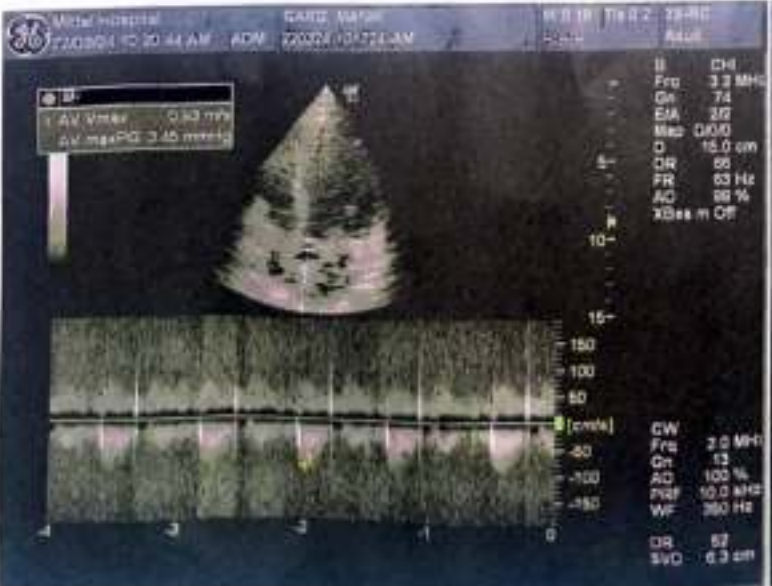Dr. Parshant Mittal
S.D.K. Medicine
PAC-102, N-57, 514
Mittal Hospital, Barnala



RADIOGRAPHY REPORT

Age: 3

Sex: M

MEASUREMENTS

NO

: 24.3

: 27.9

: 21.4

: 08.6

: 10.0

: 52.9

: 36.7

: 08.6

: 10.0

L.V. FUNCTION

Mitral Valve : Thin, opens normally. No regurgitation present.
MVA =3.57cm² EPSS=0.50, MAPSE=11mm. "E" wave more than
"A". E/A ratio=1.34

Aortic Valve : Thin, tricuspid, opens normally.
No aortic regurgitation present.

Tricuspid Valve : Thin, opens normally.
No tricuspid regurgitation present.

Pulmonary Valve : Thin, opens normally.

Pericardium : No pericardial effusion.

Wall Motion Abnormalities: No regional wall motion abnormalities present.

Cardiac Chambers : All the cardiac chambers are normal in size.


DOPPLER EVALUATION

VELOCITY (GRADIENT)		(GRADE)
MV : E=93 A=69	cm/sec.	MR : NIL
AV : 93	cm/sec.	AR : NIL
TV :	cm/sec.	TR : NIL
PV :	cm/sec.	PR : NIL

IMPRESSION:

➤ NO REGIONAL WALL MOTION ABNORMALITIES
WITH NORMAL LV SYSTOLIC FUNCTION
(EF=69.62%).

Not valid for Medico Legal Purpose


DR. PARSHANT MITTAL
MD (MEDICINE)
MITTAL HOSPITAL, BARNALA

Dr. Parshant Mittal
M.D. Medicine
PMC Regd. No. 37514
Mittal Hospital, Barnala



Mittal Hospital

For Appointment PH: 01679-237777
For Emergency M: 99142-16070
mittal_parshant@yahoo.com

ਮਿੱਤਲ ਹਸਪਤਾਲ

ਡਾ. ਪ੍ਰਸ਼ਾਂਤ ਮਿੱਤਲ

ਨੇੜੇ ਗਲੀ ਨੰ: 2, ਐਸ ਏ ਐਸ ਨਗਰ, ਬੱਸ ਸਟੈਂਡ ਰੋਡ, ਬਰਨਾਲਾ-148101 (ਪੰਜਾਬ)

Near Street No. 2, SAS Nagar, Bus Stand Road,
BARNALA-148101 (Pb.)

ਐਮ.ਡੀ. ਮੈਡੀਸਨ (ਡੀ.ਐਮ.ਸੀ. ਲੁਧਿਆਣਾ)
ਐਕਸ ਮੈਡੀਕਲ ਅਫਸਰ, ਸਿਵਲ ਹਸਪਤਾਲ, ਬਰਨਾਲਾ
ਐਕਸ ਸੀਨੀਅਰ ਰਜਿਸਟਰਾਰ, ਵੋਰਟੀਜ਼ ਹਸਪਤਾਲ, ਮੁਹਾਲੀ
ਐਕਸ ਸਪੈਸ਼ਲਿਸਟ, ਰਾਧਾ ਸੁਆਮੀ ਹਸਪਤਾਲ, ਬਿਆਸ
(ਦਿਲ, ਪੇਟ, ਛਾਤੀ, ਸ਼ੂਗਰ ਅਤੇ ਕਾਲੇ ਪੀਲੀਏ ਦੇ ਮਾਹਿਰ)
PMC Regd. No. 37514

ਡਾ. ਪ੍ਰੀਆ ਗਰਗ

ਐਮ.ਡੀ. ਐਨਸਥੀਜੀਆ (ਡੀ.ਐਮ.ਸੀ. ਲੁਧਿਆਣਾ)
ਐਕਸ ਸੀਨੀਅਰ ਰਜਿਸਟਰਾਰ ਡੀ ਐਮ ਸੀ, ਲੁਧਿਆਣਾ
ਐਕਸ ਸੀਨੀਅਰ ਰਜਿਸਟਰਾਰ ਪੀ ਜੀ ਆਈ, ਚੰਡੀਗੜ੍ਹ
ਐਕਸ ਕਨਸਲਟੈਂਟ ਰਾਧਾ ਸੁਆਮੀ ਹਸਪਤਾਲ, ਬਿਆਸ
(ਆਈ.ਸੀ.ਯੂ. ਅਤੇ ਕਰੀਟੀਕਲ ਕੇਅਰ ਸਪੈਸ਼ਲਿਸਟ)
PMC Regd. No. 36677

Name..... Age..... Sex..... Date.....

X-RAY REPORT

Name: MANIK GARG
Dr.: PARSHANT MITTAL

32/M

Date: 22/03/24

X- Ray Report: Chest pa view:

Both CP angles are clear.
Trachea is central.
Bony cage and ribs are unremarkable.
Cardiac silhouette and size are normal.
Lungs show normal parenchyma with no other active lesion.
No scar mark present.
No other abnormality seen.

DR. PARSHANT MITTAL
M. D. MEDICINE

Dr. Parshant Mittal
M.D. Medicine
PMC Regd. No. 37514
Mittal Hospital Barnala



Mittal Hospital

For Appointment PH: 01679-237777
For Emergency M: 99142-16070
mittal_parshant@yahoo.com

ਮਿੱਤਲ ਹਸਪਤਾਲ

ਡਾ. ਪ੍ਰਸ਼ਾਂਤ ਮਿੱਤਲ

ਐਮ.ਡੀ. ਮੈਡੀਸਨ (ਡੀ.ਐਮ.ਸੀ. ਲੁਧਿਆਣਾ)
ਐਕਸ ਮੈਡੀਕਲ ਅਫਸਰ, ਸਿਵਲ ਹਸਪਤਾਲ, ਬਰਨਾਲਾ
ਐਕਸ ਸੀਨੀਅਰ ਰਜਿਸਟਰਾਰ, ਫੋਰਟੀਜ਼ ਹਸਪਤਾਲ, ਮੁਹਾਲੀ
ਐਕਸ ਸਪੈਸ਼ਲਿਸਟ, ਰਾਧਾ ਸੁਆਮੀ ਹਸਪਤਾਲ, ਬਿਆਸ
(ਦਿਲ, ਪੇਟ, ਛਾਤੀ, ਸ਼ੂਗਰ ਅਤੇ ਕਾਲੇ ਪੀਲੀਏ ਦੇ ਮਾਹਿਰ)
PMC Regd. No. 37514

ਨੇੜੇ ਗਲੀ ਨੰ: 2, ਐਸ ਏ ਐਸ ਨਗਰ, ਬੱਸ ਸਟੈਂਡ ਰੋਡ, ਬਰਨਾਲਾ-148101 (ਪੰਜਾਬ)

Near Street No. 2, SAS Nagar, Bus Stand Road,
BARNALA-148101 (Pb.)

ਡਾ: ਪ੍ਰੀਆ ਗਰਗ

ਐਮ.ਡੀ. ਐਨਸਥੀਸੀਓਲੋਜੀ (ਡੀ.ਐਮ.ਸੀ. ਲੁਧਿਆਣਾ)
ਐਕਸ ਸੀਨੀਅਰ ਰਜਿਸਟਰਾਰ ਡੀ ਐਮ ਸੀ, ਲੁਧਿਆਣਾ
ਐਕਸ ਸੀਨੀਅਰ ਰਜਿਸਟਰਾਰ ਪੀ ਜੀ ਆਈ, ਚੰਡੀਗੜ੍ਹ
ਐਕਸ ਕਨਸਲਟੈਂਟ ਰਾਧਾ ਸੁਆਮੀ ਹਸਪਤਾਲ, ਬਿਆਸ
(ਆਈ.ਸੀ.ਯੂ. ਅਤੇ ਕਰੀਟੀਕਲ ਕੇਅਰ ਸਪੈਸ਼ਲਿਸਟ)
PMC Regd. No. 36677

Name..... Age..... Sex..... Dated.....
Name- MANIK GARG Ref by: Dr. PARSHANT MITTAL
Age/sex - 32/M Date-March 22, 2024

USG WHOLE ABDOMEN

Liver- is normal in size (13.6 cm), shape, position and echotexture. No obvious focal lesion is seen. Intrahepatic biliary radicals are not dilated. Portal vein is normal in course and caliber.

Gall Bladder is normally distended. Wall thickness is normal. No evidence of calculus. Common bile duct is normal in course and caliber.

Pancreas is normal in size and echotexture. Main pancreatic duct is not dilated.

Right Kidney is normal in size, position and echotexture. Corticomedullary differentiation maintained. No evidence of calculus/ hydronephrosis.

Left Kidney is normal in size, position and echotexture. Corticomedullary differentiation maintained. No evidence of calculus/ hydronephrosis.

Spleen is normal in size (11.1 cm), shape and echotexture. Splenic vein is normal in caliber.

Urinary bladder is distended. Wall thickness is normal. No evidence of calculus.

Prostate - measures 21cc in volume and shows normal echopattern.

No e/o free fluid in peritoneal cavity.

IMPRESSION- USG abdomen reveals- Normal study

Kindly correlate clinically/Lab parameters (CBC, Urine C/E).


DR. PARSHANT MITTAL

M. D. MEDICINE

Dr. Parshant Mittal
M.D. Medicine
PMC Regd. No. 37514
Mittal Hospital, Barnala

MITTAL COMPUTERISED LAB.

Ph. 01679-237777

Inside Mittal Hospital, BARNALA-148101

Patient's Name MANIK GARG 32/M Ref. By Dr. PARSHANT MITTAL Dated 22-03-2024

HEMATOLOGY

TEST	RESULT	NORMAL RANGE
Haemoglobin	13.9 gm/dl	Male 12.0-15.5 gm/dl Female 10-13.5 gm/dl
T.L.C.	5700 /cumm	4000-11000/cumm
D.L.C. (Different Leucocyte Count)		
Neutrophils	62 %	40-75%
Lymphocytes	28 %	20-45%
Eosinophils	03 %	1-6%
Monocytes	07 %	2-10%
Basophils	00 %	0-1%
MCV	89	80-99 fL
MCH	29	26-32 pg
MCHC	34	32-36 gm/dl
RDW	44	37-54 fL
Hematocrit	47	%
ESR (Westergreen)	03 mm. 1st Hr.	Male upto 10mm. 1st Hour. Female upto 20mm. 1st Hour.
Platelet Count	281000 /cumm.	1,50000-4,00000/cu.mm.
T Eosinophil Count	/Cumm	40-440 Cell/cumm
Total RBC COUNT	5.7	4.7-6.2 to 10 ¹² /µl

SEROLOGY

Widal Test	1:20	1:40	1:80	1:160	1:320	1:640
S. Typhi O	-	-	-	-	-	-
S. Typhi H	-	-	-	-	-	-
S. Paratyphi AH	-	-	-	-	-	-
S. Paaratyphi BH	-	-	-	-	-	-
Dengue NS1						
Dengue IgM/IgG						
TSH.	3.83	(0.550-4.780 uIU/ml)				
S. T4 LEVEL:	10.4	(5.4-11.5 mcg/dl)				
S. T3 LEVEL:	174	(80-220 ng/dl)				
S. PSA LEVEL:		(0-4 ng/mL)				

URINE EXAMINATION

ROUTINE EXAMINATION

Appearance :	CLEAR
Colour :	STRAW
Sp. Gravity :	1.005
Reaction :	ACIDIC
Albumin :	NIL
Sugar :	NIL
Bile Salts:	NIL
Bile Pigments :	NIL

MICROSCOPIC EXAMINATION

RBC	NIL
Pus Cells	OCCASIONAL
Epithelial Cells	0-1/hpf
Calcium Oxalate	NIL
Spermatozoa	
URINE FOR MICROALBUMIN :	(0.00-25.0 mg/l)
URINE FOR NICOTINE:	(<5ng/ml)

BIO-CHEMISTRY

TEST	RESULT	NORMAL RANGE
Blood Sugar Fasting	84 mg/dl.	80-120 mg/dl.
Blood Sugar PP/Random	92 Mg/dl.	Upto 140 mg/dl.
Blood Urea Nitrogen	13 Mg/dl.	10-20 mg/dl.
S. Creatinine	0.7 mg/dl.	0.8-1.4 mg/dl.
S. Uric Acid	3.1 mg/dl.	2-5 mg/dl.
BUN: Creatinine ratio	16.25	10-20:1.
Blood Group	O POSITIVE	

LIVER FUNCTION TEST

S. Bilirubin (Total)	0.51 mg/dl.	0.2-1.0 mg/dl.
Conjugated	0.28	0.1-0.4 mg/dl
Unconjugated	0.23	0.1-0.6 mg/dl
S. Alkaline Phosphatase	73 U/L	37-147U/L
S.G.O.T.	16 U/L	10-40 Units/ml
S.G.P.T.	18 U/L	10-35 Units/ml
G.G.T.P	14	0-40 U/L
AST:ALT ratio	0.89	Below 1.5
CHOL:HDL ratio	2.85	1-5
Total Serum Proteins	7.6 gm/dl.	6.0-8.0 gm/dl.
Albumin	4.5 Gm/dl.	3.5-5.0 gm/dl.
Globulin	3.1 gm/dl.	2.0-3.5 gm/dl
A:G ratio	1.45	1-5
HDL:LDL ratio	0.53	1-3.5

LIPIDOGRAM

S. Cholesterol	137 mg/dl.	130-240 mg/dl.
S. Triglycerides	86 mg/dl.	60-170 mg/dl.
S. HDL Cholesterol	48 mg/dl.	30-60 mg/dl.
S. LDL Cholesterol	91 Mg/dl.	Upto 150 mg/dl
S. VLDL Cholesterol	28 Mg/dl.	Upto 45 mg/dl.

ELECTROLYTES TEST

S. Chloride	mmol/L.	96-106 mmol/L.
S. Sodium	Mmol/L	135-155 mmol/L
S. Potassium	mmol/L	3.5-5.5 mmol/L

GLYCOSYLATED HEMOGLOBIN (HbA1c)


Reference Range	4.0 - 6.0 %	5.1 %
Good Diabetic Control	6.0 - 7.0 %	
Fair Control	7.0 - 8.0 %	
Poor Control	Above 8.0 %	
HbA1C test Value in %	Mean Plasma Glucose Level	
12.0	345	
11.0	310	
10.0	275	
9.0	240	
8.0	205	
7.0	170	
6.0	135	
5.0	100	

Medical Technologist

Dr. Sevan Kumar
M.D. Pathology
Reg. No. 45679

Dr. Parshant Mittal
M.D. Medicine
Consultant Physician

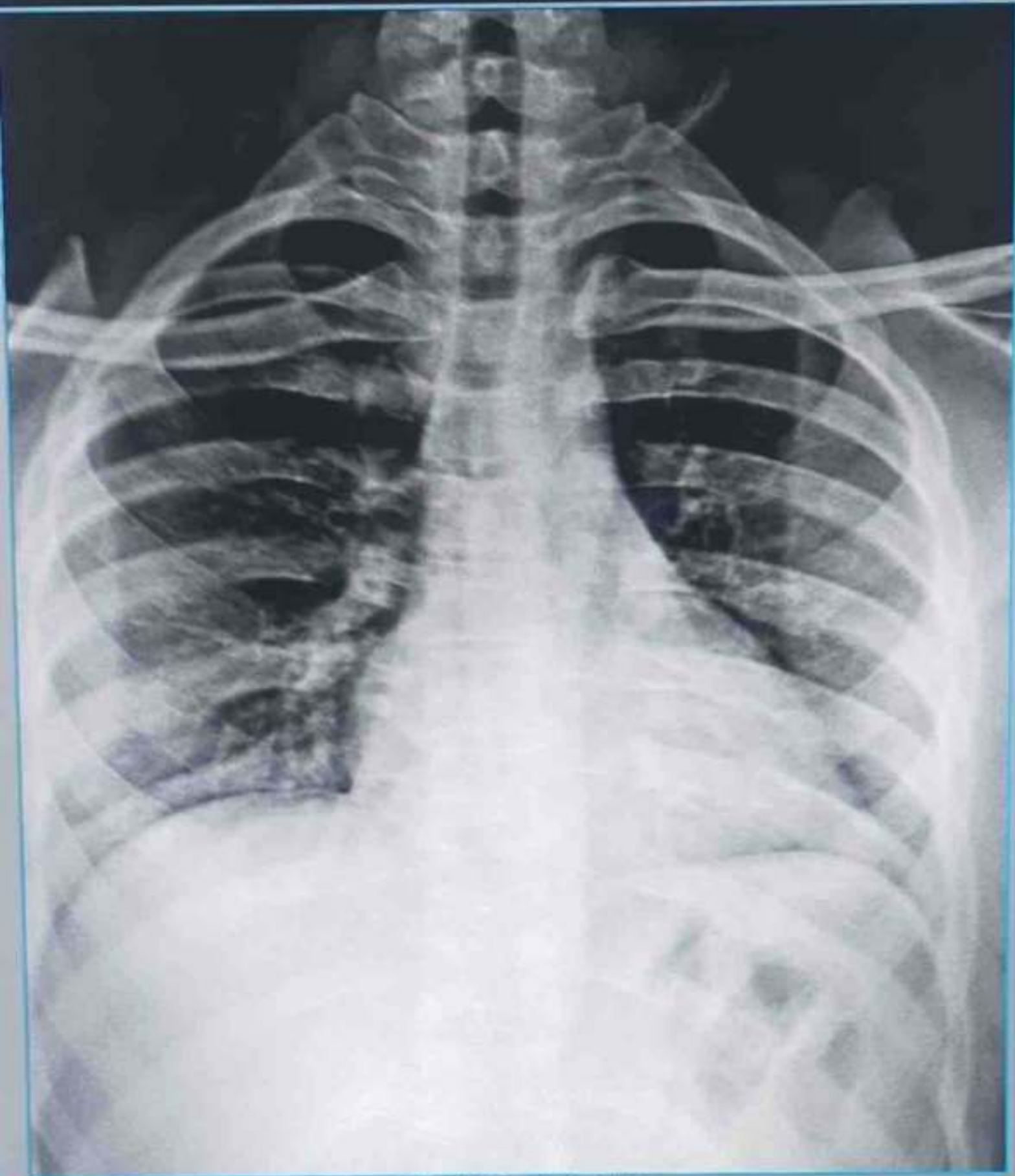


 GPS Map Camera



Barnala, Punjab, India
street no 2, New Bus Stand Rd, Sas Nagar, Barnala, Punjab 148101,
India
Lat 30.377963°
Long 75.535755°
22/03/24 10:05 AM GMT +05:30

Google





भारतीय विशिष्ट पहचान प्राधिकरण
UNIQUE IDENTIFICATION AUTHORITY OF INDIA

ਪਤਾ:

S/O: ਸੁਦਰਸ਼ਨ ਗਰਗ, 1493, ਫੇਸ-3, ਮਾਡਲ ਟਾਊਨ,
ਬਾਠਿੰਡਾ, ਬਠਿੰਡਾ,
ਪੰਜਾਬ - 151001

Address

S/O: Sudarshan Garg 1493 Phase-3
Model town Bathinda Bathinda Bathinda
Punjab - 151001

6182 2454 9249



Generation Date 07/12/2012



1947
1800 300 1947



help@uidai.gov.in

WWW

www.uidai.gov.in



P.O. Box No. 1947,
Bengalure-560 001



सत्यमेव जयते

भारत सरकार

GOVERNMENT OF INDIA



भारतीय नागरिक

Manik Garg

जन्म तिथि / DOB : 16-03-1992

पुरुष / MALE

6182 2454 9249

VID : 9110 2086 5072 7311



मेरा आधार, मेरी पहचान



MITTAL HOSPITAL

ਮਿੱਤਲ ਹਸਪਤਾਲ

ਨੇੜੇ ਗਲੀ ਨੰ: 2, ਐਸ ਏ ਐਸ ਨਗਰ, ਬੱਸ ਸਟੈਂਡ ਰੋਡ, ਬਰਨਾਲਾ-148101 (ਪੰਜਾਬ)
Near Street No. 2, SAS Nagar, Bus Stand Road, BARNALA-148101 (Pb.)

For Emergency : 99142-16070

For Appointment : 01678-237777
For Endoscopy : 62398-83393

Dr. Parshant Mittal

M.D. Medicine (D.M.C. Ludhiana)
Consultant Physician
Ex. Medical Officer, Civil Hospital, Barnala
Ex. Sen. Registrar, Fortis Hospital, Mohali
Ex. Specialist, Radha Soami Hospital, Beas
PMC Regd. No. 37514
Email : mittal_parshant@yahoo.com

Dr. Priya Garg

M.D. Anaesthesiology
Consultant Anaesthesiology
(I.C.U. & Critical Care Specialist)
Ex. Registrar DMC, Ludhiana
Ex. Sr. Registrar PGI, Chandigarh
Ex. Cons. Radha Soami Hospital, Beas
PMC Regd. No. 38677

- Emergency 24 hrs (24 ਘੰਟੇ ਐਮਰਜੈਂਸੀ)
- Fully Equipped I.C.U. (ਆਈ.ਸੀ. ਯੂ.)
- Ventilator (ਵੈਨਟੀਲੇਟਰ)
- E.C.G. / T.M.T. ਈ.ਸੀ.ਜੀ. / ਟੀ.ਐਮ.ਟੀ.
- Echo (ਈਕੋ)
- Endoscopy (ਐਂਡੋਸਕੋਪੀ)
- Colonoscopy (ਕੋਲੋਨੋਸਕੋਪੀ)
- Sigmoidoscopy (ਸਿਗਮਾਓਡੋਸਕੋਪੀ)
- Operation Theatre (ਅਪ੍ਰੇਸ਼ਨ ਥੀਏਟਰ)
- Spirometry (ਸਪੀਰੋਮੀਟਰੀ ਦੀ ਜਾਂਚ)
- Biothesiometry (ਬੀਓਥੀਸੀਮੀਟਰੀ ਦੀ ਜਾਂਚ)
- E.E.G (ਇਮਾਗ ਦੀਆਂ ਨਸਾਂ ਦਾ ਟੈਸਟ)
- Cardiac Monitoring (ਕਾਰਡੀਐਕ ਮੋਨੀਟਰਿੰਗ)
- Lab. Test (ਲੈਬੋਰੇਟਰੀ ਟੈਸਟ)
- Treatment for Hepatitis B&C (ਕਾਲੇ ਪੀਲੀਏ ਦਾ ਚਿਕਿਤਾ ਟੀਕੇ ਤੋਂ ਇਲਾਜ)
- Epidural for Chronic Back Pain (ਪੁਰਾਣੇ ਕਮਰ ਦਰਦ ਦਾ ਟੀਕੇ ਨਾਲ ਇਲਾਜ)
- Painless Normal Delivery (ਦਰਦ ਰਹਿਤ ਨੋਰਮਲ ਡਿਲਿਵਰੀ)

Name..... *Manik Garg* Age *32* Sex *M* Dated *22/3/24*

Bp - *120/80*
HR - *74*
Height - *164cm*
wt - *70kg*
waist *32"*

Chen B/L Clear
Cus - *S, L, E*
NO S/P/M

vision B/L *6/6*

Colon vision *NAD*

Dense exam - *WNL*

Medically fit

P.
Dr. Parshant Mittal
M.D. Medicine
PMC Regd. No. 37514
Mittal Hospital, Barnala

Sunday : Evening Closed

Morning : 9:00 a.m. to 2:00 p.m.

Evening : 4:30 p.m. to 7:00 p.m.

Not valid for Medico Legal Purpose

AUTO 10mm/mV

I



II



III



II 10mm/mV



10mm/mV

aVR



aVL



aVF



10mm/mV

V1



V2



V3



10mm/mV

V4



V5



V6



25mm/s AC50Hz+EMG35Hz+DFT

<< Conclusions >>

Normal Sinus Rhythm.
Mild Left axis deviation.

**Report need physician confirm

no name ECG

Q

Dr. 2024/03/27

PAC

Physician

MITTAL, HOSPITAL
2024-03-22 17:19

ID: MARK GALL

Sex: M Age: 32

Height: cm Weight: kg

SYS: mmHg

DIA: mmHg

HR	bpm	: 62
PR Interval	ms	: 120
P Duration	ms	: 97
QRS Duration	ms	: 110
T Duration	ms	: 232
QT/QTc	ms	: 427/436
P/QRS/T Axis deg		: 69.7/2.4/29.4
R (V5)/S (V1)	mV	: 0.99/0.85
R (V5)+S (V1)	mV	: 1.84

