

Patient Name : Mr.SRIDHAR SUBRAMANIAM	Collected : 26/Oct/2024 08:05AM
Age/Gender : 59 Y 9 M 12 D/M	Received : 26/Oct/2024 04:00PM
UHID/MR No : CVEL.0000147583	Reported : 26/Oct/2024 05:26PM
Visit ID : CVELOPV215600	Status : Final Report
Ref Doctor : Self	Sponsor Name : ARCOFEMI HEALTHCARE LIMITED
Emp/Auth/TPA ID : 9920144559	

DEPARTMENT OF HAEMATOLOGY

PERIPHERAL SMEAR , WHOLE BLOOD EDTA

METHODOLOGY	: Microscopic.
RBC MORPHOLOGY	: Predominantly normocytic normochromic RBC's noted.
WBC MORPHOLOGY	: Normal in number, morphology and distribution. No abnormal cells seen.
PLATELETS	: Adequate in number.
PARASITES	: No haemoparasites seen.
IMPRESSION	: Normocytic normochromic blood picture.
NOTE/ COMMENT	: Please correlate clinically.



Dr THILAGA
M.B.B.S.,M.D(Pathology)
Consultant Pathologist



Patient Name : Mr.SRIDHAR SUBRAMANIAM	Collected : 26/Oct/2024 08:05AM
Age/Gender : 59 Y 9 M 12 D/M	Received : 26/Oct/2024 04:10PM
UHID/MR No : CVEL.0000147583	Reported : 26/Oct/2024 05:10PM
Visit ID : CVELOPV215600	Status : Final Report
Ref Doctor : Self	Sponsor Name : ARCOFEMI HEALTHCARE LIMITED
Emp/Auth/TPA ID : 9920144559	

DEPARTMENT OF BIOCHEMISTRY

ARCOFEMI - MEDIWHEEL FULL BODY COMPREHENSIVE HC AND VITAMIN MALE - 2D ECHO - PAN INDIA - FY2324

Test Name	Result	Unit	Bio. Ref. Interval	Method
ALKALINE PHOSPHATASE , SERUM	105.00	U/L	30-120	IFCC AMP Buffer

Test Name	Result	Unit	Bio. Ref. Interval	Method
CALCIUM , SERUM	8.90	mg/dL	8.8-10.6	Arsenazo III

Comments:-

Serum calcium measurements are done to monitor and diagnose disorders of skeletal system, parathyroid gland, kidney, muscular disorders, and abnormal vitamin D and protein levels.



DR. R. SRIVATSAN
M.D.(Biochemistry)



Patient Name : Mr.SRIDHAR SUBRAMANIAM	Collected : 26/Oct/2024 08:05AM
Age/Gender : 59 Y 9 M 12 D/M	Received : 26/Oct/2024 04:09PM
UHID/MR No : CVEL.0000147583	Reported : 26/Oct/2024 05:09PM
Visit ID : CVELOPV215600	Status : Final Report
Ref Doctor : Self	Sponsor Name : ARCOFEMI HEALTHCARE LIMITED
Emp/Auth/TPA ID : 9920144559	

DEPARTMENT OF IMMUNOLOGY

ARCOFEMI - MEDIWHEEL FULL BODY COMPREHENSIVE HC AND VITAMIN MALE - 2D ECHO - PAN INDIA - FY2324

High	High	High	High	Pituitary Adenoma; TSHoma/Thyrotropinoma
------	------	------	------	--



DR. R. SRIVATSAN
M.D.(Biochemistry)



Patient Name : Mr.SRIDHAR SUBRAMANIAM	Collected : 26/Oct/2024 08:05AM
Age/Gender : 59 Y 9 M 12 D/M	Received : 26/Oct/2024 04:28PM
UHID/MR No : CVEL.0000147583	Reported : 26/Oct/2024 05:58PM
Visit ID : CVELOPV215600	Status : Final Report
Ref Doctor : Self	Sponsor Name : ARCOFEMI HEALTHCARE LIMITED
Emp/Auth/TPA ID : 9920144559	

DEPARTMENT OF CLINICAL PATHOLOGY

ARCOFEMI - MEDIWHEEL FULL BODY COMPREHENSIVE HC AND VITAMIN MALE - 2D ECHO - PAN INDIA - FY2324

Test Name	Result	Unit	Bio. Ref. Interval	Method
COMPLETE URINE EXAMINATION (CUE) , URINE				
PHYSICAL EXAMINATION				
COLOUR	YELLOW		PALE YELLOW	Scattering of light
TRANSPARENCY	CLEAR		CLEAR	Scattering of light
pH	5.5		5-7.5	Bromothymol Blue
SP. GRAVITY	1.032		1.002-1.030	Bromothymol Blue
BIOCHEMICAL EXAMINATION				
URINE PROTEIN	NEGATIVE		NEGATIVE	PROTEIN ERROR OF INDICATOR
GLUCOSE	POSITIVE+++		NEGATIVE	GOD-POD
URINE BILIRUBIN	NEGATIVE		NEGATIVE	Diazonium Salt
URINE KETONES (RANDOM)	NEGATIVE		NEGATIVE	Sodium nitro prusside
UROBILINOGEN	NORMAL		NORMAL (0.1-1.8mg/dl)	Diazonium salt
NITRITE	NEGATIVE		NEGATIVE	Sulfanilic acid
LEUCOCYTE ESTERASE	POSITIVE++		NEGATIVE	Diazonium salt
CENTRIFUGED SEDIMENT WET MOUNT AND MICROSCOPY				
PUS CELLS	8	/hpf	0-5	Automated Image based microscopy
EPITHELIAL CELLS	2	/hpf	< 10	Automated Image based microscopy
RBC	4	/hpf	0-2	Automated Image based microscopy
CASTS	NEGATIVE	/lpf	0-2 Hyaline Cast	Automated Image based microscopy
CRYSTALS	NEGATIVE	/hpf	Occasional-Few	Automated Image based microscopy

Comment:

All urine samples are checked for adequacy and suitability before examination. All abnormal chemical examination are rechecked and verified by manual methods. Microscopy findings are reported as an average of 10 high power fields.



Dr THILAGA
M.B.B.S.,M.D(Pathology)
Consultant Pathologist



Patient Name	: Mr. SRIDHAR SUBRAMANIAM	Age	: 59Yrs 9Mths 14Days
UHID	: CVEL.0000147583	OP Visit No.	: CVELOPV215600
Printed On	: 27-10-2024 04:25 AM	Advised/Pres Doctor	: --
Department	: Radiology	Qualification	: --
Referred By	: Self	Registration No.	: --
Employeer Id	: 9920144559		

DEPARTMENT OF RADIOLOGY

ULTRASOUND WHOLE ABDOMEN

LIVER: Liver is enlarged in size (16.6 cm) with increased echogenecity. No focal lesion is seen.

No dilatation of the intrahepatic biliary radicals.

GALL BLADDER: Gall bladder is well distended. Few calculi are seen, largest measuring 11 mm. Wall thickness appears normal. PV and CBD - 3.5 mm normal.

SPLEEN:Spleen appears normal (9.3 cms). No focal lesion seen. Splenic vein appears normal.

PANCREAS:Pancreas appears normal in echopattern. No focal/mass lesion/calcification.

KIDNEYS: Both the kidneys appear normal in size, shape and echopattern. Cortical thickness and CM differentiation are maintained. No calculus / hydronephrosis seen on either side.

Right kidney - 9.8 x 4.7 cms. **Left kidney** - 11.8 x 4.7 cms.

BLADDER:Urinary Bladder is well distended and appears normal. No evidence of any wall thickening or abnormality. **Post void (15 ml)**

PROSTATE:Prostate is enlarged in size 3.9 x 3.5 x 4.3 cms (Vol 33 ml) with intravesical extension 11 mm.

IMPRESSION:

*HEPATOMEGALY WITH GRADE II FATTY CHANGES.

*CHOLELITHIASIS.

*GRADE I PROSTATOMEGALY WITH INTRAVESICAL EXTENSION.

***NON SIGNIFICANT POST VOID RESIDUAL URINE.**

(The sonography findings should always be considered in correlation with the clinical and other investigation finding where applicable.) It is only a professional opinion, Not valid for medico legal purpose.

---End Of The Report---



Dr. PASUPULETI SANTOSH KUMAR
M.B.B.S., DNB (RADIODIAGNOSIS)
126310
Radiology

Patient Name	: Mr. SRIDHAR SUBRAMANIAM	Age	: 59Yrs 9Mths 13Days
UHID	: CVEL.0000147583	OP Visit No.	: CVELOPV215600
Printed On	: 26-10-2024 07:40 AM	Advised/Pres Doctor	: --
Department	: Cardiology	Qualification	: --
Referred By	: Self	Registration No.	: --
Employeer Id	: 9920144559		

DEPARTMENT OF CARDIOLOGY

DIMENSIONS:

Ao (ed)	2.8 CM
LA (es)	3.5 CM
LVID (ed)	4.9 CM
LVID (es)	3.3 CM
IVS (Ed)	1.2 CM
LVPW (Ed)	1.2 CM
EF	61.00%
% FD	31.00%

MORPHOLOGICAL DATA :

MITRAL VALVE	NORMAL
AML	NORMAL
PML	NORMAL
AORTIC VALVE	NORMAL
TRICUSPID VALVE	NORMAL
PULMONARY VALVE	NORMAL
RIGHT VENTRICLE	NORMAL
INTER ATRIAL SEPTUM	INTACT
INTER VENTRICULAR SEPTUM	INTACT
PULMONARY ARTERY	NORMAL
AORTA	NORMAL
RIGHT ATRIUM	NORMAL
LEFT ATRIUM	NORMAL
LEFT VENTRICLE	NORMAL
PERICARDIUM	NORMAL

DOPPLER STUDIES MITRAL INFLOW :

MV E 0.6 m/s; MV A 0.9 m/s;

PV max 0.9 m/s; PG 3.6 mmHg;

AV max 1.0 m/s; PG 4.1 mmHg;

TV max 1.0 m/s; PG 5.5 mmHg;

TV E 0.4 m/s; TV A 0.6 m/s.

IMPRESSION:

*NO REGIONAL WALL MOTION ABNORMALITY;

*NORMAL LEFT VENTRICULAR IN SIZE ;

*NORMAL LEFT VENTRICULAR SYSTOLIC FUNCTION ;

*GRADE 1 LEFT VENTRICULAR DIASTOLIC DYSFUNCTION ;

*MILD MITRAL & TRICUSPID REGURGITATION

*NO PERICARDIAL EFFUSION / PULMONARY ARTERY HYPERTENSION.

---End Of The Report---



Dr. SHANMUGA SUNDARAM D
MB, BS, MD (GM) , DNB (CARDIOLOGY)

57682
Cardiology


GE MAC1200 ST
M11E

MR SRIDHAR S. 59 000142983, APOLLO VELACHERY CLINIC

HR 96bpm

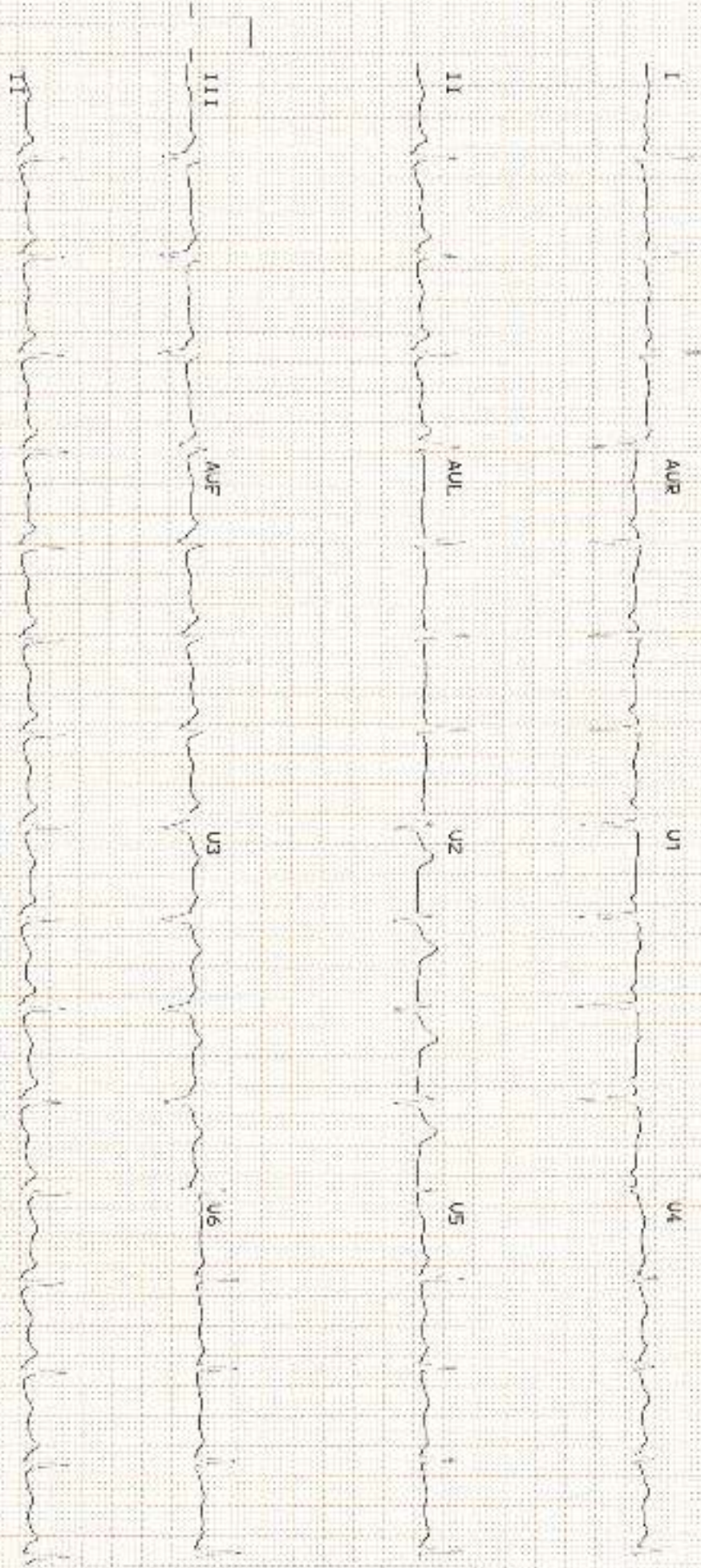
APOLLO

Measurement	Results	94 ms	< P	Interpretation
QRS			< T	
QT/QTcB	358 /	454 ms	< QRS	
PP		142 ms		
P		114 ms		
RR/PP	622 /	605 ms		
P/QRS/T	75 / 15 /	70 degrees		
QTd/QTcBd	54 /	68 ms		
Sokolow		14		
MK				



Interpretation:

Unconfirmed report.



APOLLO 7/25/2021 09:12:06 AM 250Hz 10mm/mV ADS 50Hz 0.08 -50Hz 3.71 R Automatic 46.7.121.111

MR SRIDHAR 9



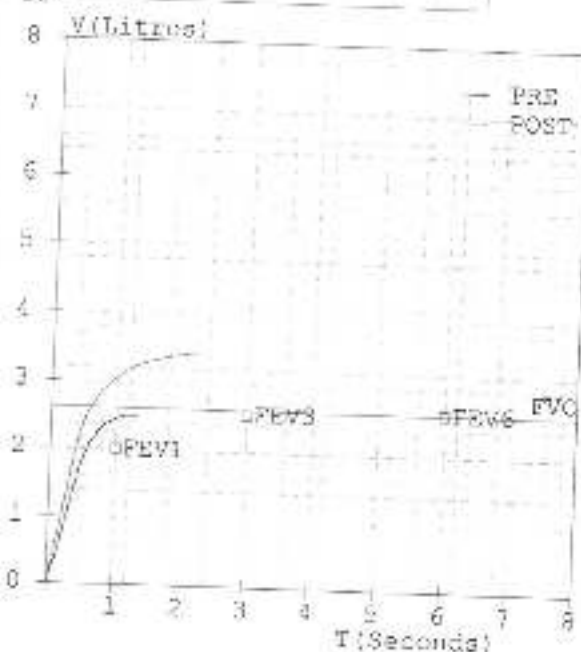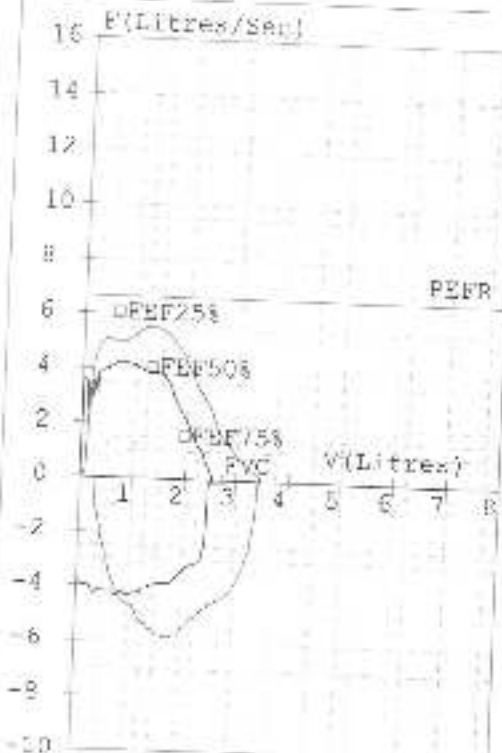
Refd. By:

Pred. Eqns: RECORDERS

Date : 26-Oct-2024 08:38 AM

Age : 59 Yrs
Height : 172 Cms
Weight : 90 Kgs
ID : 147583

Gender : Male
Smoker : No
Eth. Corr: 80
Temp :



FVC Results							
Parameter		Pred	M. Pre	%Pred	M. Post	%Pred	%Imp
FVC	(L)	02.63	02.53	096	03.45	131	+36
FEV1	(L)	02.01	02.46	122	03.07	153	+25
FEV1/FVC	(%)	76.43	97.23	127	88.99	116	-08
FEF25-75	(L/s)	02.50	03.66	146	04.13	165	+13
PEFR	(L/s)	06.66	04.20	063	05.47	082	+30
FIVC	(L)	-----	03.20	---	03.20	---	---
FEV.5	(L)	-----	01.84	---	02.37	---	+29
FEV3	(L)	02.55	02.53	099	03.45	135	+36
PIFR	(L/s)	-----	04.27	---	05.83	---	+37
FEF75-85	(L/s)	-----	01.95	---	01.40	---	-28
FEF.2-1.2	(L/s)	04.56	03.89	085	04.94	108	+27
FEF 25%	(L/s)	06.06	04.12	068	05.00	083	+21
FEF 50%	(L/s)	04.08	03.86	095	05.01	123	+30
FEF 75%	(L/s)	01.58	02.50	158	02.04	129	-18
FEV.5/FVC	(%)	-----	72.73	---	68.70	---	-06
FEV3/FVC	(%)	96.96	100.00	103	100.00	103	---
FET	(Sec)	-----	01.41	---	02.28	---	---
ExpTime	(Sec)	-----	00.02	---	00.09	---	---
Lung Age	(Yrs)	059	046	078	028	047	-39
FEV6	(L)	02.63	-----	---	-----	---	---
FIF25%	(L/s)	-----	04.23	---	04.16	---	--02
FIF50%	(L/s)	-----	04.03	---	05.35	---	+33
FIF75%	(L/s)	-----	01.33	---	05.30	---	+298

Test within normal limits
Post Test COPD Severity
Test within normal limits

Pre Medication Report Indicates Early Small Airway Obstruction as FEF 25-75 %Pred or PEFR %Pred < 70 Spirometry within normal limits as (FEV1/FVC) %Pred > 95 and FVC %Pred > 80
Post Medication Report Indicates Spirometry within normal limits as (FEV1/FVC) %Pred > 95 and FVC %Pred > 80

Date: 26/06/20

Ref. by:

Name: Mr. Sridhar Subramanian
Consultant: Dr. Nirmalana

Age: 54y Sex: M/F
UHID: 48583

ALLERGIES :

Chief Complaints:

Pain Score: Nil Location: pharynx Character:

No ENT complaints

Past History :

Nutritional assessment :

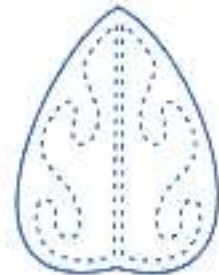
Build :

Social History : Smoking Ethanol Tobacco

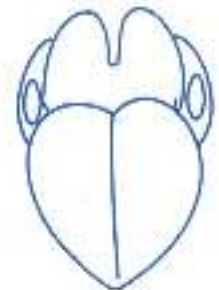
Clinical Examination :

O/E
B/L TMOK; min wax.
Nose - NAD
Throat - NAD

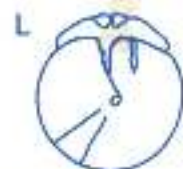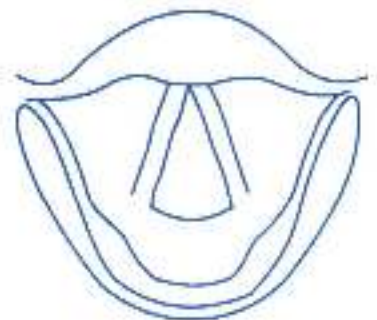NOSE



THROAT



LARYNX



Name Mr. Sridhar Subramaniam.	Date 26 - 10 - 24.
Age 59	UHD No. 147583.
Sex: <input checked="" type="checkbox"/> Male <input type="checkbox"/> Female	

OPHTHAL FITNESS CERTIFICATE

	RE	LE
DV-UCVA :	6/12	6/9.
DV-BCVA :		
NEAR VISION :	Add + 2.50 Ds N6	Add + 2.50 Ds N6
ANTERIOR SEGMENT :	Normal	Normal.
IOP :		
FIELDS OF VISION :		
E O M :	full	full
COLOUR VISION :	Normal	Normal.
FUNDUS :		
IMPRESSION :		
ADVICE :		

147583

Organization. Do not click on any links or open attachments unless you recognize the sender and know the content is safe.

Dear SRIDHAR SUBRAMANIAM,

Greetings from Apollo Clinics,

Your corporate health check appointment is confirmed at **VELACHERY** clinic on **2024-10-26** at **08:00-08:15**

Payment Mode	
Corporate Name	ARCOFEMI HEALTHCARE LIMITED
Agreement Name	[ARCOFEMI MEDIWHEEL AHC CREDIT PAN INDIA OP AGREEMENT]
Package Name	[ARCOFEMI - MEDIWHEEL FULL BODY COMPREHENSIVE IIC AND VITAMIN MALE - 2D ECHO - PAN INDIA - FY2324]

"Kindly carry with you relevant documents such as HR issued authorization letter and or appointment confirmation mail and or valid government ID proof and or company ID card and or voucher as per our agreement with your company or sponsor."

Note: Video recording or taking photos inside the clinic premises or during camps is not allowed and would attract legal consequences.

Note: Also once appointment is booked, based on availability of doctors at clinics tests will happen. any pending test will happen based on doctor availability and clinics will be updating the same to customers.

Instructions to be followed for a health check:

1. Please ensure you are on complete fasting for 10-To-12-Hours prior to check.
2. During fasting time do not take any kind of alcohol, cigarettes, tobacco or any other liquids (except Water) in the morning. If any medications taken, pls inform our staff before health check.
3. Please bring all your medical prescriptions and previous health medical records with you.



இந்திய அரசாங்கம்
Unique Identification Authority of India


பதிவு எண் / Enrolment No.: 0647/03259/71152

Download QR: 27080818

To
 பதிவு எண்
 Sridhar S
 C/O K P Subramaniam
 Old No.2, New No. 5
 Bharath Street,
 Bharath nagar
 Adambakkam
 Kancheepuram Tamil Nadu - 600068
 960001205

Generate QR: 28082018

பதிவு எண் 0647/03259/71152
 பதிவு செய்த நாள்: 14/01/2018
 பதிவு செய்த இடம்: கச்சேபுரம்



QR Code for Download

உங்கள் ஆதார் எண் / Your Aadhaar No. :

2933 0929 5697

UID : 9116 2579 0683 2618

எனது ஆதார், எனது அடையாளம்



இந்திய அரசாங்கம்
Government of India



பதிவு எண்
 Sridhar S
 பதிவு எண்/UID: 14/01/1965
 ஆண்/ MALE

2933 0929 5697

UID : 9116 2579 0683 2618

எனது ஆதார், எனது அடையாளம்



CERTIFICATE OF MEDICAL FITNESS

This is to certify that I have conducted the clinical examination

of Mr. Sridhar Subramaniam on 26/10/24

After reviewing the medical history and on clinical examination it has been found that he/she is

<ul style="list-style-type: none"> • <u>Medically Fit</u> 9. Orientated DM-2 Adv Immediate consultation <p style="text-align: center; font-weight: bold; margin-left: 100px;">FIT FOR WORK</p>	Tick <input checked="" type="checkbox"/>
<ul style="list-style-type: none"> • Fit with restrictions/recommendations <p>Though following restrictions have been revealed, in my opinion, these are not impediments to the job.</p> <p>1.....</p> <p>2.....</p> <p>3.....</p> <p>However the employee should follow the advice/medication that has been communicated to him/her.</p> <p>Review after _____</p>	
<ul style="list-style-type: none"> • Currently Unfit. Review after <u>NIL</u> recommended 	
<ul style="list-style-type: none"> • Unfit <u>NIL</u> 	

Dr. _____

Medical Officer

Dr. M S KOUTILYA CHOUDARY
MBBS., MD.,

Specialist (Genl).
Reg. No. TNMC 167543



This certificate is not meant for medico-legal purposes.