

DAKSH HOSPITAL

396 - 397, Gandhi Nagar, Scheme No. 8, ALWAR - 301001

Ref. No.

Date.....

MEDICAL EXAMINATION REPORT Mediwheel (BOB)

Name: Mrs. Manisha Meena

Age: 33 yrs

Sex: Female

Date: 24/03/2024

General Physical Examination

Height : 158cm
Pulse : 78 /mt
Respiration : 18/mt

Weight : 73 Kg
BP : 110/70 mm/hg
BMI : 29.2 kg/m²

Systemic Exam:-

NORMAL

M10 Menstrual irregular
↓ & from 4 year

Dental Check up :-

NORMAL

Eye check-up :-

NORMAL

Skin Check up:-

NORMAL

ENT Check up:-

NORMAL

Gynae Check up:-

M10 1-2-7 d/dx body Km on-P, Meds Plu man
PS-20 LP-20 day LP-11yr Paps smear later

Impression:-

NORMAL

Recommendation:-

Gyno Ref



Dr. Mukesh Kumar Gupta
MD Gen. Medicine
Reg. No 5423/16262

डॉ० मुकेश गुप्ता
M.D.F.C.C.S.
फिजिशियन एवं मधुमेह रोग विशेषज्ञ
दक्ष हॉस्पिटल, अलावर
रजि० नं०-5423/16262

Results

Run Date 24/03/2024 09:44:03 AM

Operator DAKSH

Last Name

Sample ID 5

First Name MRS MANISHA

Department

Gender Female

Age

Physician DR. MUKESH GUPTA M.D

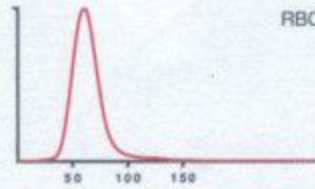
Patient ID AUTO_PID20472

Type Woman

Date of birth

Sample comments

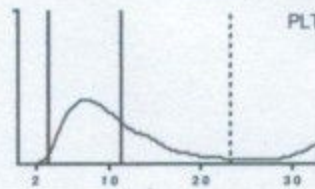
				Range
RBC	5.57	h*	10 ⁶ /μL	3.80 - 5.50
HGB	11.4	l	g/dL	11.5 - 15.2
HCT	36.7	*	%	35.0 - 46.0
MCV	65.8	L*	μm ³	77.0 - 97.0
MCH	20.4	L	pg	26.0 - 34.0
MCHC	31.0	L	g/dL	32.0 - 35.0
RDW-CV	17.7	H	%	11.0 - 17.0
RDW-SD	44.8		μm ³	37.0 - 49.0



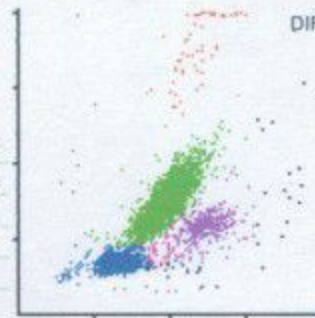
Susp. Pathologies

Microcytosis
Poikilocytosis

			Range
PLT	347		10 ³ /μL 150 - 450
PCT	0.34		% 0.15 - 0.40
MPV	9.8		μm ³ 8.0 - 11.0
PDW	16.0		μm ³ 11.0 - 22.0
P-LCC	107		10 ³ /μL 44 - 140
P-LCR	30.8		% 18.0 - 50.0



			Range
WBC	9.28		10 ³ /μL 3.50 - 10.00
	#	Range	% Range
NEU	6.37	1.60 - 7.00	68.8 40.0 - 75.0
LYM	2.48	1.00 - 3.00	26.8 20.0 - 45.0
MON	0.22	0.20 - 0.80	2.4 2.0 - 10.0
EOS	0.10	0.00 - 0.50	1.1 1.0 - 6.0
BAS	0.08	0.00 - 0.15	0.9 0.0 - 1.0
LIC	0.03	0.00 - 0.10	0.4 0.0 - 1.0



Dr. R.S. Gupta

Dr. R.S. GUPTA
MD (Pathology) (MAHE)
RMC No. 7924/19778

Date :-24/03/2024

Name :- MRS. MANISHA MEENA

Age & Sex :- 32 Yrs/ Female

Refd. :- Dr Mukesh Gupta M.D.

	TEST NAME	RESULT	REFERENCE RANGE	
	ESR	12	00 -20 mm/hrs	
	Blood Group & Rh Factor	O * POSITIVE		
	HbA1C	4.7	4 - 5.6%	
	Blood Sugar (F)	83.1	< 150 mg/dl	
	Blood Sugar (PP)	-	< 140 mg/dl	
	Urine Sugar (F)	-	-	
	Urine Sugar (PP)	-	-	
LIVER	S.Bilirubin Total	1.0	0.30 - 1.20 mg/dl	
	S.Bilirubin Direct	0.3	0.10 - 0.30 mg/dl	
	S.Bilirubin Indirect	0.7	0.30 - 0.90 mg/dl	
	S.G.O.T.	34	> 37 u/l	
	S.G.P.T.	47	> 40 u/l	
	S.Alk. Phosp.	189	80 - 306 u/l	
	G.G.T.	20.1	5 -40 u/l	
	Total Protein	6.7	6.5 - 8.5 gm/dl	
	Albumin	3.6	3.8 - 5.4 gm/dl	
	Globulin	3.1	2.3 - 3.5 gm/dl	
A/G Ratio	1.1	-		
AST/ALT Ratio	0.72	-		
KIDNEY	Blood Urea	29.1	15 -45 mg/dl	
	S.Creatinine	0.88	0.60 - 1.30 mg/dl	
	BUN	20.1	6 -24 mg/dl	
	S.Uric Acid	5.9	M 3.1 - 7.0, F 2.5 - 5.6 mg/dl	
	BUN/Creatinine Ratio	22.5	-	
LIPID PROFILE	Total Cholesterol	125.1	Up to 200 mg/dl	
	S.HDL	42.1	30 - 70 mg/dl	
	S.LDL	56.1	Up to 170 mg/dl	
	S.VLDL	27.1	5.0 - 40 mg/dl	
	S. Triglycerides	135.1	Up to 170 mg/dl	
	LDL/HDL Ratio	1.3	-	
	Total Cholesterol/ HDL Ratio	2.9	-	
THYROID	T3	104.1	40 - 181 ng/dl	
	T4	5.2	4.6 - 10.5 µg/dl	
	TSH	3.38	0.30 - 5.0 mlU/l	
URINE EXAMINATION			<i>Microscopic Examination:</i>	
General/Chemical Examination:	Colour	Pale Yellow	RBC	Absent
	Reaction	Acidic	WBC	2 - 3
	Specific Gravity	QNS	Epithelial Cells	1- 2
	Appearance	Clear	Cast	Absent
	Albumin	Nil	Crystal	Absent
	Sugar	Nil	Spermatozoa	Absent
			Amorphous Sediments	Absent
			Other	Absent
X-RAY CHEST	NORMAL STUDY			
STOOL EXAMINATION			<i>Microscopic Examination:</i>	
General/ Chemical Examination:			RBC	-
	Colour	-	WBC	-
	Consistency	-	Ova & Parasites	-

Dr. R.S. GUPTA
MD (Pathology) (MAHE)
RMC No. 7924/19778
Doctor

TECHNOLOGIST

All investigation have their own limitations regarding the sensitivity & specificity of individual assay procedures, Isolated laboratory investigations never confirm the final diagnosis of the disease. They only help in arriving at a diagnosis in conjunction with clinical presentation and other related investigations. Report is not valid for medico-legal purpose subject to ALWAR jurisdiction only.

Date :- 24/03/2024

Name :- Mrs. Manisha Meena

Refd. :- Dr Mukesh Gupta MD

Age & Sex :- 32Yrs/ Female

CYTO-PATHOLOGY

PAP SMEAR

1. Specimen type	Received two conventional smears.
2. Specimen adequacy	Smears are satisfactory for evaluation.
3. Microscopic finding	Smears are moderately cellular comprises of predominantly intermediate with mature superficial squamous epithelial cells arranged in clusters & scattered singly.
4. Inflammation	Not seen
5. Bacilli	Not seen
6. Endocervical cells	Not seen
7. Koilocytic changes	Not seen
8. Trichomonas	Not seen
9. Dysplasia	Nil
10. Neoplasia	Nil
11. Endometrial cells	Nil

Impression:- Negative for intraepithelial lesion or malignancy

Dr. R. S. GUPTA
MD (Pathology) (MAHE)
RMC No. 7924/19778

Doctor

TECHNOLOGIST

All investigation have their own limitations regarding the sensitivity & specificity of individual assay procedures, Isolated laboratory investigations never confirm the final diagnosis of the disease. They only help in arriving at a diagnosis in conjunction with clinical presentation and other related investigations. Report is not valid for medico-legal purpose subject to ALWAR jurisdiction only.



दक्ष हॉस्पिटल

396, गाँधी नगर स्कीम नं.8, अलवर (राज०) ☎ 0144-2703340

Sonography / 2D Echo Cardiography / Doppler Report

2D/ ECHO REPORT

Name: - Mrs MANISHA MEENA

Age: - 33 Yrs

Date: - 24-Mar-24

Reg. No.: - Alw/2009/04
BOB health checkup

PROCEDURES:

M-MODE/2D/DOPPLER/COLOR/CONTRAST B.A.S. M²

MEASUREMENT:		DOPPLER:	
AOD	20	NORMAL	NORMAL (cm/sec.)
LA	24	(20- 37mm)	MV 1.5 (0.8- 1.3) MR No
AVO	17	(19- 40mm)	AV 1.8 (1.2- 1.8) AR No
RVDd.	7.8	(12- 25mm)	TV 0.6 (0.3- 0.8) TR No
		(03- 09mm)	PV 0.8 (0.7- 1.1) PR No
LVDd	45.9	(37- 56mm)	MITRAL VALVE-
LVDs	27.8	(22- 40mm)	AML Normal
IVS d	7.8	(06- 12mm)	PML Normal
IVS s	11.6		
PWd	5	(05- 10mm)	AORTIC VALVE 1
LV FUNCTION		TV & PV are normal.	
M- E- S Separation		<0.9cm	
Minor		24.42%	
LV Ejection Fraction	70%	65 +/- 12%	

MITRAL A>E
LV WALL MOTION: NO RWMA
ALL CARDIAC CHAMBERS ARE NORMAL
ALL VALVES ARE NORMAL
NO CLOT, VEGETATION, PERICARDIAL EFFUSION

Adv: - Follow up/ review at higher center for confirmation

Note:- Please Correlate clinically. Due to technical limitations as well as inaccuracies inherent in the laboratory and statistical analysis of biological process. Diagnostic accuracy of ECHO is up to 95% only.
Report is not valid for medico-legal purpose.


DR. MUKESH GUPTA
Dr. Mukesh Kumar Gupta
Physician & Sonologist
RM 5423/16262



भ्रूण लिंग परीक्षण की शिकायत
104 टोल फ्री सेवा पर भी की
जा सकती है।

भ्रूण लिंग परीक्षण की शिकायत 104 टोल फ्री सेवा पर भी की जा सकती है।



दक्ष हॉस्पिटल

396, गाँधी नगर स्कीम नं.8, अलवर (राज०) ☎ 0144-2703340

Sonography / 2D Echo Cardiography / Doppler Report

NAME :- MRS MANISHA MEENA/F/33 YRS

24-Mar-24

BOB HEALTH CHECKUP

U.S.G. OF ABDOMEN & PELVIS

LIVER

Liver is normal in size shape with normal echo-texture. Intra hepatic biliary radicals Are not dilated. No evidence of focal or diffuse lesion.

GALL BLADDER

Gall bladder is normal. lumen appear clear.

PANCREAS

Pancreas is normal in size, shape & echo-texture. No evidence of focal or diffuse lesion. MPD not dilated.

SPLEEN

7.6 cm in size with normal shape & echo- texture. Spleen vein is normal. No evidence of focal or diffuse lesion

KIDNEY

Both kidneys are normal.

URINARY BLADDER

UB is normal.

UTERUS:

Uterus is normal in size (8.1x3.6x4.9cm) with homogenous echo-texture. Endometrial 8 mm in thickness & echo genicity

OVARIES:

Both ovaries appear mild enlarged & have multiple tiny follicles..

Advice- follow up/ hormonal study review at higher center for confirmation

Please correlate clinically. USG accuracy is 95 % due to technical limitations as well as inaccuracies inherent in the laboratory and statistical analysis biological process. This report is not valid for medico-legal cases


DR. MUKESH GUPTA
SONOLOGIST

Dr. Mukesh Kumar Gupta
Physician & Sonologist
RM 5423/16262



"भ्रूण लिंग परीक्षण की शिकायत
104 टोल फ्री सेवा पर भी की
जा सकती है"

भ्रूण लिंग परीक्षण की शिकायत 104 टोल फ्री सेवा पर भी की जा सकती है।

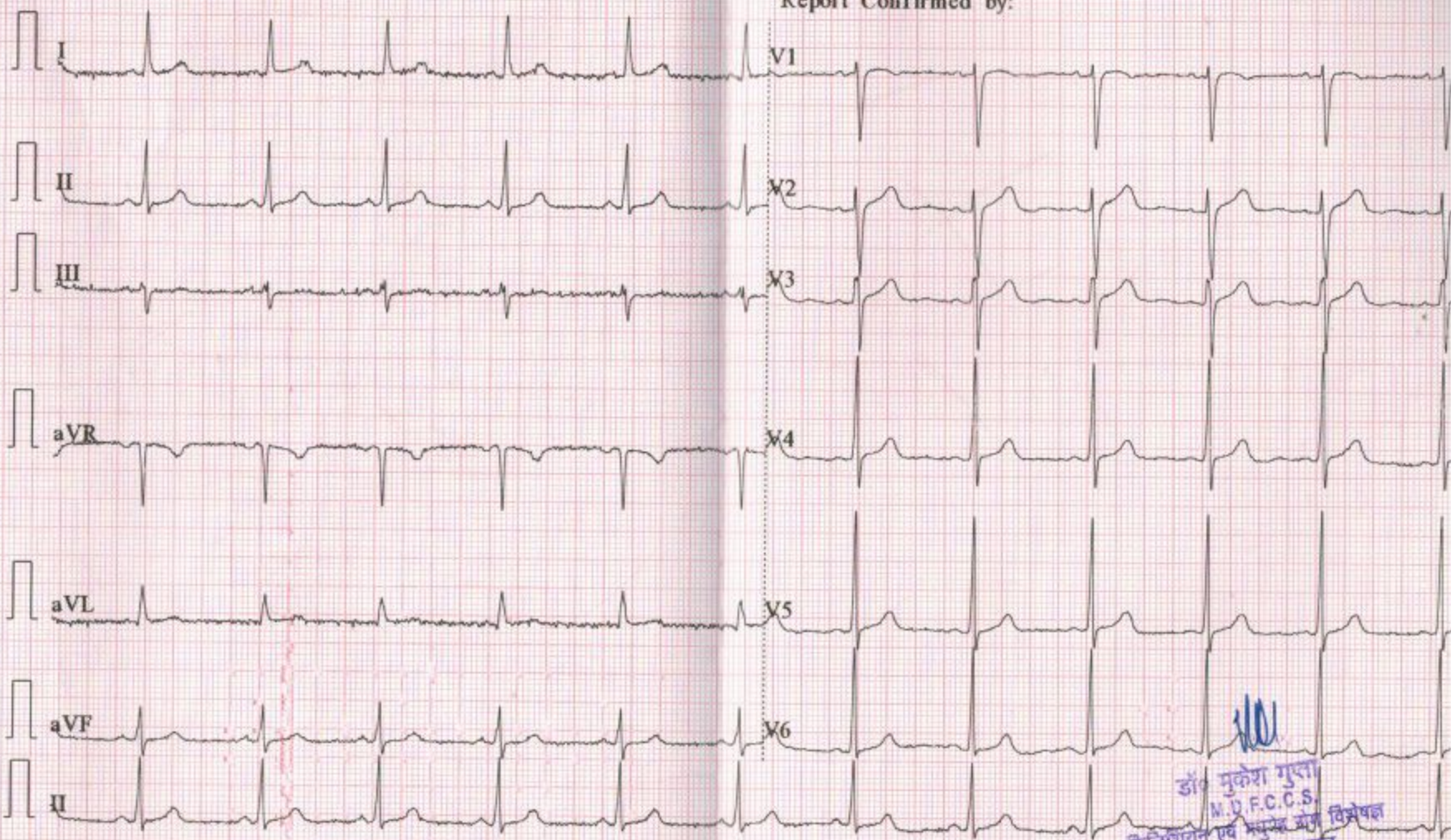
ID: 1

Female Years

HR : 72 bpm
 P : 100 ms
 PR : 132 ms
 QRS : 90 ms
 QT/QTc : 361/396 ms
 P/QRS/T : 59/19/36 °
 RV5/SV1 : 2.025/1.211 mV

Diagnosis Information:
 Sinus Rhythm
 Normal ECG

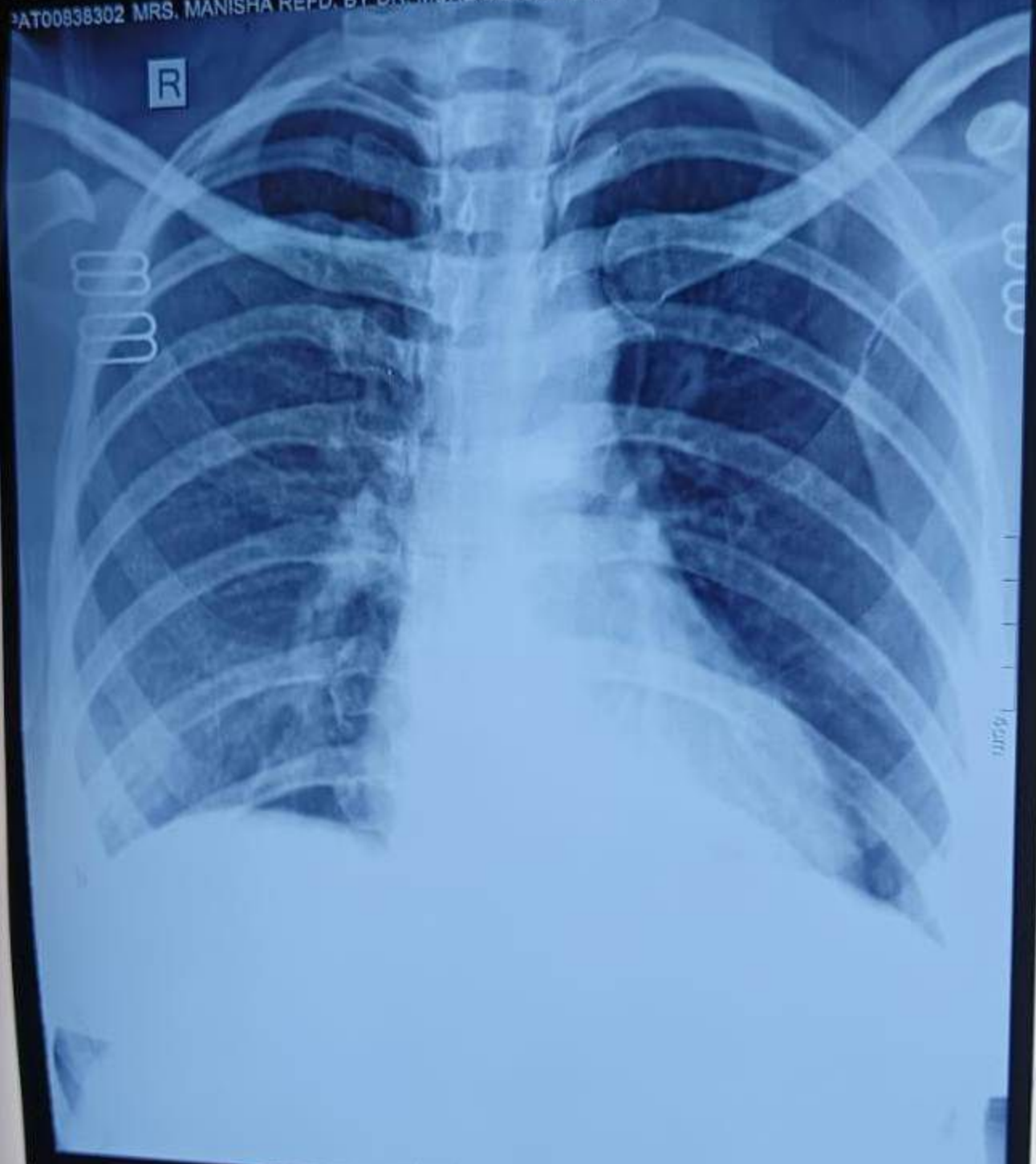Report Confirmed by:



डॉ० मुकेश गुप्ता
 M.D.F.C.C.S.
 फिजिशियन एवं प्रमुख अति विशेषज्ञ
 दक्ष हॉस्पिटल, अजमेर
 रजि० नं०-5423/16262

AT00938302 MRS. MANISHA REFD. BY DR. MUKESH GUPTA MD CHEST 24.03.2024

R



VIJAY DIAGNOSTIC CENTRE 1/18 KALA KUAN .ALWAR

2337