

MEDICAL HEALTH CHECK- UP ASSESSMENT FORM

NAME : Mr / Mrs ✓ Vaibhav Agwal

DATE: 4/5/24

AGE: 22yrs

SEX: Male / Female

NMU: NMU000 52297

DOCTOR'S NAME:
Health-Package

TEMP :	<u>98</u>	° f	BP :	<u>133/77</u>	mmHg
PULSE :	<u>67</u>	b/m	HEIGHT :	<u>178.5</u>	cm
RR :	<u>18</u>	b/m	WEIGHT :	<u>68.8</u>	kg
SPO2 :	<u>99</u>	% RA	HGT:	<u>—</u>	

REMARK:

MEDICAL CERTIFICATE

I, Dr. Ahmed Khan.....do hereby certify that I have carefully examined .

Sri./Smt. Vaibhav..... , son / daughter.

Of Girraj..... is physically fit / unfit to join Organization .

Signature of Doctor: 

Registration No :

Dr. AHMED KHAN
MBBS, MD (Internal Medicine)
Reg. No. MMC 2015/01/0236

Place : Ichanghar.....

Date : 04/12/24.....

Seal :



DEPARTMENT OF LABORATORY

NAVI MUMBAI

Patient Name : Mr. VAIBHAV AGIWAL	Age /Gender : 22 Y(s)/Male
Bill No/ UMR No : NMBC68836/NMU0052297	Referred By : Dr. DMO
Received Dt : 04-May-24 10:49 am	Report Date : 04-May-24 04:50 pm

FINAL REPORT

<u>Parameters</u>	<u>Specimen</u>	<u>Result</u>	<u>Biological Reference Intervals</u>	<u>Method</u>
CUE(COMPLETE URINE EXAMINATION)				
<u>PHYSICAL EXAMINATION</u>				
VOLUME	Urine	30 ml		
COLOUR		PALE YELLOW	PALE YELLOW	
APPEARANCE		SLIGHTLY HAZY	CLEAR	
DEPOSIT		ABSENT	ABSENT	
<u>CHEMICAL EXAMINATION</u>				
SPECIFIC GRAVITY	Urine	1.010	1.000 - 1.030	Dipstick
PH		6.5	5.0 - 8.0	Dipstick
PROTEIN		NEGATIVE	NEGATIVE	Dipstick/Heat coagulation test
GLUCOSE		ABSENT	ABSENT	Dipstick/Benedict's test
UROBILINOGEN		NORMAL	NORMAL	Dipstick
KETONE		NEGATIVE	NEGATIVE	Dipstick/Rothera's Nitroprusside test.
BILIRUBIN		NEGATIVE	NEGATIVE	Dipstick/Fouchet's test
BILE SALT		NEGATIVE	NEGATIVE	Hay's sulphur powder test
BILE PIGMENT		NEGATIVE	NEGATIVE	Fouchet test
NITRITE		NEGATIVE	NEGATIVE	Dipstick
LEUCOCYTE ESTERASE		NEGATIVE	NEGATIVE	
<u>MICROSCOPIC EXAMINATION</u>				
PUS CELLS	Urine	NIL	0 - 5 /hpf	MICROSCOPIC EXAMINATION
RBC		1-2	0 - 5 /hpf	MICROSCOPIC EXAMINATION
EPITHELIAL CELLS		NIL	0 - 5 /hpf	MICROSCOPIC EXAMINATION
CRYSTALS		Occasional	NIL	MICROSCOPIC EXAMINATION
CASTS		NIL	NIL	MICROSCOPIC EXAMINATION
BACTERIA		ABSENT		MICROSCOPIC EXAMINATION
YEAST		ABSENT		MICROSCOPIC EXAMINATION
AMORPHOUS DEPOSITS		ABSENT		MICROSCOPIC EXAMINATION
SPERMATOZOA				MICROSCOPIC EXAMINATION
MUCUS THREAD		ABSENT		MICROSCOPIC EXAMINATION
NOTE		Microscopic examination of urine is carried out on centrifuged urinary sediment.		





MEDICOVER HOSPITALS

DEPARTMENT OF LABORATORY

NAVI MUMBAI

Patient Name : Mr. VAIBHAV AGIWAL	Age / Gender : 22 Y(s)/Male
Bill No/ UMR No : NMBC68836/NMU0052297	Referred By : Dr. DMO
Received Dt : 04-May-24 10:49 am	Report Date : 04-May-24 04:50 pm

Parameters

Specimen

Result

Biological Reference In Method

*** End Of Report ***





DEPARTMENT OF LABORATORY

NAVI MUMBAI

Patient Name : Mr. VAIBHAV AGIWAL	Age / Gender : 22 Y(s)/Male
Bill No/ UMR No : NMBC68836/NMU0052297	Referred By : Dr. DMO
Received Dt : 04-May-24 10:49 am	Report Date : 04-May-24 03:34 pm

FINAL REPORT

<u>Parameters</u>	<u>Specimen</u>	<u>Result</u>	<u>TUBE AGGLUTINATI</u>
BLOOD GROUPING AND RH			
BLOOD GROUP	Blood	" A "	TUBE AGGLUTINATION
RH TYPE		POSITIVE	

*** End Of Report ***





DEPARTMENT OF LABORATORY

NAVI MUMBAI

Patient Name : Mr. VAIBHAV AGIWAL	Age /Gender : 22 Y(s)/Male
Bill No/ UMR No : NMBC68836/NMU0052297	Referred By : Dr. DMO
Received Dt : 04-May-24 10:49 am	Report Date : 04-May-24 03:45 pm

FINAL REPORT

<u>Parameters</u>	<u>Specimen</u>	<u>Result</u>	<u>Biological Reference Intervals</u>	<u>Method</u>
FBS (FASTING BLOOD GLUCOSE)				
FASTING BLOOD GLUCOSE		87	Normal Range : 70 - 99 mg/dL	Hexokinase
SERUM CREATININE				
CREATININE		0.85	0.8 - 1.3 mg/dl	Method : jaffe
BUN(BLOOD UREA NITROGEN)				
BUN (Blood Urea Nitrogen.)		8	7.0 - 21.0 mg/dL	Calculated
SGPT (ALT)		11	<= 41 U/L	Method : UV without P5P
SERUM BILIRUBIN TOTAL				
DIRECT BILIRUBIN		0.2	0.2 - 1.3 mg/dL	Jendrassik Grof
INDIRECT BILIRUBIN		0.4	<= 0.20 mg/dL	Method: Diazo Method
PLBS (POST LUNCH BLOOD GLUCOSE)				
		96	Norma Range : - < 140 mg/dL Impaired Glucose Tolerance : 140 - 199 mg/dL Diabetes Mellitus : - > 200 mg/dL	Hexokinase

*** End Of Report ***

Lab Incharge

Dr. VISHAL MEHROTRA, MD Pathology
Head, Laboratory Services

Verified By : : 022633

Test results related only to the item tested.

No part of the report can be reproduced without written permission of the laboratory.





MEDICOVER HOSPITALS

DEPARTMENT OF LABORATORY

NAVI MUMBAI

Patient Name : Mr. VAIBHAV AGIWAL	Age / Gender : 22 Y(s)/Male
Bill No/ UMR No : NMBC68836/NMU0052297	Referred By : Dr. DMO
Received Dt : 04-May-24 10:49 am	Report Date : 04-May-24 01:25 pm

FINAL REPORT

<u>Parameter</u>	<u>Specimen</u>	<u>Result Values</u>	<u>Biological Reference</u>	<u>Method</u>
COMPLETE BLOOD COUNT				
RBC				
R B C COUNT	Blood	4.18	4.5 - 5.5 $10^6/\mu\text{L}$	
HEMOGLOBIN		13.8	13.0 - 17.0 g/dl	
PCV/HCT		41.9	40 - 50 % 36 - 46 %	
MCV		100	83 - 101 fl 83 - 101 fl	
MCH		33.1	27 - 32 pg	
MCHC		33.0	31.5 - 34.5 g/dL	
RDW(cv)		12.1	11.6 - 14.0 %	
PLATELETS				
PLATELET COUNT	Blood	273	150 - 400 $10^3/\mu\text{L}$	
MPV		8.3	7.5 - 11.5 fl	
WBC				
TC (TOTAL LEUCOCYTE COUNT)	Blood	7.5	4.0 - 11.0 $10^3/\mu\text{l}$	
DIFFERENTIAL COUNT				
NEUTROPHILS	Blood	59	40 - 80 %	
LYMPHOCYTES		28	20 - 40 %	
MONOCYTES		05	02 - 10 %	
EOSINOPHILS		08	00 - 06 %	
BASOPHILS		00	00 - 01 %	
ESR	CITRATED BLOOD	06	0 - 10 mm/1st hour	WESTERGREN'S METHOD

*** End Of Report ***

Lab Incharge

Vishal Mehrotra
Dr. VISHAL MEHROTRA, MD Pathology
Head, Laboratory Services

Verified By : : 029855

Test results related only to the item tested.

No part of the report can be reproduced without written permission of the laboratory.



Patient ID:	NMU0052297	Patient Name:	VAIBHAV AGIWAL
Age:	22 Years	Sex:	M
Accession Number:	NMBC68836	Modality:	DX
Referring Physician:	DR.DMO	Study:	CHEST
Study Date:	04-May-2024	Study Time:	11:31:45

X RAY CHEST PA VIEW

Both lungs are clear.

The frontal cardiac dimensions are normal.

The pleural spaces are clear.


Both hilar shadows are normal in position and density.

no diaphragmatic abnormality is seen.

The soft tissues and bony thorax are normal.

Impression:

No significant abnormality is seen.



DR. ANUPKUMAR AGRAWAL
Consultant & HOD Radiology
MBBS, MD

Date: 04-May-2024 12:38:56

Rate 75 . Sinus rhythm.....normal P axis, V-rate 50- 99
. ST elev, probable normal early repol pattern.....ST elevation, age<55
PR 132
QRSD 91
QT 371
QTc 415

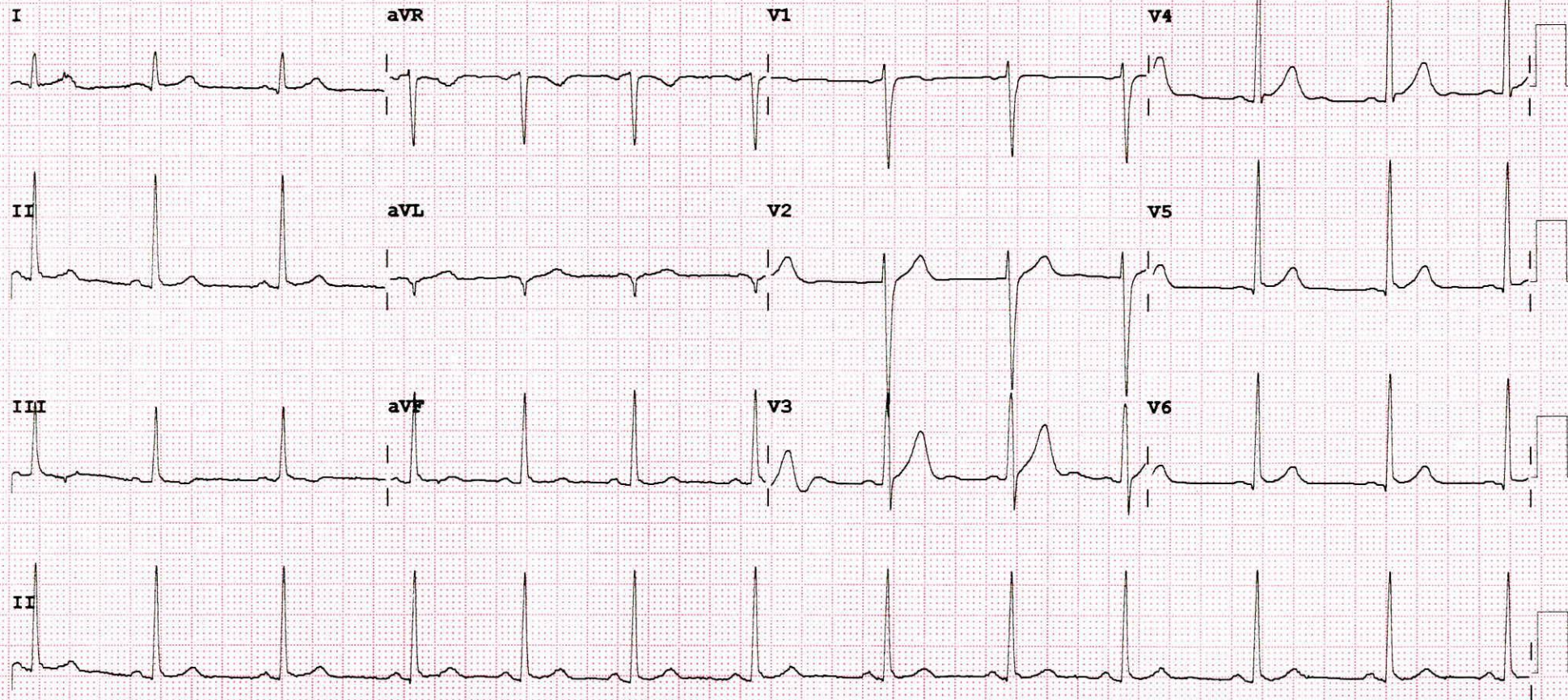
--AXIS--

P 47
QRS 70
T 28

- NORMAL ECG -

12 Lead; Standard Placement

Unconfirmed Diagnosis





DEPARTMENT OF OPHTHALMOLOGY

MEDICOVER HOSPITALS

DATE: 04/05/24
 PATIENT NAME: Mrs Vaibhaw Agiwal AGE / SEX: 22/f NAVI MUMBAI
 UMR NO: N0000052297

	RE	LE
VA (DISTANCE) 20/30	6/6	6/6
VA (NEAR) 20/30	NG	NG
COLOUR VISION	Normal	Normal

		SPHERE	CYLINDER	AXIS	VA
MRx	O D (R)	-3.00	-0.50	180°	6/6, 20/30
	O S (L)	-3.25	-1.00	175°	6/6, 20/30

HISTORY :

- H/O using spectacles for Distance
 - No H/O DM, HTN, Thyroid
 - No H/O ocular fundus Atresia & Surzenis.

OCULAR FINDINGS :

(BE) - Ant seg WNL (BE) Mod. myopia
 (undilated) Disc < 0.3
 0.2-0.3

ADVICE:

Refresh Tears 4x4 qid 1777 X 1 month
 Fundoscopy 1/10 Myopia

Mon-Fri - 10am to 2pm

AS
 CDR. ANUSHREE VANUARY



04/12/20

Vaibhav Gogwal 21/A

Routine check-up.

no complaints


no morbidity.

vitals stable



MEDICOVER
HOSPITALS

NAVI MUMBAI


Dr. AHMED KHAN
MBBS, MD (Internal Medicine)
Reg. No. MMC 2015/01/0236

