

DAKSH HOSPITAL

396 - 397, Gandhi Nagar, Scheme No. 8, ALWAR -301001

Ref. No.

Date.....

MEDICAL EXAMINATION REPORT

Mediwheel (BOB)

Name: Mr. Hemant Kumar

Age: 38 yrs

Sex: Male

Date: 23-03-2024

General Physical Examination

Height : 176 cm
Pulse : 89 mt
Respiration : 18/mt

Weight : 71.4 kg
BP : 120/80 mm/hg
BMI : 23.1 kg/m²

Systemic Exam:-

NORMAL - Performed xanthomas
- RS - 12mt wms (P)

Dental Check up:-

NORMAL

Eye check-up:-

NORMAL

Skin Check up:-

NORMAL

ENT Check up:-

NORMAL

Impression:-

* ECG - Short PR
* F20S (TCL 670) E-11-3%
* SPT 44
* TSH 6.0

Recommendation:-

Plan
• Rmt TSH After 1 month - TSH FT3/FT4
• OR AntitPO Ab -
• Better control Asthma
• PFT
• Life style modification - diet/exercise
Morning walk

Dr. Mukesh Kumar Gupta
MD Gen. Medicine
Reg. No 5423/16262

डॉ० मुकेश गुप्ता
M.D.F.C.C.S.
फिजिशियन एवं मधुमेह रोग विशेषज्ञ
दक्ष हॉस्पिटल, अलवर
रजि० नं०-5423/16262

Results

Run Date 23/03/2024 09:27:38 AM

Operator DAKSH

Last Name

Sample ID 3

First Name MR HEMANT KUMAR

Department

Gender Male Age

Physician DR. MUKESH GUPTA M.D

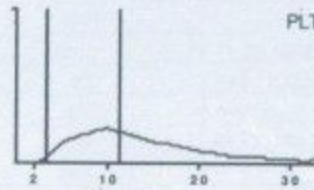
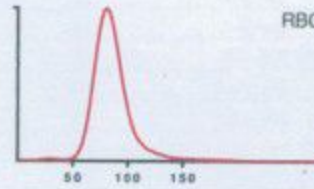
Patient ID AUTO_PID20437

Type Man

Date of birth

Sample comments

			Range
RBC	5.41	10 ⁶ /μL	3.80 - 5.50
HGB	15.2	g/dL	13.0 - 17.0
HCT	46.4	%	39.0 - 52.0
MCV	85.8	μm ³	76.0 - 100.0
MCH	28.2	pg	26.0 - 34.0
MCHC	32.8	g/dL	32.0 - 35.0
RDW-CV	15.4	%	11.0 - 16.0
RDW-SD	52.1	h μm ³	37.0 - 49.0
			Range
PLT	186	* 10 ⁹ /μL	150 - 450
PCT	0.24	* %	0.15 - 0.40
MPV	13.1	H* μm ³	8.0 - 11.0
PDW	24.1	h* μm ³	11.0 - 22.0
P-LCC	101	10 ³ /μL	44 - 140
P-LCR	54.2	h %	18.0 - 50.0



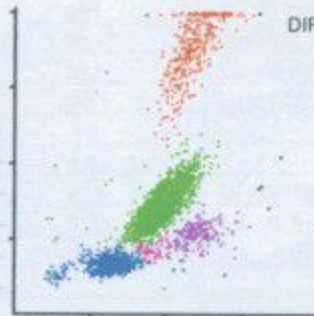
Recommended actions

Slide review

Susp. Pathologies

Macroplatelets

			Range	
WBC	5.94	10 ³ /μL	3.50 - 10.00	
	#	Range	%	Range
NEU	3.64	1.60 - 7.00	61.4	40.0 - 75.0
LYM	1.42	1.00 - 3.00	24.0	20.0 - 45.0
MON	0.11	0.20 - 0.80	1.8	2.0 - 10.0
EOS	0.67	0.00 - 0.50	11.3	1.0 - 6.0
BAS	0.09	0.00 - 0.15	1.5	0.0 - 1.0
LIC	0.01	0.00 - 0.10	0.2	0.0 - 1.0



Dr. R.S. Gupta

Dr. R.S. GUPTA
MD (Pathology) (MAHE)
RMC No. 7924/19778

Date :- 23/03/2024

Name :- MR. HAMENT KUMAR

Age & Sex :- 38 Yrs/ male

Refd. :- Dr Mukesh Gupta M.D.

	TEST NAME	RESULT	REFERENCE RANGE	
	ESR	13	00 -20 mm/hrs	
	Blood Group & Rh Factor	B ⁺ POSITIVE		
	HbA1C	4.95	4 - 5.6%	
	Blood Sugar (F)	91.1	< 70 - 100 mg/dl	
	Blood Sugar (PP)	-	< 140 mg/dl	
	Urine Sugar (F)	-	-	
	Urine Sugar (PP)	-	-	
LIVER	S.Bilirubin Total	1.1	0.30 - 1.20 mg/dl	
	S.Bilirubin Direct	0.4	0.10 - 0.30 mg/dl	
	S.Bilirubin Indirect	0.7	0.30 - 0.90 mg/dl	
	S.G.O.T.	36	> 37 u/l	
	S.G.P.T.	44	> 40 u/l	
	S.Aik. Phosp.	187	80 - 306 u/l	
	G.G.T.	22.1	5 -40 u/l	
	Total Protein	6.7	6.5 - 8.5 gm/dl	
	Albumin	3.6	3.8 - 5.4 gm/dl	
	Globulin	3.1	2.3 - 3.5 gm/dl	
	A/G Ratio	1.2	-	
	AST/ALT Ratio	0.81	-	
KIDNEY	Blood Urea	28.1	15 -45 mg/dl	
	S.Creatinine	1.2	0.60 - 1.30 mg/dl	
	BUN	17.1	6 -24 mg/dl	
	S.Uric Acid	5.6	M 3.1 - 7.0, F 2.5 - 5.6 mg/dl	
	BUN/Creatinine Ratio	14.1	-	
	Total Cholesterol	180.1	Up to 200 mg/dl	
LIPID PROFILE	S.HDL	44.1	30 - 70 mg/dl	
	S.LDL	89.1	Up to 170 mg/dl	
	S.VLDL	50.1	5.0 - 40 mg/dl	
	S. Triglycerides	250.1	Up to 170 mg/dl	
	LDL/HDL Ratio	1.9	-	
	Total Cholesterol/ HDL Ratio	4.9	-	
THYROID	T3	95.1	40 - 181 ng/dl	
	T4	6.50	4.6 - 10.5 µg/dl	
	TSH	6.02	0.30 - 5.0 mIU/l	
URINE EXAMINATION			<i>Microscopic Examination:</i>	
General/Chemical Examination:	Colour	Pale Yellow	RBC	Absent
	Reaction	Acidic	WBC	1-2
	Specific Gravity	QNS	Epithelial Cells	Absent
	Appearance	Clear	Cast	Absent
	Albumin	Nil	Crystal	Absent
	Sugar	Nil	Spermatozoa	Absent
			Amorphous Sediments	Absent
		Other	Absent	
X-RAY CHEST	NORMAL STUDY			
STOOL EXAMINATION			<i>Microscopic Examination:</i>	
General/Chemical Examination:	Colour	BRONISH	RBC	NIL
	Consistency	SOLID	WBC	NIL
			Ova & Parasites	NIL

Dr. R.S. GUPTA
Pathology (MAHE)
Doc# 024/19778

TECHNOLOGIST

All investigation have their own limitations regarding the sensitivity & specificity of individual assay procedures, Isolated laboratory investigations never confirm the final diagnosis of the disease. They only help in arriving at a diagnosis in conjunction with clinical presentation and other related investigations. Report is not valid for medico-legal purpose subject to ALWAR jurisdiction only.



दक्ष हॉस्पिटल

396, गाँधी नगर स्कीम नं.8, अलवर (राज०) ☎ 0144-2703340

Sonography / 2D Echo Cardiography / Doppler Report

2D/ ECHO REPORT

Name: - Mr Hemant Kumar

Age: - 38 Yrs

Date: - 23-Mar-24

Reg. No.: - Alw/2009/04
BOB health checkup

PROCEDURES:

M-MODE/2D/DOPPLER/COLOR/CONTRAST B.A.S. M²


MEASUREMENT:		NORMAL		DOPPLER:		NORMAL (cm/sec.)	
AOD	26	(20- 37mm)	MV	0.6	(0.8- 1.3)	MR	No
LA	23	(19- 40mm)	AV	1.4	(1.2- 1.8)	AR	No
AVO	18	(12- 25mm)	TV	0.6	(0.3- 0.8)	TR	No
RVDD	11.6	(03- 09mm)	PV	0.8	(0.7- 1.1)	PR	No
LVDd	47	(37- 56mm)	MITRAL VALVE-				
LVDs	28.5	(22- 40mm)		AML		Normal	
IVS d	6.5	(06- 12mm)		PML		Normal	
IVS s	8						
PWd	3	(05- 10mm)	AORTIC VALVE			Normal	
LV FUNCTION			TV & PV are normal.				
M- E- S Separation		<0.9cm					
Minor		24.42%					
LV Ejection Fraction	70%	65 +/- 12%					

LV WALL MOTION: NO RWMA
ALL CARDIAC CHAMBERS ARE NORMAL
ALL VALVES ARE NORMAL
NO CLOT, VEGETATION, PERICARDIAL EFFUSION

FINAL DIAGNOSIS: NORMAL STUDY

Adv: - Follow up/ review at higher center for confirmation

Note:- Please Correlate clinically. Due to technical limitations as well as inaccuracies inherent in the laboratory and statistical analysis of biological process. Diagnostic accuracy of ECHO is up to 95% only.
Report is not valid for medico-legal purpose.


Dr. Mukesh Kumar Gupta
PHYSICIAN
RM 5423716262



श्री लिंग परीक्षण की शिकायत
104 टोल फ्री सेवा पर भी की

जा सकती है।
श्री लिंग परीक्षण की शिकायत 104 टोल फ्री सेवा पर भी की जा सकती है।



दक्ष हॉस्पिटल

396, गाँधी नगर स्कीम नं.8, अलवर (राज०) ☎ 0144-2703340

Sonography / 2D Echo Cardiography / Doppler Report

Name: MR. HEMANT KUMAR /M/38 YRS

Date: 23-Mar-24

BOB HEALTH CHECK UP

U.S.G. OF ABDOMEN & PELVIS

LIVER

Liver is **14.8 cm at MCL** with normal echo-texture. Intra hepatic biliary radicals are not dilated. No evidence of focal or diffuse lesion.

GALL BLADDER

Gall bladder is normal dilated. Lumen clear. Wall thickness normal. CBD normal

PANCREAS

Pancreas is normal in size, shape & echo-texture.

SPLEEN

9.5 cm in size with normal shape & echo- texture.

BOTH KIDNEY

Both kidney normal shape, size & echo texture. CMD maintained

PROSTATE is normal shape, size & echo texture..

URINARY BLADDER well distended, visualized lumen appear clear.

Advice- X Ray KUB / URINE EXAM

Please correlate clinically. USG accuracy is 95 % due to technical limitations as well as inaccuracies inherent in the laboratory and statistical analysis biological process.

This report is not valid for medico-legal cases.


Dr. Mukesh Kumar Gupta
SONOLOGIST
Physician & Sonologist
RM 5423/16262



"भ्रूण लिंग परीक्षण की शिकायत
104 टोल फ्री सेवा पर भी की
जा सकती है"

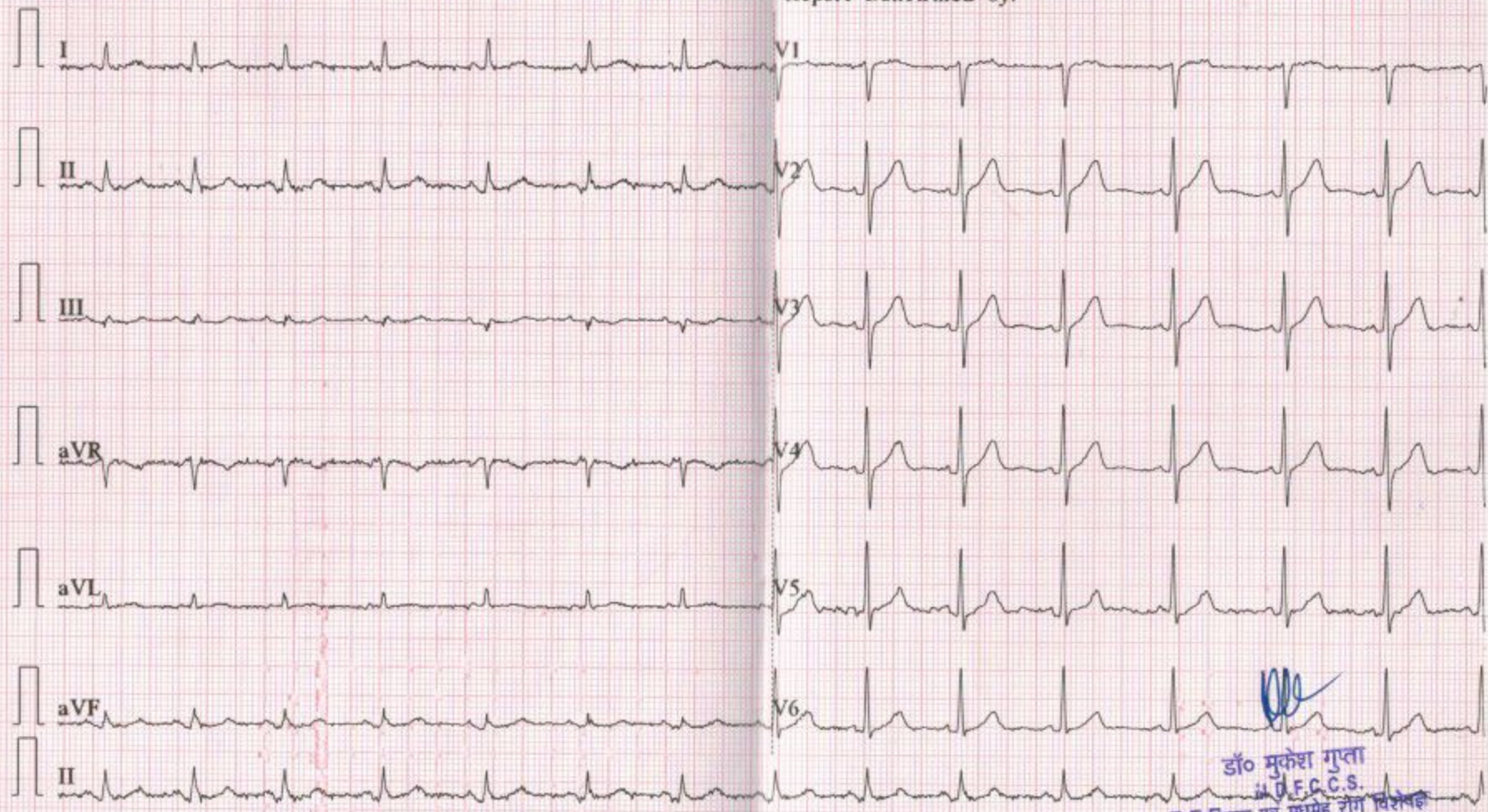
भ्रूण लिंग परीक्षण की शिकायत 104 टोल फ्री सेवा पर भी की जा सकती है।

male Years

HR	:	88	bpm
P	:	78	ms
PR	:	113	ms
QRS	:	84	ms
QT/QTc	:	342/416	ms
P/QRST	:	66/36/52	°
RV5/SV1	:	1.179/0.689	mV

Diagnosis Information:
 Sinus Arrhythmia
 Short PR Interval

Report Confirmed by:



डॉ० मुकेश गुप्ता
 M.D., F.C.C.S.
 फिजिशियन एव मधुमेह रोग विशेषज्ञ
 दस हॉस्पिटल, अलवर
 रजि० नं०-5423/16262

R

