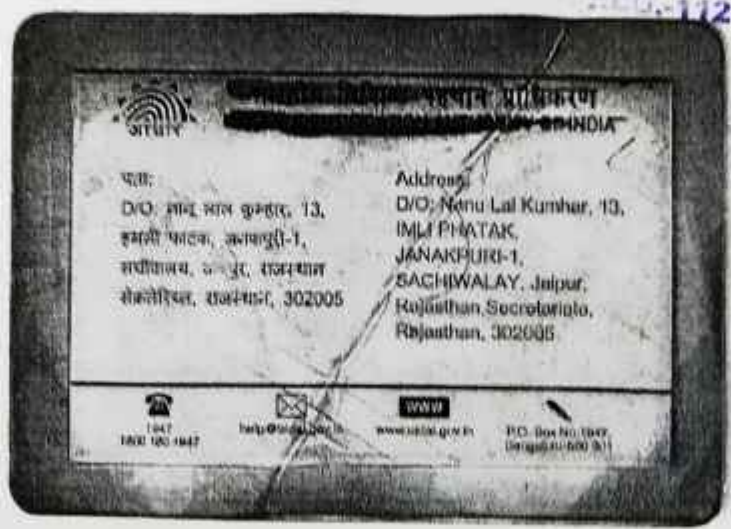




Handwritten signature in blue ink.

Handwritten signature in blue ink.
M. No. 11212



Dr. VIKRAM SINGH
M.D. (RADIO DIAGNOSIS)
R.M.C. REG.-11212



CARE DIAGNOSTIC AND IMAGING CENTER

A-7, Hanuman Nagar, Near HDFC Bank, Main Khatipura Road, Jaipur - 302021
Ph.: 0141-4025102 • E-mail : carecenterjaipur@gmail.com

General Physical Examination

Date of Examination: 24-03-2024

Name: RENU PRASAPATI Age: 33ye DOB: 08-09-1990 Sex: F

Referred By: BANK OF BARODA

Photo ID: ADHAR CARD ID #: 4290

Ht: 166 (cm)

Wt: 68 (Kg)

Chest (Expiration): 94 (cm)

Abdomen Circumference: 83 (cm)

Blood Pressure: 120/75 mm Hg

PR: 74 /min

RR: 18 /min

Temp: Afebrile

BMI _____

Eye Examination: R/E] 6/6, N/6, NCB
L/E] 6/6, N/6, NCB

Other: N/A

On examination he/she appears physically and mentally fit: Yes / No

Signature Of Examinee:

Name of Examinee: RENU PRASAPATI

Signature Medical Examiner:

Name Medical Examiner: Dr. Vikram Singh

Dr. VIKRAM SINGH
M.D. (RADIOLOGYSIS)
R.M.C. REG.-11212



CARE DIAGNOSTIC AND IMAGING CENTER

A- 7, Hanuman Nagar, Near HDFC Bank, Main Khatipura Road, Jaipur - 302021
Ph.: 0141-4025102 • E-mail : carecenterjaipur@gmail.com

Patient Name	Mrs RENU PRAJAPATI	Lab Regn No	05317
Age & Sex	33 Years , Female	Registration Date	24/03/2024 09:56
Referred by	BANK OF BARODA	Reporting Date	26/03/2024 18:49


BIOCHEMISTRY

FULL BUDDY ANNUAL PLUS CHEK

TEST NAME	RESULT	UNIT	NORMAL RANGE
CBC WITH ESR			
Hb%	13.3	gms/dl	12 - 16 gms/dl
TLC	5.50	Th/mm ³	4.5 - 11 Th/mm ³
DLC			
Neutrophils	60	%	40 - 75 %
Lymphocytes	35	%	20 - 40 %
Eosinophils	03	%	01 - 06 %
Monocytes	02	%	02 - 10 %
Basophils	00	%	00 - 01 %
TRBC	4.77	mil/cu-mm	4.5 - 5.5 mil/cu-mm
Platelet Count APC	1.78	lakh/mm ³	1.5 - 4.5 lakh/mm ³
PCV	39.2	%	42 - 52 %
MCV	82.2	fl	82 - 94 fl
MCH	27.9	pg	27 - 32 pg
MCHC	33.9	g/lt	32 - 36 g/lt
ESR	08	mm/1Hr	4 - 20 mm/1Hr

Continued on Next Page...

Technologist


Dr. Nirish Agarwal
Pathologist
RMC No 12512

This is radiological / Pathological Impression & not the final Diagnosis. It should be Correlated with relevant clinical data & Investigation
Not Valid for Medico-Legal Purpose • Subject to Jaipur Jurisdiction only.



CARE DIAGNOSTIC AND IMAGING CENTER

A- 7, Hanuman Nagar, Near HDFC Bank, Main Khatipura Road, Jaipur - 302021
Ph.: 0141-4025102 • E-mail : carecenterjaipur@gmail.com

Patient Name **Mrs RENU PRAJAPATI**
Age & Sex **33 Years , Female**
Referred by **BANK OF BARODA**

Lab Regn No **05317**
Registration Date **24/03/2024 09:56**
Reporting Date **26/03/2024 18:49**

BIOCHEMISTRY

FULL BUDDY ANNUAL PLUS CHEK

TEST NAME	RESULT	UNIT	NORMAL RANGE
Blood Group	"A" Positive		
Blood Sugar Fasting	75.0	mg/dl	65 - 110 mg/dl
Blood Sugar PG 2.00 Hr	97.9	mg/dl	80 - 145 mg/dl
LIPID PROFILE PANEL			
Triglycerides	98.30	mg/dl	Upto -160 mg/dl
Serum Cholesterol	165.20	mg/dl	Upto - 200 mg/dl
HDL Cholesterol	38.60	mg/dl	35 - 70 mg/dl
LDL Cholesterol	106.94	mg/dl	Upto - 130 mg/dl
VLDL Cholesterol	19.66	mg/dl	Upto - 60 mg/dl
CHOL/HDL RATIO	4.27	mg/dl	3.3-4.4 Low Risk 4.5-7.0 Avg.Risk 7.1-11.0 Mod.Risk >11.0 High Risk
LDL/HDL RATIO	2.77	mg/dl	0.5-3.0 Low Risk 3.1-6.0 Mod.Risk > 6.0 High Risk

Continued on Next Page...

Technologist

Dr. Nirish Agarwal
Pathologist
RMC No 12512

This is radiological / Pathological Impression & not the final Diagnosis. It should be Correlated with relevant clinical data & Investigation
Not Valid for Medico-Legal Purpose • Subject to Jaipur Jurisdiction only.



CARE DIAGNOSTIC AND IMAGING CENTER

A- 7, Hanuman Nagar, Near HDFC Bank, Main Khatipura Road, Jaipur - 302021

Ph.: 0141-4025102 • E-mail : carecenterjaipur@gmail.com

Patient Name **Mrs RENU PRAJAPATI**

Lab Regn No **05317**

Age & Sex **33 Years , Female**

Registration Date **24/03/2024 09:56**

Referred by **BANK OF BARODA**

Reporting Date **27/03/2024 16:51**

BIOCHEMISTRY

FULL BUDDY ANNUAL PLUS CHEK

TEST NAME	RESULT	UNIT	NORMAL RANGE
Uric Acid	3.66	mg/dl	2.4 - 5.7 mg/dl
Blood Urea Nitrogen - BUN	11.30	mg/dl	0 - 20 mg/dl
Creatinine	0.78	mg/dl	0.5 - 1.4 mg/dl
Protein/Creatinine Ratio	14.48		

LIVER FUNCTION TEST - LFT

Bilirubin			
Total	0.61	mg/dl	0.20 - 1.2 mg/dl
Direct	0.18	mg/dl	0.1 - 0.3 mg/dl
Indirect	0.43	mg/dl	0.2 - 0.9 mg/dl
SGOT	22.66	U/L	5 - 45 U/L
SGPT	19.55	U/L	6 - 45 U/L
Total Protein	6.99	gm/dl	6.0 - 8.3 gm/dl
Albumin	4.01	gm/dl	3.0 - 5.0 gm/dl
Globulin	2.98	gm/dl	2.0 - 3.0 gm/dl
A/G Ratio	1.34:1	mg/dl	1.0:1 - 2.5:1 mg/dl
Alkaline Phosphatase	166.30	IU/L	100 - 300 IU/L
Gamma GT	21.58	U/L	5 - 32 U/L

Continued on Next Page...

Technologist

Dr. Nirish Agarwal
Pathologist
RMC No 12512



CARE DIAGNOSTIC AND IMAGING CENTER

A- 7, Hanuman Nagar, Near HDFC Bank, Main Khatipura Road, Jaipur - 302021

Ph.: 0141-4025102 • E-mail : carecenterjaipur@gmail.com

Patient Name **Mrs RENU PRAJAPATI**

Age & Sex **33 Years , Female**

Referred by **BANK OF BARODA**

Lab Regn No **05317**

Registration Date **24/03/2024 09:56**

Reporting Date **27/03/2024 16:51**

HAEMATOLOGY

Glycosylated Haemoglobin (HBA1c)

TEST NAME	RESULT	UNIT	NORMAL RANGE
-----------	--------	------	--------------

HBA1C - INSURANCE

HBA1c 5.1 %

REFERENCE RANGE

Normal Value	:	<	06.0 %
Good Control	:	6.0 % -	07.0 %
Fair Control	:	7.0 % -	08.0 %
Unsatisfactory Control	:	8.0 % -	10.0 %
Poor Control	:	>	10.0 %

-- End of Report --

Technologist

Dr. Nirish Agarwal
Pathologist
RMC No 12512

This is radiological / Pathological Impression & not the final Diagnosis. It should be Correlated with relevant clinical data & Investigation
Not Valid for Medico-Legal Purpose • Subject to Jaipur Jurisdiction only.



CARE DIAGNOSTIC AND IMAGING CENTER

A- 7, Hanuman Nagar, Near HDFC Bank, Main Khatipura Road, Jaipur - 302021
Ph.: 0141-4025102 • E-mail : carecenterjaipur@gmail.com

Patient Name **Mrs RENU PRAJAPATI**
Age & Sex **33 Years , Female**
Referred by **BANK OF BARODA**

Lab Regn No **05317**
Registration Date **24/03/2024 09:56**
Reporting Date **27/03/2024 16:51**

HORMONES & MARKERS

Thyroid Profile

TEST NAME	RESULT	UNIT	NORMAL RANGE
T3	1.56	ng/ml	0.60 - 1.78 ng/ml
T4	7.89	µg/dl	4.50 - 12.23 µg/dl
TSH	2.20	µIU/ml	0.35 - 4.94 µIU/ml

-- End of Report --

Technologist

Dr. Nirish Agarwal
Pathologist
RMC No 12512

This is radiological / Pathological impression & not the final Diagnosis. It should be Correlated with relevant clinical data & Investigation
Not Valid for Medico-Legal Purpose • Subject to Jaipur Jurisdiction only.



CARE DIAGNOSTIC AND IMAGING CENTER

A- 7, Hanuman Nagar, Near HDFC Bank, Main Khatipura Road, Jaipur - 302021
Ph.: 0141-4025102 • E-mail : carecenterjaipur@gmail.com

Patient Name **Mrs RENU PRAJAPATI**
Age & Sex **33 Years , Female**
Referred by **BANK OF BARODA**

Lab Regn No **05317**
Registration Date **24/03/2024 09:56**
Reporting Date **26/03/2024 18:49**

BIOCHEMISTRY

FULL BUDDY ANNUAL PLUS CHEK

TEST NAME	RESULT	UNIT	NORMAL RANGE
URINE ROUTINE EXAMINATION			
Physical			
Colour	Pale Yellow		
Clarity	Clear		
Chemical			
Specific Gravity	1.020		
pH	5.5		
Albumin	NIL		
Sugar	NIL		
Microscopic			
RBC	NIL		
WBC	1-2/HPF		
Epithelial Cells	0-1/HPF		
Casts	NIL		
Crystal	NIL		
Bacteria	NIL		
Others	NIL		

Chy
Continued on Next Page...

Technologist

Nirish
Dr. Nirish Agarwal
Pathologist
RMC No 12512



CARE DIAGNOSTIC AND IMAGING CENTER

A- 7, Hanuman Nagar, Near HDFC Bank, Main Khatipura Road, Jaipur - 302021
Ph.: 0141-4025102 • E-mail : carecenterjaipur@gmail.com

Patient Name	Renu Prajapati	Age/Sex	33 Yrs/F
Patient ID	05317	Date	24/03/2024
Referred By	Bank Of Baroda		

SONOGRAPHY OF WHOLE ABDOMEN (FEMALE)

- LIVER** : Measures 131 mms. Is normal in size, shape and echotexture.
No focal lesion seen. Hepatic and portal venous systems are normal.
IHBR are not dilated.
Portal vein & CBD normal in caliber.
- GALL BLADDER** : Well distended. Lumen is echofree.
- PANCREAS** : Is normal in size, shape and echotexture. Pancreatic duct is not dilated.
- SPLEEN** : Normal in size (78 mms), shape and echotexture.
- BOTH KIDNEYS** : Both kidneys are normal in size, shape, position, outline and show normal corticomedullary differentiation.
Pelvicalyceal system is normal.
No evidence of hydronephrosis or calculus on either side.
- U. BLADDER** Well-distended with echofree lumen
- UTERUS** Is normal in size and echotexture. No focal lesion seen.
ET is thin.
- OVARIES** Are normal in size, shape and echotexture.
No free fluid is seen in peritoneal cavity
- IMPRESSION:** No significant sonographic abnormality seen.


Dr. Vikram Singh M.D.
Consultant Radiologist
RMC-No-25097/11212

Dr. VIKRAM SINGH
M.D. (RADIODIAGNOSIS)
R.M.C. REG.-11212



CARE DIAGNOSTIC AND IMAGING CENTER

A- 7, Hanuman Nagar, Near HDFC Bank, Main Khatipura Road, Jaipur - 302021
Ph.: 0141-4025102 • E-mail : carecenterjaipur@gmail.com

Name	Renu Prajapati	Age/Sex	33 Yrs/F
Ref By	Bank Of Baroda	Date	24/03/2024
Reg. Id	5317	Page	1 of 1

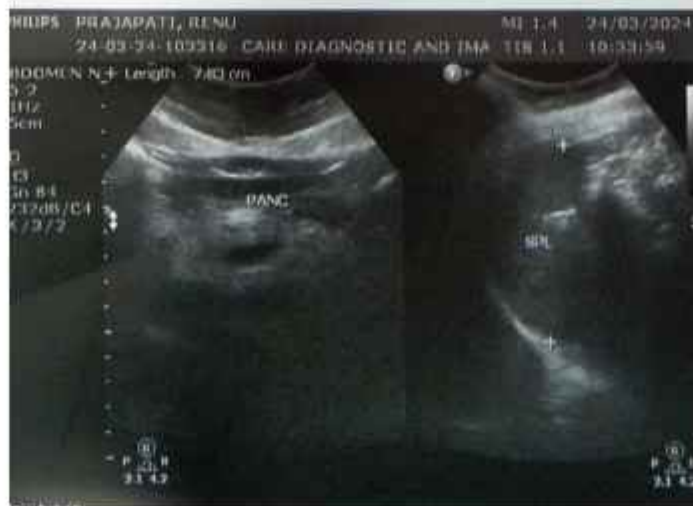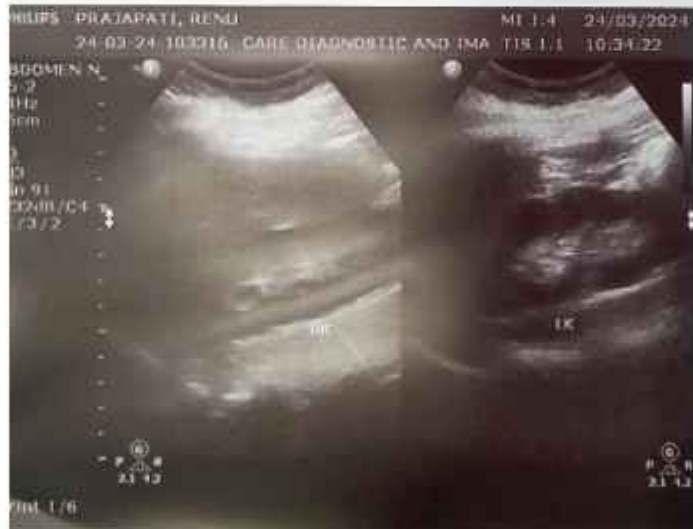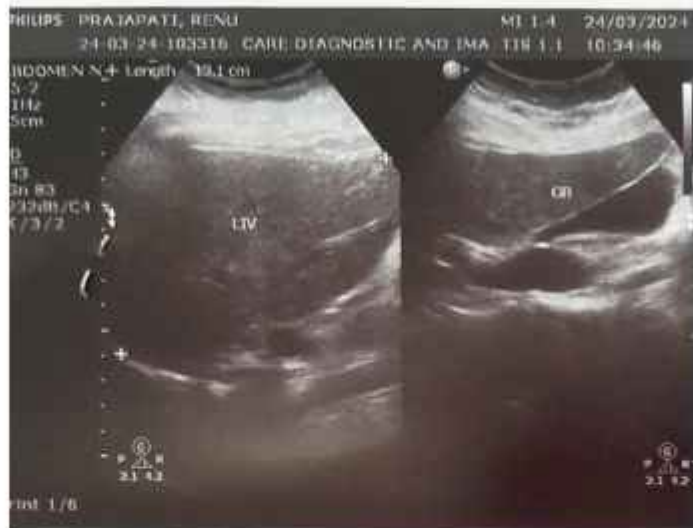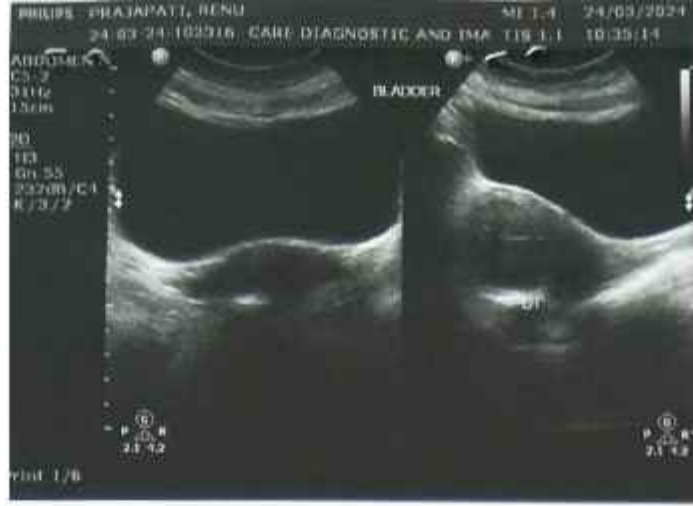X RAY CHEST PA VIEW

- * *Soft tissues & bony cage are normal.*
- * *Trachea is central.*
- * *Both domes are normal.*
- * *Both costophrenic angles appear normal.*
- * *Both lung fields are clear*
- * *Both hilar shadows are normal.*
- * *Cardiac size is normal.*

IMPRESSION: - NORMAL SKIAGRAM


Dr. Vikram Singh M.D.
Consultant Radiologist
RMC-No-25097/11212

Dr. VIKRAM SINGH
M.D. (RADIODIAGNOSIS)
R.M.C. REG.-11212



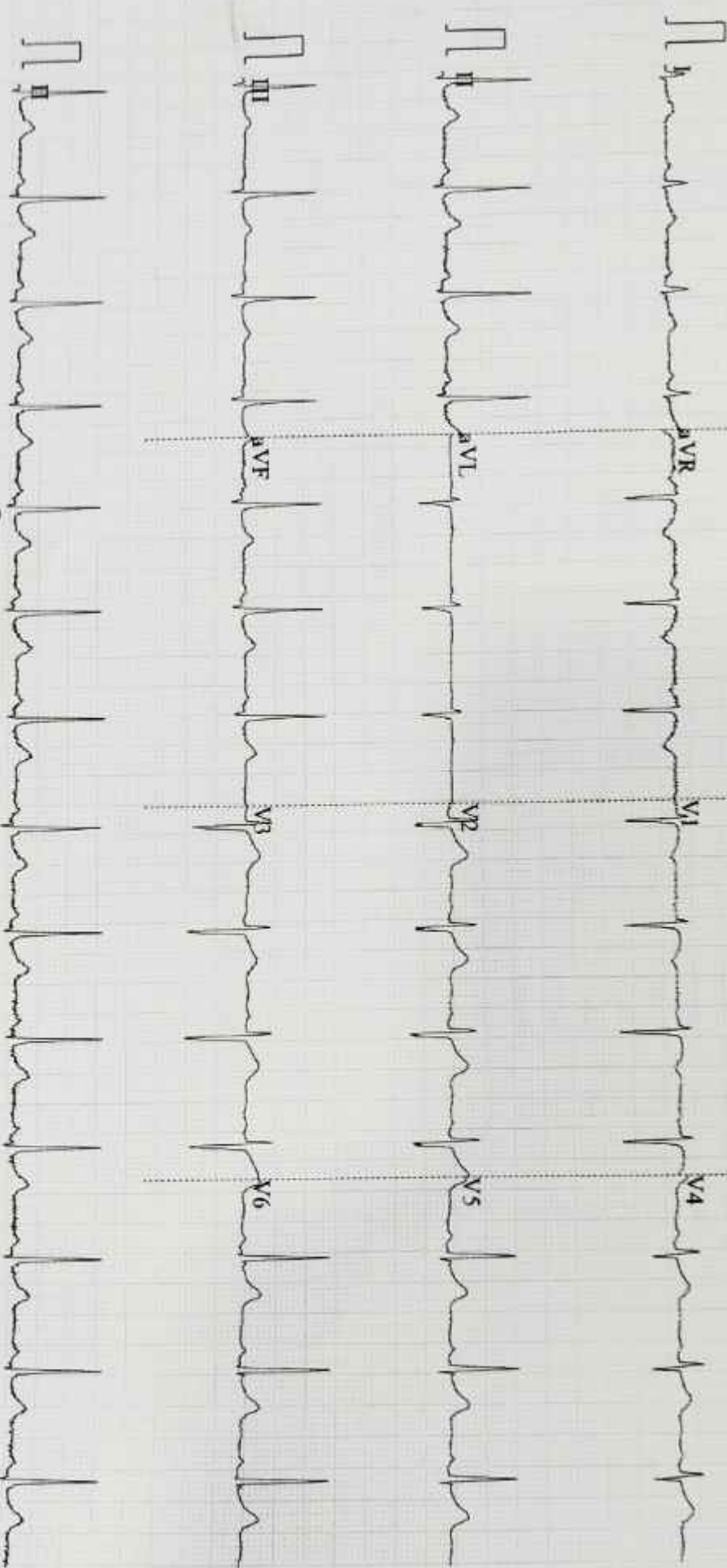
HR : 82 bpm
 P : 102 ms
 PR : 147 ms
 QRS : 75 ms
 QT/QTc : 353/415 ms
 PQRS/T : 48/75/54 °
 RV5/SVI : 1.130/0.903 mV

Diagnosis Information:
 Sinus Rhythm
 Poor R Wave Progression(V3,V4)

WNL

Report Confirmed by:

Dr. Manoj K. Sarowa
 MD, DM (Cardiology)
 Consultant Interventional Cardiologist
 RMC 025258/10451



0.67-100Hz AC50 25mm/s 10mm/mV 4*2.5s+1r 82

V2.02 SEMIP V1.7 CARE DIAGNOSTIC & IMAGING CENTER JAIPUR

CAPE DIAGNOSTIC AND IMAGING CENTER, JAIPUR
JAIPUR

1425170 / MRS. RENU PRAJAPATI / 33 YRS / F / 60 CMS / 60 KG Date: 24-Mar-2024

Report

Stage	Time	Duration	Heart Speed (bpm)	Elevation	METs	Rate	% TMB Achieved	BP	HRP	PVC	Comments
Supine	00:20	0:01	00.0	00.0	01.0	95	5.1%	120/80	114	00	
Standing	00:30	0:01	00.0	00.0	01.0	110	59%	120/80	132	00	
HI	01:02	0:01	00.0	00.0	01.0	114	61%	120/80	136	00	
Exhaust	02:18	0:07	02.7	10.0	01.1	118	63%	120/80	141	00	
EMULJE Stage 1	05:18	3:00	02.7	10.0	04.7	140	75%	130/80	182	00	
PeakEx	07:53	2:35	04.0	12.0	06.8	161	89%	140/80	225	00	
Recovery	08:22	0:29	00.0	00.0	01.8	160	88%	140/80	224	00	
Recovery	09:52	2:30	00.0	00.0	01.0	115	61%	160/90	184	00	
Recovery	11:52	4:00	00.0	00.0	01.0	106	57%	150/85	159	00	
Recovery	12:11	4:18	00.0	00.0	01.0	109	58%	140/80	152	00	

Findings :

Exercise Time: 05:36
 Max HR Achieved: 161 bpm 86% of Target 187
 Max BP Achieved: (Syst) 160/90
 Max Workload Achieved: 6.8 Fair response to induced stress
 Max ST-Dep Load & Value: 0.8 -0.9 mm to PeakEx run
 Test End Reasons: Test Complete, Heart Rate Achieved

This is Negative for ACS

MS

Dr. Manoj K. Sarawa
 MD (M. Cardiology)
 Consultant Interventional Cardiologist
 RMC 020258/10451

Doctor :

0202582310451@mcgms

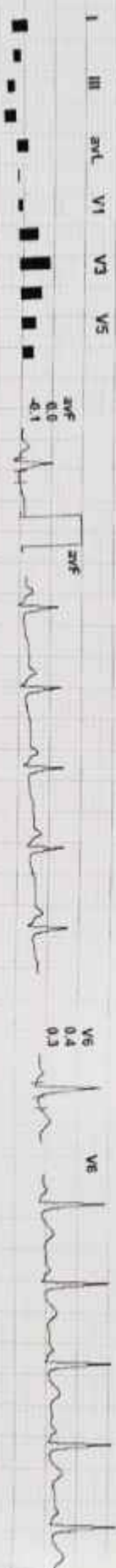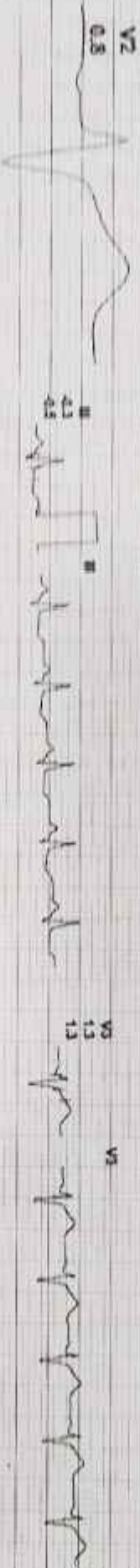CARE DIAGNOSTIC AND IMAGING CENTER, JAIPUR

425170 / MRS. RENU PRADYATI / 33 Yrs / F

Date: 24-Mar-2024 01:30:06 PM METS: 1.39 95 bpm 50% of THF Sp: 120/80 mmHg Conduction Mediators: B/C/Ox/Nauch/Clx/HF 0.05 Hz/LEF 20 Hz

Supine
ACADL
ExtTime: 00:20 0.0 Kmph 0.0%
25 mm/Sec 1.0 Cm/mV

4X 62 mm Paper



REMARKS:

(GEM213180320)(RJA)Allengers

CARE DIAGNOSTIC AND IMAGING CENTER, JAIPUR

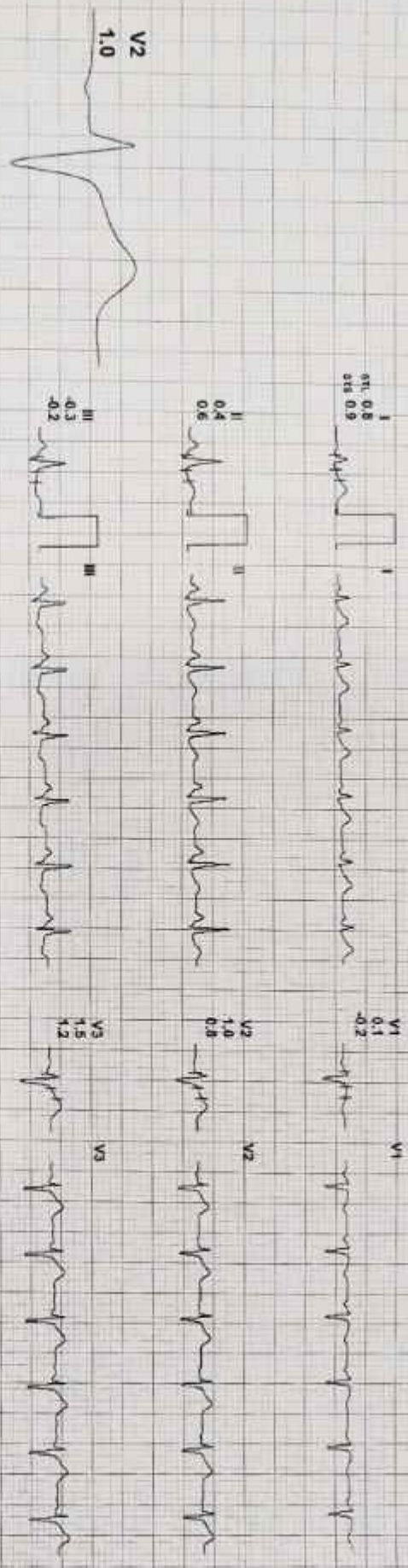
1425170 / MRS. RENU PRAJAPATI / 33 Yrs / F

Date: 24-Mar-2024 01:19:06 PM METS: 1.0/ 110 bpm 58% of THR BP: 120/80 mmHg Combined Medians/ B.C. On/ Noch On/ HF: 0.05 Hz/ LF: 20 Hz

4X 60 ms Post J

Standing
ExTime: 00:36 0.0 Km/h 0.0%
25 mm/Sec. 1.0 Cm/mV

JAIPUR



REMARKS:

You created this PDF from an application that is not licensed to print to novaPDF printer (<http://www.novapdf.com>)

(GEM213180320)(R)/Asterigaers

CARE DIAGNOSTIC AND IMAGING CENTER, JAIPUR

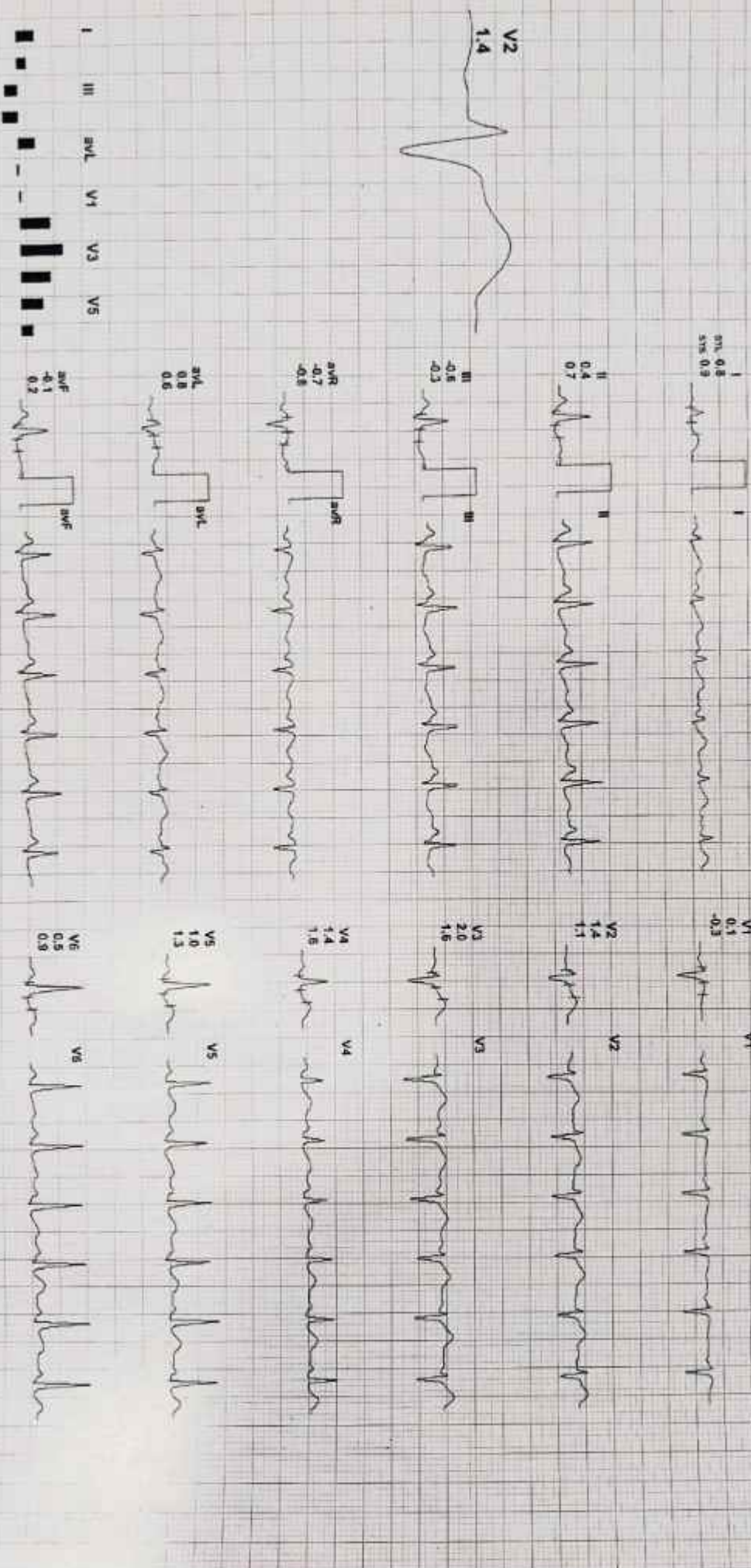
1425170 / MRS RENU PRAJAPATI / 33 Yrs / F

Date: 24-Mar-2024 01:19:06 PM METS: 1.1/ 118 bpm 63% of THR BP: 120/80 mmHg Combined Medians/ BLC/ On/ Netch On/ HF 0.05 Hz/ LF 20 Hz

4X 80 ms Post J

ExStart AGHPIL

EXTime: 00:07 2.7 Kmph, 10.0% 25 mm/Sec 1.0 CrmmV



REMARKS:
I aVR aVL V1 V2 V3 V4 V5 V6

(GENK13180320)R Fallengers

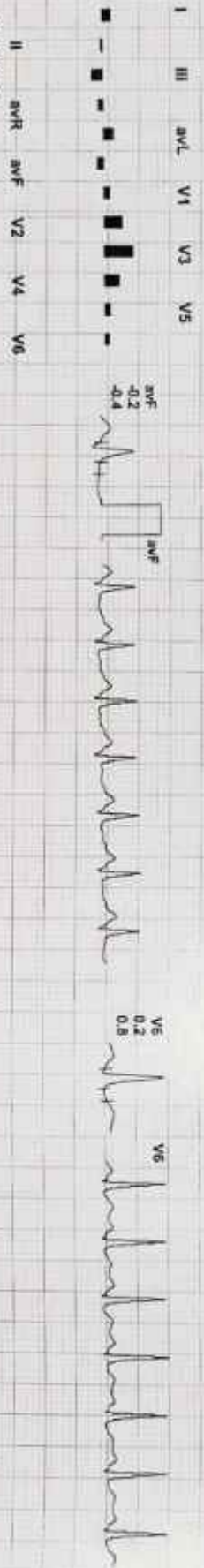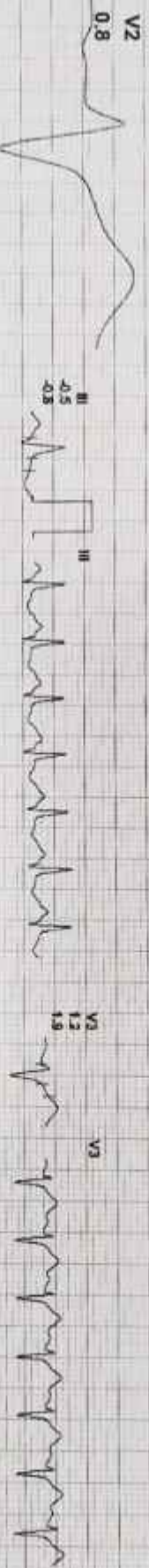1425170 / MRS. RENU PRAJAPATI / 33 YRS / F

Date: 24-Mar-2024 01:19:06 PM METS: 4.7/ 140 bpm 74% of THR BP: 130/80 mmHg Combined Median/ BLC On/ Notch On/ HF: 0.05 HZLF: 20 Hz

EXTIME: 03:00 2.7 Km/h, 10.0%

25 mm/Sec, 1.6 Cm/IV

4X 60 ms Paper J



REMARKS:

II aVR aVF V2 V4 V6

CARE DIAGNOSTIC AND IMAGING CENTER, JAIPUR

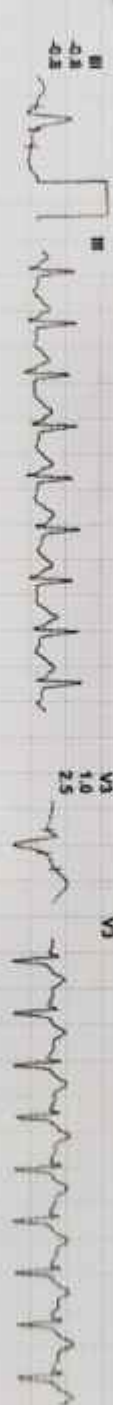
1425170 / MRS. RENU PRAJAPATI / 33 Yrs / F

Date: 24-Mar-2024 01:19:06 PM METS: 6.8/ 161 bpm 86% of THR BP: 140/80 mmHg Combined Medians/ BLC CW North CW HF: 0.05 HOLF: 20 Hz

4X 60 ms Post J

PeakEx

ESTIM: 05:35 4.6 Km/h 12.0%
25 mm/sec 1.5 Cm/mV



REMARKS: II aVR aVF V2 V4 V6

CARE DIAGNOSTIC AND IMAGING CENTER, JAIPUR

1425170 / MRS. RENU PRAJAPATI / 33 YRS / F

Date: 24-Mar-2024 01:30:06 PM METS: 1.8V 160 bpm 85% of TRV BP: 140/80 mmHg Combined Medians/ BLC On/ Notch On/ HF 0.05 Hz/LF 20 Hz

AX 94 min Lead I

Recovery(0:29)

ACIPDL

ExTime 05:36 0.0 KmPh, 0.0% 25 mm/Sec, 1.8 Cm/mV



1 II aVR aVL V1 V2 V3 V4 V5 V6

(GENE)131803201/P/Ashtorgens

CARE DIAGNOSTIC AND IMAGING CENTER, JAIPUR

1425170 / MRS. RENU PRAJAPATI / 33 Yrs / F

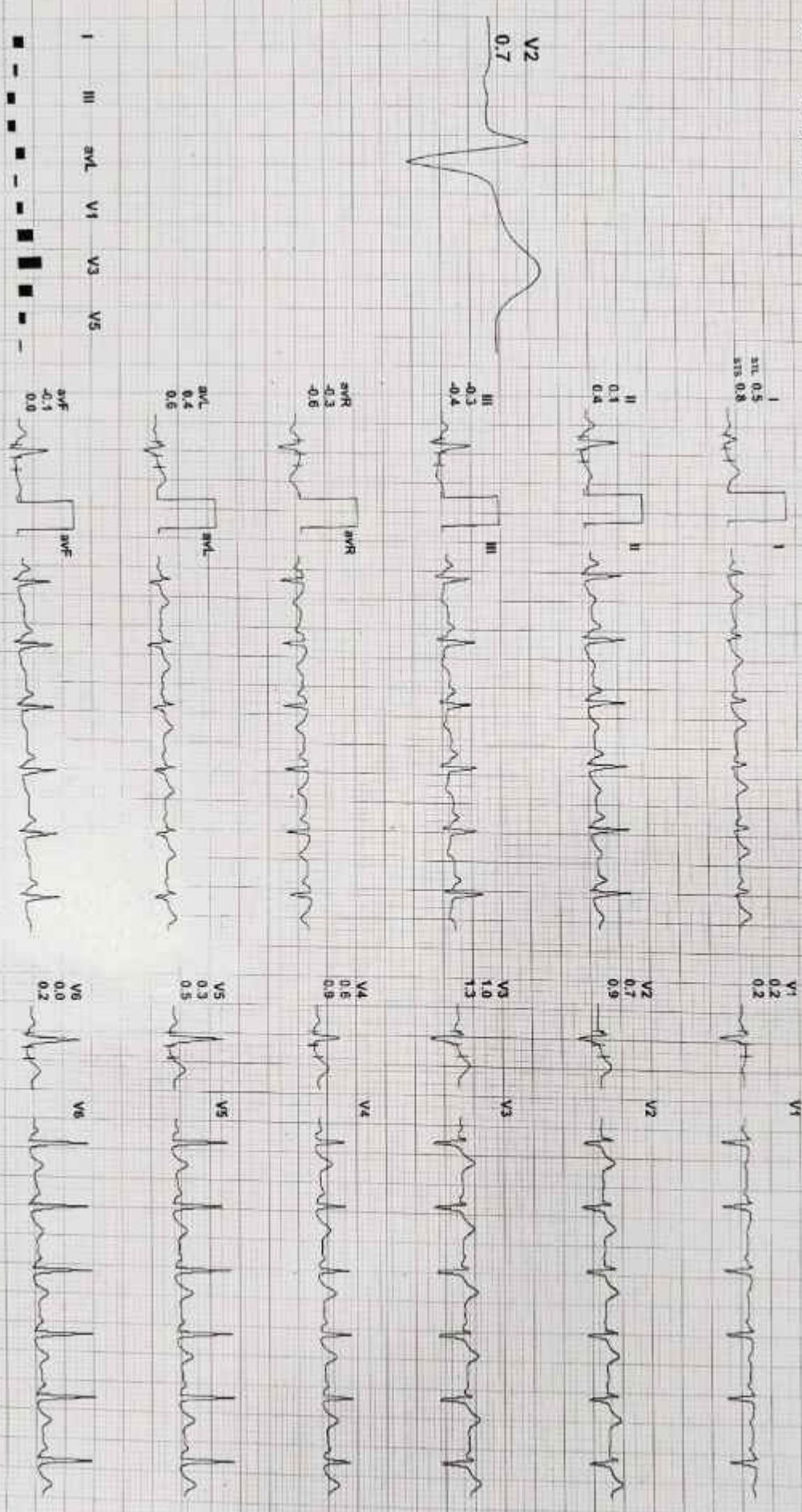
Date: 24-Mar-2024 01:19:06 PM METS: 1.0/106 bpm 56% of THR BP: 150/85 mmHg Combined Medians/ BLC On/ Notch On/ HF 0.05 Hz/LF 20 Hz

4X 80 ms Post J

Recovery(4:00)

ACAPL

EXTime: 05:36 0.0 Kmph, 0.0%
25 min/Sec, 1.0 Cm/mV



REMARKS: I II aVR aVL V1 V2 V3 V4 V5 V6

(GEM213180320)(R)Malangaris

CARE DIAGNOSTIC AND IMAGING CENTER, JAIPUR

Recovery(4:18)

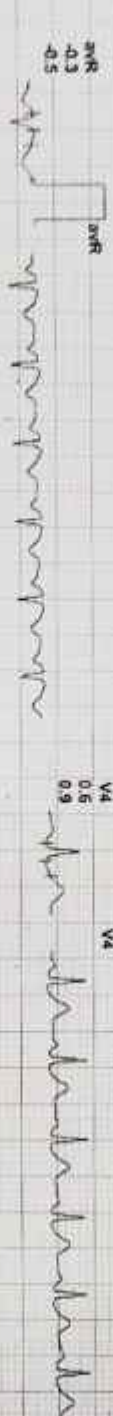
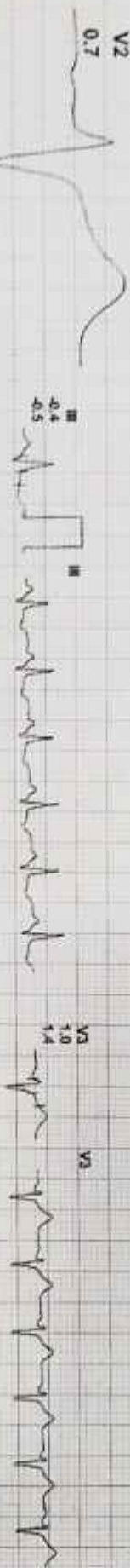
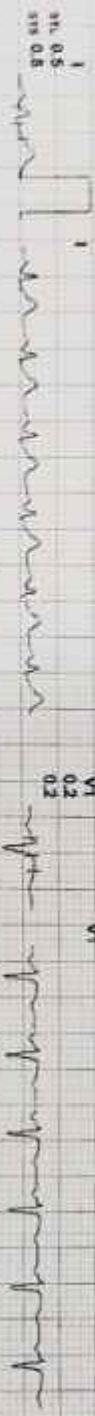1425170 / MRS. RENU PRAJAPATI / 33 Yrs / F

Date: 24-Mar-2024 01:19:06 PM METS: 1.0/ 109 bpm 55% of THR BP: 140/80 mmHg Combined Medians/ BLC Cr/ Natch Cr/ HF 0.05 HZLF 20 Hz

EXTime: 05:36 0.0 Km/h 0.0% 25 min/Sec. 1.0 Cm/hv

4X 40 MS Post J



I III aVL V1 V3 V5
 II aVR aVF V2 V4 V6

(GEM213180320)RJAJLenglers