

From

K. DIVYASUBHA, & S. MAHESH KUMAR  
EC NO : 96036,  
BANK OF BARODA,  
NAGERCOIL

To

DDRC Agilus,  
Trivandrum.

Dear Sir / Madam

I herewith confirm that,  
I am not willing to undertake eyetest &  
Dental examination outside.

Thank you,

Yours faithfully,

Divy

Subha

From

K. DIVYASUBHA, & S. MAHESH KUMAR  
EC NO : 96036,  
BANK OF BARODA,  
NAGERCOIL

To

DDRC Agilus,  
Trivandrum.

Dear Sir / Madam

I herewith confirm that,  
I am not willing to undertake eyetest &  
Dental examination outside.

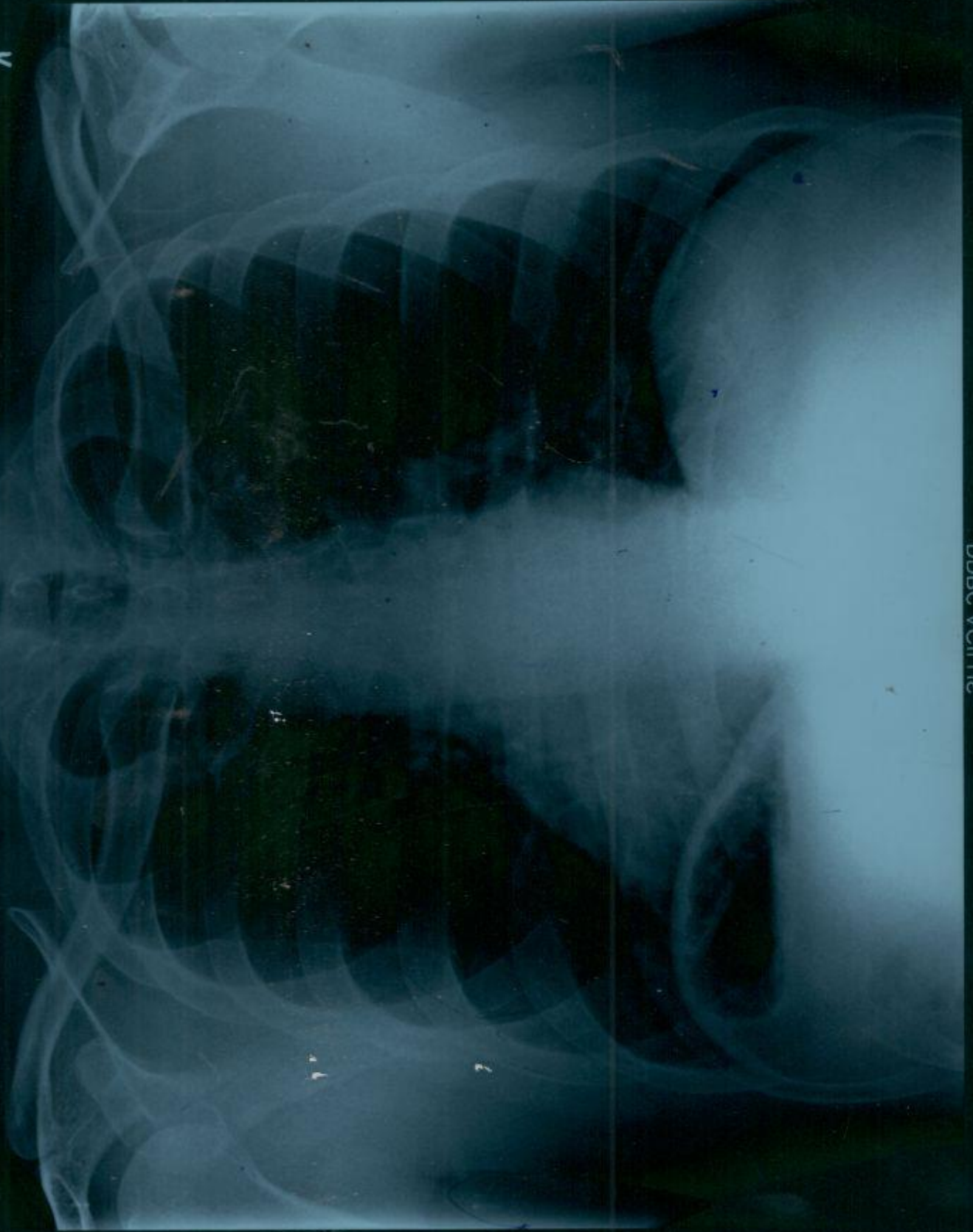
Thank you,

Yours faithfully,

Divy

Subha

R



WHEELING MOUNTAIN COLLEGE  
DORIS AGILUS  
CHEST PA

NAME : MR: MAHESH KUMAR	AGE:43/M	DATE: 24/02/2024
-------------------------	----------	------------------

**CHEST X-RAY REPORT**

CHEST X-RAY PA VIEW : Trachea central  
 No cardiomegaly  
 Normal vascularity  
 No parenchymal lesion.  
 Costophrenic and cardiophrenic angles clear

➤ **IMPRESSION** : Normal Chest Xray

ELECTRO CARDIOGRAM : NSR: 80/minute  
 No evidence of ischaemia

➤ **IMPRESSION** : Normal Ecg.

Dr. SERIN LOPEZ, MBBS  
 Medical Officer  
 DDRC AGILUS PATHLABS LTD.  
 Aster Square, Medical College, Bangalore, Karnataka



Company name: MEDIWHEEL

**DR SERIN LOPEZ MBBS**  
 Reg No 77656  
**DDRC AGILUS PATHLABS LTD**



V1

V2

V3

V4

ID: 008681

Diagnosis Information:

Male  
43Years  
cm

/ mmHg  
kg

Mr. Mahesh Kumar

HR : 80 bpm  
P : 124 ms  
PR : 155 ms  
QRS : 107 ms  
QT/QTc : 379/439 ms  
P/QRS/T : 61/26/10 °  
RV5/VI : 0.528/0.382 mV

Report Confirmed by: 

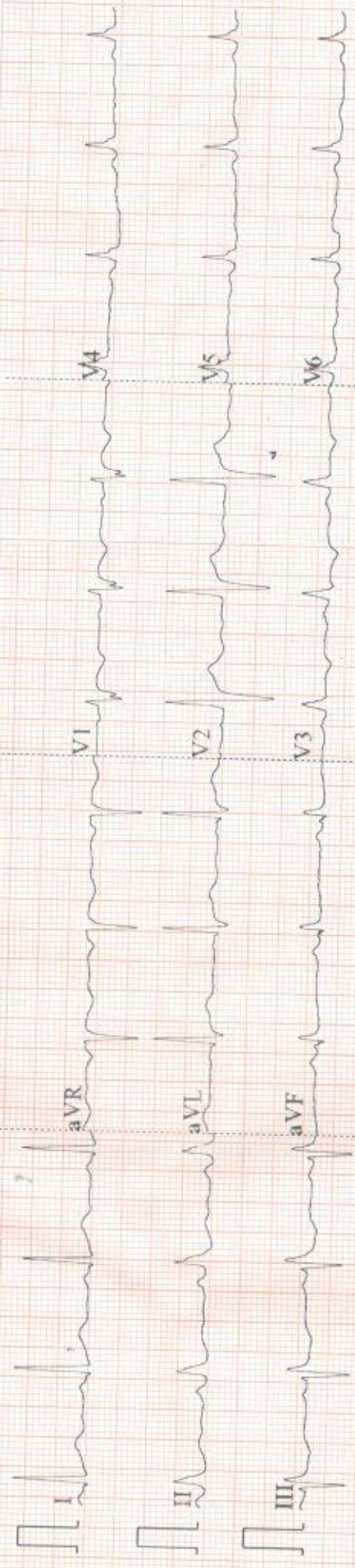


V6

Standard

Standard	L 1	L II	L III	L III Inspiration
----------	-----	------	-------	-------------------

ID: 008681 24-02-2024 10:11:00 AM



0.5-25Hz AC50 25mm/s 10mm/mV ♡81 V1.0 SEMIP V1.7 DDR-C-AGILUS  
A.W.C.C.



**RADIOLOGY DIVISION**

**ECHO REPORT**

SRD No :XB008681	Name:MAHESH KUMAR	Age:43Y	Sex:M	Date: 24/02/24
------------------	-------------------	---------	-------	----------------

**Left Ventricle:-**

	Diastole	Systole
IVS	1.09cm	1.22cm
LV	4.31cm	2.83cm
LVPW	1.16cm	1.24cm

EF -63%      FS- 34%

AO	LA
3.41cm	3.93cm

PV            -    0.80m/s  
AV            -    1.02m/s  
MVE          -    0.68m/s  
MVA          -    0.56m/s  
E/A           -    1.22

**IMPRESSION:-**

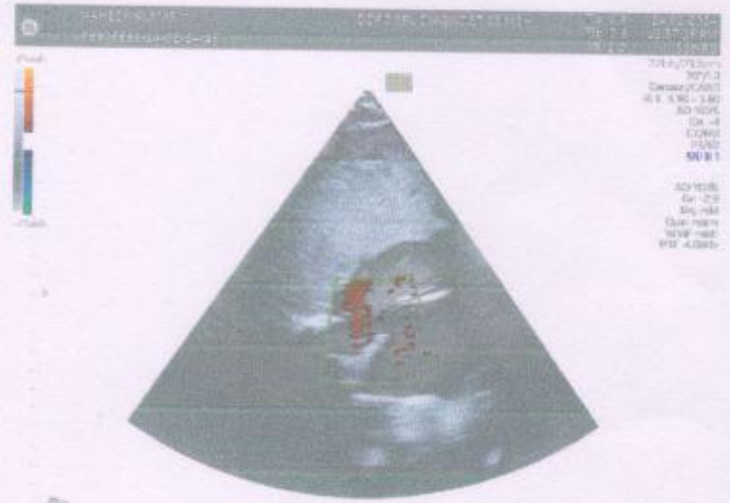
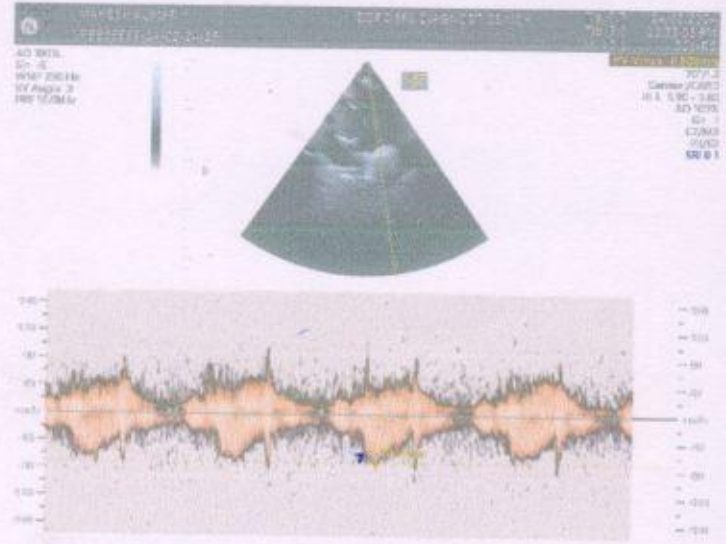
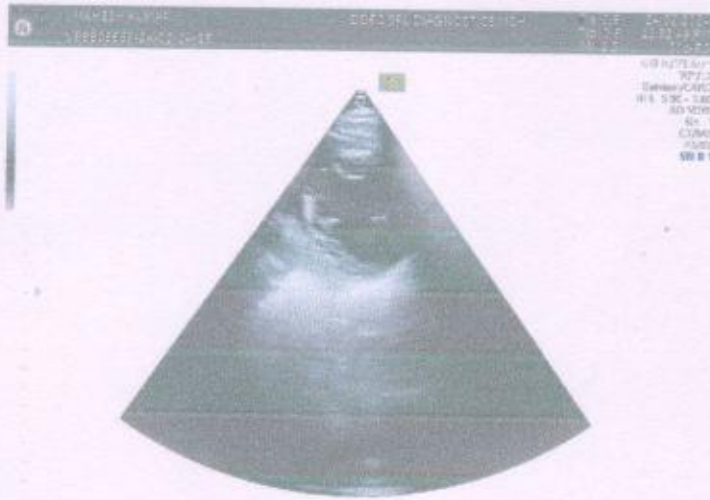- Normal chambers dimension
- No RWMA
- Good LV systolic function
- No diastolic dysfunction
- No AS,AR,MR,MS,TR,PAH
- IAS/IVS intact.No clots/effussion/coarctation

**Dr. SAJITH. K**  
**MD,DNB**  
**CONSULTANT CARDIOLOGIST**  
Reg:No: 19436



*Consultant Cardiologis*

**DDRC** agilus Pathlabs Limited.





If the examinee is suffering from an acute life threatening situation, you may be obliged to disclose the result of the medical examination to the examinee.

1. Name of the examinee	:	Mr./Mrs./Ms. <u>Mahesh Kumar</u>
2. Mark of Identification	:	(Mole/Scar/any other (specify location)):
3. Age/Date of Birth	:	<u>43</u> Gender: <u>FM</u>
4. Photo ID Checked	:	(Passport/Election Card/PAN Card/Driving Licence/Company ID)

### PHYSICAL DETAILS:

a. Height <u>174</u> (cms)	b. Weight ..... (Kgs)	c. Girth of Abdomen ..... (cms)
d. Pulse Rate ..... (/Min)	e. Blood Pressure:	Systolic      Diastolic
	1 <sup>st</sup> Reading	<u>130</u> <u>76</u>
	2 <sup>nd</sup> Reading	

### FAMILY HISTORY:

Relation	Age if Living	Health Status	If deceased, age at the time and cause
Father			
Mother			
Brother(s)			
Sister(s)			

### HABITS & ADDICTIONS: Does the examinee consume any of the following?

Tobacco in any form	Sedative	Alcohol
<u>Nil</u>	<u>Nil</u>	<u>Nil</u>

### PERSONAL HISTORY

- |   |   |
|---|---|
| a. Are you presently in good health and entirely free from any mental or Physical impairment or deformity. If No, please attach details. <u>Y/N</u> | c. During the last 5 years have you been medically examined, received any advice or treatment or admitted to any hospital? <u>Y/N</u> |
| b. Have you undergone/been advised any surgical procedure? <u>Y/N</u>   | d. Have you lost or gained weight in past 12 months? <u>Y/N</u>   |

### Have you ever suffered from any of the following?

- |  |   |
|--|---|
| • Psychological Disorders or any kind of disorders of the Nervous System? <u>Y/N</u> | • Any disorder of Gastrointestinal System? <u>Y/N</u>                               |
| • Any disorders of Respiratory system? <u>Y/N</u>                                    | • Unexplained recurrent or persistent fever, and/or weight loss <u>Y/N</u>          |
| • Any Cardiac or Circulatory Disorders? <u>Y/N</u>                                   | • Have you been tested for HIV/HBsAg / HCV before? If yes attach reports <u>Y/N</u> |
| • Enlarged glands or any form of Cancer/Tumour? <u>Y/N</u>                           | • Are you presently taking medication of any kind? <u>Y/N</u>                       |
| • Any Musculoskeletal disorder? <u>Y/N</u>   |   |

OHA (Metformin)





**RADIOLOGY DIVISION**

Acc no:4182XB008681	Name: Mr. Mahesh Kumar	Age:43 y	Sex: Male	Date: 24.02.24
---------------------	------------------------	----------	-----------	----------------

**US SCAN WHOLE ABDOMEN**

**LIVER** is normal in size (15 cm). Margins are regular. **Hepatic parenchyma shows mildly increased echogenicity.** No focal lesions seen. No dilatation of intrahepatic biliary radicles. CBD is not dilated. **Portal vein is prominent in caliber (12.2 mm) & shows hepatopetal flow.**

**GALL BLADDER** is distended and lumen clear. No calculi / polyp noted. Wall thickness is normal. No pericholecystic fluid seen.

**SPLEEN** is normal in size (8.9 cm) and parenchymal echotexture. No focal lesion seen.

**PANCREAS** Head and body visualized, appears normal in size and parenchymal echotexture. Pancreatic duct is not dilated.

**RIGHT KIDNEY** is normal in size (10.3 x 3.8 cm) and shows normal parenchymal echotexture. Cortico medullary differentiation is maintained. Parenchymal thickness is normal. No echogenic focus with shadowing suggestive of renal calculi seen. No dilatation of pelvicalyceal system seen. Ureter is not dilated. Perinephric spaces are normal.

**LEFT KIDNEY** is normal in size (12.2 x 5.2 cm) and shows normal parenchymal echotexture. Cortico medullary differentiation is maintained. Parenchymal thickness is normal. No echogenic focus with shadowing suggestive of renal calculi seen. No dilatation of pelvicalyceal system seen. Ureter is not dilated. Perinephric spaces are normal.

**PARAAORTIC AREA** No retroperitoneal lymphadenopathy or mass seen.

**URINARY BLADDER** is partially distended, normal in wall thickness, lumen clear.

**PROSTATE** is normal in size (vol - 14.4 cc) and shows normal echotexture. No focal lesion seen. No ascites or pleural effusion.

**Gaseous distension of bowel loops noted. No obvious bowel wall thickening seen sonologically.**

**CONCLUSION:-**

- > **Grade I fatty liver.**

  
**Dr. Nisha Unni MD , DNB ( RD )**  
Consultant radiologist.

*Thanks, your feedback will be appreciated.*

*(Please bring relevant investigation reports during all visits).*

*Because of technical and technological limitations complete accuracy cannot be assured on imaging.*

*Suggested correlation with clinical findings and other relevant investigations consultations, and if required repeat imaging recommended in the event of controversies. AR*

**For appointments / any clarification of report please contact 9496005190 between 9 am – 5.30 pm).**





**PATIENT NAME : MR. MAHESH KUMAR**
**REF. DOCTOR : SELF**
**CODE/NAME & ADDRESS : CA00010147 -**

 MEDIWHEEL ARCOFEMI HEALTHCARE LIMITED  
 F701A, LADO SARAI, NEW DELHI, SOUTH DELHI,  
 DELHI,  
 SOUTH DELHI 110030  
 8800465156

**ACCESSION NO : 4182XB008681**
**PATIENT ID : MAHEM2402814182**
**CLIENT PATIENT ID:**
**ABHA NO :**
**AGE/SEX : 43 Years Male**
**DRAWN :**
**RECEIVED : 24/02/2024 09:00:32**
**REPORTED : 27/02/2024 09:51:32**
**Test Report Status Final**
**Results**
**Units**
**MEDIWHEEL HEALTH CHECKUP ABOVE 40(M)2DECHO**
**ECG WITH REPORT**
**REPORT**
**REPORT GIVEN**
**USG ABDOMEN AND PELVIS**
**REPORT**
**REPORT GIVEN**
**CHEST X-RAY WITH REPORT**
**REPORT**
**REPORT GIVEN**
**2D - ECHO WITH COLOR DOPPLER**
**REPORT**
**REPORT GIVEN**
**HAEMATOTOLOGY**
**MEDIWHEEL HEALTH CHECKUP ABOVE 40(M)2DECHO**
**GLYCOSYLATED HEMOGLOBIN(HBA1C), EDTA WHOLE BLOOD**
**HBA1C**
**7.0 High**

Non-diabetic Adult &lt; 5.7 %

Pre-diabetes 5.7 - 6.4

Diabetes diagnosis: &gt; or = 6.5

Therapeutic goals: &lt; 7.0

Action suggested : &gt; 8.0

(ADA Guideline 2021)

**MEAN PLASMA GLUCOSE**
**154.2 High**

&lt; 116.0

mg/dL


**DR.HARI SHANKAR, MBBS MD**  
 (Reg No - TCMC:62092)  
 HEAD - Biochemistry &  
 Immunology


**DR NISHA UNNI, MBBS,MD**  
 (RD),DNB (Reg.No:50162)  
 Consultant Radiologist


**DR.VAISHALI RAJAN, MBBS DCP**  
 (Pathology)  
 (Reg No - TCC 27150)  
 HOD - HAEMATOTOLOGY


View Details



View Report

Page 1 Of 8

**PERFORMED AT :**

 DDRC AGILUS PATHLABS LIMITED  
 ASTER SQUARE BUILDING, ULLOOR,  
 MEDICAL COLLEGE P.O  
 TRIVANDRUM, 695011  
 KERALA, INDIA

Tel : 93334 93334, Fax : CIN - U85190MH2006PTC161480

Email : customercare.ddrc@agilus.in


**Patient Ref. No. 66600007977228**

**PATIENT NAME : MR. MAHESH KUMAR** **REF. DOCTOR : SELF**

<b>CODE/NAME &amp; ADDRESS :</b> CA00010147 - MEDIWHEEL ARCOFEMI HEALTHCARE LIMITED F701A, LADO SARAI, NEW DELHI,SOUTH DELHI, DELHI, SOUTH DELHI 110030 8800465156	<b>ACCESSION NO :</b> <b>4182XB008681</b>	<b>AGE/SEX :</b> 43 Years Male
	<b>PATIENT ID :</b> MAHEM2402814182	<b>DRAWN :</b>
	<b>CLIENT PATIENT ID:</b>	<b>RECEIVED :</b> 24/02/2024 09:00:32
	<b>ABHA NO :</b>	<b>REPORTED :</b> 27/02/2024 09:51:32

Test Report Status	Final	Results	Units
--------------------	-------	---------	-------

**BLOOD COUNTS,EDTA WHOLE BLOOD**

HEMOGLOBIN	<b>12.7 Low</b>	13.0 - 17.0	g/dL
RED BLOOD CELL COUNT	4.61	4.50 - 5.50	mil/ $\mu$ L
WHITE BLOOD CELL COUNT	8.91	4.0 - 10.0	thou/ $\mu$ L
PLATELET COUNT	292	150 - 410	thou/ $\mu$ L

**RBC AND PLATELET INDICES**

HEMATOCRIT	40.2	40.0 - 50.0	%
MEAN CORPUSCULAR VOL	87.2	83.0 - 101	fL
MEAN CORPUSCULAR HGB.	27.5	27.0 - 32.0	pg
MEAN CORPUSCULAR HEMOGLOBIN CONCENTRATION	31.6	31.50 - 34.50	g/dL
RED CELL DISTRIBUTION WIDTH	<b>14.1 High</b>	11.60 - 14.0	%
MENTZER INDEX	18.9		
MEAN PLATELET VOLUME	8.7	6.80 - 10.90	fL

**WBC DIFFERENTIAL COUNT**

SEGMENTED NEUTROPHILS	44	40.0 - 80.0	%
LYMPHOCYTES	<b>48 High</b>	20.0 - 40.0	%
MONOCYTES	5	2.0 - 10.0	%
EOSINOPHILS	3	1.0 - 6.0	%
BASOPHILS	0	0.0 - 1.0	%
ABSOLUTE NEUTROPHIL COUNT	3.92	2.0 - 7.0	thou/ $\mu$ L
ABSOLUTE LYMPHOCYTE COUNT	<b>4.23 High</b>	1.0 - 3.0	thou/ $\mu$ L
ABSOLUTE MONOCYTE COUNT	0.42	0.20 - 1.0	thou/ $\mu$ L
ABSOLUTE EOSINOPHIL COUNT	0.28	0.02 - 0.50	thou/ $\mu$ L
ABSOLUTE BASOPHIL COUNT	0.00		thou/ $\mu$ L
NEUTROPHIL LYMPHOCYTE RATIO (NLR)	0.9		

**DR.HARI SHANKAR, MBBS MD**  
 (Reg No - TCMC:62092)  
**HEAD - Biochemistry & Immunology**

**DR.VAISHALI RAJAN, MBBS DCP**  
 (Pathology)  
 (Reg No - TCC 27150)  
**HOD - HAEMATOLOGY**



View Details



View Report

**PERFORMED AT :**

DDRC AGILUS PATHLABS LIMITED  
 ASTER SQUARE BUILDING, ULLOOR,  
 MEDICAL COLLEGE P.O  
 TRIVANDRUM, 695011  
 KERALA, INDIA  
 Tel : 93334 93334, Fax : CIN - U85190MH2006PTC161480  
 Email : customercare.ddrc@agilus.in



**Patient Ref. No. 66600007977228**



PATIENT NAME : MR. MAHESH KUMAR

REF. DOCTOR : SELF

CODE/NAME &amp; ADDRESS : CA00010147 -

MEDIWHEEL ARCOFEMI HEALTHCARE LIMITED  
F701A, LADO SARAI, NEW DELHI, SOUTH DELHI,  
DELHI,  
SOUTH DELHI 110030  
8800465156

ACCESSION NO : **4182XB008681**

PATIENT ID : MAHEM2402814182

CLIENT PATIENT ID:

ABHA NO :

AGE/SEX : 43 Years Male

DRAWN :

RECEIVED : 24/02/2024 09:00:32

REPORTED : 27/02/2024 09:51:32

Test Report Status	Final	Results	Units
--------------------	-------	---------	-------

**ERYTHROCYTE SEDIMENTATION RATE (ESR), EDTA BLOOD**

SEDIMENTATION RATE (ESR)	<b>24 High</b>	0 - 14	mm at 1 hr
--------------------------	----------------	--------	------------

**SUGAR URINE - POST PRANDIAL**

SUGAR URINE - POST PRANDIAL	NOT DETECTED	NOT DETECTED
-----------------------------	--------------	--------------

**SUGAR URINE - FASTING**

SUGAR URINE - FASTING	NOT DETECTED	NOT DETECTED
-----------------------	--------------	--------------

**IMMUNOHAEMATOLOGY****MEDIWHEEL HEALTH CHECKUP ABOVE 40(M)2DECHO****ABO GROUP & RH TYPE, EDTA WHOLE BLOOD**

ABO GROUP	TYPE A
RH TYPE	POSITIVE

METHOD : COLUMN AGGLUTINATION TECHNOLOGY

&lt;b&gt;Interpretation(s)&lt;/b&gt;

ABO GROUP & RH TYPE, EDTA WHOLE BLOOD-Blood group is identified by antigens and antibodies present in the blood. Antigens are protein molecules found on the surface of red blood cells. Antibodies are found in plasma. To determine blood group, red cells are mixed with different antibody solutions to give A,B,O or AB.

Disclaimer: "Please note, as the results of previous ABO and Rh group (Blood Group) for pregnant women are not available, please check with the patient records for availability of the same."

The test is performed by both forward as well as reverse grouping methods.



**DR. HARI SHANKAR, MBBS MD**  
(Reg No - TCMC:62092)  
HEAD - Biochemistry &  
Immunology



**DR. VAISHALI RAJAN, MBBS DCP**  
(Pathology)  
(Reg No - TCC 27150)  
HOD - HAEMATOLOGY

Page 3 Of 8



View Details



View Report

**PERFORMED AT :**

DDRC AGILUS PATHLABS LIMITED  
ASTER SQUARE BUILDING, ULLOOR,  
MEDICAL COLLEGE P.O  
TRIVANDRUM, 695011  
KERALA, INDIA  
Tel : 93334 93334, Fax : CIN - U85190MH2006PTC161480  
Email : customercare.ddrc@agilus.in



Patient Ref. No. 66600007977228

<b>PATIENT NAME : MR. MAHESH KUMAR</b>		<b>REF. DOCTOR : SELF</b>	
<b>CODE/NAME &amp; ADDRESS :</b> CA00010147 - MEDIWHEEL ARCOFEMI HEALTHCARE LIMITED F701A, LADO SARAI, NEW DELHI,SOUTH DELHI, DELHI, SOUTH DELHI 110030 8800465156	<b>ACCESSION NO :</b> <b>4182XB008681</b>	<b>AGE/SEX :</b> 43 Years Male	
	<b>PATIENT ID :</b> MAHEM2402814182	<b>DRAWN :</b>	
	<b>CLIENT PATIENT ID:</b>	<b>RECEIVED :</b> 24/02/2024 09:00:32	
	<b>ABHA NO :</b>	<b>REPORTED :</b> 27/02/2024 09:51:32	

Test Report Status	Final	Results	Units
--------------------	-------	---------	-------

**BIO CHEMISTRY**

**MEDIWHEEL HEALTH CHECKUP ABOVE 40(M)2DECHO**

**BLOOD UREA NITROGEN (BUN), SERUM**

BLOOD UREA NITROGEN 13 Adult(<60 yrs) : 6 to 20 mg/dL

**BUN/CREAT RATIO**

BUN/CREAT RATIO 16.0

**CREATININE, SERUM**

CREATININE 0.81 18 - 60 yrs : 0.9 - 1.3 mg/dL

**GLUCOSE, POST-PRANDIAL, PLASMA**

GLUCOSE, POST-PRANDIAL, PLASMA **183 High** Diabetes Mellitus : > or = 200. mg/dL  
 Impaired Glucose tolerance/  
 Prediabetes : 140 - 199.  
 Hypoglycemia : < 55.

**LIVER FUNCTION TEST WITH GGT**

BILIRUBIN, TOTAL	0.39	General Range : < 1.1	mg/dL
BILIRUBIN, DIRECT	0.16	General Range : < 0.3	mg/dL
BILIRUBIN, INDIRECT	0.23	General Range : <0.85	mg/dL
TOTAL PROTEIN	7.3	Ambulatory : 6.4 - 8.3	g/dL
		Recumbant : 6 - 7.8	
ALBUMIN	4.4	20-60yrs : 3.5 - 5.2	g/dL
GLOBULIN	2.9	General Range : 2 - 3.5	g/dL
		Premature Neonates : 0.29 - 1.04	
ALBUMIN/GLOBULIN RATIO	1.5	General Range : 1.1 - 2.5	RATIO

**DR.HARI SHANKAR, MBBS MD**  
 (Reg No - TCMC:62092)  
 HEAD - Biochemistry &  
 Immunology



View Details



View Report

**PERFORMED AT :**

DDRC AGILUS PATHLABS LIMITED  
 ASTER SQUARE BUILDING, ULLOOR,  
 MEDICAL COLLEGE P.O  
 TRIVANDRUM, 695011  
 KERALA, INDIA  
 Tel : 93334 93334, Fax : CIN - U85190MH2006PTC161480  
 Email : customercare.ddrc@agilus.in



**Patient Ref. No. 66600007977228**

**PATIENT NAME : MR. MAHESH KUMAR**

**REF. DOCTOR : SELF**

**CODE/NAME & ADDRESS :** CA00010147 -  
MEDIWHEEL ARCOFEMI HEALTHCARE LIMITED  
F701A, LADO SARAI, NEW DELHI,SOUTH DELHI,  
DELHI,  
SOUTH DELHI 110030  
8800465156

**ACCESSION NO :** **4182XB008681**  
**PATIENT ID :** MAHEM2402814182  
**CLIENT PATIENT ID:**  
**ABHA NO :**

**AGE/SEX :** 43 Years Male  
**DRAWN :**  
**RECEIVED :** 24/02/2024 09:00:32  
**REPORTED :** 27/02/2024 09:51:32

Test Report Status	Final	Results	Units
--------------------	-------	---------	-------

ASPARTATE AMINOTRANSFERASE (AST/SGOT)	22	Adults : < 40	U/L
ALANINE AMINOTRANSFERASE (ALT/SGPT)	36	Adults : < 45	U/L
ALKALINE PHOSPHATASE	89	Adult(<60yrs) : 40 -130	U/L
GAMMA GLUTAMYL TRANSFERASE (GGT)	17	Adult (Male) : < 60	U/L

**TOTAL PROTEIN, SERUM**

TOTAL PROTEIN	7.3	Ambulatory : 6.4 - 8.3 Recumbant : 6 - 7.8	g/dL
---------------	-----	---	------

**URIC ACID, SERUM**

URIC ACID	6.5	Adults : 3.4-7	mg/dL
-----------	-----	----------------	-------

**GLUCOSE FASTING,FLUORIDE PLASMA**

FBS (FASTING BLOOD SUGAR)	124	Diabetes Mellitus : > or = 126. Impaired fasting Glucose/ Prediabetes : 101 - 125. Hypoglycemia : < 55.	mg/dL
---------------------------	-----	--	-------

**BIOCHEMISTRY - LIPID**

**MEDIWHEEL HEALTH CHECKUP ABOVE 40(M)2DECHO**

**LIPID PROFILE, SERUM**

CHOLESTEROL	167	Desirable : < 200 Borderline : 200-239 High : >or= 240	mg/dL
TRIGLYCERIDES	73	Normal : < 150 High : 150-199	mg/dL

**DR.HARI SHANKAR, MBBS MD**  
(Reg No - TCMC:62092)  
**HEAD - Biochemistry & Immunology**



View Details



View Report

**PERFORMED AT :**

DDRC AGILUS PATHLABS LIMITED  
ASTER SQUARE BUILDING, ULLOOR,  
MEDICAL COLLEGE P.O  
TRIVANDRUM, 695011  
KERALA, INDIA  
Tel : 93334 93334, Fax : CIN - U85190MH2006PTC161480  
Email : customercare.ddrc@agilus.in



**Patient Ref. No. 66600007977228**



**PATIENT NAME : MR. MAHESH KUMAR**

**REF. DOCTOR : SELF**

**CODE/NAME & ADDRESS :** CA00010147 -  
 MEDIWHEEL ARCOFEMI HEALTHCARE LIMITED  
 F701A, LADO SARAI, NEW DELHI,SOUTH DELHI,  
 DELHI,  
 SOUTH DELHI 110030  
 8800465156

**ACCESSION NO :** 4182XB008681  
**PATIENT ID :** MAHEM2402814182  
**CLIENT PATIENT ID:**  
**ABHA NO :**

**AGE/SEX :** 43 Years Male  
**DRAWN :**  
**RECEIVED :** 24/02/2024 09:00:32  
**REPORTED :** 27/02/2024 09:51:32

Test Report Status	Final	Results	Units
--------------------	-------	---------	-------

HDL CHOLESTEROL	<b>38 Low</b>	Hypertriglyceridemia : 200-499 Very High : > 499 General range : 40-60	mg/dL
LDL CHOLESTEROL, DIRECT	124	Optimum : < 100 Above Optimum : 100-129 Borderline High : 130-159 High : 160-189 Very High : >or= 190	mg/dL
NON HDL CHOLESTEROL	129	Desirable : < 130 Above Desirable : 130 -159 Borderline High : 160 - 189 High : 190 - 219 Very high : > / = 220	mg/dL
VERY LOW DENSITY LIPOPROTEIN CHOL/HDL RATIO	14.6 4.4	</= 30.0 Low Risk : 3.3 - 4.4 Average Risk : 4.5 - 7.0 Moderate Risk : 7.1 - 11.0 High Risk : > 11.0	mg/dL
LDL/HDL RATIO	3.3	Desirable/Low Risk - 0.5-3 Borderline/Moderate Risk- 3.1-6 High Risk- >6.0	

**Comments**

Kindly correlate clinically.  
 Kindly contact lab within 24 hrs if clinically not correlated.

**SPECIALISED CHEMISTRY - HORMONE**

**MEDIWHEEL HEALTH CHECKUP ABOVE 40(M)2DECHO**

**THYROID PANEL, SERUM**

T3	123.00	Adult : 80-200	ng/dL
T4	10.70	Adults : 4.5-12.1	µg/dl

**DR.HARI SHANKAR, MBBS MD**  
 (Reg No - TCMC:62092)  
**HEAD - Biochemistry & Immunology**



View Details



View Report

**PERFORMED AT :**

DDRC AGILUS PATHLABS LIMITED  
 ASTER SQUARE BUILDING, ULLLOOR,  
 MEDICAL COLLEGE P.O  
 TRIVANDRUM, 695011  
 KERALA, INDIA  
 Tel : 93334 93334, Fax : CIN - U85190MH2006PTC161480  
 Email : customercare.ddrc@agilus.in



**Patient Ref. No. 66600007977228**

PATIENT NAME : MR. MAHESH KUMAR

REF. DOCTOR : SELF

CODE/NAME & ADDRESS : CA00010147 -  
MEDIWHEEL ARCOFEMI HEALTHCARE LIMITED  
F701A, LADO SARAI, NEW DELHI, SOUTH DELHI,  
DELHI,  
SOUTH DELHI 110030  
8800465156

ACCESSION NO : **4182XB008681**  
PATIENT ID : MAHEM2402814182  
CLIENT PATIENT ID:  
ABHA NO :

AGE/SEX : 43 Years Male  
DRAWN :  
RECEIVED : 24/02/2024 09:00:32  
REPORTED : 27/02/2024 09:51:32

Test Report Status	Final	Results	Units
TSH 3RD GENERATION		3.670	21-50 yrs : 0.4 - 4.2 μIU/mL

## SPECIALISED CHEMISTRY - TUMOR MARKER

**MEDIWHEEL HEALTH CHECKUP ABOVE 40(M)2DECHO****PROSTATE SPECIFIC ANTIGEN, SERUM**

PROSTATE SPECIFIC ANTIGEN	0.349	Age Specific :- <49yrs : <2.5 50-59yrs : <3.5 60-69yrs : <4.5 >70yrs : <6.5	ng/mL
---------------------------	-------	---	-------

## CLINICAL PATH - URINALYSIS

**MEDIWHEEL HEALTH CHECKUP ABOVE 40(M)2DECHO****PHYSICAL EXAMINATION, URINE**

COLOR	YELLOW
APPEARANCE	CLEAR

**CHEMICAL EXAMINATION, URINE**

PH	5.0	4.7 - 7.5
SPECIFIC GRAVITY	1.024	1.003 - 1.035
PROTEIN	NEGATIVE	NOT DETECTED
GLUCOSE	NEGATIVE	NOT DETECTED
KETONES	NEGATIVE	NOT DETECTED
BLOOD	NEGATIVE	NOT DETECTED
BILIRUBIN	NEGATIVE	NOT DETECTED
UROBILINOGEN	NORMAL	NORMAL

METHOD : DIPSTICK



**DR. HARI SHANKAR, MBBS MD**  
(Reg No - TCMC:62092)  
HEAD - Biochemistry &  
Immunology



**DR. VAISHALI RAJAN, MBBS DCP**  
(Pathology)  
(Reg No - TCC 27150)  
HOD - HAEMATOLOGY

Page 7 Of 8



View Details



View Report

**PERFORMED AT :**

DDRC AGILUS PATHLABS LIMITED  
ASTER SQUARE BUILDING, ULLOOR,  
MEDICAL COLLEGE P.O  
TRIVANDRUM, 695011  
KERALA, INDIA  
Tel : 93334 93334, Fax : CIN - U85190MH2006PTC161480  
Email : customercare.ddrc@agilus.in



Patient Ref. No. 66600007977228

**PATIENT NAME : MR. MAHESH KUMAR**

**REF. DOCTOR : SELF**

**CODE/NAME & ADDRESS :** CA00010147 -  
 MEDIWHEEL ARCOFEMI HEALTHCARE LIMITED  
 F701A, LADO SARAI, NEW DELHI,SOUTH DELHI,  
 DELHI,  
 SOUTH DELHI 110030  
 8800465156

**ACCESSION NO :** **4182XB008681**  
**PATIENT ID :** MAHEM2402814182  
**CLIENT PATIENT ID:**  
**ABHA NO :**

**AGE/SEX :** 43 Years Male  
**DRAWN :**  
**RECEIVED :** 24/02/2024 09:00:32  
**REPORTED :** 27/02/2024 09:51:32

Test Report Status	Final	Results	Units
--------------------	-------	---------	-------

NITRITE		NEGATIVE	NOT DETECTED
---------	--	----------	--------------

**MICROSCOPIC EXAMINATION, URINE**

RED BLOOD CELLS	NOT DETECTED	NOT DETECTED	/HPF
WBC	0-1	0-5	/HPF
EPITHELIAL CELLS	0-1	0-5	/HPF
CASTS	NEGATIVE		
CRYSTALS	NEGATIVE		
REMARKS	NIL		

METHOD : AUTOMATED ANALYSER, MICROSCOPY

**DR.VAISHALI RAJAN, MBBS DCP**  
**(Pathology)**  
**(Reg No - TCC 27150)**  
**HOD - HAEMATOLOGY**



View Details



View Report

**PERFORMED AT :**

DDRC AGILUS PATHLABS LIMITED  
 ASTER SQUARE BUILDING, ULLOOR,  
 MEDICAL COLLEGE P.O  
 TRIVANDRUM, 695011  
 KERALA, INDIA  
 Tel : 93334 93334, Fax : CIN - U85190MH2006PTC161480  
 Email : customercare.ddrc@agilus.in



**Patient Ref. No. 66600007977228**