

CID# : 2335720085

Name : MR. BEHERA KALI CHARAN

Age / Gender : 56 Years/Male

Consulting Dr. :

Collected : 23-Dec-2023 / 08:31

Reg. Location : Kandivalli East (Main Centre)

Reported : 24-Dec-2023 / 10:01

PHYSICAL EXAMINATION REPORT

History and Complaints:

HTN since 5 yrs, DM since 8 yrs, Angiography in oct 2023.

EXAMINATION FINDINGS:

Height (cms):	159 cms	Weight (kg):	58 kgs
Temp (0c):	Afebrile	Skin:	Normal
Blood Pressure (mm/hg):	200/100	Nails:	Normal
Pulse:	72/min	Lymph Node:	Not palpable

Systems

Cardiovascular: Normal
 Respiratory: Normal
 Genitourinary: Normal
 GI System: Normal
 CNS: Normal

IMPRESSION:

BP = 200/100
 ↓ Hb 9.48/dl
 ↑ M Sugar 5.6
 ↑ uric acid
 ↑ Sr Potassium
 • HbA1c 7.3%
 • urine - protein 2+

ADVICE:

• Low Carbo diet
 • monitor BP
 • Diabetologist opinion
 • Cardiologist "

• ECG - first degree AV Block
 2D ECHO - mod. LVH
 • Diastolic dysfunction Grade II

CID# : 2335720085

Name : MR.BEHERA KALI CHARAN

Age / Gender : 56 Years/Male

Consulting Dr. :

Collected : 23-Dec-2023 / 08:31

Reg.Location : Kandivali East (Main Centre)

Reported : 24-Dec-2023 / 10:01

CHIEF COMPLAINTS:

- | | |
|--|-------------|
| 1) Hypertension: | Yes |
| 2) IHD | No |
| 3) Arrhythmia | No |
| 4) Diabetes Mellitus | Yes |
| 5) Tuberculosis | No |
| 6) Asthama | No |
| 7) Pulmonary Disease | No |
| 8) Thyroid/ Endocrine disorders | No |
| 9) Nervous disorders | No |
| 10) GI system | No |
| 11) Genital urinary disorder | No |
| 12) Rheumatic joint diseases or symptoms | No |
| 13) Blood disease or disorder | No |
| 14) Cancer/lump growth/cyst | No |
| 15) Congenital disease | No |
| 16) Surgeries | Angiography |
| 17) Musculoskeletal System | No |

PERSONAL HISTORY:

- | | |
|---------------|-----|
| 1) Alcohol | No |
| 2) Smoking | No |
| 3) Diet | Veg |
| 4) Medication | Yes |

*** End Of Report ***

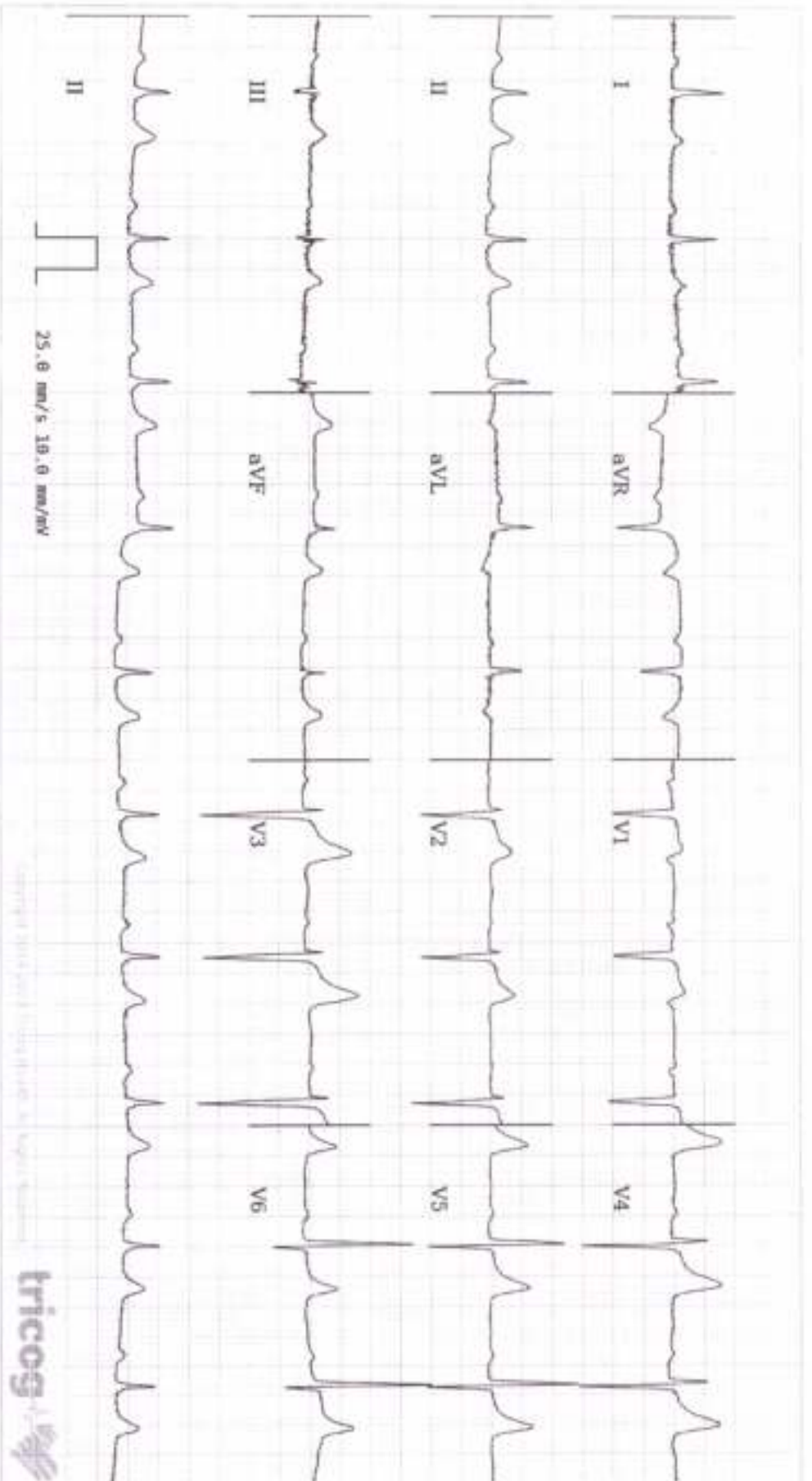
SUBURBAN DIAGNOSTICS (INDIA) PVT. LTD.
Row House No. 3, Aangan,
Thakur Village, Kandivali (east),
Mumbai - 400101.
Tel : 61700000

Dr.JAGRUTI DHALE

SUBURBAN DIAGNOSTICS - KANDIVALI EAST

Patient Name: **BEHERA KALI CHARAN**
Patient ID: **2335720085**

Date and Time: **23rd Dec 23 9:58 AM**



First Degree AV Block, Sinus Rhythm. Please correlate clinically.

Age: **56** NA NA
years months days

Gender: **Male**

Heart Rate: **64bpm**

Patient Vitals

BP: **200/100 mmHg**

Weight: **58 kg**

Height: **159 cm**

Pulse: **NA**

Spo2: **NA**

Resp: **NA**

Others:

Measurements

QRSD: **106ms**

QT: **402ms**

QTcB: **414ms**

PR: **210ms**

P-R-T: **34° 27° 74°**



REPORTED BY

[Signature]

DR. ADARSH PARIKSHAR
MBBS MD MEDICINE, DMCC Cardiology
Cardiologist
38282483

This report is the property of the hospital and should not be used for any other purpose. All rights reserved. The hospital and its staff are not responsible for any errors or omissions in this report. The hospital and its staff are not responsible for any errors or omissions in this report. The hospital and its staff are not responsible for any errors or omissions in this report.

CID : 2335720085
Name : Mr BEHERA KALI CHARAN
Age / Sex : 56 Years/Male
Ref. Dr :
Reg. Location : Kandivali East Main Centre
Reg. Date : 23-Dec-2023
Reported : 23-Dec-2023 / 10:17

Use a QR Code Scanner
Application To Scan the Code

USG WHOLE ABDOMEN

LIVER:

The liver is normal in size (14.1cm), shape and smooth margins. It shows normal parenchymal echo pattern. The intra hepatic biliary and portal radical appear normal. No evidence of any intra hepatic cystic or solid lesion seen. The main portal vein (11mm) and CBD (4.7mm) appears normal.

GALL BLADDER:

The gall bladder is physiologically distended and appears normal. No evidence of gall stones or mass lesions seen

PANCREAS:

The pancreas is well visualised and appears normal. No evidence of solid or cystic mass lesion.

KIDNEYS:

Right kidney measures 9.7 x 4.8 cm. Left kidney measures 10.1 x 5.4 cm.
Both the kidneys are normal in size shape and echotexture.
No evidence of any calculus, hydronephrosis or mass lesion seen.

SPLEEN:

The spleen is normal in size (11cm) and echotexture. No evidence of focal lesion is noted.
There is no evidence of any lymphadenopathy or ascites.

URINARY BLADDER:

The urinary bladder is well distended and reveal no intraluminal abnormality.

PROSTATE:

The prostate is normal in size and measures 3.5 x 3.2 x 3.1 cm and volume is 19 cc.

IMPRESSION: No significant abnormality is seen.

-----End of Report-----

DR. Akash Chhari
MBBS, MD, Radio-Diagnosis Mumbai
MMC REG NO - 2011/09/2862

[Click here to view images <<ImageLink>>](#)

• PATIENT NAME : MR . BEHERA KALI CHARAN	• SEX : MALE
• REFERRED BY : Arcofemi Healthcare Limited	• AGE : 56 YEARS
• CID NO : 2335720085	• DATE : 23/12/2023

2D & M-MODE ECHOCARDIOGRAM REPORT
COLOR FLOW DOPPLER REPORT

ECHO & DOPPLER FINDINGS :

- Moderate concentric left ventricular hypertrophy present
- Diastolic dysfunction grade II
- Left atrium is dilated to 40 mm by planimetry. No intra cavitory clot seen.
- Mild mitral regurgitation seen
- No regional wall motion abnormality seen at rest at present
- All other cardiac chambers appear normal in size.
- All cardiac valves show normal structure.
- No significant stenosis nor regurgitation of the other valves seen
- No defect seen in the inter ventricular and inter atrial septums.
- No evidence of aneurysm / clots / vegetations/ effusion seen.
- TAPSE and MAPSE measured to 17 mm and 15 mm respectively.
- Mild TR jet. PASP by TR jet measured to 25 mm Hg
- IVC appears dilated to 20 mm.
- Visual estimation of LVEF of 55 %.

MEASUREMENTS:

IVS d (mm)	12	Ao (mm)	27
IVS s (mm)	18	LA (mm)	40
LVIDd (mm)	50	EPSS (mm)	02
LVIDs (mm)	31	EF SLOPE (ml/s)	90
Pwd (mm)	11	MV (mm)	16
Pws (mm)	16		

Conti....2

• PATIENT NAME : MR. BEHERA KALI CHARAN	• SEX : MALE
• REFERRED BY : Arcofemi Healthcare Limited	• AGE : 56 YEARS
• CID NO : 2335720085	• DATE : 23/12/2023

DOPPLER: Mitral E / A

Mitral (m/s)	0.8	Aortic (m/s)	1.33
Tricuspid (m/s)	0.5	Pulmonary (m/s)	0.7

TDI

Septal e' = 0.06 m/s

Lateral e' = 0.06 m/s

Septal a' = 0.07 m/s

Lateral a' = 0.08 m/s

Septal s' = 0.04 m/s

Lateral s' = 0.04 m/s

Septal E/e' = 13



Dr. P. Bhatjiwale, M.D

PG cert in Clinical Cardiology,

Fellowship in 2 D Echo & Doppler Studies

Reg. No 68857

NOTE :2D ECHO has a poor sensitivity in cases of angina pectoris and does not rule out CAD

Adv: Please correlate clinically. CMR/ CAG/ Further cardiac evaluation as indicated.

-----End of Report-----



CID : 2335720085
Name : Mr BEHERA KALI CHARAN
Age / Sex : 56 Years/Male
Ref. Dr :
Reg. Location : Kandivali East Main Centre

Reg. Date : 23-Dec-2023
Reported : 25-Dec-2023 / 13:41

Use a QR Code Scanner
Application To Scan the Code

X-RAY CHEST PA VIEW

Both lung fields are clear.

Both costo-phrenic angles are clear.

The cardiac size and shape are within normal limits.

The domes of diaphragm are normal in position and outlines.

The skeleton under review appears normal.

IMPRESSION:

NO SIGNIFICANT ABNORMALITY IS DETECTED.

-----End of Report-----

DR. Akash Chhari
MBBS. MD. Radio-Diagnosis Mumbai
MMC REG NO - 2011/08/2862

Click here to view images <http://3.111.232.119/IRISViewer/NormalViewer?AccessionNo=2023122308321712>

Page no 1 of 1