

Dr. Goyal's

Path Lab & Imaging Centre

B-51, Ganesh Nagar, Near Metro Pillar No. 109-110, New Sanganer Road,
Sodala, Jaipur-302019

Tele : 0141-2293346, 4049787, 9887049787

General Physical Examination

Website: www.drgoyalpathlab.com | E-mail: drgoyalpiyush@gmail.com

Date of Examination: 09-01-24

Name: Mamta Age: 33 Sex: Female

DOB: 16.09.1990

Referred By: BOB

Photo ID: Anchal ID #: attached

Ht: 159 (cm)

Wt: 63 (Kg)

Chest (Expiration): 86 (cm)

Abdomen Circumference: 90 (cm)

Blood Pressure: 130/81 mm Hg PR: 82 / min

BMI 24.9

Eye Examination: vision normal 6/6 N/G.

No Glaucoma blindness.

Other: not significant

On examination he/she appears physically and mentally fit: Yes / No

Signature Of Examinee : Mamta Name of Examinee: mamta

Signature Medical Examiner Dr. Piyush Goyal Name Medical Examiner _____
M.B.B.S. D.M.R.D.
RMC Reg. No. 017996



आधार
DOB : 16/09/1990
Female



4170 9738 5387

आधार - आम आदमी का अधिकार

Mamta



सर्वोच्च न्यायालय
सर्वोच्च न्यायालय
Supreme Court of India

Address:
D/O: Surendra Kumar, ji sukh ka bass, Alipur, Alipur,
Jhunjhunun, Rajasthan, 333023

4170 9738 5387


1947
1800 300 1947

help@uidai.gov.in

www.uidai.gov.in

Piyush Goyal
M.B.B.S., D.M.R.D.
RMC Reg. No.-017996

3555 / Mrs. mamta / 33 Yrs / F / Non Smoker
Heart Rate : 71 bpm / Tested On : 09-Jan-24 09:44:17 / HF 0.05 Hz - LF 35 Hz / Notch 50 Hz / Sn 1.00 Cm/mV / Sw 25 mm/s
/ Refd By: BOB



Vent Rate : 71 bpm
PR Interval : 120 ms
QRS Duration : 86 ms
QT/QTc Int : 364/383 ms
P-QRS-T axis: 61.00° 72.00° 44.00°



Sinus rhythm with poor R progression
Axis
R 72.00° T 44.00° P 61.00°

Reported By:

Dr. Naresh Kumar Mohanika
RMC K8/35703
MBBS, DIP, CARDIO (ESCOARTS),
D.E.M. (PCCP-UK)



Date :- 09/01/2024 08:35:51	Patient ID :-12235184
NAME :- Mrs. MAMTA	Ref. By Doctor:-BOB
Sex / Age :- Female 33 Yrs 3 Mon 25 Days	Lab/Hosp :-
Company :- MediWheel	

Final Authentication : 09/01/2024 12:22:28

***Small hyperechoic SOL in upper uterine cavity? polyp.
 Needs clinical correlation & further evaluation**

2D ECHO OPTION TMT (ADULT/CHILD)

2D-ECHOCARDIOGRAPHY M.MODE WITH DOPPLER STUDY:

FAIR TRANSTHORACIC ECHOCARDIOGRAPHIC WINDOW MORPHOLOGY:

MITRAL VALVE	NORMAL	TRICUSPID VALVE	NORMAL
AORTIC VALVE	NORMAL	PULMONARY VALVE	NORMAL

M.MODE EXAMINATION:

AO	23	mm	LA	29	Mm	IVS-D	8	mm
IVS-S	14	mm	LVID	40	Mm	LVSD	25	mm
LVPW-D	7	mm	LVPW-S	11	Mm	RV		mm
RVWT		mm	EDV		ml	LVVS		ml
LVEF	67 %		RWMA			ABSENT		

CHAMBERS:

LA	NORMAL	RA	NORMAL
LV	NORMAL	RV	NORMAL
PERICARDIUM	NORMAL		

COLOUR DOPPLER:

MITRAL VALVE					
E VELOCITY	1.0	m/sec	PEAK GRADIENT		Mm/hg
A VELOCITY	0.75	m/sec	MEAN GRADIENT		Mm/hg
MVA BY PHT		Cm2	MVA BY PLANIMETRY		Cm2
MITRAL REGURGITATION			ABSENT		
AORTIC VALVE					
PEAK VELOCITY	1.2	m/sec	PEAK GRADIENT		mm/hg
AR VMAX		m/sec	MEAN GRADIENT		mm/hg
AORTIC REGURGITATION			ABSENT		
TRICUSPID VALVE					
PEAK VELOCITY	0.60	m/sec	PEAK GRADIENT		mm/hg
MEAN VELOCITY		m/sec	MEAN GRADIENT		mm/hg
VMax VELOCITY					

Transcript by.

Dr. Goyal's

Path Lab & Imaging Centre

B-51, Ganesh Nagar, Near Metro Pillar No. 109-110, New Sanganeer Road, Jaipur
Tele : 0141-2293346, 4049787, 9887049787
Website : www.drgoyalspathlab.com E-mail : drgoyalpiyush@gmail.com



Date :- 09/01/2024 08:35:51
NAME :- Mrs. MAMTA
Sex / Age :- Female 33 Yrs 3 Mon 25 Days
Company :- MediWheel

Patient ID :- 12235184
Ref. By Doctor :- BOB
Lab/Hosp :-

Final Authentication : 09/01/2024 12:22:28

Impression--

1. Normal LV size & contractility
2. No RWMA, LVEF 67 %.
3. Normal cardiac chamber.
4. Normal valve.
5. No clot, no vegetation, no pericardial effusion.


(Cardiologist)

*** End of Report ***

Transcript by,

Dr. Piyush Goyal
M.B.B.S., D.M.R.D.
RMC Reg No. 017996

Dr. Ashish Choudhary
MBBS, MD (Radio Diagnosis)
Fetal Medicine Consultant
FMF ID - 260517 | RMC No 22430

Dr. Abhishek Jain
MBBS, DNB, (Radio-Diagnosis)
RMC No. 21687

Dr. Navneet Agarwal
MD, DNB (Radio Diagnosis)
RMC No. 33813/14911

Dr. Poorvi Malik
MBBS, MD, DNB (Radio Diagnosis)
RMC No. 21505



Date :- 09/01/2024 08:35:51

NAME :- Mrs. MAMTA

Sex / Age :- Female 33 Yrs 3 Mon 25 Days

Company :- MediWheel

Patient ID :- 12235184

Ref. By Doctor:-BOB

Lab/Hosp :-

Final Authentication : 09/01/2024 12:13:22

BOB PACKAGEFEMALE BELOW 40

ULTRA SOUND SCAN OF ABDOMEN

Liver is mildly enlarged in size 15.8 cm . Echo-texture is bright . No focal space occupying lesion is seen within liver parenchyma. Intra hepatic biliary channels are not dilated. Portal vein diameter is normal.

Gall bladder is of normal size. Wall is not thickened. No calculus or mass lesion is seen in gall bladder. Common bile duct is not dilated.

Pancreas is of normal size and contour. Echo-pattern is normal. No focal lesion is seen within pancreas. **Spleen** is of normal size and shape. Echotexture is normal. No focal lesion is seen.

Kidneys are normally sited and are of normal size and shape. Cortico-medullary echoes are normal. No focal lesion is seen. Collecting system does not show any dilatation. **Left kidney showing two small echogenic shadow around 3 mm mid and lower calyx likely small renal concretions.**

Urinary Bladder: is well distended and showing smooth wall with normal thickness. Urinary bladder does not show any calculus or mass lesion.

Uterus is anteverted and normal in size and measures 74x47x 33 mm. Myometrium shows normal echo - pattern. **Showing a small hyperechoic SOL measuring approx.6.6x4.3 mm in upper uterine cavity.** Endometrial echo is normal. Endometrial thickness is 5.7 mm.

Both ovaries are visualised and are normal. No adnexal mass is seen. right ovary 27x16 mm left ovary 30x13 mm. No enlarged nodes are visualised. No retro-peritoneal lesion is identified. No significant free fluid is seen in pouch of douglas.

IMPRESSION:

- *Mild hepatomegaly with fatty liver.
- *Small left renal concretions
- *Small hyperechoic SOL in upper uterine cavity? polyp.

Page No: 1 of 2

RINKUSAINI

Transcript by.

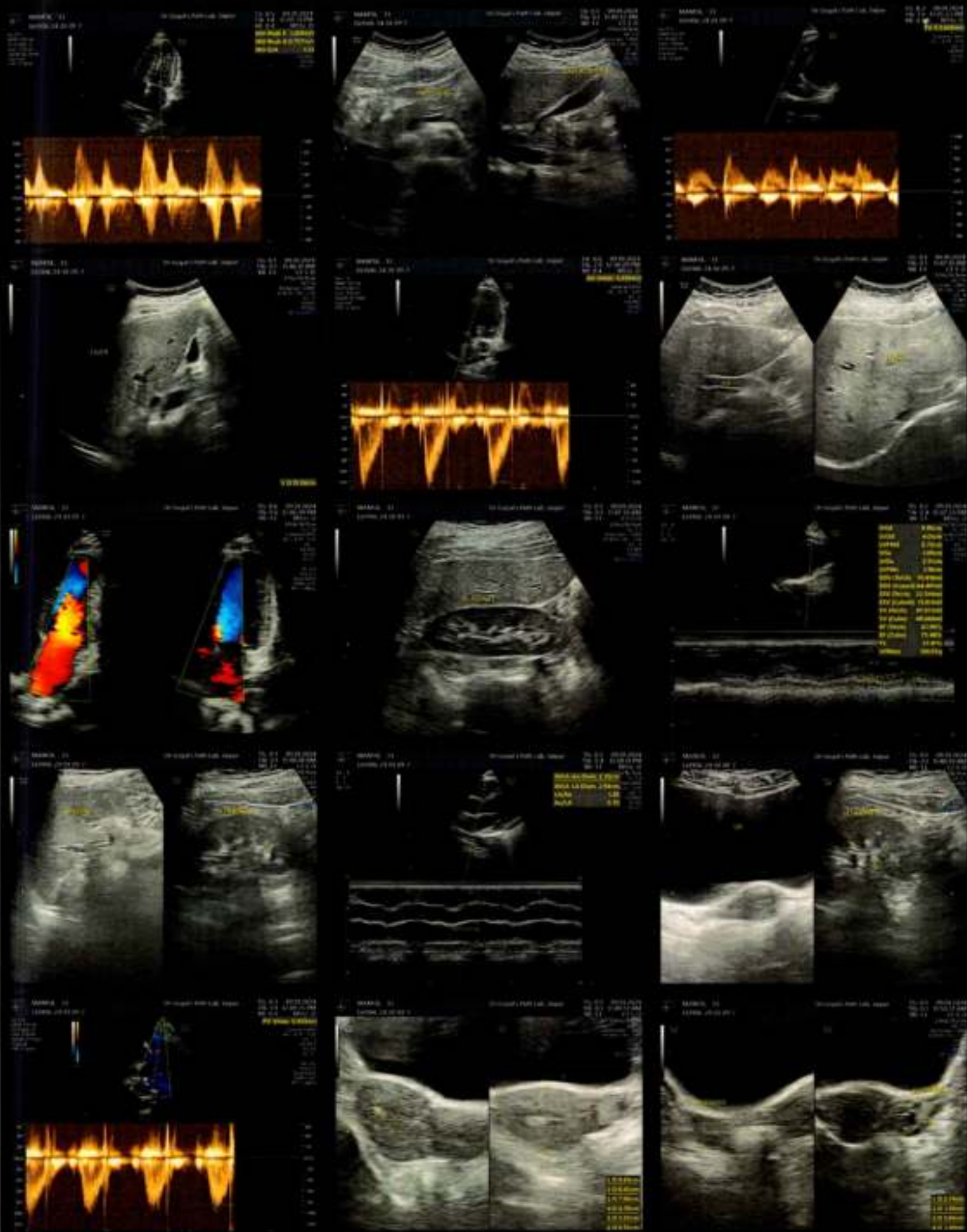
Dr. Piyush Goyal
M.B.B.S., M.R.D.
RMC Reg No. 017996

Dr. Ashish Choudhary
MBBS, MD (Radio Diagnosis)
Fetal Medicine Consultant
FMF ID - 260517 | RMC No 22430

Dr. Abhishek Jain
MBBS, DNB, (Radio-Diagnosis)
RMC No. 21587

Dr. Navneet Agarwal
MD, DNB (Radio Diagnosis)
RMC No. 33813/14911

Dr. Poorvi Malik
MBBS, MD, DNB (Radio Diagnosis)
RMC No. 21505





Date :- 09/01/2024 08:35:51
NAME :- Mrs. MAMTA
Sex / Age :- Female 33 Yrs 3 Mon 25 Days
Company :- MediWheel

Patient ID :- 12235184
Ref. By Doctor :- BOB
Lab/Hosp :-

Final Authentication : 09/01/2024 12:46:28

BOB PACKAGEFEMALE BELOW 40

X RAY CHEST PA VIEW:

Both lung fields appears clear.

Bronchovascular markings appear normal.

Trachea is in midline.

Both the hilar shadows are normal.

Both the C.P.angles is clear.

Both the domes of diaphragm are normally placed.

Bony cage and soft tissue shadows are normal.

Heart shadows appear normal.

Impression :- Normal Study

(Please correlate clinically and with relevant further investigations)



DR ABHISHEK JAIN
MBBS, DNB. (RADIO DIAGNOSIS)
RMC NO. 21687

*** End of Report ***

Dr. Piyush Goyal
(D.M.R.D.) RINKUSAINI

Page No: 1 of 1

Transcript by.

Dr. Piyush Goyal
M.B.B.S., D.M.R.D.
RMC Reg No. 017996

Dr. Ashish Choudhary
MBBS, MD (Radio Diagnosis)
Fetal Medicine Consultant
FMF ID - 260517 | RMC No.22430

Dr. Abhishek Jain
MBBS, DNB, (Radio-Diagnosis)
RMC No. 21687

Dr. Navneet Agarwal
MD, DNB (Radio Diagnosis)
RMC No. 33613/14911

Dr. Poorvi Malik
MBBS, MD, DNB (Radio Diagnosis)
RMC No. 21505

Dr. Goyal's

Path Lab & Imaging Centre



B-51, Ganesh Nagar, Near Metro Pillar No. 109-110, New Sanganer Road, Jaipur-302019
 Tele : 0141-2293346, 4049787, 9887049787
 Website: www.drgoyalpathlab.com | E-mail: drgoyalpiyush@gmail.com

Date :- 09/01/2024 08:35:51 Patient ID :-12235184
NAME :- Mrs. MAMTA Ref. By Dr:- BOB
 Sex / Age :- Female 33 Yrs 3 Mon 25 Days Lab/Hosp :-
 Company :- MediWheel



Sample Type :- EDTA Sample Collected Time 09/01/2024 08:39:55 Final Authentication : 09/01/2024 11:20:58

HAEMATOLOGY

Test Name	Value	Unit	Biological Ref Interval
-----------	-------	------	-------------------------

BOB PACKAGE FEMALE BELOW 40

GLYCOSYLATED HEMOGLOBIN (HbA1C) 6.0 %
 Method:- HPLC

Non-diabetic: < 5.7
 Pre-diabetics: 5.7-6.4
 Diabetics: = 6.5 or higher
 ADA Target: 7.0
 Action suggested: > 6.5

Instrument name: ARKRAY's ADAMS Lite HA 8380V, JAPAN.

Test Interpretation:

HbA1C is formed by the condensation of glucose with n-terminal valine residue of each beta chain of HbA to form an unstable Schiff base. It is the major fraction, constituting approximately 80% of HbA1c. Formation of glycated hemoglobin (GHb) is essentially irreversible and the concentration in the blood depends on both the lifespan of the red blood cells (RBC) (120 days) and the blood glucose concentration. The GHb concentration represents the integrated values for glucose over the period of 6 to 8 weeks. GHb values are free of day to day glucose fluctuations and are unaffected by recent exercise or food ingestion. Concentration of plasma glucose concentration in GHb depends on the time interval, with more recent values providing a larger contribution than earlier values. The interpretation of GHb depends on RBC having a normal life span. Patients with hemolytic disease or other conditions with shortened RBC survival exhibit a substantial reduction of GHb. High GHb have been reported in iron deficiency anemia. GHb has been firmly established as an index of long term blood glucose concentrations and as a measure of the risk for the development of complications in patients with diabetes mellitus. The absolute risk of retinopathy and nephropathy are directly proportional to the mean of HbA1C. Genetic variants (e.g. HbS trait, HbC trait), elevated HbF and chemically modified derivatives of hemoglobin can affect the accuracy of HbA1c measurements. The effects vary depending on the specific Hb variant or derivative and the specific HbA1c method.

Ref by ADA 2020

MEAN PLASMA GLUCOSE 126 mg/dL
 Method:- Calculated Parameter

Non Diabetic < 100 mg/dL
 Prediabetic 100- 125 mg/dL
 Diabetic 126 mg/dL or Higher

MUKESH SINGH
Technologist

Page No: 1 of 12



Dr. Chandrika Gupta
 MBBS.MD (Path)
 RMC NO. 21021/008037

Dr. Goyal's

Path Lab & Imaging Centre



B-51, Ganesh Nagar, Near Metro Pillar No. 109-110, New Sanganer Road, Jaipur-302019
Sodala, Jaipur-302019
Tele : 0141-2293346, 4049787, 9887049787
Website: www.drgoyalpathlab.com | E-mail: drgoyalpiyush@gmail.com

Date :- 09/01/2024 08:35:51
NAME :- Mrs. MAMTA
Sex / Age :- Female 33 Yrs 3 Mon 25 Days
Company :- MediWheel

Patient ID :- 12235184
Ref. By Dr:- BOB
Lab/Hosp :-



Sample Type :- EDTA

Sample Collected Time 09/01/2024 08:39:55

Final Authentication : 09/01/2024 11:20:58

HAEMATOLOGY

Test Name	Value	Unit	Biological Ref Interval
HAEMOGARAM			
HAEMOGLOBIN (Hb)	13.3	g/dL	12.0 - 15.0
TOTAL LEUCOCYTE COUNT	7.54	/cumm	4.00 - 10.00
DIFFERENTIAL LEUCOCYTE COUNT			
NEUTROPHIL	60.3	%	40.0 - 80.0
LYMPHOCYTE	35.0	%	20.0 - 40.0
EOSINOPHIL	2.1	%	1.0 - 6.0
MONOCYTE	2.3	%	2.0 - 10.0
BASOPHIL	0.3	%	0.0 - 2.0
NEUT#	4.55	10 ³ /uL	1.50 - 7.00
LYMPH#	2.64	10 ³ /uL	1.00 - 3.70
EO#	0.15	10 ³ /uL	0.00 - 0.40
MONO#	0.18	10 ³ /uL	0.00 - 0.70
BASO#	0.02	10 ³ /uL	0.00 - 0.10
TOTAL RED BLOOD CELL COUNT (RBC)	5.67 H	x10 ⁶ /uL	3.80 - 4.80
HEMATOCRIT (HCT)	41.30	%	36.00 - 46.00
MEAN CORP VOLUME (MCV)	72.8 L	fL	83.0 - 101.0
MEAN CORP HB (MCH)	23.4 L	pg	27.0 - 32.0
MEAN CORP HB CONC (MCHC)	32.1	g/dL	31.5 - 34.5
PLATELET COUNT	306	x10 ³ /uL	150 - 410
RDW-CV	15.5 H	%	11.6 - 14.0
MENTZER INDEX	12.84		

The Mentzer index is used to differentiate iron deficiency anemia from beta thalassemia trait. If a CBC indicates microcytic anemia, these are two of the most likely causes, making it necessary to distinguish between them. If the quotient of the mean corpuscular volume divided by the red blood cell count is less than 13, thalassemia is more likely. If the result is greater than 13, then iron-deficiency anemia is more likely.

MUKESH SINGH
Technologist

Page No: 2 of 12



Dr. Chandrika Gupta
MBBS.MD (Path)
RMC NO. 21021/008037

Dr. Goyal's

Path Lab & Imaging Centre

B-51, Ganesh Nagar, Near Metro Pillar No. 109-110, New Sanganer Road,
Sodala, Jaipur-302019

Tele : 0141-2293346, 4049787, 9887049787

Website: www.drgoyalpathlab.com | E-mail: drgoyalpiyush@gmail.com

Date :- 09/01/2024 08:35:51

Patient ID :- 12235184

NAME :- Mrs. MAMTA

Ref. By Dr:- BOB

Sex / Age :- Female 33 Yrs 3 Mon 25 Days

Lab/Hosp :-

Company :- MediWheel



Sample Type :- EDTA

Sample Collected Time 09/01/2024 08:39:55

Final Authentication : 09/01/2024 11:20:58

HAEMATOLOGY

Test Name	Value	Unit	Biological Ref Interval
Erythrocyte Sedimentation Rate (ESR)	06	mm/hr.	00 - 20

(ESR) Methodology : Measurement of ESR by cells aggregation.

Instrument Name : Independent form Hematocrit value by Automated Analyzer (Roller-20)

Interpretation : ESR test is a non-specific indicator of inflammatory disease and abnormal protein states.

The test is used to detect, follow course of a certain disease (e.g. tuberculosis, rheumatic fever, myocardial infarction)

Levels are higher in pregnancy due to hyperfibrinogenaemia.

The "3-figure ESR" $\times > 100$ value nearly always indicates serious disease such as a serious infection, malignant paraproteinaemia (CBC), Methodology: TLC, DLC, Fluorescent Flow cytometry, HB SLS method, TRBC, PCV, PLT Hydrodynamically focused Impedance, and MCHC, MCV, MCHC, MENTZER INDEX are calculated. Instrument Name: Sysmex 6 part fully automatic analyzer XN-L, Japan

MUKESH SINGH
Technologist

Page No: 3 of 12



Dr. Chandrika Gupta
MBBS, MD (Path)
RMC NO. 21021/008037

Dr. Goyal's

Path Lab & Imaging Centre



B-51, Ganesh Nagar, Near Metro Pillar No. 109-110, New Sanganeer Road, Meera, Jaipur-302019
Tele : 0141-2293346, 4049787, 9887049787
Website: www.drgoyalspathlab.com | E-mail: drgoyalpiyush@gmail.com

Date :- 09/01/2024 08:35:51 Patient ID :- 12235184
NAME :- Mrs. MAMTA Ref. By Dr.- BOB
Sex / Age :- Female 33 Yrs 3 Mon 25 Days Lab/Hosp :-
Company :- MediWheel



Sample Type :- PLAIN/SERUM Sample Collected Time 09/01/2024 08:39:55 Final Authentication : 09/01/2024 11:01:46

BIOCHEMISTRY

Test Name	Value	Unit	Biological Ref Interval
LIPID PROFILE			
TOTAL CHOLESTEROL Method:- Enzymatic Endpoint Method	240.95 H	mg/dl	Desirable <200 Borderline 200-239 High > 240
TRIGLYCERIDES Method:- GPO-PAP	118.86	mg/dl	Normal <150 Borderline high 150-199 High 200-499 Very high >500
DIRECT HDL CHOLESTEROL Method:- Direct clearance Method	38.06	mg/dl	Low < 40 High > 60
DIRECT LDL CHOLESTEROL Method:- Direct clearance Method	183.08 H	mg/dl	Optimal <100 Near Optimal/above optimal 100-129 Borderline High 130-159 High 160-189 Very High > 190
VLDL CHOLESTEROL Method:- Calculated	23.77	mg/dl	0.00 - 80.00
T.CHOLESTEROL/HDL CHOLESTEROL RATIO Method:- Calculated	6.33 H		0.00 - 4.90
LDL / HDL CHOLESTEROL RATIO Method:- Calculated	4.81 H		0.00 - 3.50
TOTAL LIPID Method:- CALCULATED	683.26	mg/dl	400.00 - 1000.00
<small>TOTAL CHOLESTEROL InstrumentName:Randox Rx Imola Interpretation: Cholesterol measurements are used in the diagnosis and treatment of lipid dysregulation disorders.</small>			
<small>TRIGLYCERIDES InstrumentName:Randox Rx Imola Interpretation: Triglyceride measurements are used in the diagnosis and treatment of diseases involving lipid metabolism and various endocrine disorders e.g. diabetes mellitus, nephrosis and liver obstruction.</small>			
<small>DIRECT HDL CHOLESTEROL InstrumentName:Randox Rx Imola Interpretation: An inverse relationship between HDL-cholesterol (HDL-C) levels in serum and the incidence/prevalence of coronary heart disease (CHD) has been demonstrated in a number of epidemiological studies. Accurate measurement of HDL-C is of vital importance when assessing patient risk from CHD. Direct measurement gives improved accuracy and reproducibility when compared to precipitation methods.</small>			
<small>DIRECT LDL CHOLESTEROL InstrumentName:Randox Rx Imola Interpretation: Accurate measurement of LDL-Cholesterol is of vital importance in therapies which focus on lipid reduction to prevent atherosclerosis or reduce its progress and to avoid plaque rupture.</small>			
<small>TOTAL LIPID AND VLDL ARE CALCULATED</small>			

SURENDRAKHANGA

Page No: 4 of 12



Dr. Chandrika Gupta
MBBS,MD (Path)
RMC NO. 21021/008037

Dr. Goyal's

Path Lab & Imaging Centre



B-51, Ganesh Nagar, Near Metro Pillar No. 109-110, New Sanganeer Road, Sodala, Jaipur-302019

Tele : 0141-2293346, 4049787, 9887049787

Website: www.drgoyalspathlab.com | E-mail: drgoyalpiyush@gmail.com

Date :- 09/01/2024 08:35:51

Patient ID :- 12235184



NAME :- Mrs. MAMTA

Ref. By Dr:- BOB

Sex / Age :- Female 33 Yrs 3 Mon 25 Days

Lab/Hosp :-

Company :- MediWheel

Sample Type :- PLAIN/SERUM

Sample Collected Time 09/01/2024 08:39:55

Final Authentication : 09/01/2024 11:01:46

BIOCHEMISTRY

Test Name	Value	Unit	Biological Ref Interval
LIVER PROFILE WITH GGT			
SERUM BILIRUBIN (TOTAL) Method:- Colorimetric method	0.32	mg/dl	Up to - 1.0 Cord blood <2 Premature < 6 days <16 Full-term < 6 days= 12 1month - <12 months <2 1-19 years <1.5 Adult - Up to - 1.2 Ref-(ACCP 2020)
SERUM BILIRUBIN (DIRECT) Method:- Colorimetric Method	0.01	mg/dL	Adult - Up to 0.25 Newborn - <0.6 >- 1 month - <0.2
SERUM BILIRUBIN (INDIRECT) Method:- Calculated	0.31	mg/dl	0.30-0.70
SGOT Method:- IFCC	26.6	U/L	Men- Up to - 37.0 Women - Up to - 31.0
SGPT Method:- IFCC	9.8	U/L	Men- Up to - 40.0 Women - Up to - 31.0
SERUM ALKALINE PHOSPHATASE Method:- AMP Buffer	50.40	IU/L	30.00 - 120.00
SERUM GAMMA GT Method:- IFCC	27.90	U/L	7.00 - 32.00
SERUM TOTAL PROTEIN Method:- Biuret Reagent	8.06	g/dl	6.40 - 8.30
SERUM ALBUMIN Method:- Bromocresol Green	4.74	g/dl	3.80 - 5.00
SERUM GLOBULIN Method:- CALCULATION	3.32	gm/dl	2.20 - 3.50
A/G RATIO	1.43		1.30 - 2.50

Total Bilirubin Methodology: Colorimetric method Instrument/Name: Randox Rx Ixela Interpretation: An increase in bilirubin concentration in the serum occurs in toxic or infectious diseases of the liver e.g. hepatitis B or obstruction of the bile duct and in chronic incompatible haemolysis. High levels of unconjugated bilirubin indicate that too much haemoglobin is being destroyed or that the liver is not actively treating the haemoglobin it is receiving.

AST Aspartate Aminotransferase Methodology: IFCC Instrument/Name: Randox Rx Ixela Interpretation: Elevated levels of AST can signal myocardial infarction, hepatic disease, muscular dystrophy and organ damage. Although heart muscle is found to have the most activity of the enzyme, significant activity has also been seen in the brain, liver, gastric mucosa, adipose tissue and kidneys of humans.

ALT Alanine Aminotransferase Methodology: IFCC Instrument/Name: Randox Rx Ixela Interpretation: The enzyme ALT has been found to be in highest concentrations in the liver, with decreasing concentrations found in kidney, heart, skeletal muscle, pancreas, spleen and lung tissue respectively. Elevated levels of the transaminase can indicate myocardial infarction, hepatic disease, muscular dystrophy and organ damage.

Alkaline Phosphatase Methodology: AMP Buffer Instrument/Name: Randox Rx Ixela Interpretation: Measurements of alkaline phosphatase are of use in the diagnosis, treatment and investigation of hepatobiliary disease and in bone disease associated with increased osteoblastic activity. Alkaline phosphatase is also used in the diagnosis of parathyroid and intestinal disease.

TOTAL PROTEIN Methodology: Biuret Reagent Instrument/Name: Randox Rx Ixela Interpretation: Measurements obtained by this method are used in the diagnosis and treatment of a variety of diseases involving the liver, kidney and bone marrow as well as other metabolic or nutritional disorders.

ALBUMIN (ALB) Methodology: Bromocresol Green Instrument/Name: Randox Rx Ixela Interpretation: Albumin measurements are used in the diagnosis and treatment of numerous diseases involving primarily the liver or kidneys. Globulin & A/G ratio is calculated.

Instrument Name: Randox Rx Ixela Interpretation: Elevations in GGT levels appear earlier and more pronounced than those with other liver enzymes in cases of obstructive jaundice and metastatic neoplasms. It may reach 5 to 30 times normal levels in intra- or post-hepatic biliary obstruction. Only moderate elevations in the enzyme level (2 to 5 times normal)

SURENDRAKHANGA

Page No: 5 of 12



Dr. Chandrika Gupta
MBBS, MD (Path)
RMC NO. 21021/008037

Dr. Goyal's

Path Lab & Imaging Centre



B-51, Ganesh Nagar, Near Metro Pillar No. 109-110, New Sanganeer Road, Jaipur-302019
Sodala, Jaipur-302019
Tele : 0141-2293346, 4049787, 9887049787
Website: www.drgoyalspathlab.com | E-mail: drgoyalpiyush@gmail.com

Date :- 09/01/2024 08:35:51

Patient ID :- 12235184

NAME :- Mrs. MAMTA

Ref. By Dr:- BOB

Sex / Age :- Female 33 Yrs 3 Mon 25 Days

Lab/Hosp :-

Company :- MediWheel



Sample Type :- PLAIN/SERUM

Sample Collected Time 09/01/2024 08:39:55

Final Authentication : 09/01/2024 10:26:31

IMMUNOASSAY

Test Name	Value	Unit	Biological Ref Interval
TOTAL THYROID PROFILE			
SERUM TOTAL T3 Method:- Chemiluminescence(Competitive immunoassay)	1.270	ng/ml	0.970 - 1.690
SERUM TOTAL T4 Method:- Chemiluminescence(Competitive immunoassay)	10.000	ug/dl	5.500 - 11.000
SERUM TSH ULTRA Method:- Enhanced Chemiluminescence Immunoassay	1.979	μIU/mL	0.350 - 5.500

Interpretation: Triiodothyronine (T3) contributes to the maintenance of the euthyroid state. A decrease in T3 concentration of up to 50% occurs in a variety of clinical situations, including acute and chronic disease. Although T3 results alone cannot be used to diagnose hypothyroidism, T3 concentration may be more sensitive than thyroxine (T4) for hyperthyroidism. Consequently, the total T3 assay can be used in conjunction with other assays to aid in the differential diagnosis of thyroid disease. T3 concentrations may be altered in some conditions, such as pregnancy, that affect the capacity of the thyroid hormone-binding proteins. Under such conditions, Free T3 can provide the best estimate of the metabolically active hormone concentration. Alternatively, T3 uptake, or T4 uptake can be used with the total T3 result to calculate the free T3 index and estimate the concentration of free T3.

Interpretation: The measurement of Total T4 aids in the differential diagnosis of thyroid disease. While >99.9% of T4 is protein-bound, primarily to thyroxine-binding globulin (TBG), it is the free fraction that is biologically active. In most patients, the total T4 concentration is a good indicator of thyroid status. T4 concentrations may be altered in some conditions, such as pregnancy, that affect the capacity of the thyroid hormone-binding proteins. Under such conditions, free T4 can provide the best estimate of the metabolically active hormone concentration. Alternatively, T3 uptake may be used with the total T4 result to calculate the free T4 index (FT4I) and estimate the concentration of free T4. Some drugs and some nonthyroidal patient conditions are known to alter TT4 concentrations in vivo.

Interpretation: TSH stimulates the production of thyroxine (T4) and triiodothyronine (T3) by the thyroid gland. The diagnosis of overt hypothyroidism by the finding of a low total T4 or free T4 concentration is readily confirmed by a raised TSH concentration. Measurement of low or undetectable TSH concentrations may assist the diagnosis of hyperthyroidism, where concentrations of T4 and T3 are elevated and TSH secretion is suppressed. These have the advantage of discriminating between the concentrations of TSH observed in thyrotoxicosis, compared with the low, but detectable, concentrations that occur in subclinical hyperthyroidism. The performance of this assay has not been established for neonatal specimens. Some drugs and some nonthyroidal patient conditions are known to alter TSH concentrations in vivo.

INTERPRETATION

PREGNANCY	REFERENCE RANGE FOR TSH IN uIU/mL (As per American Thyroid Association)
1st Trimester	0.10-2.50
2nd Trimester	0.20-3.00
3rd Trimester	0.30-3.00

NARENDRAKUMAR
Technologist

Page No: 6 of 12



Dr. Chandrika Gupta
MBBS.MD (Path)
RMC NO. 21021/008037

Dr. Goyal's

Path Lab & Imaging Centre



B-51, Ganesh Nagar, Near Metro Pillar No. 109-110, New Sanganeer Road, Jaipur-302019

Sodala, Jaipur-302019

Tele : 0141-2293346, 4049787, 9887049787

Website: www.drgoyalpathlab.com | E-mail: drgoyalpiyush@gmail.com

Date :- 09/01/2024 08:35:51

Patient ID :- 12235184

NAME :- Mrs. MAMTA

Ref. By Dr:- BOB

Sex / Age :- Female 33 Yrs 3 Mon 25 Days

Lab/Hosp :-

Company :- MediWheel



Sample Type :- URINE

Sample Collected Time 09/01/2024 08:39:55

Final Authentication : 09/01/2024 10:41:42

CLINICAL PATHOLOGY

Test Name	Value	Unit	Biological Ref Interval
Urine Routine			
PHYSICAL EXAMINATION			
COLOUR	PALE YELLOW		PALE YELLOW
APPEARANCE	Clear		Clear
CHEMICAL EXAMINATION			
REACTION(PH) Method:- Reagent Strip(Double indication blue reaction)	6.5		5.0 - 7.5
SPECIFIC GRAVITY Method:- Reagent Strip(bromthymol blue)	1.025		1.010 - 1.030
PROTEIN Method:- Reagent Strip (Sulphosalicylic acid test)	NIL		NIL
GLUCOSE Method:- Reagent Strip (Glu.Oxidase Peroxidase Benedict)	NIL		NIL
BILIRUBIN Method:- Reagent Strip (Azo-coupling reaction)	NEGATIVE		NEGATIVE
UROBILINOGEN Method:- Reagent Strip (Modified ehrlich reaction)	NORMAL		NORMAL
KETONES Method:- Reagent Strip (Sodium Nitroprusside) Rothera's	NEGATIVE		NEGATIVE
NITRITE Method:- Reagent Strip (Diazotization reaction)	NEGATIVE		NEGATIVE
MICROSCOPY EXAMINATION			
RBC/HPF	NIL	/HPF	NIL
WBC/HPF	2-3	/HPF	2-3
EPITHELIAL CELLS	2-3	/HPF	2-3
CRYSTALS/HPF	ABSENT		ABSENT
CAST/HPF	ABSENT		ABSENT
AMORPHOUS SEDIMENT	ABSENT		ABSENT
BACTERIAL FLORA	ABSENT		ABSENT
YEAST CELL	ABSENT		ABSENT
OTHER	ABSENT		ABSENT

VIJENDRAMEENA
Technologist

Page No: 7 of 12



Dr. Chandrika Gupta
MBBS.MD (Path)
RMC NO. 21021/008037

Dr. Goyal's

Path Lab & Imaging Centre



B-51, Ganesh Nagar, Near Metro Pillar No. 109-110, New Sanganeer Road, Sodala, Jaipur-302019

Tele : 0141-2293346, 4049787, 9887049787

Website: www.drgoyalpathlab.com | E-mail: drgoyalpiyush@gmail.com

Date :- 09/01/2024 08:35:51

Patient ID :- 12235184



NAME :- Mrs. MAMTA

Ref. By Dr:- BOB

Sex / Age :- Female 33 Yrs 3 Mon 25 Days

Lab/Hosp :-

Company :- MediWheel

Sample Type :- KOx/Na FLUORIDE-F, KOx/Na Sodium Bicarbonate BUIN/BBU/024 08:39:55

Final Authentication : 09/01/2024 12:25:30

BIOCHEMISTRY

Test Name	Value	Unit	Biological Ref Interval
-----------	-------	------	-------------------------

FASTING BLOOD SUGAR (Plasma)

104.2

mg/dl

75.0 - 115.0

Method:- GOD PAP

Impaired glucose tolerance (IGT)

111 - 125 mg/dL

Diabetes Mellitus (DM)

> 126 mg/dL

Instrument Name: Randox Rx Imola **Interpretation:** Elevated glucose levels (hyperglycemia) may occur with diabetes, pancreatic neoplasm, hyperthyroidism and adrenal cortical hyper-function as well as other disorders. Decreased glucose levels (hypoglycemia) may result from excessive insulin therapy or various liver diseases.

BLOOD SUGAR PP (Plasma)

106.4

mg/dl

70.0 - 140.0

Method:- GOD PAP

Instrument Name: Randox Rx Imola **Interpretation:** Elevated glucose levels (hyperglycemia) may occur with diabetes, pancreatic neoplasm, hyperthyroidism and adrenal cortical hyper-function as well as other disorders. Decreased glucose levels (hypoglycemia) may result from excessive insulin therapy or various liver diseases.

SERUM CREATININE

0.86

mg/dl

Men - 0.6-1.30

Women - 0.5-1.20

Method:- Colorimetric Method

SERUM URIC ACID

4.20

mg/dl

Men - 3.4-7.0

Women - 2.4-5.7

Method:- Enzymatic colorimetric

SURENDRAKHANGA

Page No: 9 of 12



Dr. Chandrika Gupta
MBBS,MD (Path)
RMC NO. 21021/008037

Dr. Goyal's

Path Lab & Imaging Centre

B-51, Ganesh Nagar, Near Metro Piller No. 109-110, New Sanganer Road,
Sodala, Jaipur-302019
Tele : 0141-2293346, 4049787, 9887049787
Website: www.drgoyalpathlab.com | E-mail: drgoyalpiyush@gmail.com

Date :- 09/01/2024 08:35:51

Patient ID :-12235184



NAME :- Mrs. MAMTA

Ref. By Dr:- BOB

Sex / Age :- Female 33 Yrs 3 Mon 25 Days

Lab/Hosp :-

Company :- MediWheel

Sample Type :- URINE-PP

Sample Collected Time:09/01/2024 08:39:55

Final Authentication : 09/01/2024 14:38:07

BOB PACKAGEFEMALE BELOW 40

URINE SUGAR PP
Collected Sample Received

Nil

Nil

*** End of Report ***

VIJENDRAMEENA
Technologist

Page No: 1 of 1



Dr. Chandrika Gupta
MBBS,MD (Path)
RMC NO. 21021/008037