

Health Check up Booking Confirmed Request(bobS12059),Package Code-PKG10000474, Beneficiary Code-287380

1 message

Mediwheel <wellness@mediwheel.in>

28 February 2024 at 17:31

To: vidhidiagnostics@gmail.com

Cc: customercare@mediwheel.in



011-41195959

Hi VIDHI DIAGNOSTICS,

The following booking has been confirmed. It is requested to honor the said booking & provide priority services to our client

Hospital Package Name : Mediwheel Full Body Health Checkup Male Below 40

Patient Package Name : Mediwheel Full Body Health Checkup Male Below 40

Package Code : PKG10000474

Appointment Date : 29-02-2024



Confirmation Status : Booking Confirmed

Preferred Time : 8:30am

Member Information		
Booked Member Name	Age	Gender
Abhishek Shah	34 year	Male

We request you to facilitate the employee on priority.

Thanks,
Mediwheel Team
Please Download Mediwheel App



You have received this mail because your e-mail ID is registered with Arcofami Healthcare Limited. This is a system-generated e-mail please don't reply to this message.

Please visit to our [Terms & Conditions](#) for more information. [Click here to unsubscribe.](#)

Health Check up Booking Request(bobS12059), Beneficiary Code-150349

1 message

Mediwheel <wellness@mediwheel.in>
To: vidhidiagnostics@gmail.com
Cc: customercare@mediwheel.in

28 February 2024 at 12:59



Mediwheel
...Your wellness partner

011-41195959

Dear VIDHI DIAGNOSTICS

We have received a booking request with the following details. Provide your confirmation by clicking on the Yes button.

You confirm this booking? Yes No

Name : MS. SHAH SUHANI DILIPBHAI
Hospital Package Name : Mediwheel Full Body Health Checkup Male Below 40
Name of Diagnostic/Hospital : VIDHI DIAGNOSTICS
Address of Diagnostic/Hospital- : L-86 Swatantra - Senani Nagar , Opp- Akhbarnagar Bus Terminals, New Wadaj , Ahmedabad -13
Appointment Date : 29-02-2024

Member Information

Booked Member Name	Age	Gender
Abhishek Shah	34 year	Male

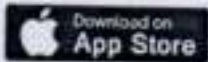

Tests included in this Package -

- Stool Test
- Thyroid Profile
- ESR
- Blood Glucose (Fasting)
- General Physician Consultation
- TMT OR 2D ECHO
- Blood Group
- Blood Glucose (Post Prandial)
- Chest X-ray
- ECG
- USG Whole Abdomen
- Eye Check-up consultation
- Urine Sugar Fasting
- Urine Sugar PP
- Dental Consultation
- Urine analysis

- CBC
- HbA1c
- Lipid Profile
- Kidney Profile
- Liver profile

Thanks,
Mediwheel Team

Please Download Mediwheel App



You have received this mail because your e-mail ID is registered with **Arcofemi Healthcare Limited** This is a system-generated e-mail please don't reply to this message.

Please visit to our [Terms & Conditions](#) for more information. [Click here to unsubscribe.](#)

© 2024 - 25, Arcofemi Healthcare Pvt Limited.(Mediwheel)

Dr. Dinesh S. Modh

M.D., D.M.R.E. (Radiodiagnosis)
Consultant Radiologist & Sonologist
Ex. Junior Lecturer, B.J. Medical College, Civil Hospital, A'bad.

VIDHI
DIAGNOSTICS

129/02/2024

NAME :- Shah Abhishek.

Age :- 34 yr / Male.

Height :- 183 cm

Weight :- 77 kg.

BP :- 122/88 mm Hg.

PULSE :- 70 Perz min.

T :- (N)

RS } (N)
Cvs }

SPO2 :- 98.

Asthmatic

H/O :- DM since 8-yr Tab. Atoglimi
NO HTN, Thyroid o TB.

Advice :- He is Physically Fit

Dr. Vidhi D. Modh
Reg. No. 6-74540

Vidhi Diagnostics
L-86, Swatantra Senani Nagar,
Opp. Akhbarnagar Bus Terminals,
Nr. Akhbarnagar Circle,
New Wada, Ahmedabad-13.

ISO 9001:2015 Certified Diagnostics Center

Vidhi Imaging Center

L-86, Swatantra Senani Nagar, Opp. Indian Oil Petrol Pump, Akhbarnagar Circle, Nava Vada, Ahmedabad - 380 013.

Phone : (Radiology) 079-2762 1406 | M. 98799 29406, 98250 09406 | Time (Radiology) : Mon. to Sat. 9 am to 2 pm, 5 to 9 pm, Sunday 9 am to 12 Noon

E-mail : vidhidiagnostics@gmail.com, Website : www.vidhidiagnostics.com

Multislice CT Scan | CBCT-Dental Scan | Live 3D-4D Sonography | Colour Doppler | Echo Cardiography | Interventional Radiology | Maxillofacial Radiology | Fetal Medicine
Digital X-Ray | Digital Mammography | Digital OPG / TMJ | ECG / TMT / PFT / EEG / EMG | Audiometry | Pathology Laboratory | Health Check Up Plans | Pre Employment Check Up

CT SCAN & CBCT FACILITY NOW AVAILABLE

Dr. Dinesh S. Modh

M.D.; D.M.R.E. (Radiodiagnosis)

Consultant Radiologist & Sonologist

Ex. Junior Lecturer, B.J. Medical College, Civil Hospital, Abad.

VIDHI
DIAGNOSTICS



29/2/2024

10:28 AM

Sub : Unable to provide stool sample

Dear Sir,

I am unable to provide the stool sample at ~~time~~ this time due to unforeseen reason. I appreciate your understanding.

Regards,

Abhishek Shah

Vidhi Diagnostics

L-86, Swatantra Senari Nagar,
Opp. Akhbarnagar Bus Terminals,
Nr. Akhbarnagar Circle,
New Vadaj, Ahmedabad-13.

ISO 9001:2015 Certified Diagnostics Center

Vidhi Imaging Center

L-86, Swatantra Senari Nagar, Opp. Indian Oil Petrol Pump, Akhbarnagar Circle, Nava Vadaj, Ahmedabad - 380 013.

Phone : (Radiology) 079-2762 1406 | M. 98799 29406, 98250 09406 | Time (Radiology) : Mon. to Sat. 9 am to 2 pm, 5 to 9 pm, Sunday 9 am to 12 Noon

E-mail : vidhidiagnostics@gmail.com, Website : www.vidhidiagnostics.com

Multislice CT Scan | CBCT-Dental Scan | Live 2D-4D Sonography | Colour Doppler | Echo Cardiography | Interventional Radiology | Maxillofacial Radiology | Fetal Medicine
Digital X-Ray | Digital Mammography | Digital OPG/TMJ | ECG/TMT/PFT/EEG/EMG | Audiometry | Pathology Laboratory | Health Check Up Plans | Pre Employment Check Up

CT SCAN & CBCT FACILITY NOW AVAILABLE

Dr. Dinesh S. Modh

M.D., D.M.R.E. (Radiodiagnosis)

Consultant Radiologist & Sonologist

Ex. Junior Lecturer, B.J. Medical College, Civil Hospital, A'bad.



Patient's name : ABHISHEK SHAH
Reg. ID : R-13723-23
Referred by : Dr. MEDIWHEEL

Age/Sex : 34 Years/Male
Accession : 23069
Date : 29/02/2024

2D- ECHO REPORT

FINAL CONCLUSION:

LV IS NORMAL SIZE. GOOD LV SYSTOLIC FUNCTION NO RWMA.
LVEF - 60%. NO CONCENTRIC LVH.
NORMAL LV COMPLANCE.
LA IS NORMAL SIZE. NO LA CLOT.
RV IS NORMAL SIZE. GOOD RV SYSTOLIC FUNCTION.
RA IS NORMAL SIZE.
MITRAL VALVE IS NORMAL. NO MS. MILD MR (10%). NO MVP.
AORTIC VALVE IS NORMAL. NO AS. NO AR.
TRICUSPID VALVE IS NORMAL. NO TR. RVSP-26 mmHg. NO PAH.

NO CLOT, NO VEGETATION, NO PERICARDIAL EFFUSION.

DIMENSIONS:

AORTA	2.6 C.M
LEFT ATRIUM	2.7 C.M
LVDD	4.1 C.M.
IVSD	1.0 C.M
PWD	1.0 C.M
LVDS	2.6 C.M.

COLOUR DOPPLER FINDING:

STRUCTURE	VELOCITY m/sec
	Max
PULMONARY VALVE	0.7
MITRAL VALVE	E : 0.7 A : 0.4
AORTIC VALVE	1.0

Dr. Avinash Bhaskar

DR AVINASH BHASKAR
CLINICAL CARDIOLOGIST

9924836431

ISO 9001:2015 Certified Diagnostics Center

Vidhi Imaging Center

L-86, Swatantra Senani Nagar, Opp. Indian Oil Petrol Pump, Akhbarnagar Circle, **Nava Vadaj**, Ahmedabad - 380 013.

Phone : (Radiology) 079-2762 1406 | M. 98799 29406, 98250 09406 | Time (Radiology) : Mon. to Sat. 9 am to 2 pm, 5 to 9 pm, Sunday 9 am to 12 Noon

E-mail : vidhidiagnostics@gmail.com, Website : www.vidhidiagnostics.com

Multislice CT Scan | CBCT-Dental Scan | Live 3D-4D Sonography | Colour Doppler | Echo Cardiography | Interventional Radiology | Maxillofacial Radiology | Fetal Medicine
Digital X-Ray | Digital Mammography | Digital OPG/TMJ | ECG/TMT/PFT/EEG/EMG | Audiometry | Pathology Laboratory | Health Check Up Plans | Pre Employment Check Up

CT SCAN & CBCT FACILITY NOW AVAILABLE

Dr. Dinesh S. Modh

M.D., D.M.R.E. (Radiodiagnosis)

Consultant Radiologist & Sonologist

Ex. Junior Lecturer, B.J. Medical College, Civil Hospital, A'bad.



Patient's name : ABHISHEK SHAH
Reg. ID : R-13723-23
Referred by : Dr. MEDIWHEEL

Age/Sex : 34 Years/Male
Accession : 23069
Date : 29/02/2024

USG ABDOMEN

LIVER:- Liver appears normal in size & echo texture. No evidence of focal lesion is seen. IHBR appear normal. Portal vein and CBD appear normal. No e/o calculus is seen in bile duct.

GALL BLADDER:- Gall bladder is distended & appears normal. No evidence of calculus or cholecystitis is seen.

SPLEEN:- Spleen appears normal in size & shows normal echo texture. No evidence of diffuse or focal lesion is seen.

PANCREAS:- Pancreas appears normal size and echo pattern. No e/o diffuse or focal lesion is seen. Main pancreatic duct appears normal.

KIDNEY:- Both Kidneys appear normal in size & echo texture.

- No e/o calculus or hydronephrosis/ hydroureter is seen on both sides.

Cortico-medullary differentiation is maintained on both sides.

Both suprarenal regions appear normal.

No evidence of pre & para aortic lymphadenopathy is seen.

Both suprarenal regions appear normal.

No evidence of pre & para aortic lymphadenopathy is seen.

RIF & BOWEL LOOPS (By high frequency probe):- Normal.

No evidence of dilated or thickened bowel loops is seen.

No evidence of free fluid is seen in abdomen.

Urinary bladder:- appears normal. No e/o calculus or mass lesion is seen in bladder.

Prostate appears normal size and echopattern.

Thanks for reference.

Dr. Dinesh S. Modh
MD D.M.R.E. (Radiodiagnosis)
DR DINESH S. MODH
M.D. DMRE(RADIODIAGNOSIS)

ISO 9001:2015 Certified Diagnostics Center

Vidhi Imaging Center

L-86, Swatantra Senani Nagar, Opp. Indian Oil Petrol Pump, Akhbarnagar Circle, Nava Vada, Ahmedabad - 380 013.

Phone : (Radiology) 079-2762 1406 | M. 98799 29406, 98250 09406 | Time (Radiology) : Mon. to Sat. 9 am to 2 pm, 5 to 9 pm, Sunday 9 am to 12 Noon

E-mail : vidhidiagnostics@gmail.com, Website : www.vidhidiagnostics.com

Multislice CT Scan | CBCT-Dental Scan | Live 3D-4D Sonography | Colour Doppler | Echo Cardiography | Interventional Radiology | Maxillofacial Radiology | Fetal Medicine
Digital X-Ray | Digital Mammography | Digital OPG / TMJ | ECG / TMT / PFT / EEG / EMG | Audiometry | Pathology Laboratory | Health Check Up Plans | Pre Employment Check Up

CT SCAN & CBCT FACILITY NOW AVAILABLE

Dr. Dinesh S. Modh

M.D., D.M.R.E. (Radiodiagnosis)

Consultant Radiologist & Sonologist

Ex. Junior Lecturer, B.J. Medical College, Civil Hospital, A'bad.



Patient's name : ABHISHEK SHAH
Reg. ID : R-13723-23
Referred by : Dr. MEDIWHEEL

Age/Sex : 34 Years/Male
Accession : 23069
Date : 29/02/2024

X-RAY CHEST (PA VIEW)

Both lung fields appear normal.
No e/o consolidation or cavitations is seen.
Both costo-phrenic angles appear clear.
Cardiac size is with in normal limits.
Both domes of diaphragm appear normal.
Bony thoracic cage appears normal.

Thanks for reference.

Dr. Dinesh S. Modh

MD DMRE (Radiodiagnosis)

DR DINESH S. MODH

M.D. DMRE(RADIODIAGNOSIS)

ISO 9001:2015 Certified Diagnostics Center

Vidhi Imaging Center

L-86, Swatantra Senani Nagar, Opp. Indian Oil Petrol Pump, Akhbarnagar Circle, Nava Vadaj, Ahmedabad - 380 013.

Phone : (Radiology) 079-2762 1406 | M. 98799 29406, 98250 09406 | Time (Radiology) : Mon. to Sat. 9 am to 2 pm, 5 to 9 pm, Sunday 9 am to 12 Noon

E-mail : vidhidiagnostics@gmail.com, Website : www.vidhidiagnostics.com

Multislice CT Scan | CBCT-Dental Scan | Live 3D-4D Sonography | Colour Doppler | Echo Cardiography | Interventional Radiology | Maxillofacial Radiology | Fetal Medicine
Digital X-Ray | Digital Mammography | Digital DPG / TMJ | ECG / TMT / PFT / EEG / EMG | Audiometry | Pathology Laboratory | Health Check Up Plans | Pre Employment Check Up

CT SCAN & CBCT FACILITY NOW AVAILABLE

29-02-2024 09:43:05

ID: 12767
Name: abhishek shah
Age: 34yrs
Sex: Male
Hospital:
Department:

Dr. Avinash Bhaskar
G-45948

0.67Hz - 35Hz AC 50Hz 25 mm/s 10 mm/mv

HR : 70 bpm
PR : 144 ms
QRS : 90 ms
QT/QTc : 350/378 ms
P/QRS/T : 63/69/59 deg.
RV5/SV1 : 1.963/0.498 mv
RV5+SV1 : 2.461 mv

<< Analysis Result >>

** normal ECG **

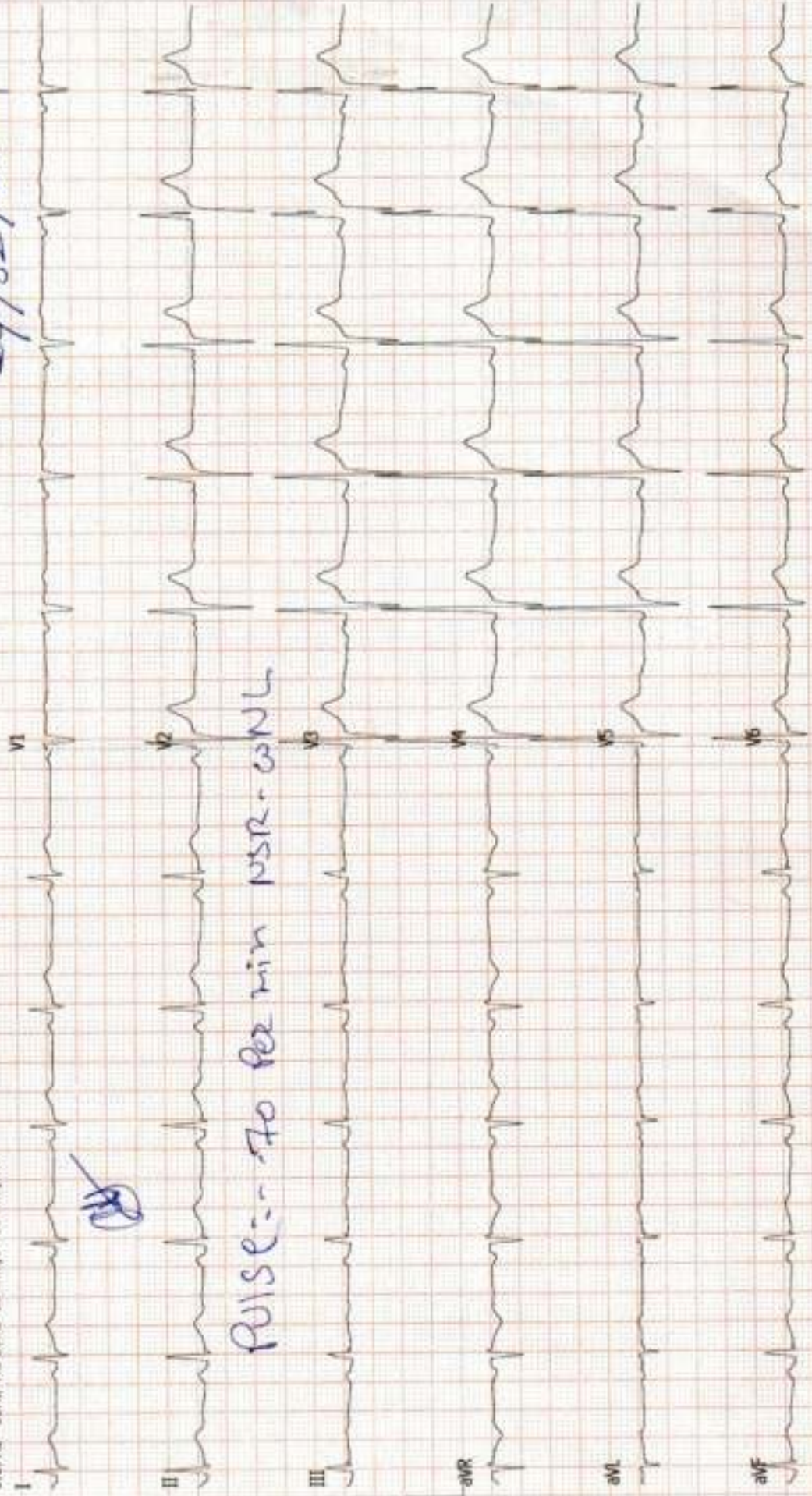
- Sinus rhythm

Vidhi Diagnostics

1-66, Swastika Road, Sector 14, Gurgaon, Haryana
Raj Bahadurgar Bus Terminals,
New Wazirpur, Gurgaon, Haryana
New Wazirpur, Gurgaon, Haryana

Need to be confirmed by doctor. Doctor Name:

Rg/02/2024





Patient's name : SHAH ABHISHEK
Age/Sex : 34 Years/Male
Referred by : Dr. MEDIWHEEL
Collection Time : 09:12

Reg. ID : P-6342-23
Accession : 23046
Order Dt/time : 29/02/2024 09:12

Complete Blood Count

Sample Type: EDTA

Test Name	Result	Units	Biological Reference Interval
<u>Blood Counts</u>			
Haemoglobin :	14.4	Gms%	13.5 - 18.0
Total R.B.C. :	4.87	mill/c.mm	4.7 - 6.0
Total W. B. C. :	5690	/cu mm	4000 - 10500
Platelet Count :	246000	/cu.mm	1,50,000 - 4,50,000
<u>Differential Count</u>			
Neutrophils :	51	%	40 - 70
Lymphocytes :	44	%	20 - 40
Eosinophils :	03	%	1 - 4
Monocytes :	02	%	2 - 6
Basophils :	00	%	0 - 01
<u>Blood Indices</u>			
P. C. V :	42.7	%	42 - 52
M. C. V. :	87.7	f	78 - 100
M.C.H :	29.5	pg	27 - 31
M. C. H. C :	33.7	%	32 - 36
R.D.W :	13.5	%	11.5 - 14.0

E.S.R.(Westergren Method)

After one hour : 04 mm/hr 1 - 7

TESTS DONE ON FULLY AUTOMATED HEMATOLOGY ANALYZER

Dr. Gayatri Mehta
DR. GAYATRI MEHTA
MD(PATHOLOGY)
Reg. No. G-32215

DR. ANAND D. PARIKH
MD(PATHOLOGY)

LAB USE ONLY (Entered by GM Enter Date/Time 29/02/2024 5:12:00 PM) (Verify by GM Verify Date/Time 29/02/2024 5:12:00 PM)



Vidhi Imaging Center | Pathology Department

L-86, Swatantra Senani Nagar, Opp. Akhbarnagar Petrol Pump, Nr. Akhbarnagar Circle, Nava-Vadaj, Ahmedabad - 380 013.
Ph. (Pathology) : 8849893954 M. 98799 29406, 98250 09406, E-mail : vidhidiagnostics@gmail.com, Web. : www.vidhidiagnostics.com
Time (Pathology) : Mon. to Sat. 8.30 am to 8.00 pm, Sunday 9 am to 12 Noon

Pathology means science behind medicine

CT SCAN & CBCT FACILITY NOW AVAILABLE



Patient's name : SHAH ABHISHEK
Age/Sex : 34 Years/Male
Referred by : Dr. MEDIWHEEL
Collection Time : 09:12

Reg. ID : P-6342-23
Accession : 23046
Order Dt/time : 29/02/2024 09:12

HbA1C

Sample Type: EDTA

Test Name	Result	Units	Biological Reference Interval
HbA1C :	<u>6.5</u>	%	Non-diabetic: 4.2-6.2 Pre-diabetic : 6.3-7.2 Diabetic : 7.3-8.2
Mean Blood Glucose of Last 03 months.	139.85	mg/dl	

Comment *As per the new 2009 update of American Diabetes Association regarding HbA1C & Mean Blood Glucose relationship.

NOTE: This test is used to monitor diabetic patients compliance with the therapeutic regimen and logo It's level is proportional to both the average blood glucose concentration and the life span of the red blood cells (RBC) in circulation. HbA1c values are free of day to day glucose fluctuations and are unaffected by exercise or recent food intake.

Dr. Gayatri Mehta
M. D. (Pathol)
Reg. No. G-32215

DR. GAYATRI MEHTA
MD(PATHOLOGY)

DR. ANAND D. PARIKH
MD(PATHOLOGY)

LAB USE ONLY (Entered by: AP Enter Date/Time 29/02/2024 5:07:00 PM) (Verify by: GM Verify Date/Time 29/02/2024 5:09:00 PM)



Vidhi Imaging Center | Pathology Department

L-86, Swatantra Senani Nagar, Opp. Akhbarnagar Petrol Pump, Nr. Akhbarnagar Circle, Nava-Vadaj, Ahmedabad - 380 013.

Ph. (Pathology) : 8849893954 M. 98799 29406, 98250 09406. E-mail : vidhidiagnostics@gmail.com, Web. : www.vidhidiagnostics.com

Time (Pathology) : Mon. to Sat. 8.30 am to 8.00 pm, Sunday 9 am to 12 Noon

Pathology means science behind medicine

CT SCAN & CBCT FACILITY NOW AVAILABLE



Patient's name	: SHAH ABHISHEK	Reg. ID	: P-6342-23
Age/Sex	: 34 Years/Male	Accession	: 23046
Referred by	: Dr. MEDIWHEEL	Order Dt/time	: 29/02/2024 09:12
Collection Time	: 09:12		

Blood Group

Sample Type: EDTA sample.

Test Name	Result
BG :	" O "
RH :	POSITIVE
Remarks	Done by forward grouping method.

Dr. Gayatri Mehta
 M.D. (Pathology)
 Reg. No. G-32215

DR. GAYATRI MEHTA
MD(PATHOLOGY)

DR. ANAND D. PARIKH
MD(PATHOLOGY)

LAB USE ONLY (Entered by: GM Enter Date/Time: 29/02/2024 5:01:00 PM) (Verify by: GM Verify Date/Time: 29/02/2024 5:01:00 PM)



Vidhi Imaging Center | Pathology Department

L-86, Swatantra Serani Nagar, Opp. Akhbarnagar Petrol Pump, Nr. Akhbarnagar Circle, Nava-Vadaj, Ahmedabad - 380 013.

Ph. (Pathology) : 8849893954 M. 98799 29406, 98250 09406, E-mail : vidhidiagnostics@gmail.com, Web. : www.vidhidiagnostics.com
Time (Pathology) : Mon. to Sat. 8.30 am to 8.00 pm, Sunday 9 am to 12 Noon

Pathology means science behind medicine

CT SCAN & CBCT FACILITY NOW AVAILABLE



Patient's name : SHAH ABHISHEK
Age/Sex : 34 Years/Male
Referred by : Dr. MEDIWHEEL
Collection Time : 09:12

Reg ID : P-6342-23
Accession : 23046
Order Dt/time : 29/02/2024 09:12

Blood Glucose

Sample Type: Serum

Test Name	Result	Units	Biological Reference Interval
Post Prandial Blood Glucose After 2hr. :	182.6	mg/dl	80 - 140
<i>GOD-POD Method.</i>			

Thyroid Function Test

Sample Type: Serum

Test Name	Result	Units	Biological Reference Interval
TOTAL T3 :	1.58	ng/ml	0.84 - 2.0
TOTAL T4 :	7.56	µg/dL	5.1 - 14.0
TSH(Ultra sensitive) :	0.66	µIU/mL	0.27 - 4.2

Dr. Gayatri M. Mehta
M.D. (Pathology)
Reg. No. G-32215

DR GAYATRI MEHTA
MD(PATHOLOGY)

DR ANAND D. PARIKH
MD(PATHOLOGY)

LAB USE ONLY (Entered by GM Enter Date/Time 29/02/2024 5:03:00 PM) (Verify by GM Verify Date/Time 29/02/2024 5:00:00 PM)



Vidhi Imaging Center | Pathology Department

L-86, Swatantra Senani Nagar, Opp. Akhbarnagar Petrol Pump, Nr. Akhbarnagar Circle, Nava-Vada], Ahmedabad - 380 013.

Ph. (Pathology) : 8849893954 M. 96799 29406, 98250 09406, E-mail : vidhidiagnostics@gmail.com, Web. : www.vidhidiagnostics.com

Time (Pathology) : Mon. to Sat. 8.30 am to 8.00 pm, Sunday 9 am to 12 Noon

Pathology means science behind medicine

CT SCAN & CBCT FACILITY NOW AVAILABLE



Quality Life in Laboratory



Pathology Department

Patient's name : SHAH ABHISHEK
Age/Sex : 34 Years/Male
Referred by : Dr. MEDIWHEEL
Collection Time : 09:12

Reg. ID : P-6342-23
Accession : 23046
Order Dt/time : 29/02/2024 09:12

Blood Glucose

Sample Type: Serum

Test Name	Result	Units	Biological Reference Interval
Fasting Blood Glucose : <i>GOD-POD Method.</i>	156.9	mg/dl	70 - 110

Lipid Profile

Sample Type: Serum

Test Name	Result	Units	Biological Reference Interval
S. Cholesterol : <i>Oxidase-esterase method</i>	175	mg/dl	0 - 200
S. Triglyceride : <i>Enzymatic Colorimetry method</i>	169.6	mg/dL	0 - 200
S. HDL - Cholesterol : <i>Serum by Enzymatic method.</i>	42.6	mg/dL	35 - 65
S. LDL - Cholesterol : <i>Serum by Enzymatic method</i>	115.8	mg/dL	0 - 130
S. VLDL - Cholesterol :	33.92	mg/dL	0 - 30
S. Chole/HDL.Ratio :	4.11		1 - 6
S. LDL / HDL Cholesterol Ratio :	2.72		0 - 3.5

Dr. Gayatri Mehta
Reg. No. G-32215

DR GAYATRI MEHTA
MD(PATHOLOGY)

DR ANAND D. PARIKH
MD(PATHOLOGY)

LAB USE ONLY (Entered by GM Enter Date/Time 29/02/2024 5:02:00 PM) (Verify by GM Verify Date/Time 29/02/2024 5:02:00 PM)



Vidhi Imaging Center | Pathology Department

L-86, Swatantra Senani Nagar, Opp. Akhbarnagar Petrol Pump, Nr. Akhbarnagar Circle, Nava-Vadaj, Ahmedabad - 380 013.
Ph. (Pathology) : 8849893954 M. 96799 29406, 98250 09406, E-mail : vidhidiagnostics@gmail.com, Web. : www.vidhidiagnostics.com
Time (Pathology) : Mon. to Sat. 8.30 am to 8.00 pm, Sunday 9 am to 12 Noon

Pathology means science behind medicine

CT SCAN & CBCT FACILITY NOW AVAILABLE



Patient's name : SHAH ABHISHEK
Age/Sex : 34 Years/Male
Referred by : Dr. MEDIWHEEL
Collection Time : 09:12

Reg. ID : P-6342-23
Accession : 23046
Order Dt/time : 29/02/2024 09:12

BIOCHEMISTRY

Sample type : Serum

Test Name	Result	Units	Biological Reference Interval
Urea, (Serum by GLDH method)	16.9	mg/dl	10 - 50
S.Uric acid, (Serum by Uricase method)	4.7	mg/dl	3.4 - 7.0
Bun :	7.9	mg/dl	6-20
Creatinine, (Serum by Enzymatic reaction)	0.83	mg/dl	0.5-1.2
S.G.P.T (ALT) : (Serum by IFCC method)	28.5	U/L	0 - 40
S.G.O.T (AST) : (Serum by IFCC method)	18.2	U/L	0 - 37
ALK.PHOSPHATASE : (Serum by PNP method)	74	U/L	40-129
G.G.T :	30.1	U/L	8 - 78
BILIRUBIN			
Total :	0.69	mg/dl	Up to 1.2
Direct :	0.28	mg/dl	0-0.7
Indirect :	0.41	mg/dl	0 - 0.5
SERUM PROTEINS			
Total Protein (Serum by Biuret method)	6.66	gms/dl	6.4 - 8.5
Albumin (Serum by BCG method)	4.38	gms/dl	3.97-4.94
Globulins :	2.28	gms/dl	2.3 - 3.5
A/G Ratio :	1.921		0.9 - 2.9

Dr. Gayatri M. Mehta
Reg. No. G-32215

DR GAYATRI MEHTA
MD(PATHOLOGY)

DR. ANAND D. PARIKH
MD(PATHOLOGY)

LAB USE ONLY (Entered by : GM Enter Date/Time:29/02/2024 5:00:08 PM) (Verify by : GM Verify Date/Time:29/02/2024 5:00:08 PM)



Vidhi Imaging Center | Pathology Department

L-86, Swatantra Senani Nagar, Opp. Akharnagar Petrol Pump, Nr. Akharnagar Circle, Nava-Vadaj, Ahmedabad - 380 013.
Ph. (Pathology) : 8849893954 M. 98799 29406, 98250 09406, E-mail : vidhidiagnostics@gmail.com, Web. : www.vidhidiagnostics.com
Time (Pathology) : Mon. to Sat. 8.30 am to 8.00 pm, Sunday 9 am to 12 Noon

Pathology means science behind medicine

CT SCAN & CBCT FACILITY NOW AVAILABLE



Patient's name : SHAH ABHISHEK
 Age/Sex : 34 Years/Male
 Referred by : Dr. MEDIWHEEL
 Collection Time : 09:12

Reg. ID : P-6342-23
 Accession : 23046
 Order Dt/time : 29/02/2024 09:12

Urine Analysis

Sample Type: Urine

Test Name	Result	Units	Biological Reference Interval
Physical Examination			
Quantity :	20	ml	0 - 500 ml
Colour :	Pale Yellow		Pale Yellow
Transparency :	Slight Turbid.		Clear
Reaction :	Acidic		4.6 - 8.0
Specific Gravity :	1.012		1.016 - 1.022
Sediment :	Present		
Chemical Examination			
Albumin :	Present (Faint Trace)		Absent
Sugar :	NIL		Absent
Acetone :	Absent		Absent
Bile Salts :	Absent		Absent
Bile Pigments :	Absent		Absent
Urobilogen :	Absent		Absent
Nitrites :	Absent		Absent
Microscopic Examination			
Red blood Cells :	1-2	/h.p.f	Absent
Pus Cells :	2-3	/h.p.f	Absent
Epithelial Cells :	1-2	/h.p.f	< 10.0
Amorphous :	Absent	/h.p.f	Absent
Bacteria :	Absent	/h.p.f	Absent
Crystals :	Absent	/h.p.f	Absent
Casts :	Absent	/h.p.f	Absent
Fungus :	Not seen	/h.p.f	Absent

Dr. Gayatri Mehta
 (MD, Pathology)
 Reg. No. G-32215



DR. ANAND D. PARIKH
 MD(PATHOLOGY)

Printed by : GM Enter Date/Time:29/02/2024 5:05:00 PM (Verify by : GM Verify Date/Time:29/02/2024 5:05:00 PM)

Vidhi Imaging Center | Pathology Department

L-86, Swatantra Senani Nagar, Opp. Akhbarnagar Petrol Pump, Nr. Akhbarnagar Circle, Nava-Vadaj, Ahmedabad - 380 013.
 Ph. (Pathology) : 8849893954 M. 98799 29406, 98250 09406. E-mail : vidhidiagnostics@gmail.com, Web. : www.vidhidiagnostics.com
 Time (Pathology) : Mon. to Sat. 8.30 am to 8.00 pm, Sunday 9 am to 12 Noon

Pathology moves science behind medicine

CT SCAN & CBCT FACILITY NOW AVAILABLE

9331 9937 9810

મારો આધાર, મારી ઓળખ

સાહ્યકરણ નંબર
9331 9937 9810

શ્રી શહીદ
Shah Abhishek
જન્મ તારીખ / ડોબ: 21/08/1988
પુરુષ / Male



Vidhi Diagnostics
L-65, Sankarika-Sankar Nagar,
Opp. Ashramnagar Bus Terminal,
Nr. Ashramnagar Circle,
New Vasodaj, Ahmedabad-13.

Abhishek

