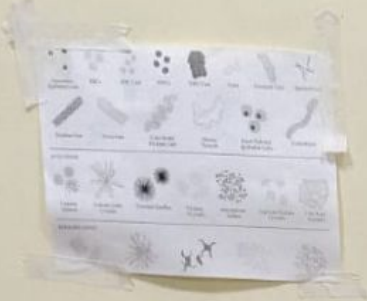



 GPS Map Camera

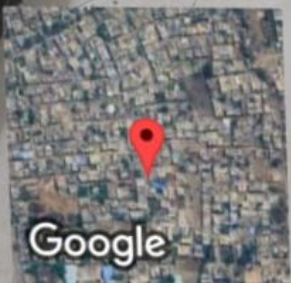**Raipur, Chhattisgarh, India**

6J6W+C64, Krishna Nagar, Santoshi Nagar, Raipur, Mathpurena, Chhattisgarh 492001, India

Lat 21.211104°

Long 81.645631°

14/09/24 11:04 AM GMT +05:30



Google

भारतीय विशिष्ट ओळख प्राधिकरण

भारत सरकार

Unique Identification Authority of India  
Government of India

नोंदविण्याचा क्रमांक / Enrollment No 1104/10023/91953


To,  
विजयेंद्र दिलीप गजभिरे  
Vijayendra Dilip Gajbiye  
S/O Dilip Gajbiye  
NEAR GANDHI KRIDA GROUND PLOT NO. 171,  
CHANDAN NAGAR  
Hanuman Nagar S O  
Nagpur  
Maharashtra 440009  
9890588372

06/01/2012

Ref: 64 / 258 / 127302 / 127680 / P



UE097022616N



आपला आधार क्रमांक / Your Aadhaar No. :

**4807 2139 7289**

**आधार – सामान्य माणसाचा अधिकार**




भारत सरकार

GOVERNMENT OF INDIA



विजयेंद्र दिलीप गजभिरे  
Vijayendra Dilip Gajbiye  
जन्म वर्ष / Year of Birth : 1984  
पुरुष / Male



**4807 2139 7289**



DATE- 14-Sep-24

PATIENT NAME ..... MR. VIJAYENDRA DILIP GAJBHIYE  
AGE/SEX ..... 40 YEAR / MALE  
REF. BY ..... MEDIWHEEL

## **X-RAY CHEST PA VIEW** **Observation & Impression**

- Bilateral lung fields are clear.
- Both costophrenic angles are normal.
- Bilateral hila are normal.
- The cardiac shadow is normal.
- The bony thorax is normal.

**IMPRESSION** No significant abnormality is seen.

*Needs clinical correlation & other investigations.*

Dr. Hulesh Mandle, MD  
Consultant Radiologist  
DR. HULESH MANDLE  
MBBS  
CGMC-223/04

Investigations have their limitation, solitary radiological / pathological and other investigations never confirm the final diagnosis of disease. They only help in diagnosing the disease in correlation to symptom and other related test please interpret accordingly.

**Note-**

1. The report & film are not valid for medico-legal purpose.
2. Please intimate us if any typing mistakes & send the report for correction within 7 days.

DATE- 14-Sep-24

PATIENT NAME	.....	MR. VIJAYENDRA DILIP GAJBHIYE
AGE/SEX	.....	40 YEAR / MALE
REF. BY	.....	MEDIWHEEL

## COLOUR DOPPLER ECHOCARDIOGRAPHY

PROCEDURES: M-MODE/2D/DOPPLER/COLOUR/CONTRAST.

### MEASUREMENTS:

AO	~	2.6 CMS
LA	~	3.5 CMS.
LVDd	~	4.1 CMS.
LVDs	~	2.5 CMS.
IVSd	~	1.0 CMS.
LVPWd	~	1.0 CMS.


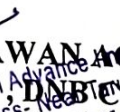
### DOPPLER

E	~	1.1 M/SEC.
A	~	0.8 M/SEC.
AO	~	1.8 M/SEC.

- NORMAL LV AND RV SIZE AND FUNCTION.
- NORMAL PERICARDIUM. NO PERICARDIAL EFFUSION.
- NORMAL PA & AORTA.

### OPINION: -

- ☞ NORMAL CHAMBER SIZE.
- ☞ NO RWMA.
- ☞ GOOD LV SYSTOLIC FUNCTION.
- ☞ EF 60%
- ☞ NO CLOT/MASS.

  
**DR. SAWAN**  & Diagnostic C  
 (MBBS, MD, **Diabetic Cardiology**)  
 Address- Noida Vihar Gali, Santoshi Naga  
 Raipur (C.G.) 492001

*Investigations have their limitation, solitary radiological / pathological and other investigations never confirm the final diagnosis of disease. They only help in diagnosing the disease in correlation to symptom and other related test please interpret accordingly.*



DATE- 14-Sep-24

PATIENT NAME ..... MR. VIJAYENDRA DILIP GAJBHIYE  
AGE/SEX ..... 40 YEAR / MALE  
REF. BY ..... MEDIWHEEL

## **SONOGRAPHY OF THE ABDOMEN**

PROCEDURE DONE BY ULTRASOUND MACHINE Canon Apllo a450 (4D COLOR DOPPLER)

**LIVER** : The liver is normal in size, shape & contour with normal echotexture. No evidence of any Focal lesion or mass seen. The intrahepatic biliary ducts are normal. The CBD is normal in course, caliber & contour. Hepatic & portal vein appear normal in morphology.

**GALL BLADDER** : Appears normal distended. No obvious intraluminal calculus is seen.

**PANCREAS** : It is normal echogenicities and size, shape. Pancreatic duct is normal.

**SPLEEN** : Spleen is normal size, shape and position. No focal lesion seen.

**KIDNEY** : Right kidney measures 10.4 x 3.6 cm.  
Left kidney measures 10.5 x 4.3 cm.  
Both Kidneys are normal size, shape and position.  
Renal parenchymal echogenicities are normal.  
No evidence of any calculus or pelvicalyceal dilation.

**URINARY BLADDER:** UB is well distended with normal wall thickness. No evidence of mass /calculus.

**PROSTATE** : It is normal in size, shape & smooth outlines.

**RETRO PERITONEUM** : No evidence of lymphadenopathy / mass.

**FREE FLUID** : No free fluid seen in abdomen & peritoneal cavity.

### **IMPRESSION:**

- NO SIGNIFICANT ABNORMALITY DETECTED.

*Needs clinical correlation & other investigations.*



Dr. Hulesh Mandale, MD  
Consultant Radiologist  
DR. HULESH MANDALE  
M.B.B.S., M.D.  
CGMC-223704

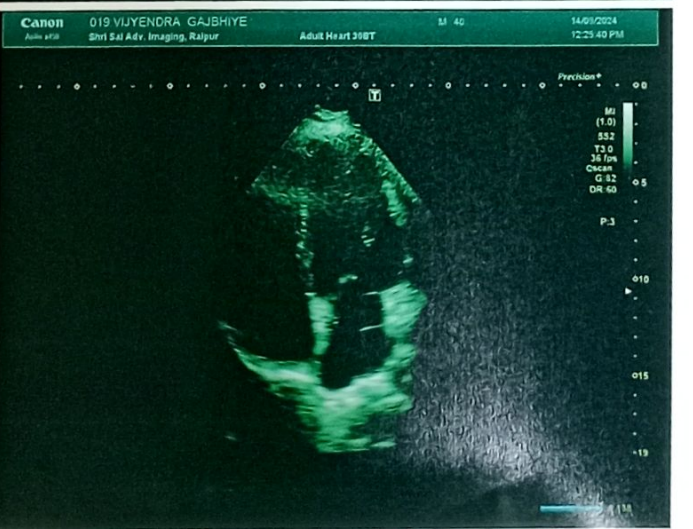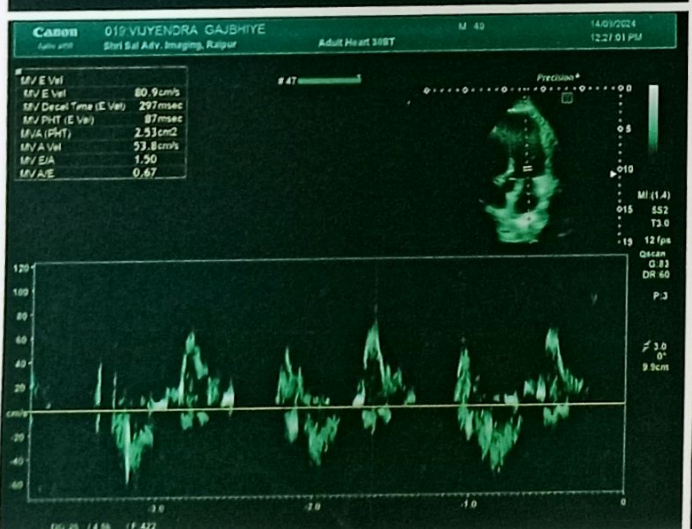
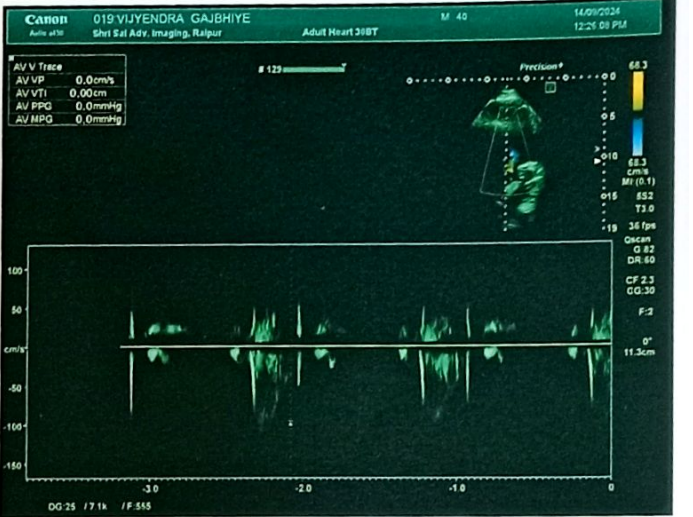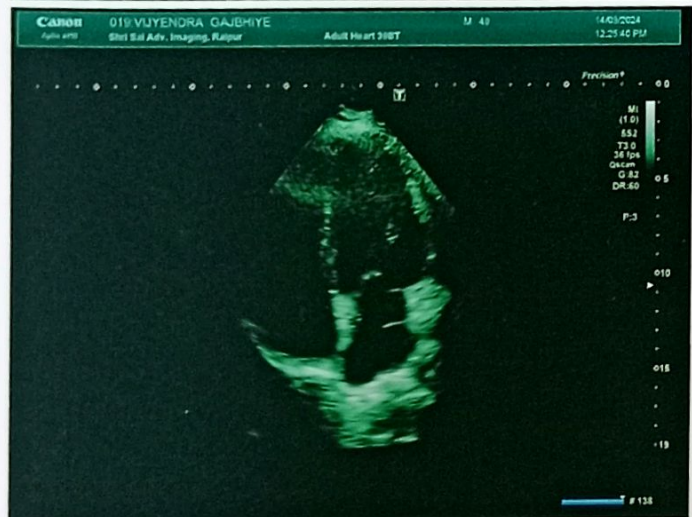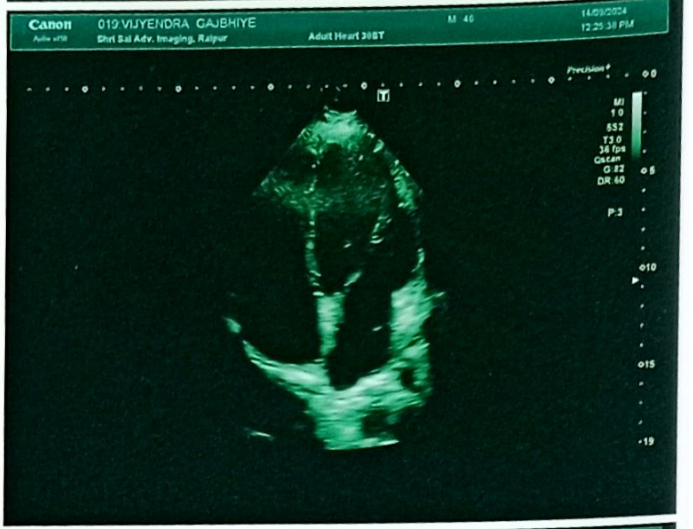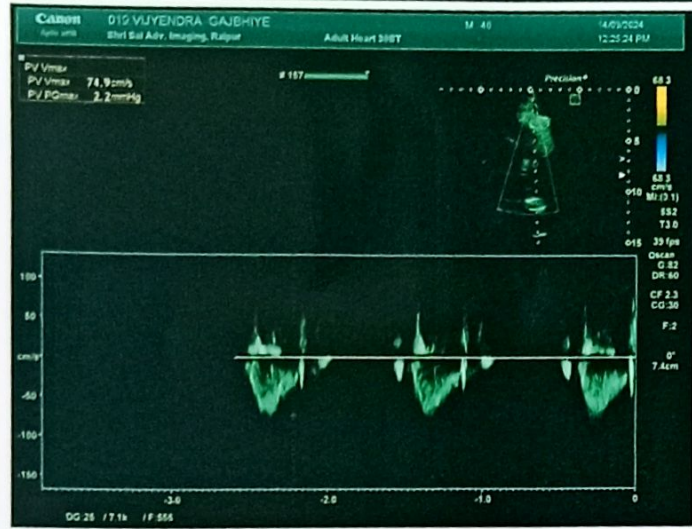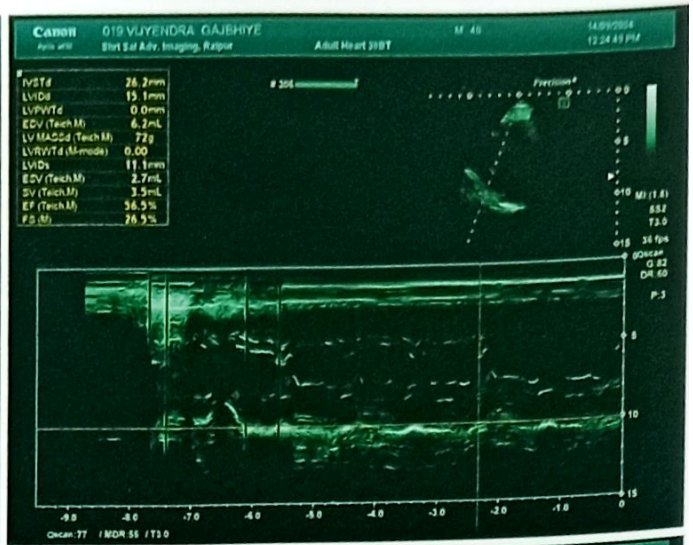
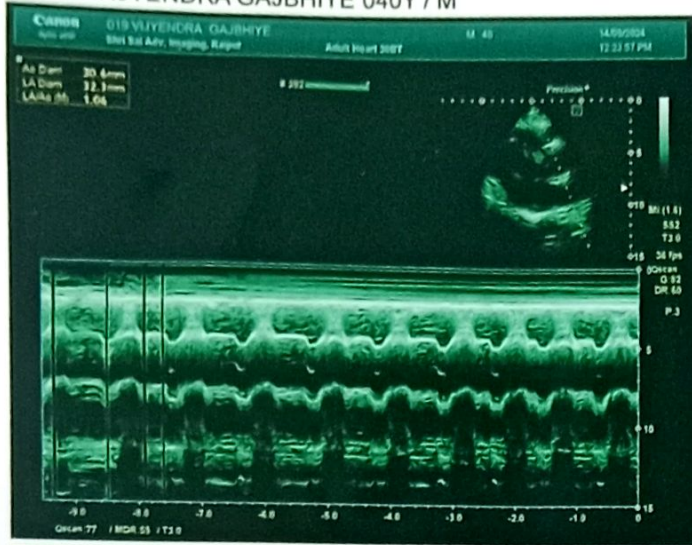
### **Kindly Note:-**

- The report and films are not valid for medico – legal purpose.
- Please Intimate us if any typing mistakes and send the report for correction within 7 days.
- कृपया अगली बार जांच के लिए आने पर पुराना रिपोर्ट साथ में लावे ।

# SHRI SAI ADVANCE IMAGING & DAIGNOSTIC CENTER, SANTOSHI NAGA R

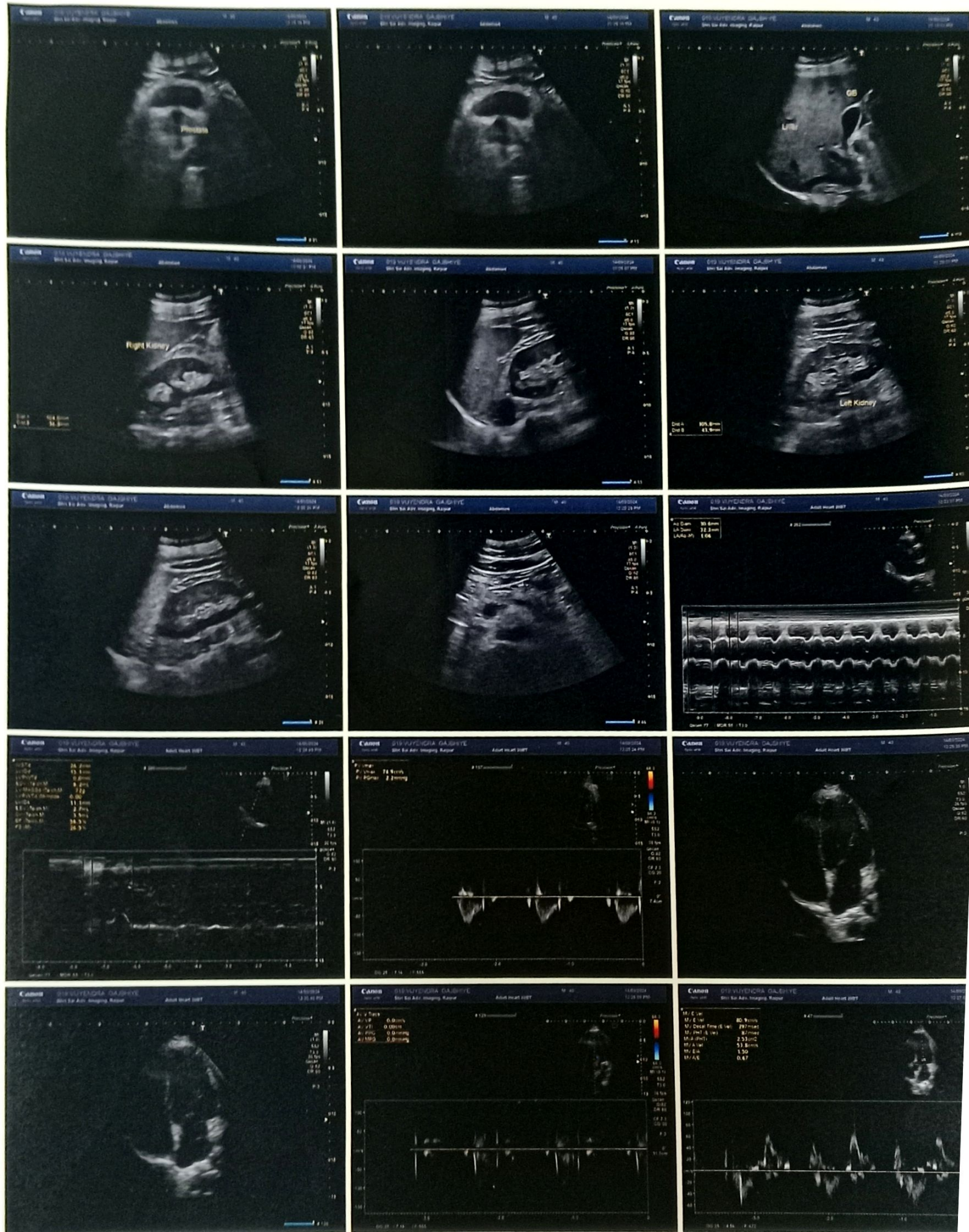
14 Sep 2024 Study : Abdomen

Name : VIJYENDRA GAJBHIYE 040Y / M



# SHRI SAI ADVANCE IMAGING & DAIGNOSTIC CENTER, SANTOSHI NAGA R

14 Sep 2024 Study: Abdomen  
 Name: VIJYENDRA GAJBHIYE 040Y / M



A Unit of Diagnostic Care with Trust

# श्री साई एडवांस इमेजिंग एंड डायग्नोस्टिक सेंटर PVT.LTD.

हर जीवन  अमूल्य है

पुराना धमतरी रोड, सब्जी बाजार के सामने,  
संतोषी नगर, रायपुर (छ.ग.) ☎ 0771-402390

Scan | 4D Color USG | Digital X-Ray | Advance Pathology | 2D Echo / E.C.G. / TMT / E.E.G. / OPG / SPI

Date:- 14-09-2024

Dear Diagnostic Center,

Due to a lack of time, we will only be unable to complete the following tests for the packages: Eye, Dental, and consultation. We kindly request that the center skip the remaining tests.

Thank you for your understanding.

  
Vijayendra



Patient: **HR. VIJAYENDRA**

HR. VIJAYENDRA

40 year / H

..... cm / ..... kg

HR 55/min

Intervals:  
RR 1094 ms  
P 96 ms  
PR 120 ms  
QRS 82 ms  
QT 378 ms  
QTc 363 ms

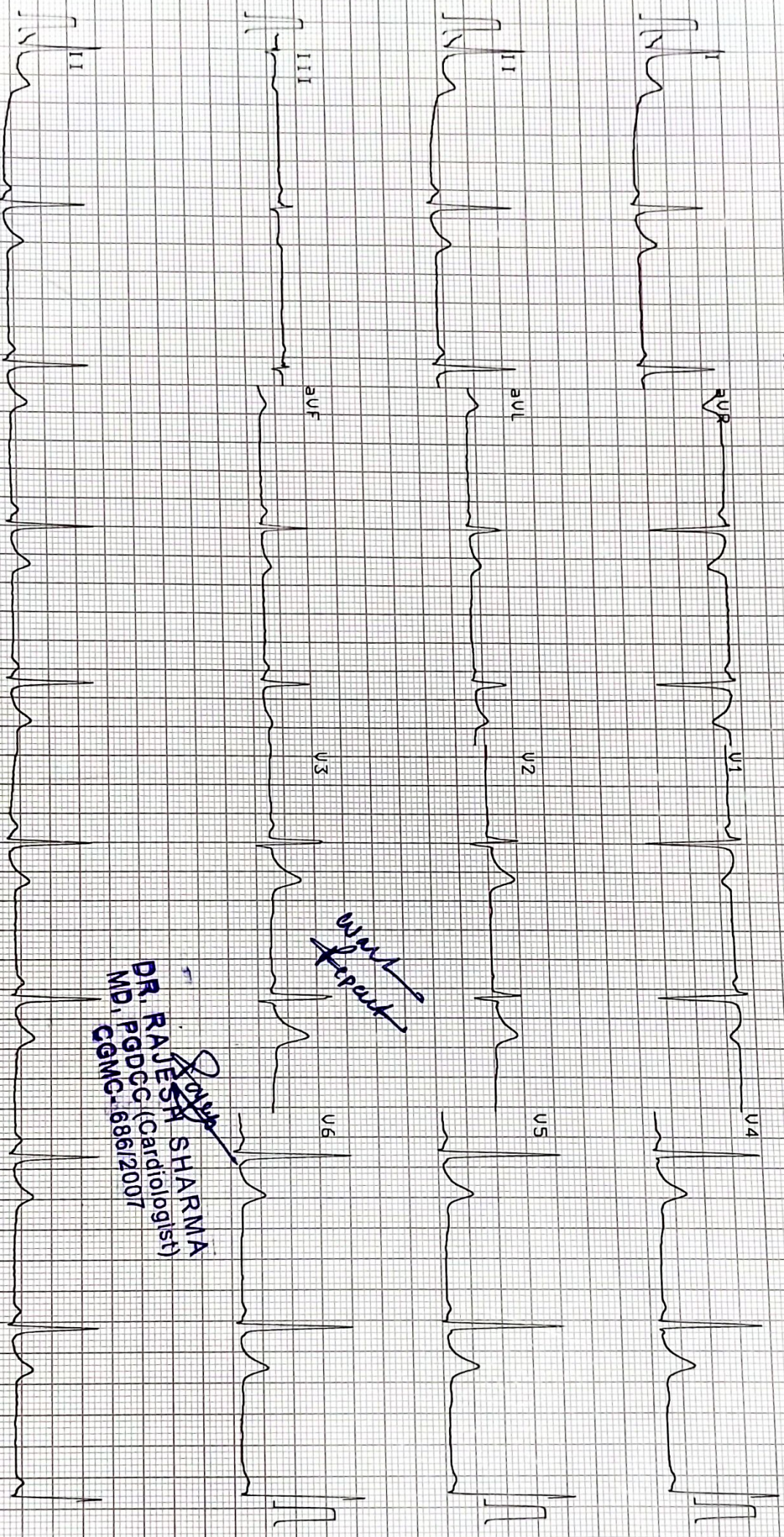
Axis:  
P 48°  
QRS 35°  
T 19°

SINUS RHYTHM  
NORMAL ECG

UNCONFIRMED REPORT

10 mm/mV

10 mm/mV



*Normal report*

**DR. RAJESH SHARMA**  
 MD, PGDCC (Cardiologist)  
 CGMC, 686/2007

25 mm/s

0.05-35Hz

F50 SF 585

Sa 14-SEP-24 00:04:19

RT-ZPIUS 4.14

(C) SCHILLER AG

RT-ZPIUS 4.14

CM