

Patient Name : Mr. Shubham Gupta

Age/Gender : 30 Y/M

UHID/MR No. : RIND.0000016454

OP Visit No : RINDOPV15172

Sample Collected on :

Reported on : 10-08-2024 17:01

LRN# : RAD2400143

Specimen :

Ref Doctor : SELF

Emp/Auth/TPA ID : APT ID 22E30763

DEPARTMENT OF RADIOLOGY

X-RAY CHEST PA

Both the lung fields and hilar shadows appears normal.

There is no obvious active pleuro-parenchymal lesion seen.

Both the costophrenic and cardiophrenic angles are clear.

Cardiac size appears within normal limits.

Both dome of hemidiaphragms are normal in position and contour.

Thoracic wall and soft tissues under view appear normal.

CONCLUSION :

No obvious abnormality seen



Dr. SANGEETA AGGARWAL
MBBS, MD
Radiology

Patient Name	: Mr. Shubham Gupta	Age/Gender	: 30 Y/M
UHID/MR No.	: RIND.0000016454	OP Visit No	: RINDOPV15172
Sample Collected on	:	Reported on	: 12-08-2024 08:57
LRN#	: RAD2400143	Specimen	:
Ref Doctor	: SELF		
Emp/Auth/TPA ID	: APT ID 22E30763		

DEPARTMENT OF RADIOLOGY

ULTRASOUND - WHOLE ABDOMEN

LIVER : Liver is enlarged in size (17cm) and the parenchymal echotexture shows grade-2 diffuse fatty infiltration. Intra-hepatic biliary radicals are not dilated. Portal vein is normal in course and calibre.

GALL BLADDER : Gall bladder appears echo free with normal wall thickness. No pericholecystic fluid noted. Common duct is not dilated.

PANCREAS : Pancreas is normal in size and echopattern.

SPLEEN : Spleen is normal in size, shape and echopattern. No focal lesion seen. Hilum is normal.

KIDNEYS : Both the kidneys are normal in position, shape, size, outline and echotexture. Cortico-medullary differentiation of both kidneys is maintained. Central sinus echoes are compact.

Visualized parts of the retroperitoneum do not reveal any lymphadenopathy.

URINARY BLADDER : Urinary bladder is normal in wall thickness with clear contents. No obvious mass lesion seen.

PROSTATE : Prostate is normal in size and echo-pattern. Capsule is intact.

No free fluid is seen in the peritoneal cavity.

IMPRESSION: Hepatomegaly with grade 2 Fatty infiltration of the liver.

SUGGEST CLINICAL CORRELATION

(The sonography findings should always be considered in correlation with the clinical and other investigation finding where applicable.) It is only a professional opinion, Not valid for medico legal purpose.

Patient Name : Mr. Shubham Gupta

Age/Gender

: 30 Y/M



Dr. SANGEETA AGGARWAL
MBBS, MD
Radiology

KINDLY NOTE: OPHTHAL BY GENERAL PHYSICIAN TEST PENDING

आयकर विभाग
INCOME TAX DEPARTMENT

SHUBHAM GUPTA
RAGHWENDRA GUPTA


15/03/1994
Permanent Account Number

BDDPGE5088E


Signature



भारत सरकार
GOVT. OF INDIA



FO Cradle

From: noreply@apolloclinics.info
Sent: 06 August 2024 19:13
To: shubhamguptapimr1416@gmail.com
Cc: fo.indira@apollocradle.com
Subject: Your appointment is confirmed



Dear Shubham Gupta,

Greetings from Apollo Clinics,

Your corporate health check appointment is confirmed at **Apollo Cradle & Children's Hospital Indirapuram clinic** on **2024-08-10** at **08:00-08:30**.

Payment Mode	
Corporate Name	ARCOFEMI HEALTHCARE LIMITED
Agreement Name	[ARCOFEMI MEDIWHEEL MALE AHC CREDIT PAN INDIA OP AGREEMENT]
Package Name	[ARCOFEMI - MEDIWHEEL - FULL BODY ANNUAL PLUS MALE - 2D ECHO - PAN INDIA - FY2324]

"Kindly carry with you relevant documents such as HR issued authorization letter and or appointment confirmation mail and or valid government ID proof and or company ID card and or voucher as per our agreement with your company or sponsor."

Note: Video recording or taking photos inside the clinic premises or during camps is not allowed and would attract legal consequences.

Note: Also once appointment is booked, based on availability of doctors at clinics tests will happen, any pending test will happen based on doctor availability and clinics will be updating the same to customers.

Instructions to be followed for a health check:

CERTIFICATE OF MEDICAL FITNESS

This is to certify that I have conducted the clinical examination

of Mr. Shubham Gupta on 13/08/24

After reviewing the medical history and on clinical examination it has been found that he/she is

	Tick
<ul style="list-style-type: none"> Medically Fit 	✓
<ul style="list-style-type: none"> Fit with restrictions/recommendations <p>Though following restrictions have been revealed, in my opinion, these are not impediments to the job.</p> <p>1. <u>GI FL</u></p> <p>2. <u>Tab. Hepat-olive - 100</u></p> <p>3. _____</p> <p>However the employee should follow the advice/medication that has been communicated to him/her.</p> <p>Review after _____</p>	
<ul style="list-style-type: none"> Currently Unfit. <p>Review after _____</p>	
<ul style="list-style-type: none"> Unfit 	

Dr. SHAILENDRA KUMAR, (Physician)
 M.P.S.S. recommended
 Regd. No. DMC-12232
 Apollo Cradle and Children's Hospital
 NH-1, Shakti Khand-2, Indirapuram,
 Ghaziabad; Uttar Pradesh-201014

Dr. _____
Medical Officer

This certificate is not meant for medico-legal purposes

Address: NH-1, Shakti Khand 2, Indirapuram, Ghaziabad, Uttar Pradesh – 201014.
 Ph No: +91 88106 85179, 1860 500 4424

Apollo Specialty Hospitals Private Limited

(Formerly known as Nova Specialty Hospitals Private Limited) CIN - U85100TG2009PTC099414

Regd Office: #7-1617/A, 615 & 616, 7th Floor, Imperial Towers, Opp: Ameerpet Metro Station, Ameerpet, Hyderabad - 500038.
 Ph No: 040 - 4904 7777, Fax No: 4904 7744 | www.apollocradle.com | Email ID: info.cradle@apollocradle.com



Height : 81 cm	Weight 73.3 kg	BMI : 22.4 kg/m ²	Waist Circum :
Temp : 101	Pulse 76 B/M	Resp : 20 B/M	B.P : 120/80 mmHg

General Examination/Allergies
History

Cinical Diagnosis & Management Plan

GERL
Carsulfim 600

Follow up date

Doctor Signature

APOLLO CRADLE- INDRAPURAM

DIET CHART

NAME: Shubram

DATE: 12/8/24

AGE:

UHID: high proteins, high fiber diet

DIETARY ADVICE FOR A HEALTHY LIFESTYLE

1. Consume at least 500 ml. of milk per day (including coffee, tea, curd and buttermilk) preferably toned or double toned.
2. Use whole grains and pulses rather than refined cereals like maida.
3. If mixing cereals with pulses for chapathi, use in the following proportion; 4 parts of cereal + 1 part of soya atta.
4. Liberal intake of green leafy vegetables in the form of soups, salads, mixed vegetable raita, cooked vegetables as sabzis etc.
5. Judicious intake of roots and tubers like potatoes, colocasia, sweet potato, yam, etc.
6. Prefer taking fruits over their juices. Low calorie fruits like apple, papaya, pear, peach, orange, sweet lime melon, pomegranate, guava should be preferred.
7. Select roasted snacks such as channa, puffed rice and heart healthy nuts like almonds, walnuts and choose low fat milk beverages over other unhealthy option.
8. Consume at least 2 liter of water every day.
9. A gap of 2 hours is required between dinner and bed time.
10. Cultivate the habit of having food at smaller intervals and in small quantities like 3 major meals and 3 - 4

small sneaks in between (fruits, salad and buttermilk)

11. Include white meat only i. e. chicken, fish and egg white in the grilled, boiled or curry form.

FOOD TO BE AVOIDED avoid

1. Extra sugar in the form of excess coffee, tea, sweets, glucose, soft drinks, honey, jams, jellies, candies, ice cream and other sweetened beverages.
2. Deep fried items such as samosa, Kachori, Namkeen, parathas, wafer etc. Eating bakery products on a daily basis.
3. Red meat like lamb (mutton), prawns, crab and organ meat.
4. Dried fruits like coconut and cashew nuts etc.
5. Fruits like avocados, mango, chikoo, grapes, custard apple, jackfruit and big bananas on a daily basis.
6. Extra salt on the table (top salt) daily consumption of pckeles, papads, ready-to-eat food, processed foods, salted nuts, salted fish and chutney powders which contain salt as a major preserving agent.

ID: 15566

10-08-2024 14:23:34

Mr. Shubham Gupta

Male 30 years

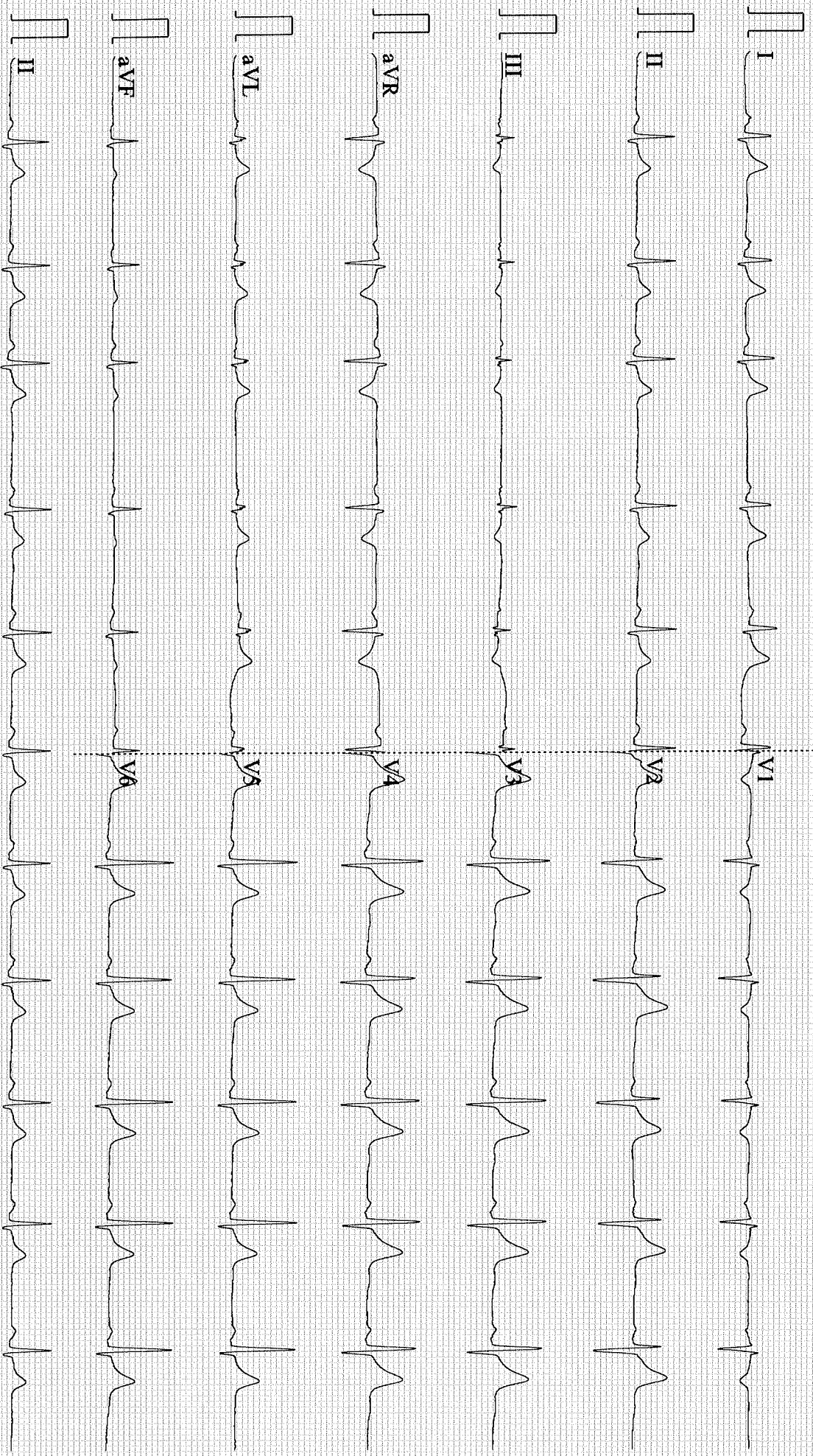
Reg. No. :

Diagnosis Information:

ECG REPORT

HR	: 69	bpm
P	: 105	ms
PR	: 146	ms
QRS	: 85	ms
QT/QTcBz	: 345/370	ms
P/QRS/T	: 41/44/14	°
RV5/SV1	: 1.167/0.528	mV

Unconfirmed Report.



Date:

Dr. NILOTPAL MISHRA

B.D.S. | M.D.S.

Fellow Head & Neck Oncology

Sr. Consultant Dental

Mobile Number: +91 9625328945, 9667406341



PATIENT NAME:	Shubhan. Gupta	30/m.
UHID:	RIND.0000016454.	

O/E - Extensive Stenosis.

Calculus. ++.

Adv - oral prophylaxis.

A large, stylized handwritten signature in black ink.

Doctor Signature

Address: NH-1, Shakti Khand 2, Indrapuram, Ghaziabad, Uttar Pradesh - 201014.

Ph No: +91 88106 85179, 1860 500 4424

Apollo Specialty Hospitals Private Limited

(Formerly known as Nova Specialty Hospitals Private Limited) CIN - U85100TG2009PTC099414

Regd Office: #7-1617/A, 615 & 616, 7th Floor, Imperial Towers, Opp: Ameerpet Metro Station, Ameerpet, Hyderabad - 500038.

Ph No: 040 - 4904 7777, Fax No: 4904 7744 | www.apollocradle.com | Email ID: info.cradle@apollocradle.com

Patient Name : Mr. Shubham Gupta Age : 30 Y/M
UHID : RIND.0000016454 OP Visit No : RINDOPV15172
Conducted By: : Dr. SANJIV KUMAR GUPTA Conducted Date : 10-08-2024 15:04
Referred By : SELF

2D-ECHO WITH COLOUR DOPPLER

Dimensions:

Ao (ed)	2.86 CM
LA (es)	3.35 CM
LVID (ed)	4.03 CM
LVID (es)	2.40 CM
IVS (Ed)	0.997 CM
LVPW (Ed)	1.22 CM
EF	70.00%
%FD	35.00%
MITRAL VALVE :	NORMAL
AML	NORMAL
PML	NORMAL
AORTIC VALVE	NORMAL
TRICUSPID VALVE	NORMAL
RIGHT VENTRICLE	NORMAL
INTER ATRIAL SEPTUM	NORMAL
INTER VENTRICULAR SEPTUM	INTACT
AORTA	NORMAL
RIGHT ATRIUM	NORMAL
LEFT ATRIUM	NORMAL
Pulmonary Valve	NORMAL
PERICARDIUM	NORMAL

Patient Name	: Mr. Shubham Gupta	Age	: 30 Y/M
UHID	: RIND.0000016454	OP Visit No	: RINDOPV15172
Conducted By:	: Dr. SANJIV KUMAR GUPTA	Conducted Date	: 10-08-2024 15:04
Referred By	: SELF		

NO REGIONAL WALL MOTION ABNORMALITY

NORMAL LEFT VENTRICULAR SYSTOLIC FUNCTION

COLOUR AND DOPPLER STUDIES NORMAL

PWD: A>E AT MITRAL INFLOW NORMAL


VELOCITY ACROSS THE AV NORMAL

IMPRESSION:

GOOD LV/RV FUNCTION

NO MR/NO AR /NO TR/NOPAH.NO CLOT

NO PERICARDIAL EFFUSION.



Dr. SANJIV
KUMAR
GUPTA

Patient Name	: Mr. Shubham Gupta	Age	: 30 Y/M
UHID	: RIND.0000016454	OP Visit No	: RINDOPV15172
Conducted By:	: Dr. SANJIV KUMAR GUPTA	Conducted Date	: 10-08-2024 15:04
Referred By	: SELF		
