


Patient Name	: Mr.RAVINDRA R	Collected	: 27/Apr/2024 08:22AM
Age/Gender	: 37 Y 1 M 9 D/M	Received	: 27/Apr/2024 10:05AM
UHID/MR No	: CMYS.0000060595	Reported	: 27/Apr/2024 12:30PM
Visit ID	: CMYSOPV124848	Status	: Final Report
Ref Doctor	: Dr.SELF	Sponsor Name	: ARCOFEMI HEALTHCARE LIMITED
Emp/Auth/TPA ID	: TZG0345115		

DEPARTMENT OF HAEMATOLOGY

PERIPHERAL SMEAR , WHOLE BLOOD EDTA



Dr. PAVAN KUMAR M
M.B.B.S,M.D(Pathology)
Consultant Pathologist

SIN No:BED240112628




Patient Name : Mr.RAVINDRA R	Collected : 27/Apr/2024 08:22AM
Age/Gender : 37 Y 1 M 9 D/M	Received : 27/Apr/2024 10:05AM
UHID/MR No : CMYS.0000060595	Reported : 27/Apr/2024 01:08PM
Visit ID : CMYSOPV124848	Status : Final Report
Ref Doctor : Dr.SELF	Sponsor Name : ARCOFEMI HEALTHCARE LIMITED
Emp/Auth/TPA ID : TZG0345115	

DEPARTMENT OF HAEMATOLOGY

ARCOFEMI - MEDIWHEEL - PMC PACK D - PAN INDIA - FY2324

Test Name	Result	Unit	Bio. Ref. Range	Method
HEMOGRAM , WHOLE BLOOD EDTA				
HAEMOGLOBIN	15.3	g/dL	13-17	Spectrophotometer
PCV	49.60	%	40-50	Electronic pulse & Calculation
RBC COUNT	7.59	Million/cu.mm	4.5-5.5	Electrical Impedance
MCV	65	fL	83-101	Calculated
MCH	20.2	pg	27-32	Calculated
MCHC	30.9	g/dL	31.5-34.5	Calculated
R.D.W	16.1	%	11.6-14	Calculated
TOTAL LEUCOCYTE COUNT (TLC)	7,000	cells/cu.mm	4000-10000	Electrical Impedance
DIFFERENTIAL LEUCOCYTIC COUNT (DLC)				
NEUTROPHILS	56.1	%	40-80	Electrical Impedance
LYMPHOCYTES	37.7	%	20-40	Electrical Impedance
EOSINOPHILS	1.4	%	1-6	Electrical Impedance
MONOCYTES	4.3	%	2-10	Electrical Impedance
BASOPHILS	0.5	%	<1-2	Electrical Impedance
ABSOLUTE LEUCOCYTE COUNT				
NEUTROPHILS	3927	Cells/cu.mm	2000-7000	Calculated
LYMPHOCYTES	2639	Cells/cu.mm	1000-3000	Calculated
EOSINOPHILS	98	Cells/cu.mm	20-500	Calculated
MONOCYTES	301	Cells/cu.mm	200-1000	Calculated
BASOPHILS	35	Cells/cu.mm	0-100	Calculated
Neutrophil lymphocyte ratio (NLR)	1.49		0.78- 3.53	Calculated
PLATELET COUNT	283000	cells/cu.mm	150000-410000	Electrical impedance
ERYTHROCYTE SEDIMENTATION RATE (ESR)	06	mm at the end of 1 hour	0-15	Modified Westergren
PERIPHERAL SMEAR				

R.B.C: Majority are microcytic hypochromic with normocytic hypochromic RBCs. Also seen are good number of normocytic



Dr. PAVAN KUMAR M
M.B.B.S,M.D(Pathology)
Consultant Pathologist

SIN No:BED240112628



Patient Name	: Mr.RAVINDRA R	Collected	: 27/Apr/2024 08:22AM
Age/Gender	: 37 Y 1 M 9 D/M	Received	: 27/Apr/2024 10:05AM
UHID/MR No	: CMYS.0000060595	Reported	: 27/Apr/2024 01:08PM
Visit ID	: CMYSOPV124848	Status	: Final Report
Ref Doctor	: Dr.SELF	Sponsor Name	: ARCOFEMI HEALTHCARE LIMITED
Emp/Auth/TPA ID	: TZG0345115		

DEPARTMENT OF HAEMATOLOGY

ARCOFEMI - MEDIWHEEL - PMC PACK D - PAN INDIA - FY2324

normochromic cells.


W.B.C: Are normal in number with normal morphology.

Platelets: Normal in number and are seen in singles and clumps.

Hemoparasites: Not seen.

IMPRESSION: MICROCYTIC HYPOCHROMIC BLOOD PICTURE.

Note : Suggested treatment correlation.



Dr. PAVAN KUMAR M
M.B.B.S,M.D(Pathology)
Consultant Pathologist

SIN No:BED240112628



Patient Name	: Mr.RAVINDRA R	Collected	: 27/Apr/2024 08:22AM
Age/Gender	: 37 Y 1 M 9 D/M	Received	: 27/Apr/2024 10:05AM
UHID/MR No	: CMYS.0000060595	Reported	: 27/Apr/2024 12:30PM
Visit ID	: CMYSOPV124848	Status	: Final Report
Ref Doctor	: Dr.SELF	Sponsor Name	: ARCOFEMI HEALTHCARE LIMITED
Emp/Auth/TPA ID	: TZG0345115		

DEPARTMENT OF HAEMATOLOGY

ARCOFEMI - MEDIWHEEL - PMC PACK D - PAN INDIA - FY2324

Test Name	Result	Unit	Bio. Ref. Range	Method
BLOOD GROUP ABO AND RH FACTOR , WHOLE BLOOD EDTA				
BLOOD GROUP TYPE	B			Forward & Reverse Grouping with Slide/Tube Aggluti
Rh TYPE	POSITIVE			Forward & Reverse Grouping with Slide/Tube Agglutination



Dr. PAVAN KUMAR M
M.B.B.S,M.D(Pathology)
Consultant Pathologist

SIN No:BED240112628



Patient Name : Mr.RAVINDRA R	Collected : 27/Apr/2024 08:21AM
Age/Gender : 37 Y 1 M 9 D/M	Received : 27/Apr/2024 10:05AM
UHID/MR No : CMYS.0000060595	Reported : 27/Apr/2024 10:51AM
Visit ID : CMYSOPV124848	Status : Final Report
Ref Doctor : Dr.SELF	Sponsor Name : ARCOFEMI HEALTHCARE LIMITED
Emp/Auth/TPA ID : TZG0345115	

DEPARTMENT OF BIOCHEMISTRY

ARCOFEMI - MEDIWHEEL - PMC PACK D - PAN INDIA - FY2324

Test Name	Result	Unit	Bio. Ref. Range	Method
GLUCOSE, FASTING , NAF PLASMA	211	mg/dl	74-106	GOD, POD


Comment:

As per American Diabetes Guidelines, 2023

Fasting Glucose Values in mg/dL	Interpretation
70-100 mg/dL	Normal
100-125 mg/dL	Prediabetes
≥126 mg/dL	Diabetes
<70 mg/dL	Hypoglycemia

Note:

- The diagnosis of Diabetes requires a fasting plasma glucose of $> \text{ or } = 126 \text{ mg/dL}$ and/or a random / 2 hr post glucose value of $> \text{ or } = 200 \text{ mg/dL}$ on at least 2 occasions.
- Very high glucose levels ($>450 \text{ mg/dL}$ in adults) may result in Diabetic Ketoacidosis & is considered critical.



Dr. PAVAN KUMAR M
M.B.B.S,M.D(Pathology)
Consultant Pathologist

SIN No:PLF02150628



Patient Name : Mr.RAVINDRA R	Collected : 27/Apr/2024 08:22AM
Age/Gender : 37 Y 1 M 9 D/M	Received : 27/Apr/2024 10:05AM
UHID/MR No : CMYS.0000060595	Reported : 27/Apr/2024 11:34AM
Visit ID : CMYSOPV124848	Status : Final Report
Ref Doctor : Dr.SELF	Sponsor Name : ARCOFEMI HEALTHCARE LIMITED
Emp/Auth/TPA ID : TZG0345115	


DEPARTMENT OF BIOCHEMISTRY

ARCOFEMI - MEDIWHEEL - PMC PACK D - PAN INDIA - FY2324

Test Name	Result	Unit	Bio. Ref. Range	Method
ALANINE AMINOTRANSFERASE (ALT/SGPT) , SERUM	29	U/l	0-45	IFCC

Comment:

ALT elevations are noted in liver parenchymal diseases, leading to injury / destruction of hepatocytes. ALT levels are seen to be elevated even before the signs and symptoms of the liver injury appear. The ALT levels remain high longer in blood as compared to AST levels. And though both the enzymes increase in liver injury, the rise in ALT is more compared to AST, thus also altering the ALT:AST ratio.



Dr. PAVAN KUMAR M
M.B.B.S,M.D(Pathology)
Consultant Pathologist

SIN No:SE04707095




Patient Name : Mr.RAVINDRA R	Collected : 27/Apr/2024 08:22AM
Age/Gender : 37 Y 1 M 9 D/M	Received : 27/Apr/2024 10:05AM
UHID/MR No : CMYS.0000060595	Reported : 27/Apr/2024 11:51AM
Visit ID : CMYSOPV124848	Status : Final Report
Ref Doctor : Dr.SELF	Sponsor Name : ARCOFEMI HEALTHCARE LIMITED
Emp/Auth/TPA ID : TZG0345115	

DEPARTMENT OF BIOCHEMISTRY

ARCOFEMI - MEDIWHEEL - PMC PACK D - PAN INDIA - FY2324

Test Name	Result	Unit	Bio. Ref. Range	Method
TOTAL CHOLESTEROL , SERUM	251	mg/dl	0-200	CHOD


Dr. PAVAN KUMAR M
 M.B.B.S,M.D(Pathology)
 Consultant Pathologist

SIN No:SE04707095




Patient Name : Mr.RAVINDRA R	Collected : 27/Apr/2024 08:22AM
Age/Gender : 37 Y 1 M 9 D/M	Received : 27/Apr/2024 10:05AM
UHID/MR No : CMYS.0000060595	Reported : 27/Apr/2024 11:34AM
Visit ID : CMYSOPV124848	Status : Final Report
Ref Doctor : Dr.SELF	Sponsor Name : ARCOFEMI HEALTHCARE LIMITED
Emp/Auth/TPA ID : TZG0345115	

DEPARTMENT OF BIOCHEMISTRY

ARCOFEMI - MEDIWHEEL - PMC PACK D - PAN INDIA - FY2324

Test Name	Result	Unit	Bio. Ref. Range	Method
UREA , SERUM	30.57	mg/dl	13-43	Urease, UV

Test Name	Result	Unit	Bio. Ref. Range	Method
CREATININE , SERUM	0.87	mg/dL	0.67-1.17	Enzymatic colorimetric


Dr. PAVAN KUMAR M
M.B.B.S,M.D(Pathology)
Consultant Pathologist

SIN No:SE04707095



Patient Name	: Mr.RAVINDRA R	Collected	: 27/Apr/2024 08:22AM
Age/Gender	: 37 Y 1 M 9 D/M	Received	: 27/Apr/2024 10:19AM
UHID/MR No	: CMYS.0000060595	Reported	: 27/Apr/2024 10:53AM
Visit ID	: CMYSOPV124848	Status	: Final Report
Ref Doctor	: Dr.SELF	Sponsor Name	: ARCOFEMI HEALTHCARE LIMITED
Emp/Auth/TPA ID	: TZG0345115		


DEPARTMENT OF CLINICAL PATHOLOGY

ARCOFEMI - MEDIWHEEL - PMC PACK D - PAN INDIA - FY2324

Test Name	Result	Unit	Bio. Ref. Range	Method
COMPLETE URINE EXAMINATION (CUE) , URINE				
PHYSICAL EXAMINATION				
COLOUR	PALE YELLOW		PALE YELLOW	Visual
TRANSPARENCY	CLEAR		CLEAR	Visual
pH	6.0		5-7.5	Bromothymol Blue
SP. GRAVITY	1.015		1.002-1.030	Dipstick
BIOCHEMICAL EXAMINATION				
URINE PROTEIN	NEGATIVE		NEGATIVE	PROTEIN ERROR OF INDICATOR
GLUCOSE	POSITIVE (+++)		NEGATIVE	GOD-POD
URINE BILIRUBIN	NEGATIVE		NEGATIVE	AZO COUPLING
URINE KETONES (RANDOM)	NEGATIVE		NEGATIVE	NITROPRUSSIDE
UROBILINOGEN	NORMAL		NORMAL	EHRlich
NITRITE	NEGATIVE		NEGATIVE	Dipstick
LEUCOCYTE ESTERASE	NEGATIVE		NEGATIVE	PYRROLE HYDROLYSIS
CENTRIFUGED SEDIMENT WET MOUNT AND MICROSCOPY				
PUS CELLS	2 - 3	/hpf	0-5	Microscopy
EPITHELIAL CELLS	1 - 2	/hpf	<10	MICROSCOPY
RBC	NIL	/hpf	0-2	MICROSCOPY
CASTS	NIL		0-2 Hyaline Cast	MICROSCOPY
CRYSTALS	ABSENT		ABSENT	MICROSCOPY

Comment:

All urine samples are checked for adequacy and suitability before examination. Microscopy findings are reported as an average of 10 high power fields.



Dr. PAVAN KUMAR M
M.B.B.S,M.D(Pathology)
Consultant Pathologist

SIN No:UR2338764



Patient Name : Mr.RAVINDRA R	Collected : 27/Apr/2024 09:40AM
Age/Gender : 37 Y 1 M 9 D/M	Received : 27/Apr/2024 10:19AM
UHID/MR No : CMYS.0000060595	Reported : 27/Apr/2024 10:53AM
Visit ID : CMYSOPV124848	Status : Final Report
Ref Doctor : Dr.SELF	Sponsor Name : ARCOFEMI HEALTHCARE LIMITED
Emp/Auth/TPA ID : TZG0345115	


DEPARTMENT OF CLINICAL PATHOLOGY

ARCOFEMI - MEDIWHEEL - PMC PACK D - PAN INDIA - FY2324

Test Name	Result	Unit	Bio. Ref. Range	Method
STOOL ROUTINE EXAMINATION , STOOL				
PHYSICAL EXAMINATION				
COLOUR	YELLOWISH			Macroscopy
CONSISTENCY	SEMISOLID			Macroscopy
MUCUS	ABSENT		ABSENT	Macroscopy
CHEMICAL EXAMINATION				
OCCULT BLOOD	NEGATIVE		NEGATIVE	Guaiac Method
pH	5.0		5-7.5	Double Indicator
MICROSCOPIC EXAMINATION				
PUS CELLS	2 - 3	/hpf	0-5	Microscopy
RED BLOOD CELLS	NIL	/hpf	Nil	Microscopy
OVA	ABSENT		ABSENT	Lugols Iodine
CYSTS	ABSENT		ABSENT	Lugols Iodine
EPITHELIAL CELLS	NIL	/hpf	<10	MICROSCOPY
VEGETABLE CELLS	ABSENT		ABSENT	Microscopy
MUSCLE FIBRES	ABSENT		ABSENT	Microscopy
STARCH GRANULES	ABSENT		ABSENT	Microscopy
FAT GLOBULES	ABSENT		ABSENT	Microscopy

*** End Of Report ***

Page 10 of 10



Dr. PAVAN KUMAR M
M.B.B.S,M.D(Pathology)
Consultant Pathologist

SIN No:ST364520



Name : Mr. Ravindra R

Age: 37 Y

Sex: M

Address : MYSORE

Plan : ARCOFEMI MEDIWHEEL PMC CREDIT PAN INDIA OP AGREEMENT

UHID:CMYS 0000060595



OP Number:CMYSOPV124848

Bill No.:CMYS-OCR-23064

Date : 27.04.2024 08:20

Sno	Service Type/ServiceName	Department
1	ARCOFEMI - MEDIWHEEL - PMC PACK D - PAN INDIA - FY2324	
1	GLUCOSE, FASTING	
2	HEMOGRAM + PERIPHERAL SMEAR	
3	ALANINE AMINOTRANSFERASE (ALT/SGPT), SERUM	
4	COMPLETE URINE EXAMINATION	
5	PERIPHERAL SMEAR	
6	EKG	76.4 kg
7	CREATININE, SERUM	178 cm
8	STOOL ROUTINE EXAMINATION	
9	CHOLESTEROL - SERUM / PLASMA	
10	X-RAY CHEST PA → P	130/80.
11	FITNESS BY GENERAL PHYSICIAN → P	
12	BLOOD GROUP ABO AND RH FACTOR	
13	OPHTHAL BY GENERAL PHYSICIAN	
14	UREA - SERUM / PLASMA	

CERTIFICATE OF MEDICAL FITNESS

This is to certify that I have conducted the clinical examination

of Mr Ravindra R. on 27/4/24,

After reviewing the medical history and on clinical examination it has been found that he/she is

	Tick
<ul style="list-style-type: none"> • Medically Fit 	<input checked="" type="checkbox"/>
<ul style="list-style-type: none"> • Fit with restrictions/recommendations <p>Though following restrictions have been revealed, in my opinion, these are not impediments to the job.</p> <p>1.....</p> <p>2.....</p> <p>3.....</p> <p>However the employee should follow the advice/medication that has been communicated to him/her.</p> <p>Review after _____</p>	
<ul style="list-style-type: none"> • Currently Unfit. Review after _____ recommended 	
<ul style="list-style-type: none"> • Unfit 	

Dr. [Signature]

Medical Officer
The Apollo Clinic, Mysore.

Apollo Clinic

23rd Floor,
Kalidasa Road, Mysore - 02
Ph : 0821-4006040/41

This certificate is not meant for medical purposes.

Apollo Health and Lifestyle Limited


(CIN - U85110TG2000PLC115819)
Regd. Office: 1-10-60/62, Ashoka Raghupathi Chambers, 5th Floor, Begumpet, Hyderabad, Telangana - 500 016.
Ph No: 040-4904 7777, Fax No: 4904 7744 | Email ID: enquiry@apollohl.com | www.apollohl.com

APOLLO CLINICS NETWORK KARNATAKA

Bangalore (Basavanagudi | Bellandur | Electronic City | Fraser Town | HSR Layout | Indira Nagar | JP Nagar | Kundalahalli | Koramangala | Sarjapur Road) Mysore (VV Mohalla)

Online appointments: www.apolloclinic.com

TO BOOK AN APPOINTMENT



Date : 27-04-2024
 MR NO : CMYS.0000060595
 Name : Mr. Ravindra R
 Age/ Gender : 37 Y / Male

Department : GENERAL [Ophthal]
 Doctor :
 Registration No :
 Qualification :

Consultation Timing: 08:20

Height: 178	Weight: 76.4	BMI:	Waist Circum:
Temp: (N)	Pulse: 90/min	Resp: 30/min	B.P: 130/80

General Examination /
 Allergies History

- No

Clinical Diagnosis & Management Plan

Wearing corrected spectacles.
 regularly - since > 3 yrs

No fresh complaints

No significant treatment

KC/O TY II DM - on I

O/E P I C R L E

vision (R) (L)

Far CG CG

Near wearing corrected glasses -

Follow up date :

Doctor Signature

Apollo Clinic
 # 23, 1st Floor,
 Kalidasa Road, Mysore - 02
 Ph : 0821-4000040/41

Regular Eye checks.

Date : 27-04-2024
MR NO : CMYS.0000060595

Department : GENERAL
Doctor :

Name : Mr. Ravindra R
Age/ Gender : 37 Y / Male

Registration No :
Qualification :

Consultation Timing: 08:20

Height : 178	Weight : 76.4	BMI :	Waist Circum :
Temp :	Pulse :	Resp :	B.P : 130/80

General Examination /
Allergies History

-NO-

Clinical Diagnosis & Management Plan

No fresh complaints

NO + on medications

K/Clo Ty # DM - on R

L2 P I C K L E

R.S }
PIA. } NAD.
CVS }

CNS - NO focal deficits

Follow up date :

Doctor Signature

Apollo Clinic
23, 1st Floor,
Kalidasa Road, Mysore - 02
PK: 0824400041

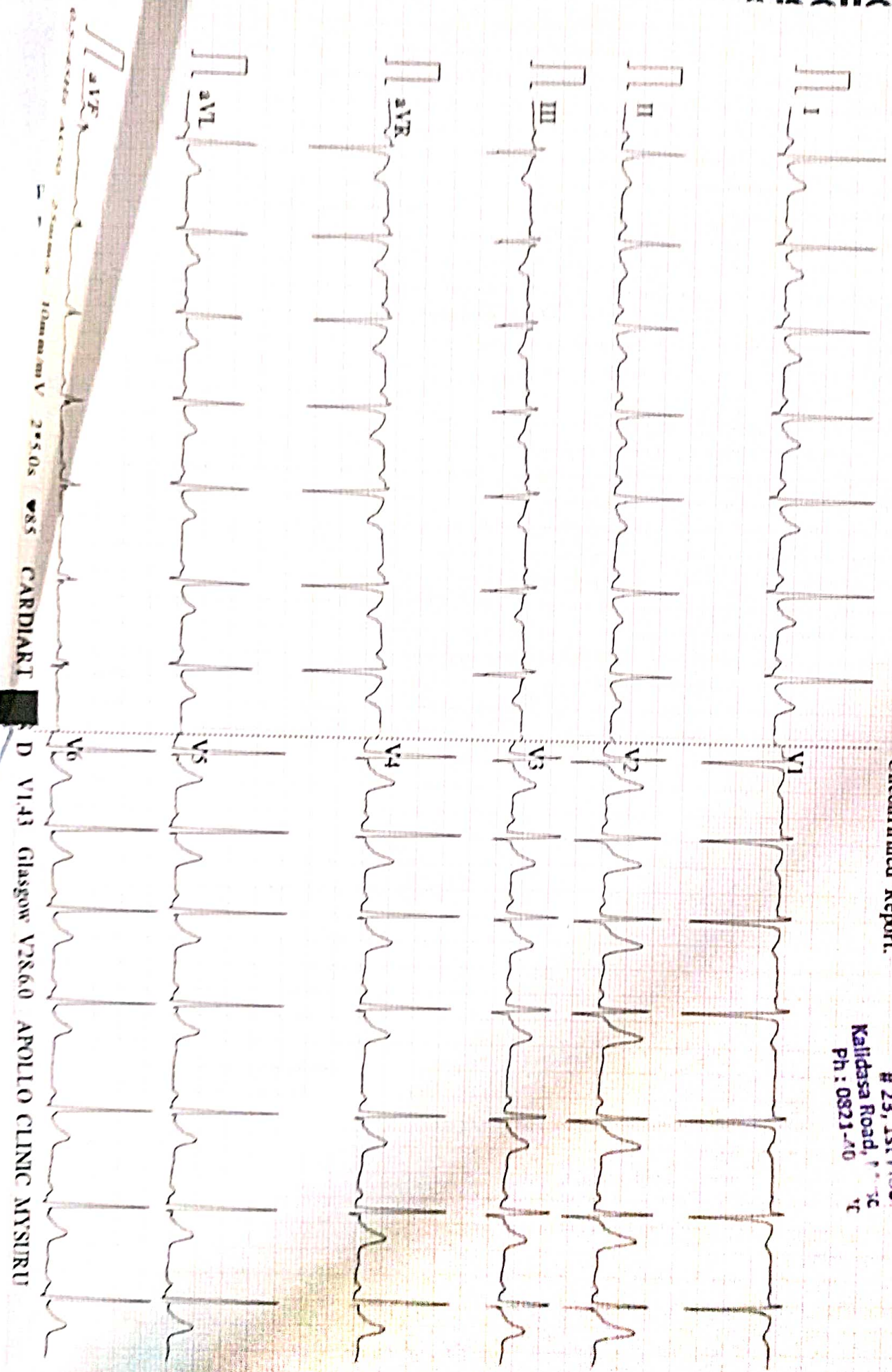
Regular health

MR RAVINDRA R
Male 37 years
178cm 76kg 130/80 mmHg

Diagnosis Information:

Unconfirmed Report.

Apollo Clinics
23, 1st Floor,
Kallidasa Road, Mysuru
Ph : 0821-40XXXX



CARDIARI

D V1.43 Glasgow V2860 APOLLO CLINIC MYSURU

Patient Name : Mr. Ravindra R
UHID : CMYS.0000060595
Reported on : 27-04-2024 15:56
Adm/Consult Doctor :

Age : 37 Y M
OP Visit No : CMYSOPV124342
Printed on : 27-04-2024 15:56
Ref Doctor : SELF

DEPARTMENT OF RADIOLOGY

X-RAY CHEST PA

Both lung fields and hila are normal .

No obvious active pleuro-parenchymal lesion seen .

Both costophrenic and cardiophrenic angles are clear .


Both diaphragms are normal in position and contour .

Thoracic wall and soft tissues appear normal.

IMPRESSION : NORMAL STUDY.

Printed on:27-04-2024 15:56

---End of the Report---


Dr. CHETAN HOLEPPAGOL
MBBS, DNB(RADIO DIAGNOSIS)
Radiology

Apollo Health and Lifestyle Limited

(CIN: U85110TG20XKAPL115819)

Regd Office: 110 MG Road, Ashoka Raghupathi Chambers, 5th Floor, Bengaluru, Hyderabad, Telangana - 500 016
Ph: No. (044) 4744 7777 | Fax: No. (044) 7744 | Email ID: enquiry@apolohl.com | www.apolohl.com

APOLLO CLINICS NETWORK KARNATAKA

Bangalore (Basavanagudi) | Bellarychik | Electronic City | Fraser Town | HSR Layout | Indira Nagar | JP Nagar | Kundalahalli |
Kumarhattigala | Sarjapur Road | Mysore (VV Mohalla)

Online appointments: www.apolohl.com

TO BOOK AN APPOINTMENT

 **1860 500 7788**

Patient Name	: Mr. Ravindra R	Age/Gender	: 37 Y/M
UHID/MR No.	: CMYS.0000060595	OP Visit No	: CMYSOPV124848
Sample Collected on	:	Reported on	: 27-04-2024 15:56
LRN#	: RAD2311244	Specimen	:
Ref Doctor	: SELF		
Emp/Auth/TPA ID	: TZG0345115		

DEPARTMENT OF RADIOLOGY

X-RAY CHEST PA

Both lung fields and hila are normal .

No obvious active pleuro-parenchymal lesion seen .

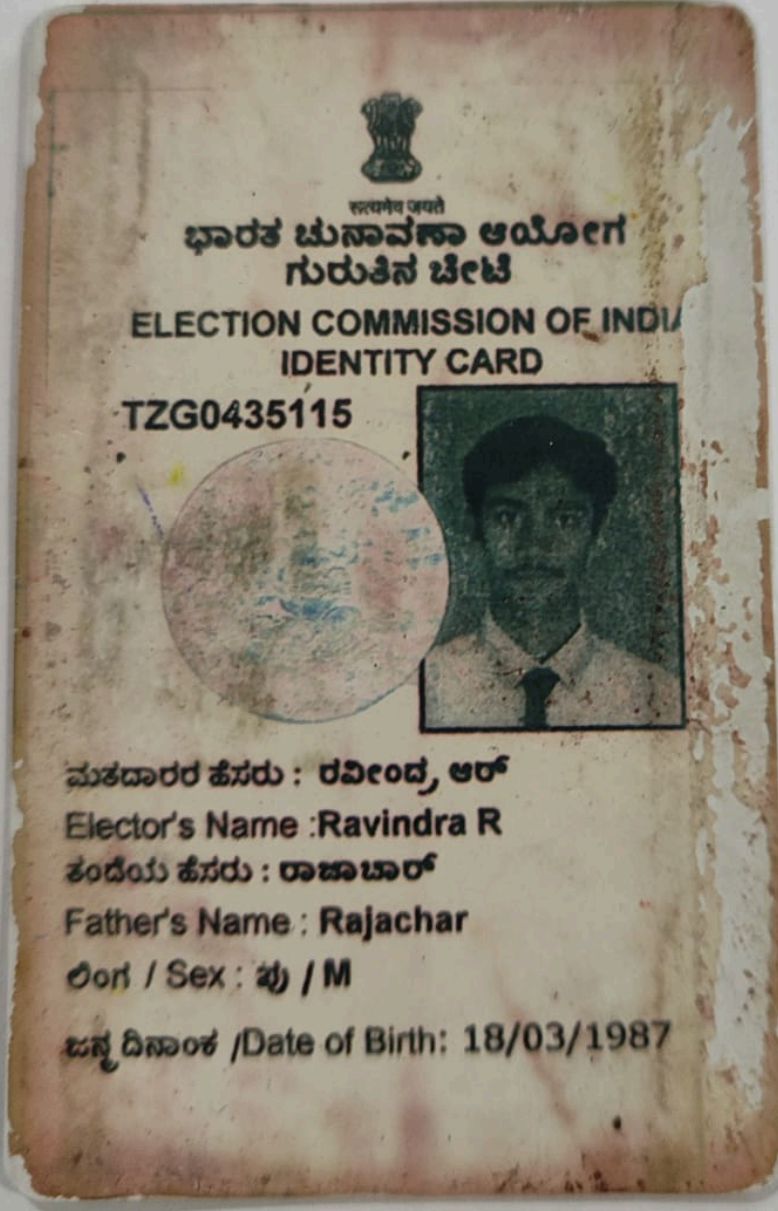
Both costophrenic and cardiophrenic angles are clear .

Both diaphragms are normal in position and contour .

Thoracic wall and soft tissues appear normal.

IMPRESSION : NORMAL STUDY.

Dr. CHETAN HOLEPPAGOL
MBBS, DNB(RADIO DIAGNOSIS)
Radiology



Your appointment is confirmed

noreply@apolloclinics.info <noreply@apolloclinics.info>

Tue 23-04-2024 12:08

To:ravindraraj.008@gmail.com <ravindraraj.008@gmail.com>

Cc:Mysore Apolloclinic <mysore@apolloclinic.com>;Yogeesh KV <mkt.mysore@apolloclinic.com>;Syamsunder M <syamsunder.m@apollohl.com>



Dear Ravindra R,

Greetings from Apollo Clinics,

Your corporate health check appointment is confirmed at **KALIDASA RAOD clinic** on **2024-04-27** at **08:30-08:45**.

Payment Mode	
Corporate Name	ARCOFEMI HEALTHCARE LIMITED
Agreement Name	[ARCOFEMI MEDIWHEEL PMC CREDIT PAN INDIA OP AGREEMENT]
Package Name	[ARCOFEMI - MEDIWHEEL - PMC PACK D - PAN INDIA - FY2324]

"Kindly carry with you relevant documents such as HR issued authorization letter and or appointment confirmation mail and or valid government ID proof and or company ID card and or voucher as per our agreement with your company or sponsor."

Note: Video recording or taking photos inside the clinic premises or during camps is not allowed and would attract legal consequences.

Note: Also once appointment is booked, based on availability of doctors at clinics tests will happen, any pending test will happen based on doctor availability and clinics will be updating the same to customers.

Instructions to be followed for a health check:

1. Please ensure you are on complete fasting for 10-To-12-Hours prior to check.
2. During fasting time do not take any kind of alcohol, cigarettes, tobacco or any other liquids (except Water) in the morning. If any medications taken, pls inform our staff before health check.
3. Please bring all your medical prescriptions and previous health medical records with you.
4. Kindly inform our staff, if you have a history of diabetes and cardiac problems.

For Women:

1. Pregnant women or those suspecting are advised not to undergo any X-Ray test.

2. It is advisable not to undergo any health check during menstrual cycle.

For further assistance, please call us on our Help Line #: 1860 500 7788.

Clinic Address: 23, KALIDASA ROAD, VV MOHLLA, MYSORE.

Contact No: (0821) 400 6040 - 41.

P.S: Health Check-Up may take 4 - 5hrs for completion on week days & 5 - 6hrs on Saturdays, kindly plan accordingly, Doctor Consultation will be completed after all the Reports are ready.

Warm Regards,
Apollo Clinic