



NABH



NABL



No.1



UNITED HOSPITAL

Care Par Excellence
Jayanagar, Bangalore

Out Patient Record

Patient Name : Mrs.KANCHELA ADILAKSHMI UHID : UHJA23018090
 Age / Sex : 34 Years / Female OP NO/Reg Dt : 10-02-2024 09:10 AM
 Spouse / Father Name : Department :
 Address : # NB353,Vijay Enclave Vijaya Bank Layout Referred By :
 Bilekahalli Banglroe 76, BANGALORE CITY Consultant : Dr.Preventive Health Check Up
 KMC No. :

Complaints / Findings / Observations :

Regular health check up

Investigations:

- Iron rich food

Treatment / Care of Plan / Provisional Diagnosis :

Iron

*Ⓣ Lab CHEMICAL - x + 001
x serum (GAP)*

Follow Up Advice :

Medically fit

Signature of the Doctor

UNITED HOSPITAL (A Unit of United Brothers Healthcare Services Private Limited)

DEPARTMENT OF RADIODIAGNOSIS

Name	Kanchela Adilakshmi	Date	10/02/24
Age	34 years	Hospital ID	UHJA23018090
Sex	Female	Ref.	Health check

RADIOGRAPH OF THE CHEST (PA – VIEW)

FINDINGS:

Bilateral lung fields are normal.

Bilateral costo-phrenic angles are normal.

Cardia and mediastinal contours are normal.

The bony thorax is grossly normal.

IMPRESSION:

- No radiographic abnormality.



Dr. Elluru Santosh Kumar
Consultant Radiologist

10-Feb-2024 AM 11:02:29

ID: 23018090

Name: Mrs. Adilakshmi

Birth date: / /

34 years

Sex: F cm kg

1100 Sinus rhythm
9110 ** normal ECG **

Indication:

Symptoms:

History:

Heart rate 75 bpm

PR interval 140 ms

QRS duration 80 ms

QT/QTc (E) interval 376/405 ms

QT/QTc (T) interval 56/38 ms

IV5/SV1 axis 1.00/0.82 mV

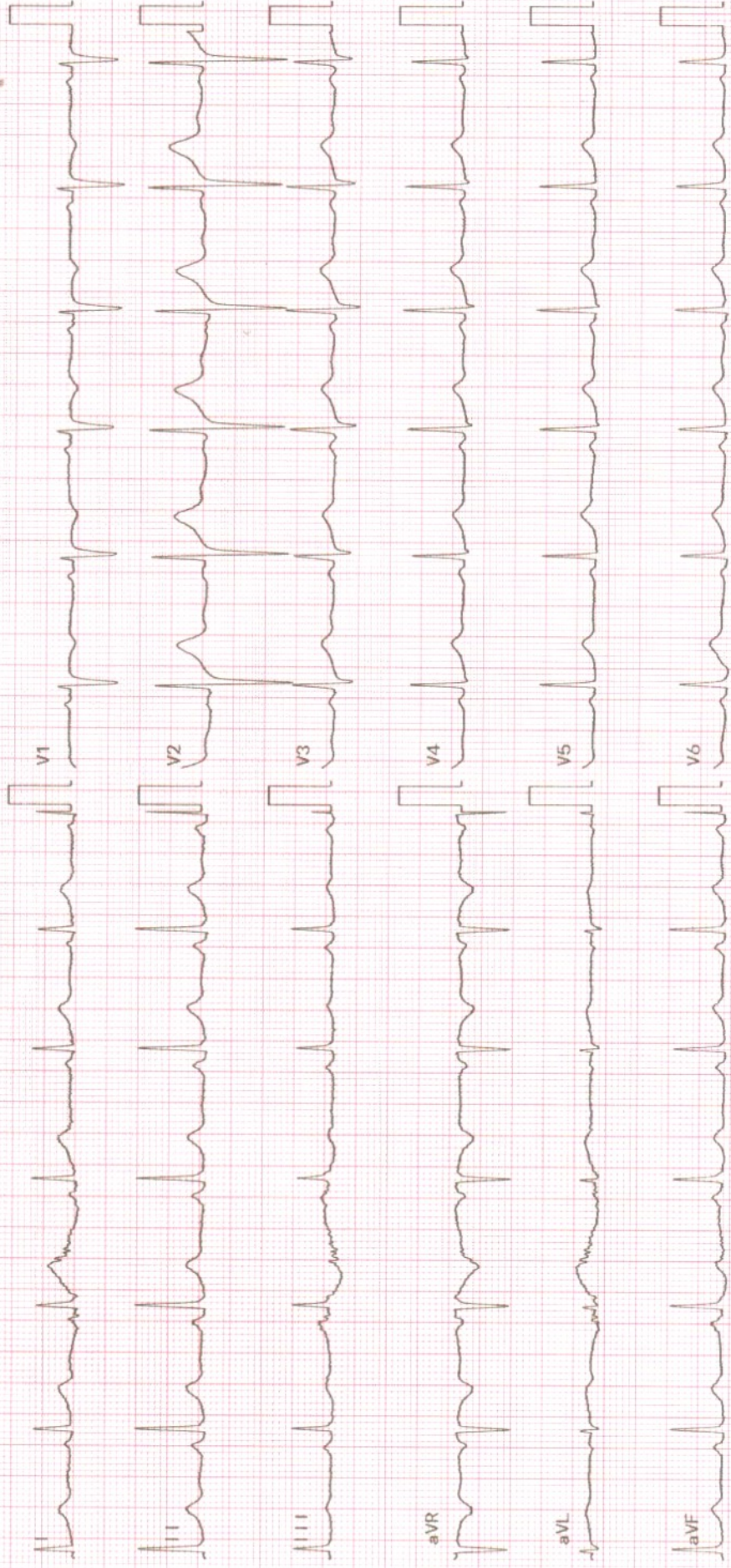
IV5+SV1 amp 1.82 mV

Unconfirmed Report

Reviewed by:

10 mm/mV 25 mm/s Filter: H50 D 35 Hz

10 mm/mV





NABH



NABL



No.1

Care Par Excellence
Jayanagar, Bangalore

Patient name :	Mrs. KANCHELA ADILAKSHMI	Date :	10/02/24
Age :	34 years GENDER: FEMALE	Patient ID :	18090
Ref by :	DR.CMO	OP/IP :	HEALTH CHECK

2D- ECHOCARDIOGRAPHY**M - MODE AND DOPPLER MEASUREMENTS**

(c.m)	(c.m)	(cm/sec)		
AO : 2.7 (2.5-3.7)	LVIDD : 3.9 (3.5-5.5)	MV EV : 76.3	AV : 84.7	MR : NORMAL
LA : 3.4 (1.9-4.0)	LVIDS : 3.2 (2.4-4.2)	AV : 100		AR : NORMAL
RA : 2.4 (<4.4)	IVSD : 0.8 (0.6-1.1)	PV : 97.5		PR : NORMAL
RV : 2.0 (<3.5)	IVSS : 1.0 (0.9-1.2)	TV EV : -----	AV : -----	TR : NORMAL
TAPSE: 1.9 (>1.6)	LVPWD : 1.1 (0.6-1.1)	Diastolic Function : NO LVDD		
	LVPWS : 1.2 (0.9-1.2)			
	EF : 60%			

DESCRIPTIVE FINDINGS

Left Ventricle	: NORMAL
Right Ventricle	: NORMAL
Left Atrium	: NORMAL
Right Atrium	: NORMAL
Wall motion analysis:	NO RWMA
Mitral Valve	: NORMAL
Aortic Valve	: NORMAL
Tricuspid Valve	: NORMAL
Pulmonary Valve	: NORMAL
IAS	: INTACT
IVS	: INTACT
Pericardium	: NORMAL
Other Findings	: IVC NORMAL

IMPRESSION :

NORMAL CHAMBER DIMENSIONS
 NORMAL LV SYSTOLIC FUNCTION EF : 60%
 NORMAL LV DIASTOLIC FUNCTION
 NO PULMONARY HYPERTENSION
 NO REGIONAL WALL MOTION ABNORMALITIES
 NO CLOTS/ PERICARDIAL EFFUSION /VEGETATION


DR. RAHUL PATIL
 CONSULTANT CARDIOLOGIST

UNITED HOSPITAL (A Unit of United Brothers Healthcare Services Private Limited)

United Hospital

No.110 (30), Madhavan Park Circle, 10th Main Rd,
 3rd Block Jayanagar, Bangalore - 560 011

T: 080 4566 6666

E: appointments@unitedhospital.
 W: www.unitedhospitals.com



NABH



NABL



No.1



UNITED HOSPITAL

Care Par Excellence
Jayanagar, Bangalore

Out Patient Record

Patient Name : Mrs.KANCHELA ADILAKSHMI UHID : UHJA23018090
 Age / Sex : 34 Years / Female OP NO/Reg Dt : 10-02-2024 09:10 AM
 Spouse / Father Name : Department :
 Address : # NB353, Vijay Enclave, Vijaya Bank Layout, Bilekahalli Bangalore, 76, BANGALORE CITY Referred By :
 Consultant : Dr.Preventive Health Check Up
 KMC No. :

Dr. Yoga Lakshmi SK
 MBBS, MS OBG, FMAS
 Consultant Obstetrician and
 Gynecologist, Laparoscopy
 Specialist
 KMC No. NB 353

Complaints / Findings / Observations :

for health check up

Investigations:

g/o very incoherence

*Ht - 161cm
 Wt - 69.1kg
 PR - 76b/min
 SpO2 - 98%
 BP - 96/60*

Treatment / Care of Plan / Provisional Diagnosis :

*No h/o ODM, DM, HTN, Thyroid
 No h/o any systemic
 or h/o falls*

*MI - 10y
 B/L
 AN 10y*

Follow Up Advice :

*P/A - soft
 P/B - soft
 med Vegetables*

*Coronary Artery Disease
 10y - 29/1/24
 10y - 29/1/24*

Boat - 1/1

Signature of the Doctor

Advice

- Blood sugar @

- $1/2 \rightarrow$

variations \rightarrow non

- formula $\frac{1}{2}$
3g L.

- keep in case
15 20 hi

1 





NABH



NABL



No.1



UNITED HOSPITAL

Care Par Excellence
Jayanagar, Bangalore

Out Patient Record

Patient Name : Mrs.KANCHELA ADILAKSHMI UHID : UHJA23018090
 Age / Sex : 34 Years / Female OP NO/Reg Dt : 10-02-2024 09:10 AM
 Spouse / Father Name : Department :
 Address : # NB353,Vijay Enclave Vijaya Bank Layout Referred By :
 Bilekahalli Banglroe 76, BANGALORE CITY Consultant : Dr.Preventive Health Check Up
 KMC No. :

Complaints / Findings / Observations :

Routine Eye test

Investigations:

VA L 6/6 (AV)

AIL 0

Treatment / Care of Plan / Provisional Diagnosis :

findings L 0

Follow Up Advice :

2yr! normal sm eye

Adv

Keep records

Signature of the Doctor

10/2/24

UNITED HOSPITAL (A Unit of United Brothers Healthcare Services Private Limited)

DEPARTMENT OF RADIODIAGNOSIS

Name	Kanchela Adilakshmi	Date	10/02/24
Age	34 years	Hospital ID	UHJA23018090
Sex	Female	Ref.	Health check

ULTRASOUND ABDOMEN AND PELVIS**FINDINGS:**

Liver is normal in size and echopattern. No intra or extra hepatic biliary duct dilatation. No focal lesions. **Portal vein** is normal in size, course and caliber. **CBD** is not dilated.

Gall bladder is normal without evidence of calculi, wall thickening or pericholecystic fluid.

Pancreas - Visualized part of the pancreatic head and body appears normal in size, contour and echogenicity. Rest of the pancreas is obscured by bowel gas.

Spleen is normal in size, shape, contour and echopattern. No evidence of mass or focal lesions.

Right Kidney is normal in size (10.5 x 3.5 cms), position, shape and echopattern. Corticomedullary differentiation is maintained. No evidence of calculi or hydronephrosis.

Left Kidney is normal in size (10.9 x 4.4 cms), position, shape and echopattern. Corticomedullary differentiation is maintained. No evidence of calculi or hydronephrosis.

Retroperitoneum- Visualized aorta appeared normal. No obvious enlarged para-aortic nodes.

Urinary Bladder is minimally distended.

Uterus is anteverted and normal in size, measures 7.6 x 3.4 x 4.7 cms. Myometrial and endometrial echoes are normal. Endometrium measures 6 mm.

Right ovary is normal in size and echopattern, measures 3.2 cc.

Left ovary is normal in size and echopattern, measures 3.9 cc.

Both adnexa: Normal. No mass is seen.

There is no ascites or pleural effusion. Appendix could not be localized. No RIF probe tenderness.

IMPRESSION:

- No definite sonological abnormality detected.



Dr. Elluru Santosh Kumar
Consultant Radiologist

Please bring this report during your visit to the Hospital / ಆಸ್ಪತ್ರೆಗೆ ಬರುವಾಗ ಈ ರಿಪೋರ್ಟನ್ನು ತನ್ನಿ