

**Health Check up Booking Confirmed Request(bobE8833),Package Code-
PKG10000474, Beneficiary Code-306339**

1 message

Mediwheel <wellness@mediwheel.in>
To: vidhidiagnostics@gmail.com
Cc: customercare@mediwheel.in

12 February 2024 at 16:22

**011-41195959****Hi Vidhi Diagnostics,**

We have received the confirmation for the following booking. Please provide your confirmation by clicking on the yes and no button.

Hospital Package Name : Mediwheel Full Body Health Checkup Male Below 40
Patient Package Name : Mediwheel Full Body Health Checkup Male Below 40
Package Code : PKG10000474
Contact Details : 8160346697
Email : solankidilip1505@gmail.com
Booking Date : 09-02-2024
Appointment Date : 20-02-2024
Confirmation Status : Booking Confirmed
Preferred Time : 9:00am

Member Information		
Booked Member Name	Age	Gender
MR. SOLANKI DILIPKUMAR RATILAL	38 year	Male

We request you to facilitate the employee on priority.

Thanks,
Mediwheel Team

You have received this mail because your e-mail ID is registered with This is a system-generated e-mail Arcofemi Healthcare Limited, please don't reply to this message.

Please visit to our Terms & Conditions for more information. This email is received because you are register with us. [Click here to unsubscribe.](#)

Dr. Dinesh S. Modh

M.D., D.M.R.E. (Radiodiagnosis)

Consultant Radiologist & Sonologist

Ex. Junior Lecturer, B.J. Medical College, Civil Hospital, Abad.

VIDHI
DIAGNOSTICS

Creating life in images

20/02/2024

Name:- Dilipkumar Ratilal Solanki

Age :- 38 yr. / Male

Height :- 176 cm.

Weight :- 56 kg

Sp :- 124/76 mm/hg

Pulse :- 66 per min.

T :- (N)

RS } (N)
CVS }

SpO₂ :- 98

Asymptomatic

H/o no DM, HTV, Thyroid or TB

Advice :- He is medically fit.

Dr. Vidhi D. Modh
Reg. No. 8-74540

ISO 9001:2015 Certified Diagnostics Center
Vidhi Imaging Center

Vidhi Diagnostics
L-86, Swatantra-Senani Nagar,
Opp. Akharnagar Bus Terminal,
Nr. Akharnagar Circle,
New Wadaj, Ahmedabad-13.

L-86, Swatantra Senani Nagar, Opp. Indian Oil Petrol Pump, Akharnagar Circle, Nava Wadaj, Ahmedabad - 380 013.

Phone : (Radiology) 079-2762 1406 | M. 98799 29406, 98250 09406 | Time (Radiology) : Mon. to Sat. 9 am to 2 pm, 5 to 9 pm, Sunday 9 am to 12 Noon
E-mail : vidhidiagnostics@gmail.com, Website : www.vidhidiagnostics.com

Multislice CT Scan | CBCT-Dental Scan | Live 3D-4D Sonography | Colour Doppler | Echo Cardiography | Interventional Radiology | Maxillofacial Radiology | Fetal Medicine
Digital X-Ray | Digital Mammography | Digital OPG/TMJ | ECG/TMT/PFT/EEG/EMG | Audiometry | Pathology Laboratory | Health Check Up Plans | Pre Employment Check Up

CT SCAN & CBCT FACILITY NOW AVAILABLE

Dr. Dinesh S. Modh

M.D., D.M.R.E. (Radiodiagnosis)
Consultant Radiologist & Sonologist
Ex. Junior Lecturer, B.J. Medical College, Civil Hospital, A'bad.



Patient's name : DILIPKUMAR RATILAL SOLANKI
Reg. ID : R-13290-23
Referred by : Dr. MEDIWHEEL

Age/Sex : 38 Years/Male
Accession : 22440
Date : 20/02/2024

2D- ECHO REPORT

FINAL CONCLUSION:

LV IS NORMAL SIZE. GOOD LV SYSTOLIC FUNCTION NO RWMA.
LVEF - 60%. NO CONCENTRIC LVH.
NORMAL LV COMPLIANCE.
LA IS NORMAL SIZE. NO LA CLOT.
RV IS NORMAL SIZE. GOOD RV SYSTOLIC FUNCTION.
RA IS NORMAL SIZE.
MITRAL VALVE IS NORMAL. NO MS. MILD MR (10%). NO MVP.
AORTIC VALVE IS NORMAL. NO AS. NO AR.
TRICUSPID VALVE IS NORMAL. NO TR. RVSP-26 mmHg. NO PAH.

NO CLOT, NO VEGETATION, NO PERICARDIAL EFFUSION.

DIMENSIONS:

AORTA	2.6 C.M
LEFT ATRIUM	2.7 C.M
LVDD	4.1 C.M.
IVSD	1.0 C.M
PWD	1.0 C.M
LVDS	2.6 C.M.

COLOUR DOPPLER FINDING:

STRUCTURE	VELOCITY m/sec
	Max
PULMONARY VALVE	0.7
MITRAL VALVE	E : 0.7 A: 0.4
AORTIC VALVE	1.0

Dr. Avinash Bhaskar
Avinash Bhaskar
G-48548
DR AVINASH BHASKAR
CLINICAL CARDIOLOGIST
9924836431

ISO 9001:2015 Certified Diagnostics Center

Vidhi Imaging Center

L-86, Swatantra Senani Nagar, Opp. Indian Oil Petrol Pump, Akhbarnagar Circle, **Nava Vadaaj**, Ahmedabad - 380 013.

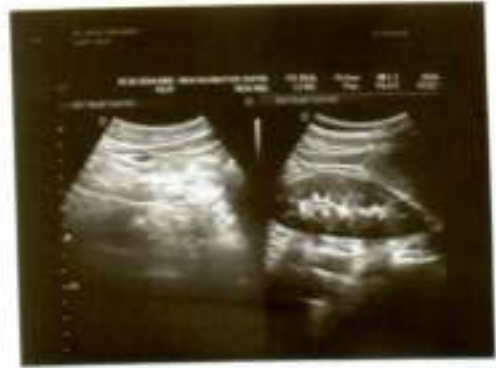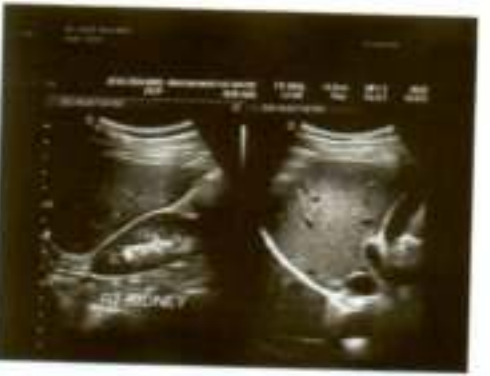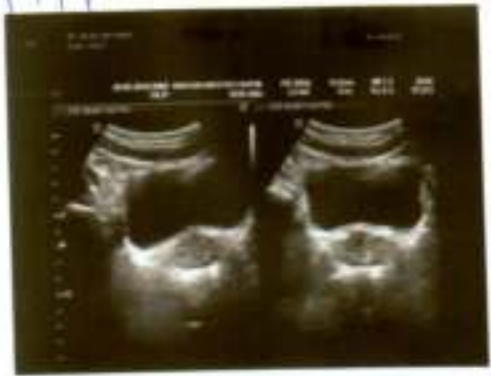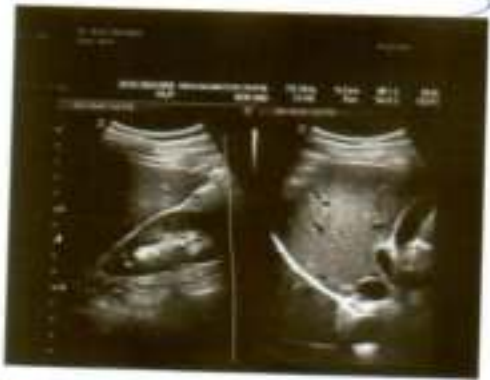Phone : (Radiology) 079-2762 1406 | M. 98799 29406, 98250 09406 | Time (Radiology) : Mon. to Sat. 9 am to 2 pm, 5 to 9 pm, Sunday 9 am to 12 Noon

E-mail : vidhidiagnostics@gmail.com, Website : www.vidhidiagnostics.com

Multislice CT Scan | CBCT-Dental Scan | Live 3D-4D Sonography | Colour Doppler | Echo Cardiography | Interventional Radiology | Maxillofacial Radiology | Fetal Medicine
Digital X-Ray | Digital Mammography | Digital DPG/TMJ | ECG/TMT/PFT/EEG/EMG | Audiometry | Pathology Laboratory | Health Check Up Plans | Pre Employment Check Up

CT SCAN & CBCT FACILITY NOW AVAILABLE

Diarr



Dr. Dinesh S. Modh

M.D., D.M.R.E. (Radiodiagnosis)

Consultant Radiologist & Sonologist

Ex. Junior Lecturer, B.J. Medical College, Civil Hospital, A'bad.



Patient's name : DILIPKUMAR RATILAL SOLANKI
Reg. ID : R-13290-23
Referred by : Dr. MEDIWHEEL

Age/Sex : 38 Years/Male
Accession : 22440
Date : 20/02/2024

USG ABDOMEN

LIVER:- Liver appears normal size and echopattern. No e/o focal lesion is seen. IHBR appear normal. PV & CBD appears normal. No e/o calculus is seen in bile duct.

GALL BLADDER:- Gall bladder is distended & appears normal. No e/o calculus or cholecystitis is seen. No evidence of pericholecystic fluid is seen.

SPLEEN:- Spleen appears normal in size & shows normal echotexture. No evidence of diffuse or focal lesion is seen.

PANCREAS:- Pancreas appears normal size and echopattern. No e/o diffuse or focal lesion is seen. Main pancreatic duct appears normal.

KIDNEY:- Both Kidneys appear normal in size & echotexture.

- Right kidney shows 6mm calculus in upper calyx.
- Left kidney shows 4mm calculus in upper calyx.

No e/o hydronephrosis or hydroureter is seen in both sides.

Cortico-medullary differentiation is maintained on either side.

Both suprarenal regions appear normal.

No evidence of pre & para aortic lymphadenopathy is seen.

RIF & BOWEL (by high frequency probe-10Mhz): -Normal.

No evidence of free fluid is seen in abdomen.

No evidence of dilated or thickened bowel loops is seen.

Urinary bladder: - appear normal. No e/o calculus or mass lesion is seen in bladder.

Prostate appears normal size and echopattern.

Thanks for reference.

Dr. Dinesh S. Modh
(M.D. DMRE (Radiodiagnosis))
DR DINESH S. MODH
M.D. DMRE (RADIO DIAGNOSIS)

ISO 9001:2015 Certified Diagnostics Center

Vidhi Imaging Center

L-86, Swatantra Senani Nagar, Opp. Indian Oil Petrol Pump, Akharnagar Circle, Nava Vada, Ahmedabad - 380 013.

Phone : (Radiology) 079-2762 1406 | M. 98799 29406, 98250 09406 | Time (Radiology) : Mon. to Sat. 9 am to 2 pm, 5 to 9 pm, Sunday 9 am to 12 Noon

E-mail : vidhidiagnostics@gmail.com, Website : www.vidhidiagnostics.com

Multislice CT Scan | CBCT-Dental Scan | Live 3D-4D Sonography | Colour Doppler | Echo Cardiography | Interventional Radiology | Maxillofacial Radiology | Fetal Medicine
Digital X-Ray | Digital Mammography | Digital DPG / TMJ | ECG / TMT / PFT / EEG / EMG | Audiometry | Pathology Laboratory | Health Check Up Plans | Pre Employment Check Up

CT SCAN & CBCT FACILITY NOW AVAILABLE

HR : 66 bpm
 PR : 144 ms
 QRS : 84 ms
 QT/QTc : 386/404 ms
 P/QRS/T : 40/43/56 deg
 RV5/SV1 : 1.634/-0.859 mv
 RV5+SV1 : 2.493 mv

ID: 12597
 Name: dilipkumar solanki
 Age: 38yrs
 Sex: Male
 Hospital: Dr. Avinash Bhaskar
123/DC/India

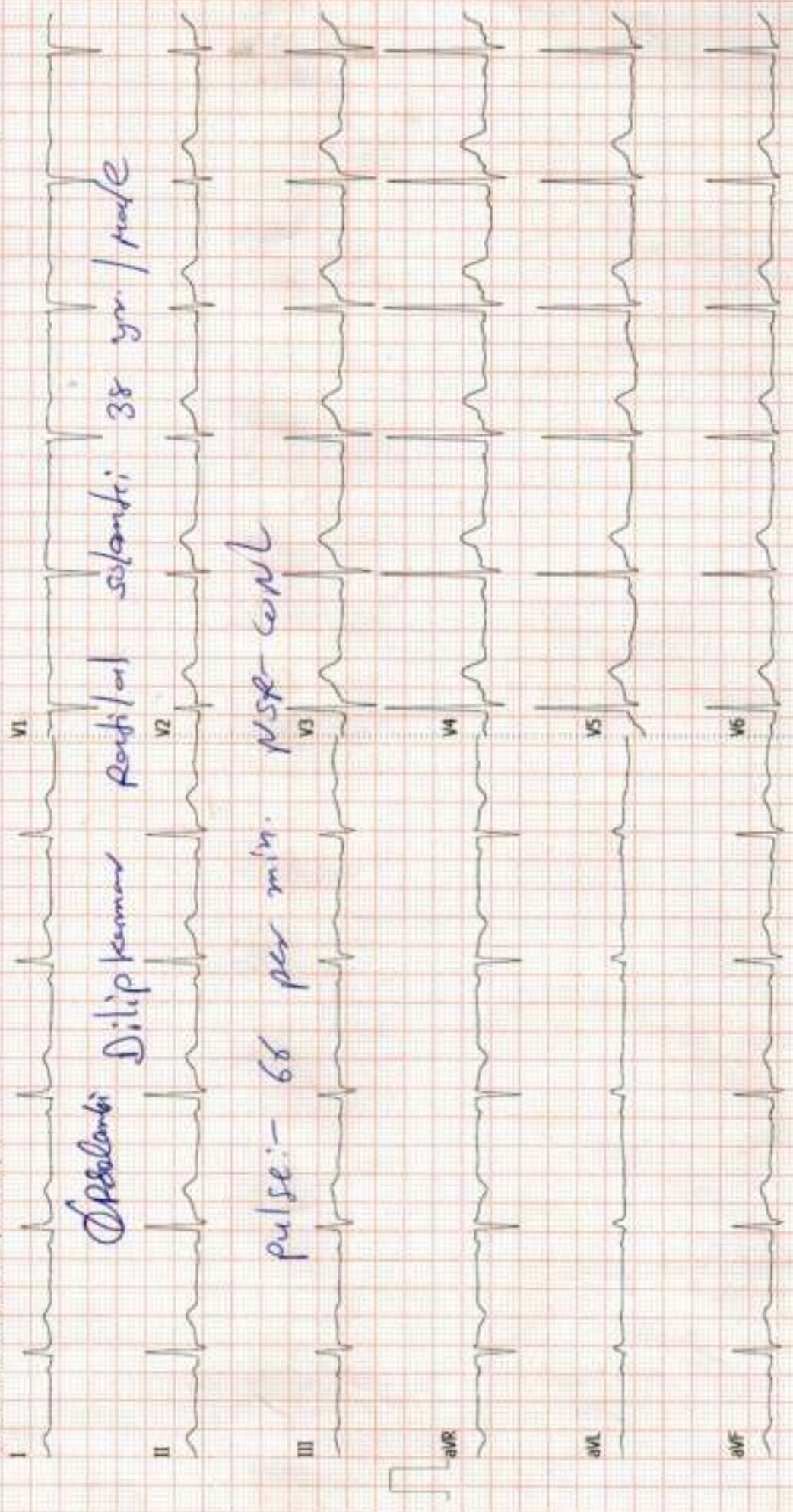
Vidhi Diagnostics
 L-86, Svatantre-Senani Nagar,
 Opp. Akhbarnagar Bus Terminals,
 Nr. Akhbarnagar Circle,
 New Wadaj, Ahmedabad-13.

Department: **G-45948**

Need to be confirmed by doctor. Doctor Name:

20/02/2024

0.67Hz - 35Hz AC 50Hz 25 mm/s 10 mm/mv



Dr. Dinesh S. Modh

M.D., D.M.R.E. (Radiodiagnosis)

Consultant Radiologist & Sonologist

Ex. Junior Lecturer, B.J. Medical College, Civil Hospital, A'bad.

VIDHI[®]
DIAGNOSTICS

Creating life in health

20/09/2024

Name:- Dilipkumar Patil Salanki
38 yr. / male

Dear Team,

I don't give stool sample.

Vidhi Diagnostics

L-86, Swatantra-Senani Nagar,
Opp. Akhbarnagar Bus Terminal,
Nr. Akhbarnagar Circle,
New Wadaj, Ahmedabad - 380 013.

D. Salanki

ISO 9001:2015 Certified Diagnostics Center

Vidhi Imaging Center

L-86, Swatantra Senani Nagar, Opp. Indian Oil Petrol Pump, Akhbarnagar Circle, **Nava Wadaj**, Ahmedabad - 380 013.

Phone : (Radiology) 079-2762 1406 | M. 98799 29406, 98250 09406 | Time (Radiology) : Mon. to Sat. 9 am to 2 pm, 5 to 9 pm, Sunday 9 am to 12 Noon

E-mail : vidhidiagnostics@gmail.com, Website : www.vidhidiagnostics.com

Multislice CT Scan | CBCT-Dental Scan | Live 3D-4D Sonography | Colour Doppler | Echo Cardiography | Interventional Radiology | Maxillofacial Radiology | Fetal Medicine
Digital X-Ray | Digital Mammography | Digital OPG / TMJ | ECG / TMT / PFT / EEG / ENG | Audiometry | Pathology Laboratory | Health Check Up Plans | Pre Employment Check Up

CT SCAN & CBCT FACILITY NOW AVAILABLE



Patient's name : DILIPKUMAR RATILAL SOLANKI
Age/Sex : 38 Years/Male
Referred by : Dr. MEDIWHEEL
Collection Time : 08:56

Reg. ID : P-6156-23
Accession : 22431
Order Dt/time : 20/02/2024 08:56

Complete Blood Count

Sample Type: EDTA

Test Name	Result	Units	Biological Reference Interval
<u>Blood Counts</u>			
Haemoglobin :	13.3	Gms%	13.5 - 18.0
Total R.B.C. :	4.87	mill/c.mm	4.7 - 6.0
Total W. B. C. :	5610	/cu mm	4000 - 10500
Platelet Count :	167000	/cu.mm	1,50,000 - 4,50,000
<u>Differential Count</u>			
Neutrophils :	57	%	40 - 70
Lymphocytes :	38	%	20 - 40
Eosinophils :	03	%	1 - 4
Monocytes :	02	%	2 - 6
Basophils :	00	%	0 - 01
<u>Blood Indices</u>			
P. C. V :	40.7	%	42 - 52
M. C. V. :	83.5	fl	78 - 100
M.C.H :	27.4	pg	27 - 31
M. C. H. C :	32.8	%	32 - 36
R.D.W :	13.8	%	11.5 - 14.0

E.S.R.(Westergren Method)

After one hour : 04 mm/hr 1 - 7

TESTS DONE ON FULLY AUTOMATED HEMATOLOGY ANALYZER.

Dr. Gayatri M. Mehta

M. D. (Patho)

DR GAYATRI MEHTA
MD(PATHOLOGY)

DR. ANAND D. PARIKH
MD(PATHOLOGY)

LAB USE ONLY (Entered by :GM Enter Date/Time:20/02/2024 15:31:00) (Verify by :GM Verify Date/Time:20/02/2024 15:31:00)



Vidhi Diagnostics | Pathology Department

L-86, Swatantra Senani Nagar, Opp. Akhbaragar Petrol Pump, Nr. Akhbaragar Circle, Nava-Vadaj, Ahmedabad - 380 013.

M. - Pathology : 8849893954, Ph. : 079-27621406, M. 98799 29406, 98250 09406, E-mail : vidhidiagnostics@gmail.com, Web. : www.vidhidiagnostics.com

Time (Pathology) : Mon. to Sat. 8.30 am to 8.00 pm, Sunday 9 am to 12 Noon

Pathology means science behind medicine

CT SCAN & CBCT FACILITY NOW AVAILABLE



Patient's name : DILIPKUMAR RATILAL SOLANKI
Age/Sex : 38 Years/Male
Referred by : Dr. MEDIWHEEL
Collection Time : 08:56

Reg. ID : P-6156-23
Accession : 22431
Order Dt/time : 20/02/2024 08:56

Blood Group

Sample Type: EDTA sample.

Test Name	Result
BG :	" O "
RH :	POSITIVE
Remarks	Done by forward grouping method.

Blood Glucose

Sample Type: Serum

Test Name	Result	Units	Biological Reference Interval
Fasting Blood Glucose :	79.2	mg/dl	70 - 110
Urine Sugar :	NIL		Absent
<i>GOD-POD Method.</i>			

Blood Glucose

Sample Type: Serum

Test Name	Result	Units	Biological Reference Interval
Post Prandial Blood Glucose After 2hr. :	86.2	mg/dl	80 - 140
Urine Sugar :	NIL		Absent
<i>GOD-POD Method.</i>			

Dr. Gayatri M. Mehta
M. D. (Patho)

DR GAYATRI MEHTA
MD(PATHOLOGY)
Reg. No. G-32215

DR. ANAND D. PARIKH
MD(PATHOLOGY)

LAB USE ONLY (Entered by :GM Enter Date/Time:20/02/2024 15:33:00) (Verify by :GM Verify Date/Time 20/02/2024 15:33:00)



Vidhi Diagnostics | Pathology Department

L-85, Swatantra Senani Nagar, Opp. Akharnagar Petrol Pump, Nr. Akharnagar Circle, Nava-Vadaj, Ahmedabad - 380 013.

M. - Pathology : 8849833954, Ph. : 079-27621406, M. 98799 29406, 98250 09406, E-mail : vidhidiagnostics@gmail.com, Web. : www.vidhidiagnostics.com

Time (Pathology) : Mon. to Sat. 8.30 am to 8.00 pm, Sunday 9 am to 12 Noon

Pathology means science behind medicine

CT SCAN & CBCT FACILITY NOW AVAILABLE



Patient's name : DILIPKUMAR RATILAL SOLANKI
Age/Sex : 38 Years/Male
Referred by : Dr. MEDIWHEEL
Collection Time : 08:56

Reg. ID : P-6156-23
Accession : 22431
Order Dt/time : 20/02/2024 08:56

Lipid Profile

Sample Type: Serum

Test Name	Result	Units	Biological Reference Interval
S. Cholesterol : Oxidase-esterase method.	176	mg/dl	0 - 200
S. Triglyceride : Enzymatic Colorimetry method	101.3	mg/dL	0 - 200
S. HDL - Cholesterol : Serum by Enzymatic method.	57.6	mg/dL	35 - 65
S. LDL - Cholesterol : Serum by Enzymatic method	98.14	mg/dL	0 - 130
S. VLDL - Cholesterol :	20.26	mg/dL	0 - 30
S. Chole/HDL.Ratio :	3.06		1 - 6
S. LDL / HDL Cholesterol Ratio :	1.7		0 - 3.5

Dr. Gayatri M. Mehta
M. D. (Patho)

DR GAYATRI MEHTA-32215
MD(PATHOLOGY)

DR. ANAND D. PARIKH
MD(PATHOLOGY)

LAB USE ONLY (Entered by :GM Enter Date/Time:20/02/2024 15:33:00) (Verify by :GM Verify Date/Time:20/02/2024 15:33:00)



Vidhi Diagnostics | Pathology Department

L-86, Swatantra Senani Nagar, Opp. Akhbarnagar Petrol Pump, Nr. Akhbarnagar Circle, Nava-Vadaj, Ahmedabad - 380 013.

M. - Pathology : 8849893954, Ph. : 079-27621406, M. 98799 29406, 98250 09406, E-mail : vidhidiagnostics@gmail.com, Web. : www.vidhidiagnostics.com

Time (Pathology) : Mon. to Sat. 8.30 am to 6.00 pm, Sunday 9 am to 12 Noon

Pathology means science behind medicine

CT SCAN & CBCT FACILITY NOW AVAILABLE



Patient's name : DILIPKUMAR RATILAL SOLANKI
Age/Sex : 38 Years/Male
Referred by : Dr. MEDIWHEEL
Collection Time : 08:56

Reg. ID : P-6156-23
Accession : 22431
Order Dt/time : 20/02/2024 08:56

HbA1C

Sample Type: EDTA

Test Name	Result	Units	Biological Reference Interval
HbA1C :	5.0	%	Non-diabetic: 4.2-6.2 Pre-diabetic : 6.3-7.2 Diabetic : 7.3-8.2
Mean Blood Glucose of Last 03 months.	97	mg/dl	

Comment *As per the new 2009 update of American Diabetes Association regarding HbA1C & Mean Blood Glucose relationship.
NOTE: This test is used to monitor diabetic patients compliance with the therapeutic regimen and logo It's level is proportional to both the average blood glucose concentration and the life span of the red blood cells (RBC) in circulation. HbA1c values are free of day to day glucose fluctuations and are unaffected by exercise or recent food intake.

Dr. Gayatri M. Mehta
M. D. (Patho)

DR GAYATRI MEHTA
MD(PATHOLOGY)

DR. ANAND D. PARIKH
MD(PATHOLOGY)

LAB USE ONLY (Entered by :GM Enter Date/Time:20/02/2024 15:33:00) (Verify by :GM Verify Date/Time:20/02/2024 15:33:00)



Vidhi Diagnostics | Pathology Department

L-86, Swatantra Senani Nagar, Opp. Akhbarnagar Petrol Pump, Nr. Akhbarnagar Circle, Nava-Vadaj, Ahmedabad - 380 013.

M. - Pathology : 8849893954, Ph. : 079-27621406, M. 98799 29406, 98250 09406, E-mail : vidhidiagnostics@gmail.com, Web. : www.vidhidiagnostics.com

Time (Pathology) : Mon. to Sat. 8.30 am to 8.00 pm, Sunday 9 am to 12 Noon

Pathology means science behind medicine

CT SCAN & CBCT FACILITY NOW AVAILABLE



Pathology Department

VIDHI
DIAGNOSTICS

Caring life in Ahmedabad

Patient's name : DILIPKUMAR RATILAL SOLANKI
Age/Sex : 38 Years/Male
Referred by : Dr. MEDIWHEEL
Collection Time : 08:56

Reg. ID : P-6156-23
Accession : 22431
Order Dt/time : 20/02/2024 08:56

BIOCHEMISTRY

Sample type : Serum

Test Name	Result	Units	Biological Reference Interval
Urea, (Serum by GLDH method) :	18.2	mg/dl	10 - 50
S.Uric acid, (Serum by Uricase method) :	6.7	mg/dl	3.4 - 7.0
Bun :	8.5	mg/dl	6-20
Creatinine, (Serum by Enzymatic reaction) :	0.94	mg/dl	0.5-1.2
S.G.P.T (ALT) : (Serum by IFCC method)	12.2	U/L	0 - 40
S.G.O.T (AST) : (Serum by IFCC method)	26.9	U/L	0 - 37
ALK.PHOSPHATASE : (Serum by PNP method)	66	U/L	40-129
G.G.T :	15.9	U/L	8 - 78
BILIRUBIN			
Total :	0.88	mg/dl	Up to 1.2
Direct :	0.42	mg/dl	0-0.7
Indirect :	0.46	mg/dl	0 - 0.5
SERUM PROTEINS			
Total Protein (Serum by Biuret method) :	6.67	gms/dl	6.4 - 8.5
Albumin (Serum by BCG method) :	4.30	gms/dl	3.97-4.94
Globulins :	2.37	gms/dl	2.3 - 3.5
A/G Ratio :	1.814		0.9 - 2.9

Dr. Gayatri M. Mehta

M. D. (Patho)

DR. GAYATRI MEHTA
MD(PATHOLOGY)

DR. ANAND D. PARIKH
MD(PATHOLOGY)

LAB USE ONLY (Entered by : GM Enter Date/Time: 20/02/2024 15:31:00) (Verify by : GM Verify Date/Time: 20/02/2024 15:31:00)



Vidhi Diagnostics | Pathology Department

L-86, Swatantra Senani Nagar, Opp. Akhbarnagar Petrol Pump, Nr. Akhbarnagar Circle, Nava-Vadaj, Ahmedabad - 380 013.

M. - Pathology : 8849893954, Ph. : 079-27621406, M. 98799 29406, 98250 09406, E-mail : vidhidiagnostics@gmail.com, Web. : www.vidhidiagnostics.com

Time (Pathology) : Mon. to Sat. 8.30 am to 8.00 pm, Sunday 9 am to 12 Noon

Pathology means science behind medicine

CT SCAN & CBCT FACILITY NOW AVAILABLE



Pathology Department



Patient's name : DILIPKUMAR RATILAL SOLANKI
Age/Sex : 38 Years/Male
Referred by : Dr. MEDIWHEEL
Collection Time : 08:56

Reg. ID : P-6156-23
Accession : 22431
Order Dt/time : 20/02/2024 08:56

Thyroid Function Test

Sample Type: Serum

Test Name	Result	Units	Biological Reference Interval
TOTAL T3 :	1.26	ng/ml	0.84 - 2.0
TOTAL T4 :	8.01	µg/dL	5.1 - 14.0
TSH(Ultra sensitive) :	1.96	µIU/mL	0.27 - 4.2

Dr. Gayatri M. Mehta
M. D. (Patho)

DR. GAYATRI MEHTA
MD(PATHOLOGY)

DR. ANAND D. PARIKH
MD(PATHOLOGY)

LAB USE ONLY (Entered by :GM Enter Date/Time:20/02/2024 15:35:00) (Verify by :GM Verify Date/Time:20/02/2024 15:35:00)



Vidhi Diagnostics | Pathology Department

L-86, Swatantra Senani Nagar, Opp. Akhbarnagar Petrol Pump, Nr. Akhbarnagar Circle, Nava-Vadaj, Ahmedabad - 380 013.

M. - Pathology : 8849893954, Ph. : 079-27621406, M. 98799 29406, 98250 09406, E-mail : vidhidiagnostics@gmail.com, Web. : www.vidhidiagnostics.com

Time (Pathology) : Mon. to Sat. 8.30 am to 8.00 pm, Sunday 9 am to 12 Noon

Pathology means science behind medicine

CT SCAN & CBCT FACILITY NOW AVAILABLE



Patient's name : DILIPKUMAR RATILAL SOLANKI
Age/Sex : 38 Years/Male
Referred by : Dr. MEDIWHEEL
Collection Time : 08:56

Reg. ID : P-8156-23
Accession : 22431
Order Dt/time : 20/02/2024 08:56

Urine Analysis

Sample Type: Urine

Test Name	Result	Units	Biological Reference Interval
-----------	--------	-------	-------------------------------

Physical Examination

Quantity :	20	ml	0 - 500 ml
Colour :	Pale Yellow		Pale Yellow
Transparency :	Slight Turbid.		Clear
Reaction :	Acidic		4.6 - 8.0
Specific Gravity :	1.010		1.016 - 1.022
Sediment :	Present		

Chemical Examination

Albumin :	Present (Faint Trace)		Absent
Sugar :	NIL		Absent
Acetone :	Absent		Absent
Bile Salts :	Absent		Absent
Bile Pigments :	Absent		Absent
Urobilogen :	Absent		Absent
Nitrites :	Absent		Absent

Microscopic Examination

Red blood Cells :	Occasional	/h.p.f	Absent
Pus Cells :	1-2	/h.p.f	Absent
Epithelial Cells :	1-2	/h.p.f	< 10.0
Amorphous :	Absent	/h.p.f	Absent
Bacteria :	Absent	/h.p.f	Absent
Crystals :	Absent	/h.p.f	Absent
Casts :	Absent	/h.p.f	Absent
Fungus :	Not seen	/h.p.f	Absent

Dr. Gayatri M. Mehta

M. D. (Patho)

Reg. No. G-32215

DR. GAYATRI MEHTA
MD(PATHOLOGY)

DR. ANAND D. PARIKH
MD(PATHOLOGY)



(Entered by :GM Enter Date/Time:20/02/2024 15:34:00) (Verify by :GM Verify Date/Time:20/02/2024 15:34:00)

Vidhi Diagnostics | Pathology Department

L-86, Swatantra Senani Nagar, Opp. Akhbaragar Petrol Pump, Nr. Akhbaragar Circle, Nava-Vadaj, Ahmedabad - 380 013.

M. - Pathology : 8849893954, Ph. : 079-27621406, M. 98799 29406, 98250 09406, E-mail : vidhidiagnostics@gmail.com, Web. : www.vidhidiagnostics.com

Time (Pathology) : Mon. to Sat. 8.30 am to 8.00 pm, Sunday 9 am to 12 Noon

Pathology means science behind medicine

CT SCAN & CBCT FACILITY NOW AVAILABLE

સુરક્ષિત દસ્તાવેજ
Government of India




Aadhaar no. 1985-1985-1985



સાધારણ ઓળખ કાર્ડ
Dikpumar Rastel Solanki
www.aadhaar.gov.in/DOB: 15/05/1985
પુલ/ MALE

આધાર એ ઓળખનો પુરાવો છે, નાગરિકતા અથવા જન્મ તારીખનો નથી.
 It is not a proof of citizenship or date of birth. It should be used with verification (online authentication, or scanning of QR code / offline XML).

4099 7015 1540

મારી આધાર, મારી ઓળખ

D Solanki

Vidhi Diagnostics
 L-66, Swatantra-Sonani Nagar,
 Opp. Akharnagar Bus Terminals,
 Nr. Akharnagar Circle,
 New Nedaaj, Ahmedabad-13.



Vidhi Diagnostics

L-25, Gokulnagar Sonani Nagar,
Opp. Akhbarnagar Bus Terminal,
Nr. Akhbarnagar Circle,
New Waziraj, Ahmedabad-13.

Dr. Dinesh S. Modh

M.D., D.M.R.E. (Radiodiagnosis)

Consultant Radiologist & Sonologist

Ex. Junior Lecturer, B.J. Medical College, Civil Hospital, A'bad.

VIDHI
DIAGNOSTICS



Patient's name: DILIPKUMAR RATILAL SOLANKI
Reg. ID : R-13290-23
Referred by : Dr. MEDIWHEEL

Age/Sex : 38 Years/Male
Accession : 22440
Date : 20/02/2024

X-RAY CHEST (PA VIEW)

Both lung fields appear normal.
No e/o consolidation or cavitations is seen.
Both costo-phrenic angles appear clear.
Cardiac size is with in normal limits.
Both domes of diaphragm appear normal.
Bony thoracic cage appears normal.

Thanks for reference.

Dr. Dinesh S. Modh
MD DMRE (Radiodiagnosis)
G-23825
DR DINESH S. MODH
M.D. DMRE(RADIODIAGNOSIS)

ISO 9001:2015 Certified Diagnostics Center

Vidhi Imaging Center

L-86, Swatantra Senani Nagar, Opp. Indian Oil Petrol Pump, Akhbarnagar Circle, Nava Vadaaj, Ahmedabad - 380 013.

Phone : (Radiology) 079-2762 1406 | M. 98799 29406, 98250 09406 | Time (Radiology) : Mon. to Sat. 9 am to 2 pm, 5 to 9 pm, Sunday 9 am to 12 Noon

E-mail : vidhidiagnostics@gmail.com, Website : www.vidhidiagnostics.com

Multislice CT Scan | CBCT-Dental Scan | Live 3D-4D Sonography | Colour Doppler | Echo Cardiography | Interventional Radiology | Maxillofacial Radiology | Fetal Medicine
Digital X-Ray | Digital Mammography | Digital OPG / TMJ | ECG / TMT / PFT / EEG / EMG | Audiometry | Pathology Laboratory | Health Check Up Plans | Pre Employment Check Up

CT SCAN & CBCT FACILITY NOW AVAILABLE