



MEDICOVER
HOSPITALS

MEDICOVER HOSPITALS

MEDICAL HEALTH CHECK- UP ASSESMENT FORM

NAME : Mr / Mrs Sarif Elahi

DATE: 29/4/24

AGE : 26 yrs

SEX: Male/ Female

NMU: NMU000 51949

DOCTOR'S NAME:

Health Package

TEMP :	<u>97° f</u>	BP :	<u>110/64</u> mmHg
PULSE :	<u>81</u> b/m	HEIGHT :	<u>162</u> cm
RR :	<u>22</u> b/m	WEIGHT :	<u>50</u> kg
SPO2 :	<u>100%</u>	HGT:	<u>-</u>

REMARK:



MEDICOVER
HOSPITALS

NAVI MUMBAI

MEDICAL CERTIFICATE

I, Dr. Sachin J. Nalavade do hereby certify that I have carefully examined .

Sri./Smt. Saif Elahi , son / daughter.

Of Mohammed Asees is physically fit / unfit to join Organization .

Signature of Doctor: Sachin J. Nalavade

Registration No : 2005010410

Place : Kharghar

Date : 29/09/24

Dr. Sachin Nalavade
MD Medicine , FADM F-Echo, MBBS
Consultant Physician
Diabetes & Intensivist
Regd. No- 2005/01/0410

Seal:





DEPARTMENT OF LABORATORY

NAVI MUMBAI

Patient Name : Mr. SAIF ELAHI	Age / Gender : 26 Y(s)/Male
Bill No/ UMR No : NMBC68226/NMU0051949	Referred By : Dr. DMO
Received Dt : 29-Apr-24 09:54 am	Report Date : 29-Apr-24 02:43 pm

FINAL REPORT

<u>Parameters</u>	<u>Specimen</u>	<u>Result</u>	<u>Biological Reference Intervals</u>	<u>Method</u>
CUE(COMPLETE URINE EXAMINATION)				
<u>PHYSICAL EXAMINATION</u>				
VOLUME	Urine	20 ml		
COLOUR		PALE YELLOW	PALE YELLOW	
APPEARANCE		SLIGHTLY HAZY	CLEAR	
DEPOSIT		ABSENT	ABSENT	
<u>CHEMICAL EXAMINATION</u>				
SPECIFIC GRAVITY	Urine	1.015	1.000 - 1.030	Dipstick
PH		6.0	5.0 - 8.0	Dipstick
PROTEIN		NEGATIVE	NEGATIVE	Dipstick/Heat coagulation test
GLUCOSE		ABSENT	ABSENT	Dipstick/Benedict's test
UROBILINOGEN		NORMAL	NORMAL	Dipstick
KETONE		NEGATIVE	NEGATIVE	Dipstick/Rothera's Nitroprusside test.
BILIRUBIN		NEGATIVE	NEGATIVE	Dipstick/Fouchet's test
BILE SALT		NEGATIVE	NEGATIVE	Hay's sulphur powder test
BILE PIGMENT		NEGATIVE	NEGATIVE	Fouchet test
NITRITE		NEGATIVE	NEGATIVE	Dipstick
LEUCOCYTE ESTERASE		NEGATIVE	NEGATIVE	
<u>MICROSCOPIC EXAMINATION</u>				
PUS CELLS	Urine	Occasional	0 - 5 /hpf	MICROSCOPIC EXAMINATION
RBC		NIL	0 - 5 /hpf	MICROSCOPIC EXAMINATION
EPITHELIAL CELLS		Occasional	0 - 5 /hpf	MICROSCOPIC EXAMINATION
CRYSTALS		NIL	NIL	MICROSCOPIC EXAMINATION
CASTS		NIL	NIL	MICROSCOPIC EXAMINATION
BACTERIA		ABSENT		MICROSCOPIC EXAMINATION
YEAST		ABSENT		
AMORPHOUS DEPOSITS		ABSENT		
MUCUS THREAD		ABSENT		
NOTE		Microscopic examination of urine is carried out on centrifuged urinary sediment.		

*** End Of Report ***





MEDICOVER HOSPITALS

DEPARTMENT OF LABORATORY

NAVI MUMBAI

Patient Name : Mr. SAIF ELAHI	Age / Gender : 26 Y(s)/Male
Bill No/ UMR No : NMBC68226/NMU0051949	Referred By : Dr. DMO
Received Dt : 29-Apr-24 09:54 am	Report Date : 29-Apr-24 02:43 pm

<u>Parameters</u>	<u>Specimen</u>	<u>Result</u>	<u>Biological Reference In Method</u>
-------------------	-----------------	---------------	---------------------------------------





DEPARTMENT OF LABORATORY

NAVI MUMBAI

Patient Name : Mr. SAIF ELAHI	Age / Gender : 26 Y(s)/Male
Bill No/ UMR No : NMBC68226/NMU0051949	Referred By : Dr. DMO
Received Dt : 29-Apr-24 09:54 am	Report Date : 29-Apr-24 11:16 am

FINAL REPORT

<u>Parameter</u>	<u>Specimen</u>	<u>Result Values</u>	<u>Biological Reference</u>	<u>Method</u>
COMPLETE BLOOD COUNT				
RBC				
R B C COUNT	Blood	5.36	4.5 - 5.5 $10^6/\mu\text{L}$	
HEMOGLOBIN		16.2	13.0 - 17.0 g/dl	
PCV/HCT		47.9	40 - 50 % 36 - 46 %	
MCV		89	83 - 101 fl 83 - 101 fl	
MCH		30.3	27 - 32 pg	
MCHC		33.9	31.5 - 34.5 g/dL	
RDW(cv)		12.2	11.6 - 14.0 %	
PLATELETS				
PLATELET COUNT	Blood	200	150 - 400 $10^3/\mu\text{L}$	
MPV		9.7	7.5 - 11.5 fl	
WBC				
TC (TOTAL LEUCOCYTE COUNT)	Blood	4.0	4.0 - 11.0 $10^3/\mu\text{l}$	
DIFFERENTIAL COUNT				
NEUTROPHILS	Blood	51	40 - 80 %	
LYMPHOCYTES		39	20 - 40 %	
MONOCYTES		08	02 - 10 %	
EOSINOPHILS		02	00 - 06 %	
BASOPHILS		00	00 - 01 %	
ESR	CITRATED BLOOD	05	0 - 10 mm/1st hour	WESTERGREN'S METHOD
BLOOD GROUPING AND RH				
BLOOD GROUP		" B "		TUBE AGGLUTINATION
RH TYPE		POSITIVE		

*** End Of Report ***





MEDICOVER
HOSPITALS

DEPARTMENT OF LABORATORY

NAVI MUMBAI

Patient Name : Mr. SAIF ELAHI	Age /Gender : 26 Y(s)/Male
Bill No/ UMR No : NMBC68226/NMU0051949	Referred By : Dr. DMO
Received Dt : 29-Apr-24 09:54 am	Report Date : 29-Apr-24 02:30 pm

Parameters

Specimen **Result**

TUBE AGGLUTINATI





DEPARTMENT OF LABORATORY

NAVI MUMBAI

Patient Name : Mr. SAIF ELAHI	Age /Gender : 26 Y(s)/Male
Bill No/ UMR No : NMBC68226/NMU0051949	Referred By : Dr. DMO
Received Dt : 29-Apr-24 09:54 am	Report Date : 29-Apr-24 12:26 pm

FINAL REPORT

<u>Parameters</u>	<u>Specimen</u>	<u>Result</u>	<u>Biological Reference Intervals</u>	<u>Method</u>
FBS (FASTING BLOOD GLUCOSE)				
FASTING BLOOD GLUCOSE		100	Normal Range : 70 - 99 mg/dL	Hexokinase
SERUM CREATININE				
CREATININE		0.73	0.8 - 1.3 mg/dl	Method : jaffe
BUN(BLOOD UREA NITROGEN)				
BUN (Blood Urea Nitrogen.)		12	7.0 - 21.0 mg/dL	Calculated
SGPT (ALT)		12	<= 41 U/L	Method : UV without P5P
SERUM BILIRUBIN TOTAL		1.8	0.2 - 1.3 mg/dL	Jendrassik Grof
DIRECT BILIRUBIN		0.4	<= 0.20 mg/dL	Method: Diazo Method
INDIRECT BILIRUBIN		1.4	<= 1.0 mg/dL	

*** End Of Report ***

Lab Incharge

Dr. Vishal Mehrotra
Dr. VISHAL MEHROTRA, MD Pathology
Head, Laboratory Services

Verified By : : 022315

Test results related only to the item tested.

No part of the report can be reproduced without written permission of the laboratory.



Patient ID:	NMU0051949	Patient Name:	SAIF ELAHI
Age:	26 Years	Sex:	M
Accession Number:	NMBC68226	Modality:	DX
Referring Physician:	DR.DMO	Study:	CHEST
Study Date:	29-Apr-2024		

X RAY CHEST PA VIEW

Both lungs are clear.

The frontal cardiac dimensions are normal.

The pleural spaces are clear.

Both hilar shadows are normal in position and density.


No diaphragmatic abnormality is seen.

The soft tissues and bony thorax are normal.

Impression:

No significant abnormality is seen.




DR JAMILA FANI
Consultant Radiologist
MBBS, MD

Date: 29-Apr-2024 15:01:22

26 Years

SAIF ELAHI
Male

4/29/2024 9:54:09 AM

Rate 82 . Sinus rhythm.....normal P axis, V-rate 50- 99
 . Atrial premature complex.....SV complex w/ short R-R interval
 PR 120 . Consider right atrial enlargement.....P >0.24mV limb lead
 QRSD 95 . ST elev, probable normal early repol pattern.....ST elevation, age<55
 QT 332 . Baseline wander in lead(s) V1
 QTc 388

--AXIS--

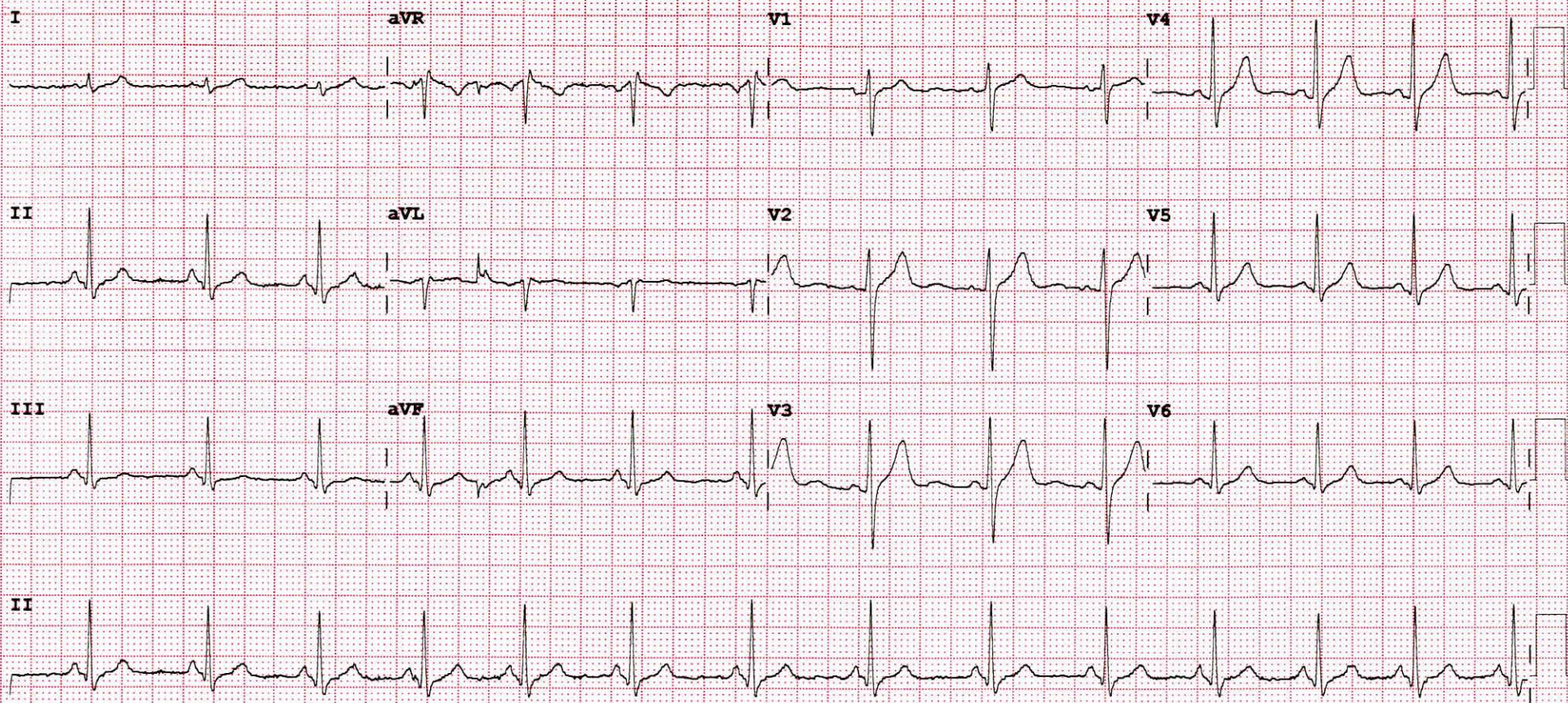
P 78
 QRS 84
 T 46

- OTHERWISE NORMAL ECG -

12 Lead; Standard Placement

Unconfirmed Diagnosis

ASell
 Dr. Anuj A. Sathe
 DM Cardiology, MD (Med), MBBS
 Consultant Interventional Cardiologist
 Reg No 2005/03/1862



Device: Speed: 25 mm/sec Limb: 10 mm/mV Chest: 10.0 mm/mV

F 60~ 0.50- 40 Hz W 100B CL P?



DEPARTMENT OF OPHTHALMOLOGY

MEDICOVER HOSPITALS

DATE: 29/04/24

PATIENT NAME: Mr Saif Elahi

AGE / SEX 28 / M NAVI MUMBAI

UMR NO : NMU00051949

	RE	LE
VA (DISTANCE)	6/6	6/6
VA(NEAR)	N6	N6
COLOUR VISION	Normal	Normal

		SPHERE	CYLINDER	AXIS	VA
MRx	O D	Plano	_____		6/6, N6
	O S	Plano	_____		6/6, N6

HISTORY :

- NO H/O spectacle use
- NO H/O systemic illness (DM, HTN, Thyroid).
- NO H/O Ocular trauma Allergies & surgeries.

OCULAR FINDINGS :

(BE) - Ant seg WNL
 (undilated) Disc (BE) - 0-3

ADVICE:

Refresh Tear e/d qid 1777 X 1 month

AT
 (DR. ANUSHREE VANWAL)

