

Gmail - Your Apollo order has been confirmed

4/27/24, 9:44 AM



Anand Rishiji Medical Centre <armmedicalreporting@gmail.com>

**Your Apollo order has been confirmed**

1 message

noreply@apolloclinics.info <noreply@apolloclinics.info>

To: armmedicalreporting@gmail.com  
Cc: rahul.rai@apolloclinic.com, pnitam.padyal@apolloclinic.com, syamsunder.m@apollohi.com, corporate@apolloclinic.com, deepak.gaddam@apolloclinic.com, rani.g@apolloclinic.com, apsara.bagchi@apollohi.com, dilip.b@apolloclinic.com

**Greetings from Apollo!!**

**Respected Sir/Madam,**

Please find corporate HC appointment details scheduled for **27-04-2024** at your **ANANDRISHIJI MEDICAL CENTRE LLP - Pune Center**.

**Points to note:-**

- Collect photocopy of employee ID proof if health check is through an employer.
- Collect photocopy of personal ID proof if health check is for insurance.
- Collect MER as per package details & that company's format (already shared).
- By 12 noon of appointment date share Work order number & visit status (Show/No show).
- Upload reports in Adbhutam portal as per specifications given earlier.

ARCOFEMI HEALTHCARE LIMITED	ARCOFEMI MEDIWHEEL PAN INDIA OP AGREEMENTFY2324	ARCOFEMI MEDIWHEEL PMC CREDIT - PAN INDIA H - PAN INDIA -	Urine Routine (CUE), GLUCOSE - SERUM / PLASMA (FASTING AND POST PRANDIAL, ALT (SGPT) - Serum / Plasma, Bilirubin, Total - Serum, Creatinine - Serum / Plasma, Blood Grouping And Typing (Abo And Rh), ECG, HEMOGRAM (CBC+ESR), X-Ray Chest PA, Fitness by General Physician, Ophthal by General Physician, BUN/CREATININE RATIO	Swapnil Digambarrao male Sell Raut	16-01-1987	N/A	swapnilraut.111@gmail.com	95958285852024-04-27	08:30-09:00
-----------------------------	---	---	---	------------------------------------	------------	-----	---------------------------	----------------------	-------------

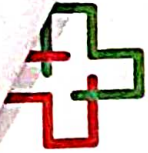Please login to AHCN Portal for more details.

AHCN Login Url: [Click on Link](#)

Regards,  
Team Clinic Operations  
Apollo Health and Lifestyle Ltd.,

*Handwritten notes:*  
FPP  
ECG -  
x-Ray  
consult -





**ANANDRISHIJI**  
MEDICAL CENTRE

PATIENT NAME: Mr. Swapnil Raut      DATE: 27/4/24  
AGE:      YRS      SEX-  
Male      37  
HEIGHT- 179 cms      WEIGHT- 94 KG      BP-130/80 mmhg

HEART RATE- 64      PAST HISTORY- Covid-19 2021, home quarantine, no complications, vaccinated.

PRESENT COMPLAINTS-  
- no complaints.


ophthm. - nearsightedness  
near vision - (N), clear.  
color vision - (N)  
- no squint  
- external app - (N)

F/H      S/E  
Healthy      CNS  
CVS } (N)  
R.S }  
PIA }

UNFIT

FIT WITH RECOMMANDATION

FIT



Doctors Stamp & Signature

*Dr. Pushpalakshmi Challa*  
MD Physician  
Reg. No. 60450  
Per. Reg. No. 1811070027



भारत सरकार  
GOVT. OF INDIA

आयकर विभाग  
INCOME TAX DEPARTMENT

SWAPNIL DIGAMBARRAO RAUT  
DIGAMBARRAO RAUT

16/01/1987  
Permanent Account Number  
BVZPR9133A

*[Signature]*  
Signature

15082014

*[Handwritten Signature]*



Swapnil Raut



First name: Swapnil raut / 37 yrs  
 Patient ID: D7866a7f-2dac-4b2a-8b8f-658913a1e115

27.04.2024 10:07:36  
 Standard 12-Lead

ANAND RISHIJ MEDICAL CENTER  
 PUNE

Age: Male  
 Gender: Male  
 Height: Undefined  
 Weight: Unknown  
 Ethnicity: Unknown  
 Pacemaker: Unknown


Room:   
 Medication:   
 Order ID:   
 Ord. prov.:   
 Ord. prot.:

HR: 66 bpm  
 RR: 113 ms  
 P axis: 45°  
 QRS axis: 58°  
 T axis: 23°

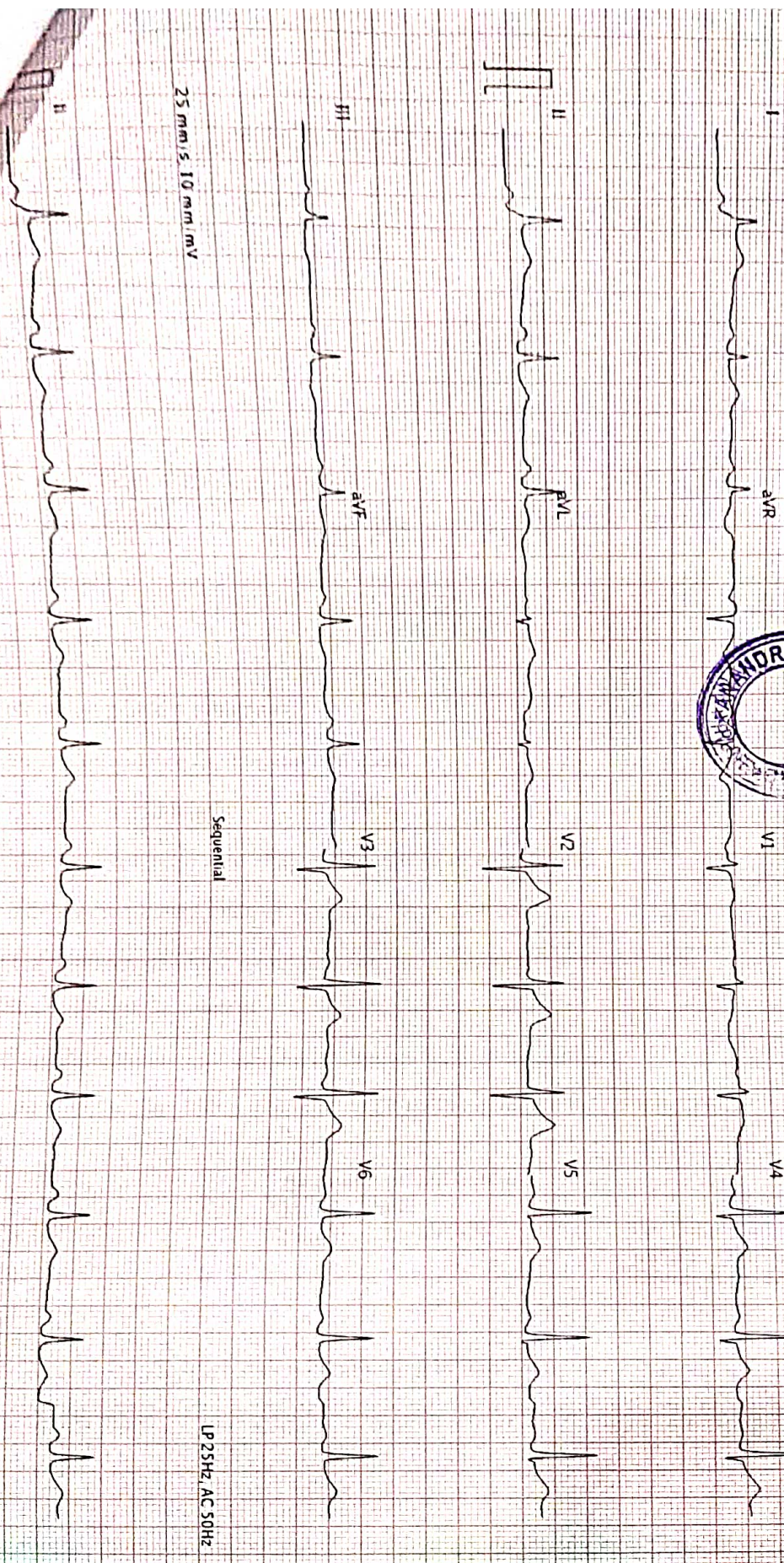
Sinus rhythm  
 Normal electrical axis  
 Normal ECG  
 Unconfirmed report

Normal rhythm  
 Normal ECG  
 Unconfirmed report

*(Signature)*



Dr. Puspakshmi Chaffa  
 MD Physician  
 Reg. No. 60450  
 Per. Reg. No. 1811070027



25 mm/s, 10 mm/mV

Sequential

LP25Hz, AC 50Hz

Printed on 27.04.2024 10:07:53

LP25Hz, AC 50Hz



**ANANDRISHIJI**  
MEDICAL CENTRE

Name: MR. SWAPNIL RAUT	Date:- 27/04/2024
Sex:- MALE      Age:-37 yrs	Ref. By:- APOLLO

**RADIOLOGICAL EXAMINATION**  
**X-RAY CHEST PA VIEW**

Both lung fields are clear.

Both costo-phrenic angles are clear.

No hilar abnormality.

The cardiac size and shape are within normal limits.

The aorta shows normal radiological features.


The domes of diaphragm are normal in position and outlines.

The trachea is central.

The skeleton under review presents normal features.

**IMPRESSION: NO SIGNIFICANT ABNORMALITY DETECTED.**

**Dr Prashant Shende**  
MBBS., DMRE  
Reg No. 2001/03/1430

  
**Dr. Prashant Shende**  
MBBS, DMRE  
Consultant Radiologist



**Consultants: - Department of Radiology and Imaging**

**NOTE: INVESTIGATIONS HAVE THEIR LIMITATIONS, SOLITARY INVESTIGATIONS NEVER CONFIRM THE FINAL DIAGNOSIS OF DISEASE IT ONLY HELPS IN DIAGNOSING THE DISEASE IN CORRELATION TO THE CLINICAL FINDINGS & OTHER INVESTIGATIONS.**

4th floor Vardhaman, Shankar Seth Road, Mahatma Phule Peth, Pune-411042, Maharashtra

armmedicalreporting@gmail.com | www.armedicalcentre.in