



Name	BHARAD SAPNA RAMESHBHAI	Age/Gender	34Yrs/Female
Reg No.	807/24	Receipt No	15905
Referred By	Bank of Baroda (BOB) - MEDI WHEEL()	Mode of Payment	CREDIT
Collection Type	CENTER	Collection DateTime	27-Jan-2024 08:36 AM

PAP SMEAR - 27012462 Released at 31-Jan-2024 11:35 AM

Parameter	Result	Biological Ref.Range	Method
-Pap Smear Report	<p>PAP SMEAR: Specimen Two unstained slides received for pap smear evaluation</p> <p>Gross description Received two unstained slides for pap smear examination.Papanicolou stain done.</p> <p>Microscopic Description Smears are satisfactory for cellularity. Endocervical cells/ Transformation zone is absent. There is presence of many sheets& singly scattered superficial and intermediate cells seen. No parasites/fungi. No evidence of intraepithelial lesion or malignancy.</p> <p>Diagnosis PAP smear- Negative for intraepithelial lesion malignancy – NILM. (The Bethesda system for the reporting of cervical cytology-2014). Note-The pap test is a screening procedure to aid in the detection of cervical cancer and its precursors</p>		

Revival Diagnostics

401-Aqua Corridor,
Beside Star Bazar, Adajan,
Surat-395009. Mo. 9825947717

Dr. Shivangi Gandhi
M.B.B.S, M.D (Pathology)

Laboratory Test Result are Subject to technical limitation and should be clinically correlate for final diagnosis

4th Floor, Aqua Corridor, Hazira Road, Adajan Pal, Surat-395009.

0261 2747788, 9825947712 revivaldiagnostics.surat@gmail.com www.revivaldiagnostics.com

This medical report is not intended for medico-legal purposes.





HEALTH CHECK-UP SUMMARY

Name: Sapna Bhasad

Date: 27/01/2024

Email ID:

Sex: F Age: 34 Years Contact No: 8485 992010

Remarks:

i> BMI

Height (in Cm): 156	Weight (in Kg): 53	BMI: 21.8
Hip (in Cm): 91	Waist (in Cm): 77	Hip to Waist Ratio: 1.18

Under-weight	-
Normal	✓
Over-weight	-

ii> Blood Pressure & Pulse

110/70 mmHg
82/min Regular.

If high or low, whether the person is on medication: YES / (NO)

iii> Blood Tests & Lung Function Remarks

RS }
CRS }
CRS } (P)

If abnormal, whether the person is on medication: YES / (NO)

iv> Eye Test Remarks

Eye Sight: (R) 6/6 (L) 6/6
Color Vision: (P)

v> Heart Disease

Whether any specific heart ailment detected (ECG findings):
SAD

vi> Any other problems needing attention / Overall Assessment:

NO

C.K. Patel
Dr. Chirag Patel
M.B.B.S. G-49432

Revival Diagnostic
401, Aqua Corridor,
B/s. Star Bazar, Surat-395009
Mo. 91062-28601

(P) ~~for~~ ~~hasad~~..

Laboratory Test Result are Subject to technical limitation and should be clinically correlate for final diagnosis

4th Floor, Aqua Corridor, Hazira Road, Adajan Pal, Surat-395009.

0261 2747788, 9825947712 revivaldiagnostics.surat@gmail.com www.revivaldiagnostics.com

This medical report is not intended for medico-legal purposes.



Name	BHARAD SAPNA RAMESHBHAI	Age/Gender	34Yrs/Female
Reg No.	807/24	Receipt No	15905
Referred By	Bank of Baroda (BOB) - MEDI WHEEL()	Mode of Payment	CREDIT
Collection Type	CENTER	Collection DateTime	27-Jan-2024 08:36 AM

BLOOD GROUP - 27012460 Released at 27-Jan-2024 12:25 PM

Parameter	Result	Biological Ref.Range	Method
-Blood Group	"O"		
-Rh Factor	NEGATIVE		

CBC - 27012460 Released at 27-Jan-2024 11:33 AM

Parameter	Result	Biological Ref.Range	Method
-Haemoglobin	11.7 gm/dL	L (12 - 16 gm/dL)	Auto
-RBC Count	4.71 mill/cumm	(4.2 - 5.4 mill/cumm)	Auto
-Total WBC Count	5300 /cumm	(4000 - 10000 /cumm)	Auto
-Platelet Count	3.02 lakh/cumm	(1.5 - 4.5 lakh/cumm)	Auto

Blood Indices

-HCT	35.9 %	L (40 - 55 %)	Auto
-MCV	76.2 fl	L (80 - 92 fl)	Auto
-MCH	24.9 pg	L (27 - 31 pg)	Auto
-MCHC	32.6 gm/dL	(32 - 36 gm/dL)	Auto
-RDW	12.6 %	(11 - 15 %)	Auto

Diff WBC Count

-Polymorphs	50 %	(40 - 80 %)	Microscopically
-Lymphocytes	45 %	H (20 - 40 %)	Microscopically
-Eosinophils	03 %	(1 - 6 %)	Microscopically
-Monocytes	02 %	(2 - 7 %)	Microscopically
-Basophils	00 %	(0 - 1 %)	Microscopically
-PLATELET ON SMEAR	Adequate		Microscopically
-MALARIAL PARASITES	Malarial Parasites Not Detected		Microscopically

[Test performed on Fully Automated Hematology Analyzer ERBA H-360]

Revival Diagnostics
401-Aqua Corridor,
Beside Star Bazar, Adajan,
Surat-395009. Mo. 9825947717

Sg

Dr. Shivangi Gandhi
M.B.B.S, M.D (Pathology)

Laboratory Test Result are Subject to technical limitation and should be clinically correlate for final diagnosis

📍 4th Floor, Aqua Corridor, Hazira Road, Adajan Pal, Surat-395009.
☎ 0261 2747788, 9825947712 📧 revivaldiagnostics.surat@gmail.com 🌐 www.revivaldiagnostics.com

This medical report is not intended for medico-legal purposes.

REVIVAL DIAGNOSTICS



Name	BHARAD SAPNA RAMESHBHAI	Age/Gender	34Yrs/Female
Reg No.	807/24	Receipt No	15905
Referred By	Bank of Baroda (BOB) - MEDI WHEEL()	Mode of Payment	CREDIT
Collection Type	CENTER	Collection DateTime	27-Jan-2024 08:36 AM

ESR - 27012460 Released at 27-Jan-2024 11:56 AM

Parameter	Result	Biological Ref.Range	Method
-E.S.R	06 mm/hr	(3 - 15 mm/hr)	



Revival Diagnostics
401-Aqua Corridor,
Beside Star Bazar, Adajan,
Surat-395009. Mo. 9825947712

Dr. Shivangi Gandhi
M.B.B.S, M.D (Pathology)

Laboratory Test Result are Subject to technical limitation and should be clinically correlate for final diagnosis



Name	BHARAD SAPNA RAMESHBHAI	Age/Gender	34Yrs/Female
Reg No.	807/24	Receipt No	15905
Referred By	Bank of Baroda (BOB) - MEDI WHEEL()	Mode of Payment	CREDIT
Collection Type	CENTER	Collection DateTime	27-Jan-2024 08:36 AM

FBS & PPBS - 27012461 Released at 27-Jan-2024 12:40 PM

Parameter	Result	Biological Ref.Range	Method
-Fasting Blood Sugar (FBS)	85 mg/dL	70-100 mg/dl Impaired Tolerance: 100-125 Diabetes Mellitus: \geq 126 (American diabetes association guidelines 2022)	
-Fasting Urine Sugar	Absent		
-Fasting Urine Acetone	Absent		
-PPBS	110 mg/dL	(90 - 140 mg/dL)	
-PP2BS URINE SUGAR	Absent		
-PP2BS URINE ACETONE	Absent		

HBA1C - 27012460 Released at 27-Jan-2024 12:40 PM

Parameter	Result	Biological Ref.Range	Method
-HBA1C	5.2 %	HbA1C Degree of Glucose Control <5.6 % Non Diabetics 5.7 - 6.4 % Prediabetics > =6.5 % Diabetics (REF:Wallace, 11th Edition) REMARKS: 6 - 7 % Excellent Control 7 - 8 % Good Control 8 - 10 % Unsatisfactory Control >10 % Poor Control	Immuno-Turbidometry method
-Method[]	High Performance Liquid Chromatography (HPLC)		

Revival Diagnostics
401-Aqua Corridor,
Beside Star Bazar, Adajan,
Surat-395009. Mo. 9825947717

Dr. Shivangi Gandhi
M.B.B.S, M.D (Pathology)

Laboratory Test Result are Subject to technical limitation and should be clinically correlate for final diagnosis



Name	BHARAD SAPNA RAMESHBHAI	Age/Gender	34Yrs/Female
Reg No.	807/24	Receipt No	15905
Referred By	Bank of Baroda (BOB) - MEDI WHEEL()	Mode of Payment	CREDIT
Collection Type	CENTER	Collection DateTime	27-Jan-2024 08:36 AM

LIVER FUNCTION TEST (LFT) - 27012463 Released at 27-Jan-2024 12:40 PM

Parameter	Result	Biological Ref.Range	Method
-Serum Total Bilirubin	0.2 mg/dL	(0 - 1.3 mg/dL)	Diazo
-Serum Direct Bilirubin	0.1 mg/dL	(0 - 0.4 mg/dL)	Diazo
-Serum InDirect Bilirubin	0.1 mg/dL	(0.1 - 1.3 mg/dL)	Calculated
-Total Protein (TP)	6.4 gm/dL	(6.4 - 8.3 gm/dL)	Biuret
-Albumin (ALB)	3.7 gm/dL	(3.5 - 5.2 gm/dL)	BCG
-Globulin	2.7 gm/dL	(2.3 - 3.6 gm/dL)	Calculated
-A/G Ratio	1.37 gm/dL	(1 - 2.3 gm/dL)	Calculated
-SGPT(ALT)	24 U/L	(5 - 45 U/L)	IFCC, Kinetic without Pyridoxal Phosphate
-SGOT (AST)	19 U/L	(0 - 35 U/L)	IFCC, Without Pyridoxal Phosphate
-Alkaline Phosph.	78 U/L	(42 - 128 U/L)	ALP-AMP
-GGT	22 U/L	(5 - 50 U/L)	Glupa-C

[Test performed on Fully Automated Biochemistry Analyzer ERBA EM200]



Name	BHARAD SAPNA RAMESHBHAI	Age/Gender	34Yrs/Female
Reg No.	807/24	Receipt No	15905
Referred By	Bank of Baroda (BOB) - MEDI WHEEL()	Mode of Payment	CREDIT
Collection Type	CENTER	Collection DateTime	27-Jan-2024 08:36 AM

Creatinine - 27012463 Released at 27-Jan-2024 12:40 PM

Parameter	Result	Biological Ref.Range	Method
-Creatinine	0.6 mg/dL	(0.6 - 1.14 mg/dL)	ENZYMATIC

BUN - 27012463 Released at 27-Jan-2024 11:37 AM

Parameter	Result	Biological Ref.Range	Method
-Blood Urea Nitrogen (BUN)	8 mg/dL	(6 - 20 mg/dL)	Calculated

Uric Acid - 27012459 Released at 27-Jan-2024 12:40 PM

Parameter	Result	Biological Ref.Range	Method
-Uric Acid	3.7 mg/dL	(3.5 - 7.2 mg/dL)	Uricase-POD

REVIVAL
DIAGNOSTICS

Revival Diagnostics

401-Aqua Corridor,
Beside Star Bazar, Adajan,
Surat-395009, Mo: 9825947712
Dr. Shivangi Gandhi
M.B.B.S, M.D (Pathology)

Laboratory Test Result are Subject to technical limitation and should be clinically correlate for final diagnosis

4th Floor, Aqua Corridor, Hazira Road, Adajan Pal, Surat-395009.

0261 2747788, 9825947712 revivaldiagnostics.surat@gmail.com www.revivaldiagnostics.com

This medical report is not intended for medico-legal purposes.



Name	BHARAD SAPNA RAMESHBHAI	Age/Gender	34Yrs/Female
Reg No.	807/24	Receipt No	15905
Referred By	Bank of Baroda (BOB) - MEDI WHEEL()	Mode of Payment	CREDIT
Collection Type	CENTER	Collection DateTime	27-Jan-2024 08:36 AM

Lipid Profile - 27012463 Released at 27-Jan-2024 12:41 PM

Parameter	Result	Biological Ref.Range	Method
-Serum Cholesterol	218 mg/dL	Desirable < 200 mg/dl Borderline High : 200-239 mg/dl High : > 240 mg/dl	CHOD-PAP
-Serum Triglyceride	106 mg/dL	Normal < 150 mg/dl Borderline High : 150 - 199 mg/dl High : 200 - 499 mg/dl Very High : 500 mg/dl	GPO-POD Method
-Serum HDLD(Direct)	49 mg/dL	Normal > 55 mg/dl Borderline : 35-55 mg/dl Undesirable: < 35 mg/dl	PVS-PEGME Precipitation with CHOD-POD
-Serum VLDL	21 mg/dL	(5 - 30 mg/dL)	Calculated
-Serum LDL(Direct)	148 mg/dL	Optimal:< 100 mg/dl Above Optimal : 100- 129 mg/dl Borderline High : 130-159 mg/dl High : > 160-189mg/dl Very High : >190 mg/dl	Calculated
-Chol/HDL	4.45	Low risk: <3.8 Medium Risk: 3.8 to 5.9 High Risk: > 6	Calculated
-LDL/Chol	1.47	Low risk: <3.55 Medium Risk: 3.55 to 4.0 High Risk: > 6	Calculated

[Test performed on Fully Automated Biochemistry Analyzer ERBA EM200]

Revival Diagnostics
401-Aqua Corridor,
Beside Star Bazar, Adajan,
Surat-395009. Mo. 9825947717

Dr. Shivangi Gandhi
M.B.B.S, M.D (Pathology)

Laboratory Test Result are Subject to technical limitation and should be clinically correlate for final diagnosis

4th Floor, Aqua Corridor, Hazira Road, Adajan Pal, Surat-395009.

0261 2747788, 9825947712 revivaldiagnostics.surat@gmail.com www.revivaldiagnostics.com

This medical report is not intended for medico-legal purposes.



Name	BHARAD SAPNA RAMESHBHAI	Age/Gender	34Yrs/Female
Reg No.	807/24	Receipt No	15905
Referred By	Bank of Baroda (BOB) - MEDI WHEEL()	Mode of Payment	CREDIT
Collection Type	CENTER	Collection DateTime	27-Jan-2024 08:36 AM

Urine Routine & Micro Examination - 2701246 Released at 27-Jan-2024 12:39 PM

Parameter	Result	Biological Ref.Range	Method
<u>Physical Examination</u>			
-Quantity	15		Manual
-Colour	Pale Yellow	Pale Yellow	Manual
-Appearance	Clear	Clear	Manual
-Reaction (pH)	Acidic		Dipstick
-Specific Gravity	1.030		Dipstick
<u>Chemical Examination</u>			
-Proteins.	Absent		Dipstick
-Sugar	Absent		Dipstick
-Acetone.	Absent		Dipstick
-Bile Salts	Absent	Absent	Dipstick
-Bile Pigments	Absent	Absent	Dipstick
-Occult Blood Test (OBT).	Negative		Dipstick
<u>Microscopic Examination</u>			
-Pus Cells	2-3		Microscopically
-Red Blood Cells	Absent		Microscopically
-Epithelial Cells	2-3		Microscopically
-Bacteria.	Absent		Microscopically
-Crystals	Absent	Absent	Microscopically
-Others	NIL	Absent	Microscopic Examination

Revival Diagnostics
401-Aqua Corridor,
Beside Star Bazar, Adajan,
Surat-395009. Mo. 9825947712

Dr. Shivangi Gandhi
M.B.B.S, M.D (Pathology)

Laboratory Test Result are Subject to technical limitation and should be clinically correlate for final diagnosis

📍 4th Floor, Aqua Corridor, Hazira Road, Adajan Pal, Surat-395009.

☎ 0261 2747788, 9825947712 ✉ revivaldiagnostics.surat@gmail.com 🌐 www.revivaldiagnostics.com

This medical report is not intended for medico-legal purposes.



Name	BHARAD SAPNA RAMESHBHAI	Age/Gender	34Yrs/Female
Reg No.	807/24	Receipt No	15905
Referred By	Bank of Baroda (BOB) - MEDI WHEEL()	Mode of Payment	CREDIT
Collection Type	CENTER	Collection DateTime	27-Jan-2024 08:36 AM

Total T3 T4 TSH - 27012463 Released at 27-Jan-2024 12:55 PM

Parameter	Result	Biological Ref.Range	Method
-Total T3	1.41 ng/ml	(0.87 - 1.78 ng/ml)	Fluorescence Enzyme Immunoassay
-Total T4	9.91 ug/dl	(4.6 - 11 ug/dl)	Fluorescence Enzyme Immunoassay
-TSH	1.33 uIU/ml	0.50 - 5.50 uIU/ml 5.5 to 15 ul U/ml - Suggested	Fluorescence Enzyme Immunoassay

Clinical co-relation or Repeat test with new sample as physiological factors can give falsely high TSH
Above 15uIU/ml Hypothyroid
PREGNANT WOMEN normal ranges for TSH:
1st Trimester : 0.0878 - 2.8293 uIU/ml
2nd Trimester : 0.1998 - 2.7915 uIU/ml
3rd Trimester : 0.307 - 2.9028 uIU/ml
Ref: Tietz Fundamentals of Clinical Chemistry

[Test performed on Fully Automated Immunology Analyzer Maglumi-600]

Revival Diagnostics
401-Aqua Corridor,
Beside Star Bazar, Adajan,
Surat-395009. Mo. 9825947717

Dr. Shivangi Gandhi
M.B.B.S, M.D (Pathology)

Laboratory Test Result are Subject to technical limitation and should be clinically correlate for final diagnosis

4th Floor, Aqua Corridor, Hazira Road, Adajan Pal, Surat-395009.
0261 2747788, 9825947712 revivaldiagnostics.surat@gmail.com www.revivaldiagnostics.com

This medical report is not intended for medico-legal purposes.



Department Of Ophthalmology

Demographic Information:

EMP ID :		SR.NO :	
Name :	Safna Bharwad	Date :	27/11/24
Age :	34		
Sex :	Female		
Department :			

EYE TEST

1. VISION :-

RIGHT EYE :- 6/6

LEFT EYE :- 6/6

2. COLOR VISION :-

RIGHT EYE :- 3

LEFT EYE :- 3

3. NIGHT VISION :-

RIGHT EYE :- 3

LEFT EYE :- 3


REMARKS :-

No

Revival Diagnostic

401, Aqua Corridor,
B/s. Star Bldg, Surat-395009
Mo. 91062-28601

help@healthledger.co.in
+91 916 907 5555



**HEALTHLEDGER
DIAGNOSTICS**

Dental Checkup

Reg. No. : _____

Date: 27/01/24

Patient Name Mr./Mrs Sopna Bhard

Age 34 Sex F Address Surat

Mobile No. 8485992244

Past Medical History

1) Smoking 2) Alcohol 3) Hepatitis B & C 4) Diabetics 6) Tobacco 5) Allergy 6) Asthma

7) Any Other: NO

PDH:-

O/E :-

Investigation :-

Treatment:- NO

Doctor's Sign and Stamp

C.K. Patel
Dr. Chirag Patel
M.B.B.S. G-49432

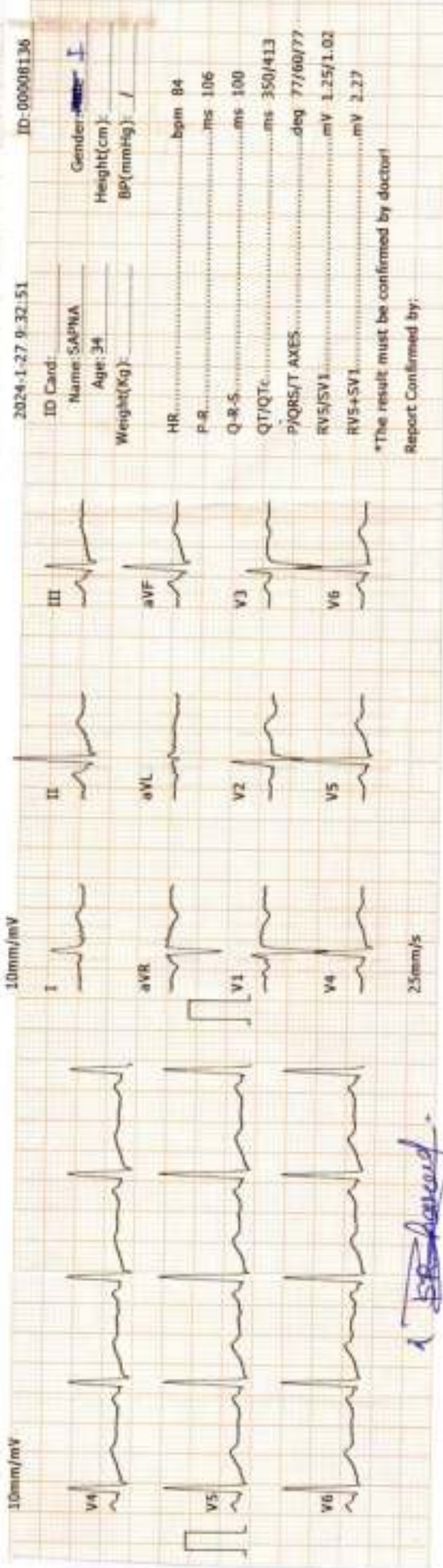

Consent Form:

I Sopna Bhard

.....have given true & total information to the dentist regarding past & present illness as well as ongoing medical treatment. I have been fully informed regarding treatment for present illness. Along with benefit & possible risk from medicines / Surgery / Anesthetic drugs to be used by the dentist in my own understanding language. I hereby willingly permit the dentist to undertake the treatment or surgical intervention.

Patient Signature: Sopna Bhard

Revival Diagnostic
401, Aqua Corridor,
B/s. Star Bazar, Surat-395009
Mo. 91062-28601



2024-1-27 9:32:51 ID: 00000136
 ID Card: _____
 Name: SAPNA _____
 Age: 34 _____
 Weight(Kg): _____
 Gender: ~~Male~~ F
 Height(cm): _____
 BP(mmHg): _____
 HR: _____ bpm 84
 P-R: _____ ms 106
 Q-R-S: _____ ms 100
 QT/QTc: _____ ms 350/413
 P/QRS/T AXES: _____ deg 77/60/77
 RV5/SV1: _____ mV 1.25/1.02
 RV5+SV1: _____ mV 2.27
 *The result must be confirmed by doctor!
 Report Confirmed by:

1 *[Signature]*

Revival Diagnostics
 401-Aqua Corridor,
 Beside Star Bazar, Adajan,
 Surat-395009. Mo. 9825947712

DR. ADAMS BORA
 PHYSICIAN
 GENERAL CARDIOLOGIST
 G-3, 906

REVIVAL DIAGNOSTICS



Name	BHARAD SAPNA RAMESHBHAI	Age/Gender	34Yrs/Female
Reg No.	807/24	Receipt No	15905
Referred By	Bank of Baroda (BOB) - MEDICAL WHEEL()	Mode of Payment	CREDIT
Collection Type	CENTER	Collection DateTime	27-Jan-2024 08:25 AM

Ecg

1. The rhythm is sinus.
2. Heart rate is 84 beats per minute.
3. Normal P,QRS,T wave axis.
4. Normal PR,QRS,Q.T. Duration.
5. No pathological q wave or ST-T changes seen.
6. No evidence of chamber hypertrophy or enlargement seen.

IMPRESSION : ECG WITHIN NORMAL LIMITS

Revival Diagnostics

401-Aqua Corridor,
Beside Star Bazar, Adajan,
Surat-395009. Tel: 9825947712

Signature

DR. ADITYA S. BORA
MBBS, DNB, PGDCC
PHYSICIAN & CLINICAL CARDIOLOGIST
G-54906

Laboratory Test Result are Subject to technical limitation and should be clinically correlate for final diagnosis

📍 4th Floor, Aqua Corridor, Hazira Road, Adajan Pal, Surat-395009.

☎ 0261 2747788, 9825947712 ✉ revivaldiagnostics.surat@gmail.com 🌐 www.revivaldiagnostics.com

This medical report is not intended for medico-legal purposes.



Name	BHARAD SAPNA RAMESHBHAI	Age/Gender	34Yrs/Female
Reg No.	807/24	Receipt No	15905
Referred By	Bank of Baroda (BOB) - MEDICAL WHEEL()	Mode of Payment	CREDIT
Collection Type	CENTER	Collection DateTime	27-Jan-2024 08:25 AM

2D ECHO
2D ECHOCARDIOGRAPHY & COLOR DOPPLER REPORT

INDICATION: Preventive Health check up

- **CARDIAC CHAMBERS :** Left Ventricle : Normal size , Left Atrium: Normal size.
- NO e/o thrombus in LA/LV
- Right Atrium: Normal size. Right Ventricle: Normal Size,
- Normal Right Ventricular function. (TAPSE=20mm)
- Normal Left Ventricular systolic function. LVEF = 60%
- No regional wall abnormality. No thinning / scarring / dyskinesia of LV wall
- No Left Ventricular Hypertrophy. (IVSd= 10 mm),
- LV Compliance:
- NO Left Ventricular Diastolic Dysfunction [LVDD].

VALVES :

- Structurally Normal Mitral valve/ Aortic valve/Tricuspid valve/ Pulmonary valve .
- No significant Valvular Stenosis
- Doppler findings: AV max = 1.23 m/s, PV max = 0.91 m/s.
- Trivial MR, Trivial Tricuspid regurgitation.
- No Pulmonary Arterial Hypertension. PASP by TRjet vel.method = 24 mmHg.
- SEPTAE: IAS / IVS Appear Intact.
- IVC : Normal in dimension and shows good inspiratory 13mm collapse.
- OTHERS: No e/o Pericardial effusion / vegetation.

IMPRESSION:

NORMAL LV SYSTOLIC FUNCTION, LVEF= 60 %, NO RWMA,
NO LVH , NO LVDD , NO PAH.

Revival Diagnostics

401-Aqua Corridor,

Star Bazar, Adajan,

Surat, Guj. No. 9825947712

Signature

DR. ADITYA S. BORA

MBBS, DNB, PGDCC

PHYSICIAN & CLINICAL CARDIOLOGIST

G-54906

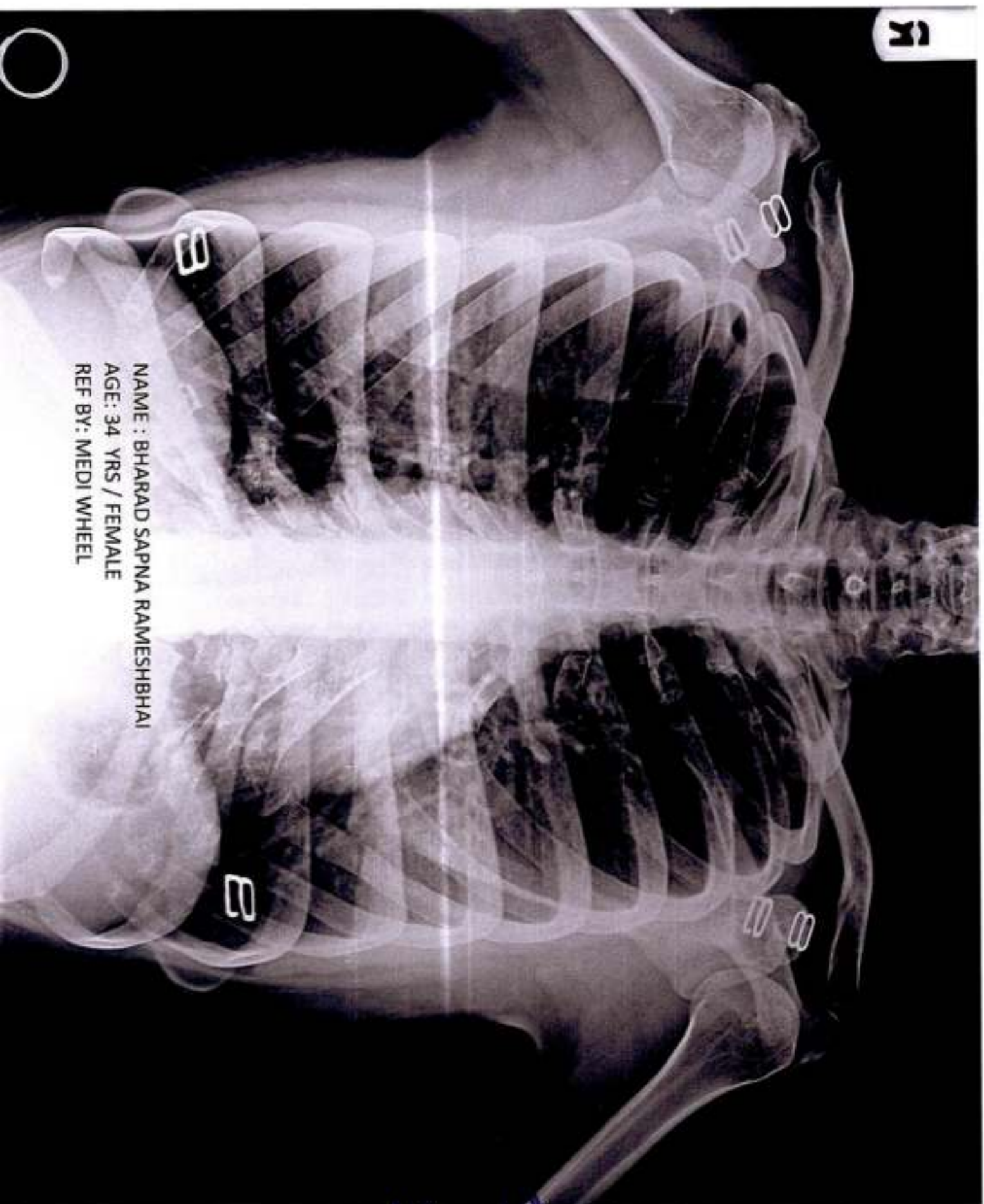
Laboratory Test Result are Subject to technical limitation and should be clinically correlate for final diagnosis

4th Floor, Aqua Corridor, Hazira Road, Adajan Pal, Surat-395009.

☎ 0261 2747788, 9825947712 ✉ revivaldiagnostics.surat@gmail.com 🌐 www.revivaldiagnostics.com

This medical report is not intended for medico-legal purposes.

R



NAME : BHARAD SAPNA RAMESHBHAI
AGE : 34 YRS / FEMALE
REF BY : MEDI WHEEL





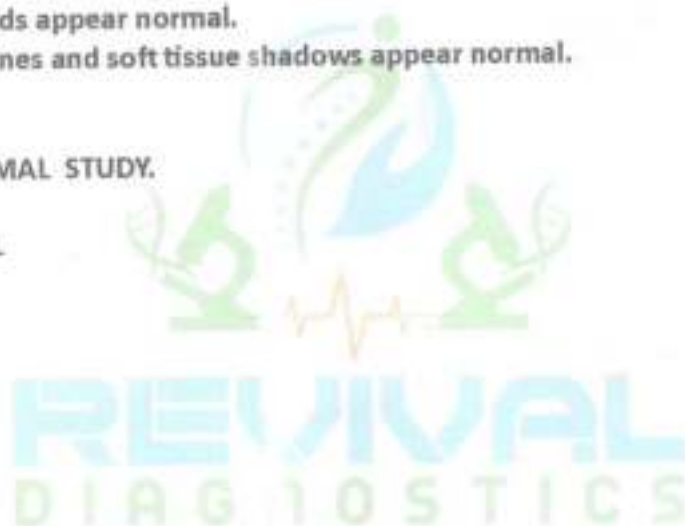Name	BHARAD SAPNA RAMESHBHAI	Age/Gender	34Yrs/Female
Reg No.	807/24	Receipt No	15905
Referred By	Bank of Baroda (BOB) - MEDI WHEEL()	Mode of Payment	CREDIT
Collection Type	CENTER	Collection DateTime	27-Jan-2024 08:25 AM

CHEST RADIOGRAPH (PA VIEW)

- Hilar shadows are within normal limits.
- Pulmonary vasculature appears normal.
- Cardiac appears normal in size.
- Both domes of the diaphragm are smooth.
- Both costophrenic recesses are clear.
- Both lung fields appear normal.
- Visualized bones and soft tissue shadows appear normal.

IMPRESSION: NORMAL STUDY.

DR. CHIRAG K PATEL
RADIOLOGIST



Dr. Chirag K. Patel
MBBS-DMPD
REG. No. 15905
Signature
Revival Diagnostics
4th Floor, Aqua Corridor,
Nr. Star Bazar, Hazira Main Road,
Adajan, Surat-395009.
Mo. 97266 726683

Laboratory Test Result are Subject to technical limitation and should be clinically correlate for final diagnosis

4th Floor, Aqua Corridor, Hazira Road, Adajan Pal, Surat-395009.

☎ 0261 2747788, 9825947712 ✉ revivaldiagnostics.surat@gmail.com 🌐 www.revivaldiagnostics.com

This medical report is not intended for medico-legal purposes.



Name	BHARAD SAPNA RAMESHBHAI	Age/Gender	34Yrs/Female
Reg No.	807/24	Receipt No	15905
Referred By	Bank of Baroda (BOB) - MEDI WHEEL()	Mode of Payment	CREDIT
Collection Type	CENTER	Collection DateTime	27-Jan-2024 08:25 AM

USG OF ABDOMEN & PELVIS

LIVER:

Liver is normal in size, shape and echotexture.
No evidence of focal SOL or dilatation of IHBR seen.
Portahepatis appear normal.

GALLBLADDER:

Gallbladder is distended and appears normal.
No e/o calculus, mass lesion or changes of cholecystitis seen.

PANCREAS:

Pancreas appears normal in size, shape and echotexture.
No e/o focal lesion, mass or changes of pancreatitis seen.

SPLEEN:

Spleen appears normal in size, shape and echotexture.

PARAAORTIC REGION:

Aorta grossly appears normal. No e/o paraaortic lymphnodes seen.

KIDNEYS:

Both kidneys appear normal in size, shape, position and echotexture.
Cortex and collecting system of both kidneys appear normal.
No evidence of calculus or obstructive uropathy on either side.

URINARY BLADDER:

Bladder is distended and appears normal.
No calculus, mass lesion or changes of cystitis is seen.

UTERUS:

anteverted, Normal in size, shape and echotexture with empty central uterine cavity.
Cervix appears normal.
No e/o focal SOL. Endometrial thickness is normal.

OVARIES:

Both adnexal region appear normal.
No e/o adnexal mass lesion seen on either side.
No evidence of free fluid seen in pelvis.

COMMENTS: NORMAL USG ABDOMEN AND PELVIS.

Dr. Chirag K. Patel
MBBS-DMPD

Reg. No. G-23509

Revival Diagnostic

4th Floor, Aqua Corridor,
Nr. Star Bazar, Hazira Main Road,
Adajan, Surat-395009.

Laboratory Test Result are Subject to technical limitation and should be clinically correlated for final diagnosis.

4th Floor, Aqua Corridor, Hazira Road, Adajan Pal, Surat-395009.

0261 2747788, 9825947712 revivaldiagnostics.surat@gmail.com www.revivaldiagnostics.com

This medical report is not intended for medico-legal purposes.