



# YASHFEEN CARDIAC HOSPITAL™

At. & Po. Viraval, Navsari. 396 445. Phone (H) (02637) 235725

Website : www.yashfeenhospital.in E-mail : info@yashfeenhospital.in

(For Laboratory Reports Only)



Patient Name : DHARMESH MANUBHAI PATEL

Age : 42 Years Sex : M

Ref By Dr. : -

Area : Navsari Date : 08/06/2024

Sample Time : 08/06/2024 08:48 No : 11

Time : 12:55PM

## HAEMOGRAM

Test	Findings	UOM	Normal Range
HAEMOGLOBIN	15.4	gm/dl	M-13.5-17.0 gm/dl F-11.5-15.5 gm/dl
<b>HAEMOGRAM</b>			
RED BLOOD CELL	<b>5.89</b>	10 <sup>6</sup> /μL	3.76-5.70
TOTAL LEUCOCYTE COUNT	6000	cells/cumm	4,000-11,000cells/cumm
<b>Differential Count</b>			
Neutrophil	45	%	40-75 %
Lymphocytes	<b>48</b>	%	20-40 %
Eosinophil	2	%	01-06 %
Monocytes	5	%	02-10 %
Basophils	0	%	00-00 %
PLATELET COUNT	251000	lacs/cumm	1.5-5.5 Lacs/cumm
<b>RBC INDICES</b>			
P.C.V.	46.0	%	Male-40-56%, Female-37-47%
M.C.V.	78.1	cu/microns	76.0-94.0
M.C.H.	<b>26.2</b>	pg	27.0-30.0
M.C.H.C.	33.6	-	30.0-35.0
BLOOD GROUP	" O "	-	-
RH FACTOR	POSITIVE	-	-
E.S.R.(1 hour)	8	mm/hr.	Male-5-10 mm/hr, Female-5-20 mm/hr

Remarks

Dr. PIYUSH B. CHAUDHARI

M.D. Medicine

Designed By : Sarita Infotech Pvt. Ltd., Navsari

Yashfeen Cardiac Hospital

Thanks for Reference

Signature  
Technician



# YASHFEEN CARDIAC HOSPITAL™

At. & Po. Viraval, Navsari. 396 445. Phone (H) (02637) 235725

Website : [www.yashfeenhospital.in](http://www.yashfeenhospital.in) E-mail : [info@yashfeenhospital.in](mailto:info@yashfeenhospital.in)

(For Laboratory Reports Only)



Patient Name : DHARMESH MANUBHAI PATEL

Age : 42 Years Sex : M

Ref By Dr. : -

Area : Navsari Date : 08/06/2024

Sample Time : 08/06/2024 08:48 No : 11

Time : 12:55PM

## HAEMOGLOBIN A1 C ESTIMATION

Test	Findings	UOM	Normal Range
Hb A1C	5.4	%	>8 :Action Suggested, 7-8 :Good Control, <7 :Goal, 6-7 :Near Normal Glycemia, <6 :Non-diabetic Level
<b>Technique</b>			
METHOD - HPLC			
Mean Blood Glucose	109.2	mg/dL	



*P. Chaudhari*  
Dr. PIYUSH B. CHAUDHARI  
M.D. Medicine

Reg.No. G - 21518

Remarks

Designed By : Sarita Infotech Pvt. Ltd., Navsari

Yashfeen Cardiac Hospital

*[Signature]*  
Signature  
Technician

*Thanks for Reference*



# YASHFEEN CARDIAC HOSPITAL™

At. & Po. Viraval, Navsari. 396 445. Phone (H) (02637) 235725

Website : www.yashfeenhospital.in E-mail : info@yashfeenhospital.in

(For Laboratory Reports Only)



Patient Name : DHARMESH MANUBHAI PATEL

Age : 42 Years Sex : M

Ref By Dr. : -

Area : Navsari Date : 08/06/2024

Sample Time : 08/06/2024 08:48 No : 11

Time : 12:55PM

## LIPID PROFILE TEST REPORT

Test	Findings	UOM	Normal Range
S. CHOLESTEROL	<b>203.8</b>	mg/dL	<200:Desirable, 200-239:Borderline High, >=240:High
HDL CHOLESTEROL	<b>33.8</b>	mg/dL	<40:Low(High Risk), >=60:High(Low Risk)
LDL CHOLESTEROL	<b>159.5</b>	mg/dL	<100.0: Optimal, 100.0-129.0: Nearoptimal/ Aboveoptimal, 130.0-159.0:Borderline High, 160.0-189.0:High, >=190.0:Very High
VLDL CHOLESTEROL	-	mg/dL	Upto 40.0 mg/dL
S. TRIGLYCERIDES	<b>273.5</b>	mg/dL	<150.0:Normal, 150.0-199.0:Borderline high, 200.0-499.0:High, >=500.0:Very High
CHOL/ HDL RATIO	-	mg/dL	LESS THAN 5.0
LDL/ HDL RATIO	-	mg/dL	LESS THAN 5.0

**SOME LIPIDS ARE HIGH -  
SO DERIVED  
PARAMETERS ARE NOT  
GIVEN**



*P. Chaudhari*  
**Dr. PIYUSH B. CHAUDHARI**  
M.D. Medicine  
Reg. No. G-21518

Remarks

Designed By : Sarita Infotech Pvt. Ltd., Navsari

Yashfeen Cardiac Hospital

*[Signature]*  
**Signature  
Technician**

*Thanks for Reference*



# YASHFEEN CARDIAC HOSPITAL™

At. & Po. Viraval, Navsari. 396 445. Phone (H) (02637) 235725

Website : [www.yashfeenhospital.in](http://www.yashfeenhospital.in) E-mail : [info@yashfeenhospital.in](mailto:info@yashfeenhospital.in)

(For Laboratory Reports Only)



Patient Name : DHARMESH MANUBHAI PATEL

Age : 42 Years Sex : M

Ref By Dr. : -

Area : Navsari Date : 08/06/2024

Sample Time : 08/06/2024 08:48 No : 11

Time : 12:55PM

## RENAL FUNCTION TEST REPORT

Test	Findings	UOM	Normal Range
S.CREATININE	1.1	mg/dL	Male-0.9-1.4 mg/dL, Female-0.8-1.2 mg/dL
S.URIC ACID	7.2	mg/dL	Male:3.5-7.2 mg/dL, Female:2.6-6.0 mg/dL
BLOOD UREA NITROGEN	10.7	mg/dL	4.7-23.0 mg/dL



*P. Chauhan*  
Dr. PIYUSH B. CHAUDHARI  
M.D. Medicine

Reg. No. G - 21518

Remarks

Designed By : Sarita Infotech Pvt. Ltd., Navsari

Yashfeen Cardiac Hospital

*Sarita Infotech*  
Signature  
Technician

*Thanks for Reference*



# YASHFEEN CARDIAC HOSPITAL™

At. & Po. Viraval, Navsari. 396 445. Phone (H) (02637) 235725

Website : www.yashfeenhospital.in E-mail : info@yashfeenhospital.in

(For Laboratory Reports Only)



Patient Name : DHARMESH MANUBHAI PATEL

Age : 42 Years Sex : M

Ref By Dr. : -

Area : Navsari Date : 08/06/2024

Sample Time : 08/06/2024 08:48 No : 11

Time : 12:55PM

## BLOOD SUGAR TEST REPORT

Test	Findings	UOM	Normal Range
FASTING BLOOD SUGAR	97.6	mg/dL	70-110 mg/dL
FASTING URINE SUGAR	NIL	-	NIL
POSTPANDRIAL BLOOD SUGAR	87.0	mg/dL	70-140 mg/dL
POSTPANDRIAL URINE SUGAR	NIL	-	NIL



*P. Chaudhary*  
Dr. PIYUSH B. CHAUDHARI

M.D. Medicine

Reg. No. G-21518

Remarks

Designed By : Sarita Infotech Pvt. Ltd., Navsari

Yashfeen Cardiac Hospital

*Hi...*  
Signature  
Technician

*Thanks for Reference*



# YASHFEEN CARDIAC HOSPITAL™

At. & Po. Viraval, Navsari. 396 445. Phone (H) (02637) 235725

Website : www.yashfeenhospital.in E-mail : info@yashfeenhospital.in

(For Laboratory Reports Only)



Patient Name : DHARMESH MANUBHAI PATEL

Age : 42 Years Sex : M

Ref By Dr. : -

Area : Navsari Date : 08/06/2024

Sample Time : 08/06/2024 08:48 No : 11

Time : 12:55PM

## THYROID FUNCTION TEST REPORT

Test	Findings	UOM	Normal Range
T3 (TRIODOXYRONE)	1.46	ng/ml	Newborns:0.73-2.88, 6 Days-3 Months:0.80-2.75, 4-12Months:0.86-2.65, 1-6 Years:0.92-2.48, 7-11 Years:0.93-2.31, 12-20Years:0.91-2.18, Adults:0.80-2.00
T4(THYROXINE)	8.61	µg/dl	Newborns:5.04-18.5, 6 Days-3 Months:5.41-17.0, 4-12 Months:5.67-16.0, 1-6 Years:5.95-14.7, 7-11 Years:5.99-13.8, 12-20 Years:5.91-13.2, Adults:5.10-14.1
TSH	3.88	µIU/ml	Newborns:0.70-15.2, 6 Days-3 Months:0.72-11.0, 4-12 Months:0.73-8.35, 1-6 Years:0.70-5.97, 7-11 Years:0.60-4.84, 12-20 Years:0.51-4.30, Adults:0.27-4.20

### TECHNIQUE

ELECTROCHEMILUMINESCEN  
CE



*P. Chel*  
Dr. PIYUSH B. CHAUDHARI  
M.D. Medicine  
Reg. No. G-21518

Remarks

Designed By : Sarita Infotech Pvt. Ltd., Navsari

Yashfeen Cardiac Hospital

*[Signature]*  
Signature  
Technician

*Thanks for Reference*



# YASHFEEN CARDIAC HOSPITAL™

At. & Po. Viraval, Navsari. 396 445. Phone (H) (02637) 235725

Website : [www.yashfeenhospital.in](http://www.yashfeenhospital.in) E-mail : [info@yashfeenhospital.in](mailto:info@yashfeenhospital.in)  
(For Laboratory Reports Only)



Patient Name : DHARMESH MANUBHAI PATEL

Age : 42 Years Sex : M

Ref By Dr. : -

Area : Navsari Date : 08/06/2024

Sample Time : 08/06/2024 08:48 No : 11

Time : 12:55PM

## GGT TEST REPORT

Test	Findings	UOM	Normal Range
SERUM GGT	36.0	U/L	10.0-71.0 U/L



*P. Chaudhari*  
Dr. PIYUSH B. CHAUDHARI  
M.D. Medicine

Reg.No. G - 21518

Remarks

Designed By : Sarita Infotech Pvt. Ltd., Navsari

Yashfeen Cardiac Hospital

*Sarita*  
Signature  
Technician

*Thanks for Reference*



# YASHFEEN CARDIAC HOSPITAL™

At. & Po. Viraval, Navsari. 396 445. Phone (H) (02637) 235725

Website : [www.yashfeenhospital.in](http://www.yashfeenhospital.in) E-mail : [info@yashfeenhospital.in](mailto:info@yashfeenhospital.in)

(For Laboratory Reports Only)



Patient Name : DHARMESH MANUBHAI PATEL  
Ref By Dr. : -  
Sample Time : 08/06/2024 08:49 No : 11

Age : 42 Years Sex : M  
Area : Navsari Date : 08/06/2024  
Time : 12:55PM

## ROUTINE URINE ANALYSIS

Test	Findings	UOM	Normal Range
<b><u>PHYSICAL EXAMINATION</u></b>			
Quantity	-	-	
Colour	YELLOW	-	
Appearance	CLEAR	-	
Reaction	ACIDIC	-	
Sp. Gravity	1.004	-	
<b><u>CHEMICAL EXAMINATION</u></b>			
U.Albumin	NIL	-	
Sugar	NIL	-	
Acetone	NIL	-	
Bile Salt	NIL	-	
Bile Pigment	NIL	-	
Occult Blood	NIL	-	
<b><u>MICROSCOPIC EXAMINATION</u></b>			
Pus Cells	1-2	/hpf	
Epithelial cells	1-2	/hpf	
Red cells	ABSENT	/hpf	
Casts	-	/hpf	
Crystals	-	/hpf	
Others	-	/hpf	



*f.cho*  
Dr. PIYUSH B. CHAUDHARI  
M.D. Medicine

Reg.No. G - 21518

Remarks

Designed By : Sarita Infotech Pvt. Ltd., Navsari

Yashfeen Cardiac Hospital

*Signature*  
Signature  
Technician

*Thanks for Reference*



DHARMESH ,  
ID:  
DOB:  
42 Years , ,  
Female , Unknown  
Med.:  
Location:  
Referring Physician:  
Notes:

08-06-2024 09:48:51

Vent. Rate:	72 BPM
PR int:	166 ms
QRS dur:	81 ms
QT/QTc:	334/359 ms
P-R-T axes:	47 47 79
Avg. RR:	822 ms
QTcB:	368 ms
QTcF:	356 ms

SINUS RHYTHM  
NONSPECIFIC T-WAVE ABNORMALITY  
BORDERLINE ECG

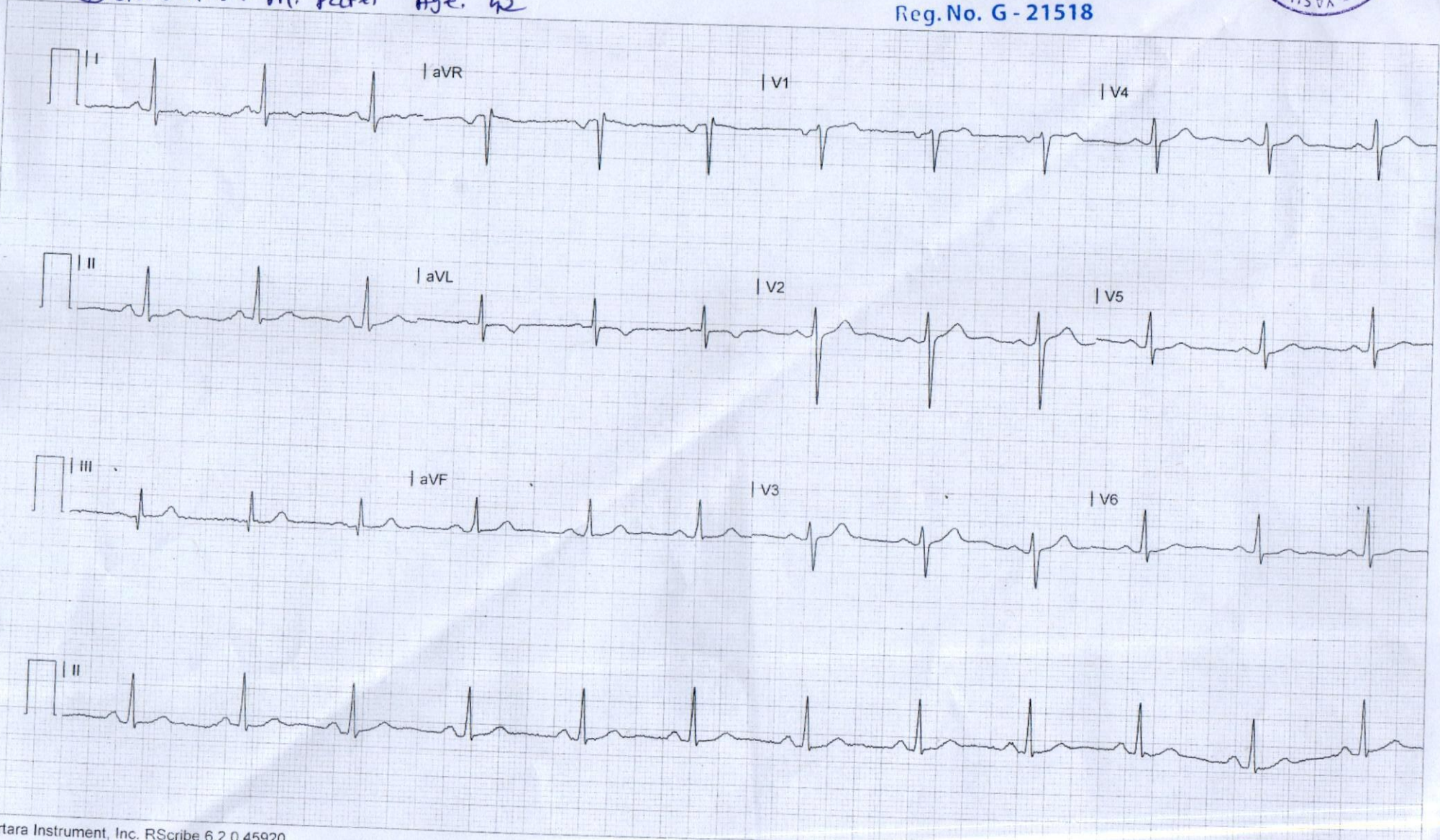
UNCONFIRMED REPORT  
Reviewed by:

*P. Chauhari*  
**Dr. PIYUSH B. CHAUDHARI**  
M.D. Medicine  
Reg. No. G - 21518

Signed by:  
Date:



*Dharmesh m. Pateri Age. 42*



# YASHFEEN IMAGING & RADIOLOGY DEPARTMENT

MANAGED BY :- YASHFEEN FOUNDATION

VIRAVAL, NAVSARI. 396 445. PHONE : (H) (02637) 235725

Website : [www.yashfeenhospital.in](http://www.yashfeenhospital.in) E-mail : [info@yashfeenhospital.in](mailto:info@yashfeenhospital.in)

Name	DHARMESH M. PATEL	Age	42Y/M
Ref by Dr	SELF	Date	08/06/2024

## USG ABDOMEN (SCREENING)

**Liver** appears normal in size & shape with normal echopattern.  
No e/o focal or diffuse lesion. IHBR appear normal.  
PV and CBD appear normal.

**Gall bladder** appears minimally distended & shows hyper echoic shadow of size 6 mm ?calculus. Adv: fasting scan.

**Excessive bowel gas obscures retroperitoneal organs.**

**Spleen** appears normal in size and shows normal echopattern. No e/o focal lesion.

**Both Kidneys** appear normal in size and echopattern. CM Differentiation is preserved.  
No e/o calculus or hydronephrosis on either side.  
Perirenal spaces appear normal on either side.  
Suprarenal regions appear normal on either side. No e/o mass lesion.

**Bladder** is empty (due to non-compliance of patient). Adv: Follow up USG with normally distended bladder.

RIF region appears normal.

No e/o ascites.

### IMPRESSION:

**Gall bladder appears minimally distended & shows hyper echoic shadow ?calculus.**  
Adv: fasting scan.

**Dr. DHARMESH DESAI**  
(M.D. Radiology)  
Dr. Dharmesh Desai  
Reg. No. G - 45284  
YASHFEEN GROUP OF HOSPITAL





# YASHFEEN CARDIAC HOSPITAL™

MANAGED BY :- YASHFEEN FOUNDATION

VIRAVAL, NAVSARI. 396 445. PHONE : (H) (02637) 235725

Website : www.yashfeenhospital.in E-mail : info@yashfeenhospital.in

(Stationary For Report Only)



(Regd. No. E / 1390 / Navsari)

## 2D ECHO CARDIOGRAPHY COLOUR DOPPLER REPORT

Patient Name & No	: DHARMESH MANUBHAI PATEL CH24009295	Age/Sex	UHID :	: 1311
Doctor	: Mohil Nagad	42/ M	No :	: 1128
Referred By	:		Date :	: 08/06/2024

### M-Mode findings

LVIDd : 44mm  
 LVIDs : 30mm  
 IVSd : 10mm  
 PWd : 09mm  
 EF : 60%  
 Aorta : 22mm  
 LA : 31mm

### 2D Imaging

Aortic Valve : Trileaflet, Peak Gradient 5mm of Hg.  
 Mitral Valve : Thin, Pliable, Normal Mobility, Normal function  
 Tricuspid Valve : Normal  
 Pulmonary Valve : Normal

=> : All cardiac chambers are normal sized.  
 => : All cardiac valves are normal.  
 => : No regional wall motion abnormality.  
 => : Normal LV systolic function.  
 => : Normal LV diastolic function.  
 => : IAS/IVS intact.  
 => : No obvious clots/ vegetations/ or effusion.  
 => : IVC Normal size.

### Doppler Findings

=> : No MS/MR, No TS/TR, No AS/AR & No PS/PR  
 Mitral inflow Pattern : E > A  
 Tissue Doppler Findings : E' > A'

Impression : Normal LVEF: 60%, No RWMA.



Report Prepared By

Report Checked By  
**DR. MOHIL NAGAD**  
 M.D. Medicine, D.M. Cardiology  
 Senior Consultant Interventional Cardiology  
 Reg. No. - 622093  
 YASHFEEN HOSPITAL, NAVSARI

Designed By : Sarita Infotech Pvt. Ltd., Navsari

# YASHFEEN IMAGING & RADIOLOGY DEPARTMENT

MANAGED BY :- YASHFEEN FOUNDATION

VIRVAL, NAVSARI. 396 445. PHONE : (H) (02637) 235725

Website : [www.yashfeenhospital.in](http://www.yashfeenhospital.in) E-mail : [info@yashfeenhospital.in](mailto:info@yashfeenhospital.in)

Patient's Name:	DHARMESH M. PATEL	Age & Sex:	42Yrs/M
Ref. by Dr.	SELF	Date:	08-06-2024

## X RAY CHEST (PA VIEW)

Both lung fields appear normal.

Both hila appear normal.

Both CP angles appear clear.

Cardiac size appears within normal limit.


Both domes of diaphragm appear normal.

Bony thoracic cage appears normal.

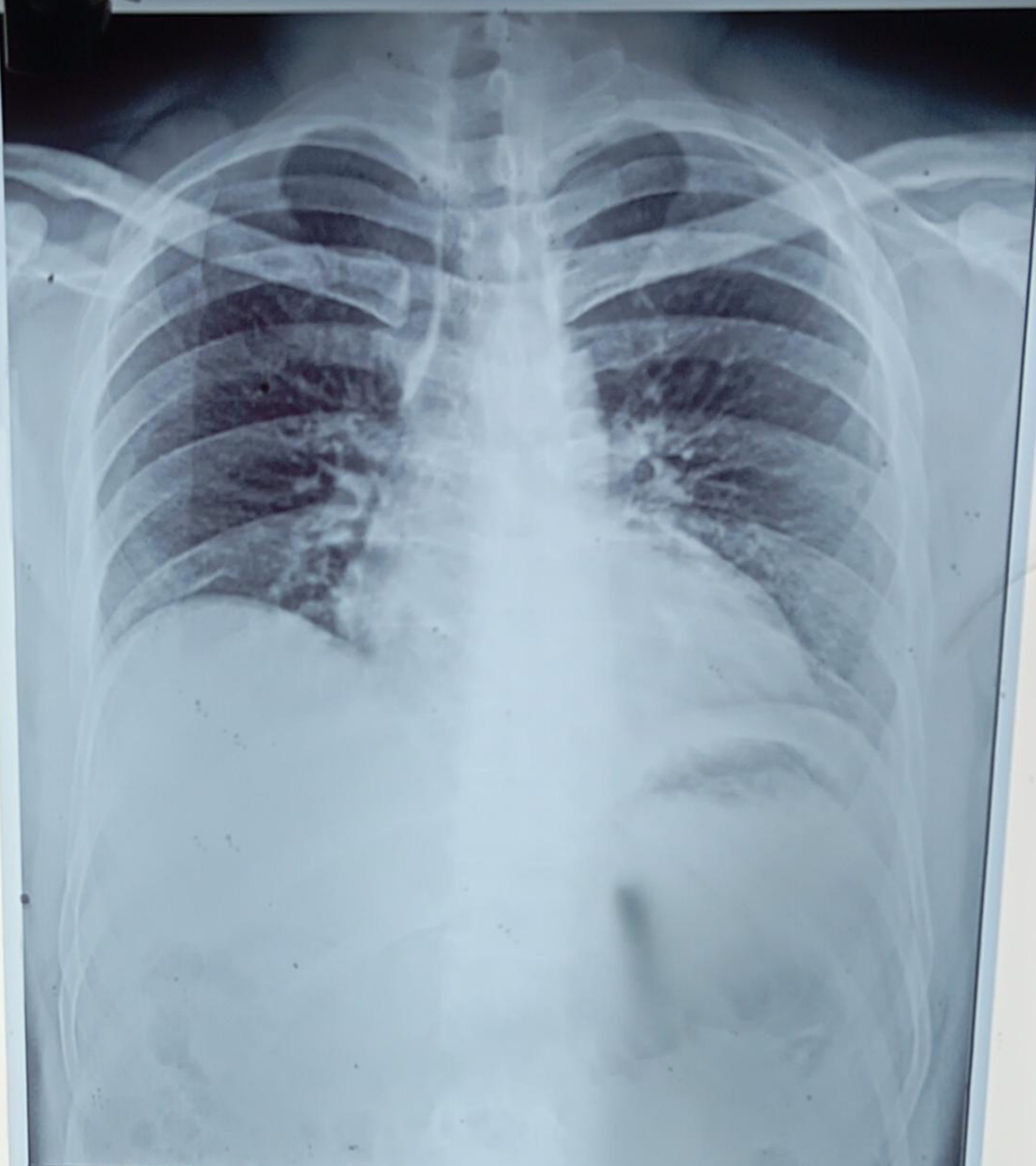### IMPRESSION:

- Normal X-ray chest (PA view).



  
Dr. DHARMESH DESAI  
(M.D. Radiology)  
Reg. No. G - 45284  
MD  
YASHFEEN GROUP OF HOSPITAL

Please contact immediately for any typographical error.  
This is only professional opinion, not a final diagnosis. Kindly correlate clinically. Not valid for medicolegal purpose.



24009295 DHARMESH M PATEL 42/Y 080624193 ChestErect PA 08/06/2024  
YASHFEEN GROUP OF HOSPITALS NAVSARI PH:9924047789