

PATIENT ID : 475
DATE : 14/11/2024
PATIENT NAME : BHARATSINH P SOLANKI
AGE : 36 YRS
GENDER : MALE

ECHO IDENTIFICATION DETAILS:

DOCTOR INCHARGE :

FINDING DESCRIPTION:

VALVE MORPHOLOGY:

MITRAL VALVE: MILD MR

TRICUSPID VALVE: MILD TR

AORTIC VALVE: NO AR

PULMONARY VALVE: NORMAL

1. NORMAL SIZED LA, LV, RA, RV.
2. NORMAL LV FUNCTION, LVEF: 55-60%.
3. NO SIGNIFICANT RWMA.
4. NORMAL LV COMPLIANCE.
5. MILD MR, MILD TR, TRIVIAL PR, NO AR.
6. MILD PAH, RVSP: 36 MMHG.
7. NORMAL RV SYSTOLIC FUNCTION.
8. IAS/IVS: INTACT.
9. NO CLOT/VEGETATION/PERICARDIAL EFFUSION.

DR. NEVIL PATEL
(CARDIOLOGIST)

Patient Name	Mr Bharatsinh Pravansinh Solanki	UHID	MIIA-13782
Age/Gen	36 Y/Male	Payer Name	Mediwheel
Ordering Doctor		Acknowledge Date	14-11-2024 09:45 AM
Refer By	MEDIWHEEL	Accession Number	OPAC-3617
Specimen	Blood	Order Id	ODN-65286
Collection Date	14-11-2024 09:44 AM	Report Date	14-11-2024 12:13 PM
Order Date	14-11-2024 12:00 AM		

Haematology

Service Name	Result	Unit	Reference Range
CBC			
Hemoglobin(Hb)	15.1	gm/dl	14-18
RBC COUNT	5.28	millions/cumm	4.2-5.4
Hematocrit(PCV)	46.5	%	42-52
MCV (Mean Cell Volume)	88.07	fL	76-96
MCH (Mean Corpuscular Hemoglobin)	28.60	pg	27-32
MCHC (Mean Corpuscular Hemoglobin Concentration)	32.47	g/dL	32-36
RDW (Red Cell Distribution Width)	13.2	%	11-16
WBC count - Total(TC)	6030	/cu.mm	4500-11000
Neutrophils.	61	%	40-70
Lymphocyte	33	%	20-40
Eosinophils.	2	%	2-10
Monocytes.	4	%	1-6
Basophils.	0	%	0-2
Platelet Count	285000	/cu.mm	150000-400000
BGRb			
ABO	O		
Rh FACTOR	Positive		
Note	Done by Forward Blood Grouping Method.		
ESR	20	mm/Hr	0-20



Dr Asha C Solanki
 MD (Pathology)

Patient Name	Mr Bharatsinh Pravinsinh Solanki	UHID	MHA-13782
Age/Gen	36 Y/Male	Payer Name	Mediwheel
Ordering Doctor		Acknowledge Date	14-11-2024 09:45 AM
Refer By	MEDIWHEEL	Accession Number	OPAC-3617
Specimen	Whole Blood	Order Id	ODN-65286
Collection Date	14-11-2024 09:44 AM	Report Date	14-11-2024 12:14 PM
Order Date	14-11-2024 12:00 AM		

Clinical Biochemistry

Service Name	Result	Unit	Reference Range
FBS	97.8	mg/dL	60-110
ALKALINE PHOSPHATE	56.0	U/L	53-128
Uric Acid	5.9	mg/dL	3.5-7.2
S Billirubin			
Billirubin Total	0.45	mg/dL	0.2-2.0
Billirubin Direct	0.20	mg/dL	0.0-0.2
Billirubin Indirect	0.25	mg/dL	0.2-0.7
Total Protein(Alb)			
Total Protein	7.17	g/dL	5.8-8.3
Serum Albumin	4.5	gm/dl	3.5-5.0
Serum Globulin	2.67	gm/dl	2.4-3.5
ALBUMIN/GLOBULIN RATIO	1.69		1.2-2.2
Serum Creatinine	0.79	mg/dL	0.74-1.35
GGT (Gamma Glutamin Transferase)	20.4	U/L	
HbA1c			
Glycosylated Hb	5.6	%	Normal : <= 5.7 Prediabetes : 5.7 -6.4 Diabetes : >= 6.5 6-7 : Near Normal Glycemia, <7 : Goal, 7-8 : Good Control >8 : Action Suggested
Estimated Average Glucose	114.02	mg/dL	

Dr. Asha C. Solanki
MD (Pathology)

-----End of the Report-----

(***** Electronically Generated Report *****)

Patient Name	Mr Bharatsinh Pravinsinh Solanki	UHID	MHA-13782
Age Gen	36 Y/Male	Payer Name	Mediwheel
Ordering Doctor		Acknowledge Date	14-11-2024 09:45 AM
Refer By	MEDIWHEEL	Accession Number	OPAC-3617
Specimen	Serum	Order Id	ODN-65286
Collection Date	14-11-2024 09:44 AM	Report Date	14-11-2024 12:14 PM
Order Date	14-11-2024 12:00 AM		

Clinical Biochemistry

Service Name	Result		Unit	Reference Range
Lipid Profile				
Cholesterol	229.0	H	mg/dL	Low Risk : < 200 Moderate Risk : 200-239 High Risk : ≥240
Triglycende	112.6		mg/dL	Normal : <150 Border Line:150-199 High:200-499 Very High=>500
HDL Cholesterol	40.7		mg/dL	Negative Risk : > or = 60 High Risk : < 40
LDL Cholesterol	165.78	H	mg/dL	Low Risk < 130 Moderate Risk : 131-159 High Risk > 160
VLDL	22.52		mg/dL	0-34
LDL/HDL RATIO	4.07	H		Low Risk : 0.5-3.0 Moderate Risk : 3.0-6.0 Elevated Level High: >6.0
Total Chol/ HDL Ratio	5.63	H		Low Risk : 3.3 to 4.4 Average Risk : 4.4 to 7.1 Moderate Risk > 7.1 to 11.0 High Risk : > 11.0
Total Lipids	683.20		mg/dL	400-700



Dr Asha C Solanki
MD (Pathology)

-----End of the Report-----

(***** Electronically Generated Report *****)

Patient Name	Mr Bharatsinh Pravinsinh Solanki	UHID	MHA-13782
Age/Gen	36 Y/Male	Payer Name	Mediwheel
Ordering Doctor		Acknowledge Date	14-11-2024 09:45 AM
Refer By	MEDIWHEEL	Accession Number	OPAC-3617
Specimen	Serum	Order Id	ODN-65286
Collection Date	14-11-2024 09:44 AM	Report Date	14-11-2024 12:14 PM
Order Date	14-11-2024 12:00 AM		

Immunology

Service Name	Result	Unit	Reference Range
Thyroid function test(T3/ T4/ TSH)			
T3	1.46	ng/L	0.69-2.15
T4	5.57	ng/mL	4.3-12.5
TSH	3.53	μIU/mL	0.3-4.5



Dr Asha C Solanki
MD (Pathology)

-----End of the Report-----

(***** Electronically Generated Report *****)

Patient Name	Mr Bharatsinh Pravinsinh Solanki	UHID	MHA-13782
Age/Gen	36 Y/Male	Payer Name	Mediwheel
Ordering Doctor		Acknowledge Date	14-11-2024 09:45 AM
Refer By	MEDIWHEEL	Accession Number	OPAC-3617
Specimen	Urine	Order Id	ODN-65286
Collection Date	14-11-2024 09:44 AM	Report Date	14-11-2024 12:14 PM
Order Date	14-11-2024 12:00 AM		

Clinical Pathology

Service Name	Result	Unit	Reference Range
URINE R/M			
Volume	20	ml	
Colour	Pale Yellow		
Appearance	Clear		
Specific Gravity	1.003		1.003-1.03
pH	5.5		4.6-8.0
Chemical Examination			
Protein	Absent		
Glucose	Absent		
Ketones	Absent		
Bile pigments	Absent		
Bile salts	Absent		
Blood	Absent		
Nitrite	Absent		
Microscopic Examination			
Pus cells	Occasional	/hpf	0-2
RBCs	Nil	/hpf	
Epithelial cells	Occasional	/hpf	0-2
Cast	Absent		
Crystals	Absent		
Amorphous Deposit	Absent		
Bacteria	Absent		
Yeast	Absent		



Dr. Asha C. Solanki
MD (Pathology)



NAME: BHARATSINH SOLANKI
DATE: 14/11/2024
REF. BY: AAYUSH HOSPITAL

36YRS/M

Clinical Profile: Evaluation for abdominal pain.

USG OF ABDOMEN & PELVIS

Liver is normal in size (13.5 cm), contour and echotexture. No focal mass or biliary dilatation is seen. Portal vein is normal.

Spleen is normal in size (12.7 cm) and echogenicity.

Gall bladder is well distended with normal wall thickness. No sludge or calculus seen in it. CBD is normal.

Pancreas is normal in size, contour and echotexture. No focal mass, calcification or duct dilatation is seen.

No ascites /pleural effusion or para-aortic/mesenteric adenopathy is seen.

No obvious mass or abnormal bowel wall thickening is seen in either iliac fossa or peri-umbilical region.

Both the kidney are normal in size, contour & echotexture. No calculus or hydronephrosis is seen in either kidney.

Right kidney: 95 x 34 mm

Left kidney: 86 x 41 mm

Ureters are not dilated on either side.

Urinary bladder is well distended with normal contour and wall thickness. No vesical calculus is seen in it.

Prostate appears normal in size and measures 25 x 36 x 25 mm (13 cc) and shows normal echogenicity.

IMPRESSION:

- **NORMAL SONOGRAPHIC STUDY OF ABDOMEN AND PELVIS.**

DR. DINESH PATEL M.D., D.M.R.E. DR. MRUGESH DOCTOR M.D., D.M.R.E. DR. HEMANT PATEL M.D., D.M.R.E., DNB DR. RAJENDRA SOLANKI M.D. DR. ANKUR SHAN M.R.E. DR. DHARA PATEL M.B.B.S DMRE

ID: 13182
Name: Ismail, Umarah
Age: 36 Years
Gender: Male


2024-11-14 09:46:49

Heart Rate
PR Interval
QRS Duration
QT/QTc Interval
P/QRS/T Axis

57 bpm
152 ms
34 ms
412/407 ms
79/53/29 deg

Sinus rhythm
Normal ECG

Unconfirmed Diagnosis



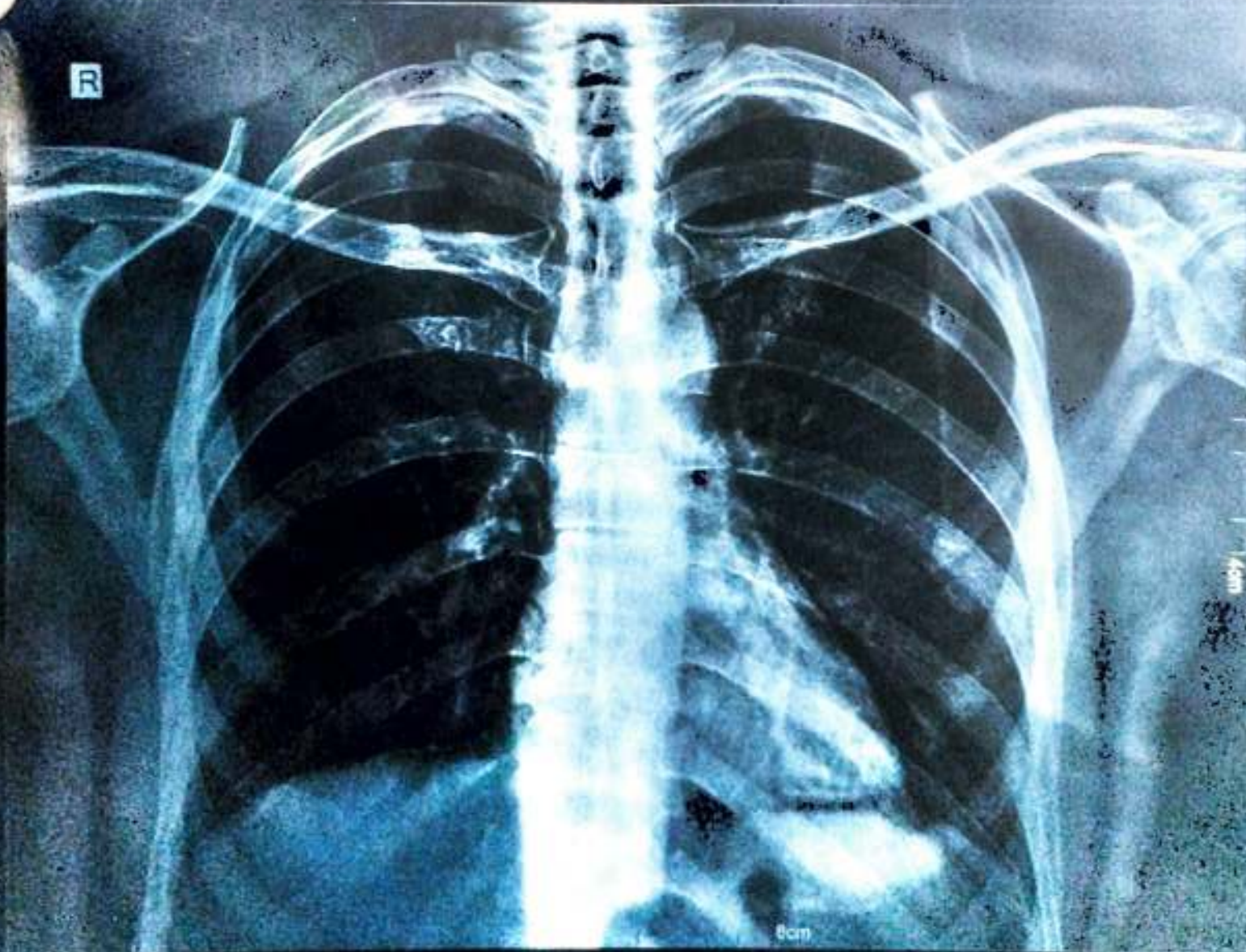25 mm/s 10 mm/mV 50 Hz ECG 20 Hz

AMISH HOSPITAL

02.19.00V28.4.1

SN FN 804687

R



8cm