

Patient Name : Ms.RAGHUPATHY MONICA	Collected : 10/Aug/2024 08:52AM
Age/Gender : 31 Y 6 M 28 D/F	Received : 10/Aug/2024 01:25PM
UHID/MR No : CANN.0000240509	Reported : 10/Aug/2024 02:38PM
Visit ID : CANNOPV417449	Status : Final Report
Ref Doctor : Self	Sponsor Name : ARCOFEMI HEALTHCARE LIMITED
Emp/Auth/TPA ID : 22E29801	

DEPARTMENT OF IMMUNOLOGY

ARCOFEMI - MEDIWHEEL - FULL BODY HEALTH ANNUAL PLUS CHECK - FEMALE - 2D ECHO - PAN INDIA - FY2324

Test Name	Result	Unit	Bio. Ref. Range	Method
THYROID PROFILE TOTAL (T3, T4, TSH) , SERUM				
TRI-IODOTHYRONINE (T3, TOTAL)	1.07	ng/mL	0.7-2.04	CLIA
THYROXINE (T4, TOTAL)	12.57	µg/dL	5.48-14.28	CLIA
THYROID STIMULATING HORMONE (TSH)	1.620	µIU/mL	0.34-5.60	CLIA

Comment:

For pregnant females	Bio Ref Range for TSH in uIU/ml (As per American Thyroid Association)
First trimester	0.1 - 2.5
Second trimester	0.2 – 3.0
Third trimester	0.3 – 3.0

- TSH is a glycoprotein hormone secreted by the anterior pituitary. TSH activates production of T3 (Triiodothyronine) and its prohormone T4 (Thyroxine). Increased blood level of T3 and T4 inhibit production of TSH.
- TSH is elevated in primary hypothyroidism and will be low in primary hyperthyroidism. Elevated or low TSH in the context of normal free thyroxine is often referred to as sub-clinical hypo- or hyperthyroidism respectively.
- Both T4 & T3 provides limited clinical information as both are highly bound to proteins in circulation and reflects mostly inactive hormone. Only a very small fraction of circulating hormone is free and biologically active.
- Significant variations in TSH can occur with circadian rhythm, hormonal status, stress, sleep deprivation, medication & circulating antibodies.

TSH	T3	T4	FT4	Conditions
High	Low	Low	Low	Primary Hypothyroidism, Post Thyroidectomy, Chronic Autoimmune Thyroiditis
High	N	N	N	Subclinical Hypothyroidism, Autoimmune Thyroiditis, Insufficient Hormone Replacement Therapy.
N/Low	Low	Low	Low	Secondary and Tertiary Hypothyroidism
Low	High	High	High	Primary Hyperthyroidism, Goitre, Thyroiditis, Drug effects, Early Pregnancy
Low	N	N	N	Subclinical Hyperthyroidism
Low	Low	Low	Low	Central Hypothyroidism, Treatment with Hyperthyroidism
Low	N	High	High	Thyroiditis, Interfering Antibodies



DR. R. SRIVATSAN
M.D.(Biochemistry)



SIN No:CAG240802051

This test has been performed at Apollo Health and Lifestyle Ltd - Chennai, Diagnostics Laboratory.

This test has been performed at Apollo Health and Lifestyle Ltd - RRL ASHOK NAGAR

Apollo Health and Lifestyle Limited (CIN - U85110TG2000PLC115819)

Regd. Office: 1-10-60/62, Ashoka Raghupathi Chambers, 5th Floor, Begumpet, Hyderabad, Telangana - 500 016 |
www.apollohl.com | Email ID: enquiry@apollohl.com, Ph No: 040-4904 7777, Fax No: 4904 7744

Address:
D No.30, F – Block, 2nd Avenue, Anna Nagar East, Chennai.600 102,
Phone : 044.26224504 / 05

1860 500 7788
www.apolloclinic.com

APOLLO CLINICS NETWORK

Telangana: Hyderabad (AS Rao Nagar | Chanda Nagar | Kondapur | Nallakunta | Nizampet | Manikonda | Uppal) | Andhra Pradesh: Vizag (Seethamma Peta) | Karnataka: Bangalore (Basavanagudi | Bellandur | Electronics City | Fraser Town | HSR Layout | Indira Nagar | JP Nagar | Kundalahalli | Koramangala | Sarjapur Road) | Mysore (VV Mohalla) | Tamilnadu: Chennai (Annanagar | Kotturpuram | Mogappair | T Nagar | Valasaravakkam | Velachery) | Maharashtra: Pune (Aundh | Nigdi Pradhikaran | Viman Nagar | Wanowrie) | Uttar Pradesh: Ghaziabad (Indrapuram) | Gujarat: Ahmedabad (Satellite) | Punjab: Amritsar (Court Road) | Haryana: Faridabad (Railway Station Road)

Patient Name	: Ms.RAGHUPATHY MONICA	Collected	: 10/Aug/2024 08:52AM
Age/Gender	: 31 Y 6 M 28 D/F	Received	: 10/Aug/2024 01:25PM
UHID/MR No	: CANN.0000240509	Reported	: 10/Aug/2024 02:38PM
Visit ID	: CANNOPV417449	Status	: Final Report
Ref Doctor	: Self	Sponsor Name	: ARCOFEMI HEALTHCARE LIMITED
Emp/Auth/TPA ID	: 22E29801		

DEPARTMENT OF IMMUNOLOGY

ARCOFEMI - MEDIWHEEL - FULL BODY HEALTH ANNUAL PLUS CHECK - FEMALE - 2D ECHO - PAN INDIA - FY2324

N/Low	High	N	N	T3 Thyrotoxicosis, Non thyroidal causes
High	High	High	High	Pituitary Adenoma; TSHoma/Thyrotropinoma

***** End Of Report *****

Result/s to Follow:

PERIPHERAL SMEAR, HBA1C (GLYCATED HEMOGLOBIN), GLUCOSE (FASTING) - URINE, LBC PAP SMEAR, COMPLETE URINE EXAMINATION (CUE), HEMOGRAM, RENAL PROFILE/KIDNEY FUNCTION TEST (RFT/KFT), LIVER FUNCTION TEST (LFT), GAMMA GLUTAMYL TRANSFERASE (GGT), GLUCOSE, FASTING, LIPID PROFILE, BLOOD GROUP ABO AND RH FACTOR, GLUCOSE (POST PRANDIAL) - URINE, GLUCOSE, POST PRANDIAL (PP), 2 HOURS (POST MEAL)



DR. R. SRIVATSAN
M.D.(Biochemistry)



SIN No:CAG240802051

This test has been performed at Apollo Health and Lifestyle Ltd - Chennai, Diagnostics Laboratory.

This test has been performed at Apollo Health and Lifestyle Ltd - RRL ASHOK NAGAR

Apollo Health and Lifestyle Limited (CIN - U85110TG2000PLC115819)
Regd. Office: 1-10-60/62, Ashoka Raghupathi Chambers, 5th Floor, Begumpet, Hyderabad, Telangana - 500 016 |
www.apollohl.com | Email ID: enquiry@apollohl.com, Ph No: 040-4904 7777, Fax No: 4904 7744

Address:
D No.30, F - Block, 2nd Avenue, Anna Nagar East, Chennai.600 102,
Phone : 044.26224504 / 05

1860 500 7788
www.apolloclinic.com

APOLLO CLINICS NETWORK
Telangana: Hyderabad (AS Rao Nagar | Chanda Nagar | Kondapur | Nallakunta | Nizampet | Manikonda | Uppal) Andhra Pradesh: Vizag (Seethamma Peta) Karnataka: Bangalore (Basavanagudi | Bellandur | Electronics City | Fraser Town | HSR Layout | Indira Nagar | JP Nagar | Kundalahalli | Koramangala | Sarjapur Road) Mysore (VV Mohalla) Tamilnadu: Chennai (Annanagar | Kotturpuram | Mogappair | T Nagar | Valasaravakkam | Velachery) Maharashtra: Pune (Aundh | Nigdi Pradhikaran | Viman Nagar | Wanowrie) Uttar Pradesh: Ghaziabad (Indrapuram) Gujarat: Ahmedabad (Satellite) Punjab: Amritsar (Court Road) Haryana: Faridabad (Railway Station Road)

Patient Name	: Ms. RAGHUPATHY MONICA	Age	: 31Yrs 6Mths 29Days
UHID	: CANN.0000240509	OP Visit No.	: CANNOPV417449
Printed On	: 10-08-2024 11:04 AM	Advised/Pres Doctor	: --
Department	: Radiology	Qualification	: --
Referred By	: Self	Registration No.	: --
Employeer Id	: 22E29801		

DEPARTMENT OF RADIOLOGY

ULTRASOUND WHOLE ABDOMEN

Liver shows uniform echopattern with no evidence of focal or diffuse pathology.
Intra and extra hepatic biliary passages are not dilated.

Gall bladder appears normal with no evidence of calculus.
Wall thickness appear normal.

Pancreas and spleen appear normal.
Spleen measures 6.5cms.

Portal and splenic veins appear normal.
No evidence of ascites or lymphadenopathy.

Diaphragmatic movements are satisfactory.
There is no evidence of sub diaphragmatic pathology or pleural effusion.

Right kidney measures 7.5 x 3.3cms.
Left kidney measures 8.1 x 3.7cms.
Both kidneys show normal echopattern with no evidence of calculi or calyceal dilatation.

Uterus measures 7.4 x 2.5cms and shows normal endometrial and myometrial echoes.
The endometrial thickness 2.8mm.
Right ovary measures 1.5 x 0.8cms.
Left ovary measures 1.9 x 1.4 cms.
Both ovaries are normal in size and echotexture.
No mass lesion seen in the pelvis.
Bladder is normal in contour.

IMPRESSION:

*NO SIGNIFICANT ABNORMALITY DETECTED

---End Of The Report---

Dr.A R RAGHUL
MBBS MD Radiodiagnosis
139605
Radiology

Patient Name	: Ms. RAGHUPATHY MONICA	Age	: 31Yrs 6Mths 29Days
UHID	: CANN.0000240509	OP Visit No.	: CANNOPV417449
Printed On	: 10-08-2024 08:56 AM	Advised/Pres Doctor	: --
Department	: Cardiology	Qualification	: --
Reffered By	: Self	Registration No.	: --
Employeer Id	: 22E29801		

DEPARTMENT OF CARDIOLOGY

Observation :-

1. Sinus Rhythm.
2. Heart rate is 76 beats per minutes.

Impression:

NORMAL RESTING ECG.

---End Of The Report---

Dr. ARULNITHI AYYANATHAN
MBBS., MRCP, AB, MBA
63907
Cardiology

Patient Name	: Ms. RAGHUPATHY MONICA	Age	: 31Yrs 6Mths 29Days
UHID	: CANN.0000240509	OP Visit No.	: CANNOPV417449
Printed On	: 10-08-2024 07:52 AM	Advised/Pres Doctor	: --
Department	: Cardiology	Qualification	: --
Referred By	: Self	Registration No.	: --
Employee Id	: 22E29801		

DEPARTMENT OF CARDIOLOGY

DIMENSIONS:

AO (ed) 2.7 CM
LA (es) 3.2 CM
LVID (ed) 4.8 CM
LVID (es) 3.5 CM
IVS (Ed) 0.7 CM
LVPW (Ed) 0.9 CM
EF 68%
% FD 33%

MORPHOLOGICAL DATA :

MITRAL VALVE	NORMAL
AML	NORMAL
PML	NORMAL
AORTIC VALVE	NORMAL
TRICUSPID VALVE	NORMAL
PULMONARY VALVE	NORMAL
RIGHT VENTRICLE	NORMAL
INTER ATRIAL SEPTUM	INTACT
INTER VENTRICULAR SEPTUM	INTACT
PULMONARY ARTERY	NORMAL
AORTA	NORMAL
RIGHT ATRIUM	NORMAL
LEFT ATRIUM	NORMAL
LEFT VENTRICLE	NORMAL
PERICARDIUM	NORMAL

DOPPLER STUDIES MITRAL INFLOW :

VALVE	VELOCITY (m / sec)
PULMONARY VALVE	0.8
AORTIC VALVE	0.9
TRICUSPID VALVE	0.8
MITRAL VALVE : E WAVE :	0.7
MITRAL VALVE : A WAVE :	0.5

IMPRESSION :

NO RWMA
NORMAL LEFT VENTRICULAR FUNCTION (EF - 68%)
NORMAL CARDIAC CHAMBERS & VALVES
TRIVIAL TRICUSPID REGURGITATION
NO PAH / CLOT / PE .

DONE BY :

Ms. VITHYASREE. VS

---End Of The Report---

Dr. RAKESH GOPAL

--

--

Cardiology



Patient Name	: Ms. RAGHUPATHY MONICA	Age	: 31Yrs 6Mths 29Days
UHID	: CANN.0000240509	OP Visit No.	: CANNOPV417449
Printed On	: 10-08-2024 11:31 AM	Advised/Pres Doctor	: --
Department	: Radiology	Qualification	: --
Referred By	: Self	Registration No.	: --
Employer Id	: 22E29801		

DEPARTMENT OF RADIOLOGY

Lung fields are clear.

Cardio thoracic ratio is normal.

Apices, costo and cardio phrenic angles are free.

Cardio vascular shadow and hila show no abnormal feature.

Bony thorax shows no significant abnormality.

Domes of diaphragm are well delineated.

IMPRESSION:

***NO SIGNIFICANT ABNORMALITY DETECTED.**


---End Of The Report---


Dr. PRAVEENA T
MBBS, DMRD, FAGE
72064
Radiology



नाम : RAGHUPATHY MONICA
Name

कर्मचारी कूट क्र : 116293
E.C. No.


जारीकर्ता प्राधिकारी
Issuing Authority


धारक के हस्ताक्षर
Signature of Holder

CANN-240509
OCR-105578

सिलने पर, विमोचित को लौटाएँ
साहायक महाप्रबन्धक (सुरक्षा)
बैंक ऑफ़ बड़ोदा, बड़ोदा कॉर्पोरेट सेंटर
प्लॉ-26, जी-ब्लॉक, बान्द्रा-कुर्ला कॉम्प्लेक्स, मुंबई-400 051, भारत
फोन: 91 22 6698 5196, फ़ैक्स: 91 22 2652 5747

If found, please return to:
Asst. General Manager (Security)
Bank of Baroda, Baroda Corporate Centre
C-26, G-Block, Bandra-Kurla Complex
Mumbai 400 051, India
Phone: 91 22 6698 5196, Fax: 91 22 2652 5747

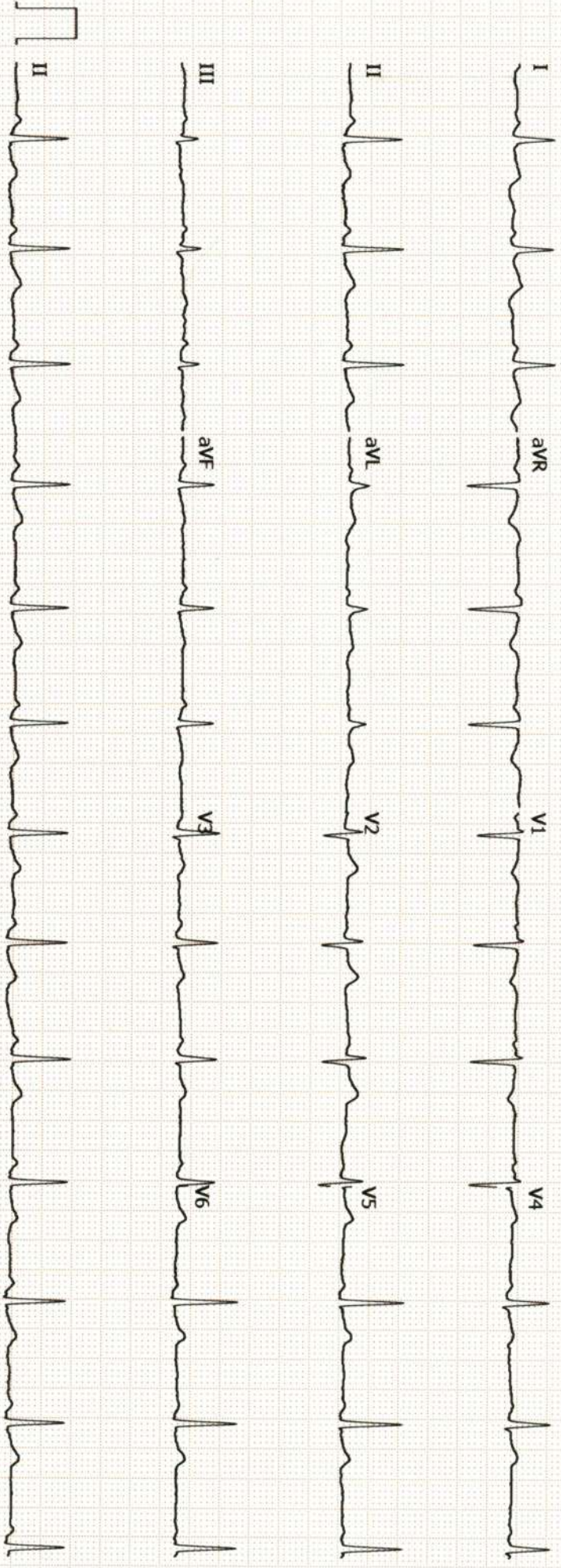
रक्त समूह / Blood Group : O +ve
पसवान चिह्न / Identification Marks : A mole on the right side of
forehead

Technician:
Ordering Ph:
Referring Ph:
Attending Ph:

QRS : 68 ms
QT / QTcBaz : 352 / 396 ms
PR : 132 ms
P : 98 ms
RR / PP : 784 / 789 ms
P / QRS / T : 50 / 48 / 31 degrees

Indication 1:
Medication 2:
Medication 3:

*NDR
RHR*



Done



Apollo Clinic

CONSENT FORM

Patient Name: Raghupathy Monica Age: 31

UHID Number: 240509 Company Name: arcofemi

I Mr/Mrs/Ms Raghupathy Monica Employee of arcofemi

(Company) Want to inform you that I am not interested in getting ur (testing)

Tests done which is a part of my routine health check package.

And I claim the above statement in my full consciousness.

Patient Signature: [Signature] Date: 08.08.2024

Reason: UNNARAI

Apollo Medical Centre
No. 90, F-Block, 2nd Avenue,
Anna Nagar East, Chennai-600 102
Ph: 2620 6666 2622 4506
Toll No: 1860 500 7788

ENT check up

Raghuopathy Monica

31/F

10/8/21

Height:	Weight:	BMI:	Waist Circum:
Temp:	Pulse:	Resp:	B.P:

General Examination / Allergies
History

No complaints

of E

ENT - WNLs



Follow up date:

Doctor Signature & Stamp

Convenient & reliable. Complete diagnostic services for the entire family. All under one roof.

Name: Saghu Pathy moni ca
 Occupation:
 Age: 81y Sex: Male Female
 Address:
 Ph:

Date: 10/8/24 Reg. No.: 240509
 Ref. Physician:
 Copies to:

REPORT ON OPHTHALMIC EXAMINATION

History: Nil

Present Complaint: Nil

ON EXAMINATION:

	RE	LE
Ocular Movements :		
Anterior Segment :	<u>Free</u>	<u>Free</u>
Intra-Ocular-Pressure :		
Visual Acuity: D.V. :		<u>N</u>
Without Glass :	<u>N</u>	
With Glass :	<u>6/6</u>	<u>6/6</u>
N.V. :		
Visual Fields :		
Fundus :	<u>N6</u>	<u>N6</u>
Impression :	<u>Free</u>	<u>Free</u>
Advice :		<u>N</u>
Colour Vision :	<u>N</u>	

OPHTHALMOLOGY / OPTOMETRIST

LETTER OF APPROVAL / RECOMMENDATION

To,

The Coordinator,
MediWheel (M/s. Arcofemi Healthcare Pvt. Ltd.)

Dear Sir / Madam,

Sub: Annual Health Checkup for the employees of Bank of Baroda

This is to inform you that the following employee wishes to avail the facility of Cashless Annual Health Checkup provided by you in terms of our agreement.

PARTICULARS	EMPLOYEE DETAILS
NAME	MS. RAGHUPATHY MONICA
EC NO.	116293
DESIGNATION	CUSTOMER SERVICE ASSOCIATE
PLACE OF WORK	CHENNAI, RAJAJI ROAD
BIRTHDATE	13-01-1993
PROPOSED DATE OF HEALTH CHECKUP	10-08-2024
BOOKING REFERENCE NO.	24S116293100108848E

This letter of approval / recommendation is valid if submitted along with copy of the Bank of Baroda employee id card. This approval is valid from **23-07-2024** till **31-03-2025** The list of medical tests to be conducted is provided in the annexure to this letter. Please note that the said health checkup is a **cashless facility** as per our tie up arrangement. We request you to attend to the health checkup requirement of our employee and accord your top priority and best resources in this regard. The EC Number and the booking reference number as given in the above table shall be mentioned in the invoice, invariably.

We solicit your co-operation in this regard.

Yours faithfully,

Sd/-

Chief General Manager
HRM & Marketing Department
Bank of Baroda

(Note: This is a computer generated letter. No Signature required. For any clarification, please contact MediWheel (M/s. Arcofemi Healthcare Pvt. Ltd.))

CASE RECORD

Name: <u>Dr. Rajkumar Patil</u>	Date: <u>10.8.21</u>
Occupation: _____	UHID No.: <u>240509</u>
Age: <u>31</u> Sex: <input checked="" type="checkbox"/> Male <input type="checkbox"/> Female	OP / Company: <u>Dr. Lakshmi</u>
Address: _____	Ref. Physician: <u>R. Suresh</u>
Tel No: _____	

Consultant :

ccid vaccinated

DHS v
vit D - 13
B12 - 1u2

Echinopril - 8
HbA1c - 5.9
- a cholesterol

History :

Chief Complaints : (If pain is present, please describe location, character, score etc.)

- T.B - 3yrs ago - pleural eff x 6m Rx
- ? pain lt basal chest on inspiration

- urine - UTI
yeast +
- xray - clear

History of Present illness :

- odv
- urine - C+S
 - PAP follow up gynec
 - vit D3 / B12 at advised
 - Follow up on chest pain
 - Dietary changes for cholesterol / hbA1c
 - daily walk / Jut
 - follow up on Echinopril LPR +

Apollo Medical Centre
F-Block, 2nd Avenue,
Kaduganur East, Chennai-600 102
224505, Mobile: 7356302800
Tel No. 1800 800 7788

[Signature]

Physical Examination

General : Build Height 155 Weight 53
Anaemia Icterus Cyanosis Clubbing
Oedema Glands

ENT :

CVS : Heart Rate & Rhythm

B.P. : Supine Sitting Standing

Chest Shape

120/80

Heart Sounds

90/min

Murmurs

Thrills

S11 (1)

RS : Rate & Type

Breath Sounds

N.B.C

Abdomen : Appearance

Liver

Spleen

Tenderness

N

Bowel sounds

Fluid

Genitals :

CNS : Cranial Nerves

Sensors System

Motor System

N

Reflexes

Fundus

Skin :

N

Extremities :