

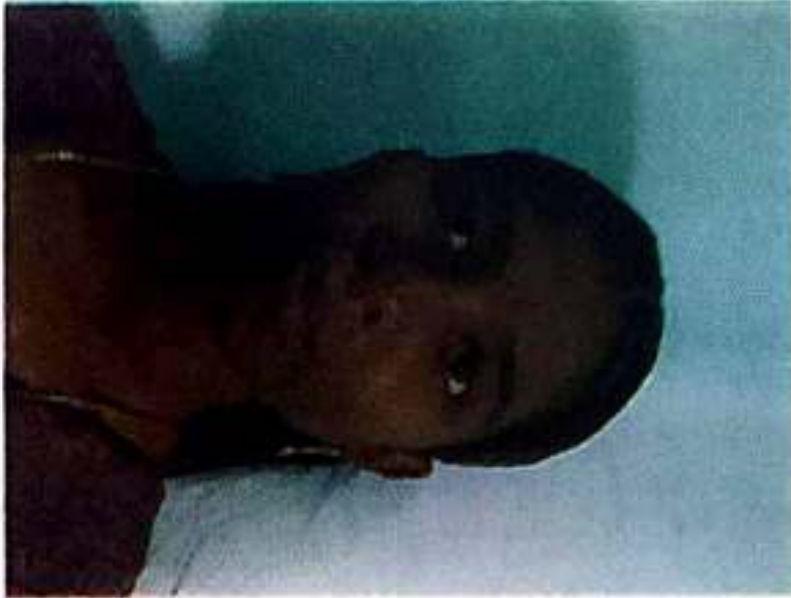

இந்திய அரசாங்கம்

Government of India

கார்த்திகா ரா

Karthika R



பிறந்த நாள்/DOB: 29/07/1995

பெண்யால் / Female

9315 6473 7507



ஆதார் - சாதாரண மனிதனின் அதிகாரம்



இந்திய தனிப்பட்ட அடையாள ஆணைய அமைப்பு

Unique Identification Authority of India

முகவரி: D/O: ராமகிருஷ்ணன், 10/162

மெயின் ரோடு, லெவிஞ்சிபுரம்

லெவிஞ்சிபுரம், திருநெல்வேலி

தமிழ் நாடு, 627114

Address: D/O:

Ramakrishnan, 10/162,

MAIN ROAD, Levinjipuram,

Levinjipuram, Tirunelveli,

Radhapuram, Tamil Nadu,

627114

9315 6473 7507



1947

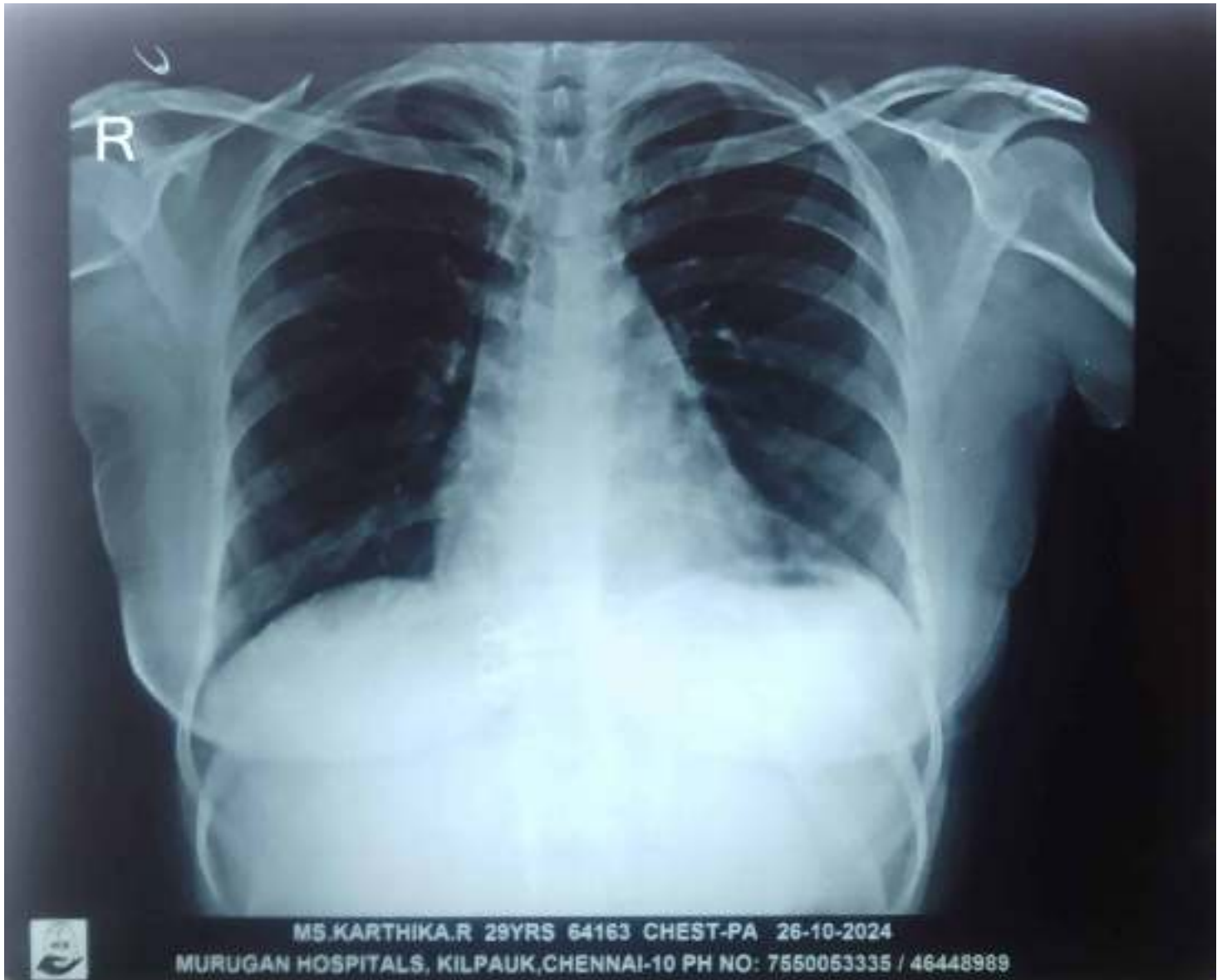1800 300 1947



help@uidai.gov.in

WWW

www.uidai.gov.in



M5.KARTHIKA.R 29YRS 64163 CHEST-PA 26-10-2024

MURUGAN HOSPITALS, KILPAUK, CHENNAI-10 PH NO: 7550053335 / 46448989





SCAN REPORT

NAME	: MS. KARTHIKA.R	PATIENT ID	: MII20240061463
AGE/SEX	: 29-Years / Female	IP / OP NO	: OP21100685
CONSULTANT	: DR. ARUN PRAKASH	DATE	: 26/10/2024

ULTRA SOUND SCAN OF ABDOMEN

LIVER: Normal in size and measures- 12.7 cm and normal in echotexture. No focal lesions are seen. No dilatation of intra-hepatic biliary radicals present. Hepatic veins and IVC appear normal. Portal vein is normal in caliber. Common bile duct is normal in caliber.

GALL BLADDER: Normal in size and wall thickness. No evidence of any calculus or mass present. No evidence of pericholecystic collections.

PANCREAS: Normal in size and echotexture. No focal lesions are seen. No evidence of calculi or calcifications. No evidence of pancreatic duct dilation.

PARA AORTIC AREAS: Aorta and IVC appear normal. No evidence of para aortic lymphadenopathy.

SPLEEN: Normal in size and measures-8.8 cm. Normal in echotexture. No evidence of focal lesions.

RIGHT KIDNEY: Measures 9.9 x 4.5 cm and is normal in size and echotexture. Cortico medullary differentiation is well maintained. There is no hydronephrosis or mass.

LEFT KIDNEY: Measures 10.0 x 4.9 cm and is normal in size and echotexture. Cortico medullary differentiation is well maintained. There is no calculus or hydronephrosis or mass.

Healing Hearts and Lives

URINARY BLADDER: Normal in size, contour and wall thickness. There is no evidence of calculus or mass. No vesical diverticulum present.

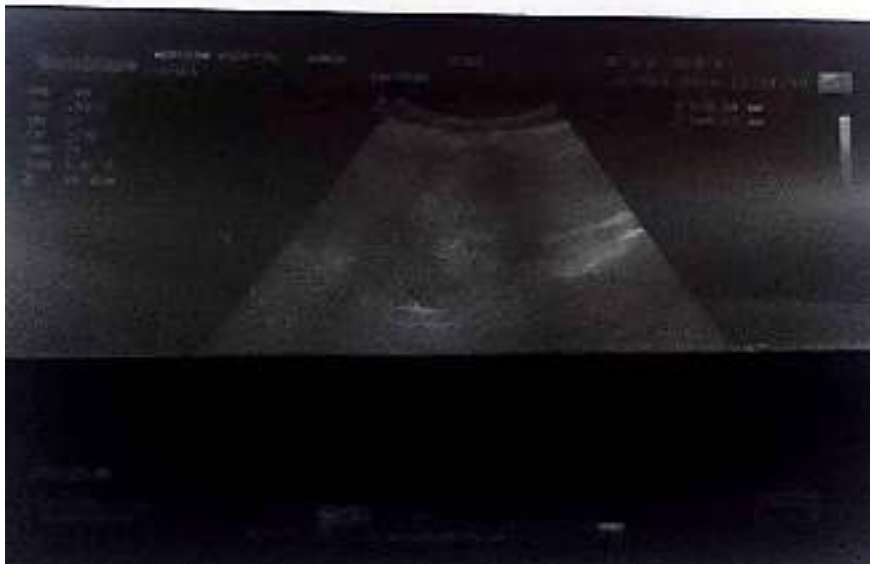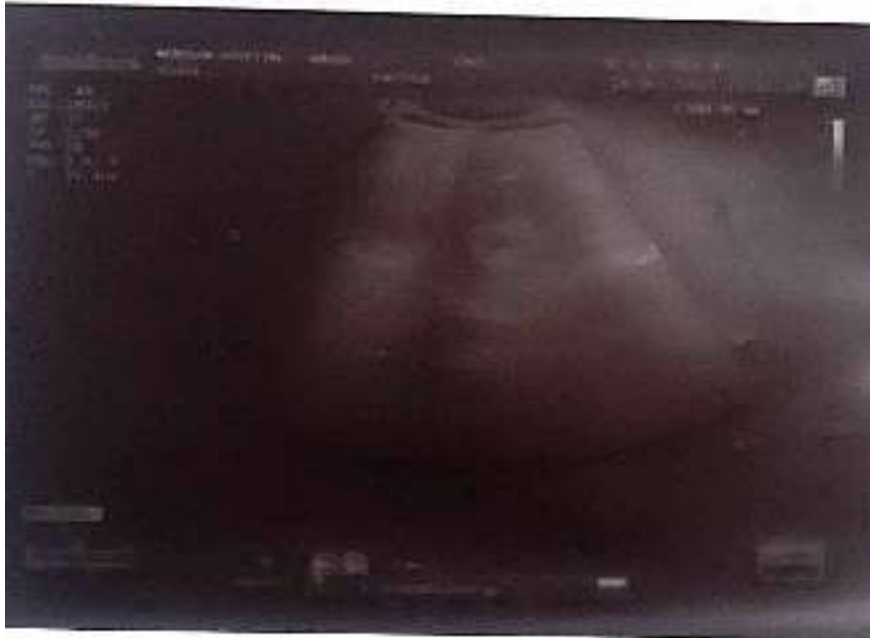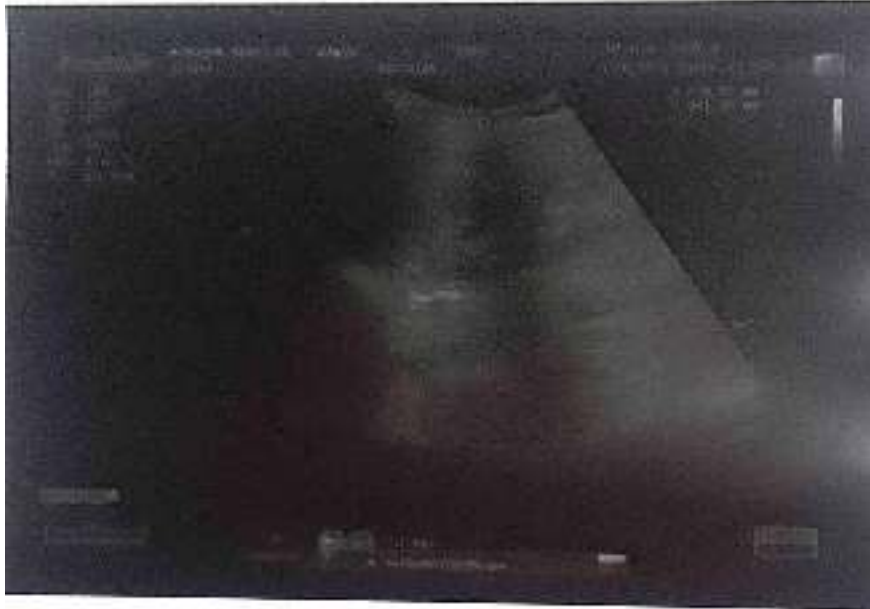UTERUS AND OVARIES: Normal in size and measures- 6.0 x 5.0 cm echotexture. ET- 5 mm.
Bilateral ovaries normal for age.

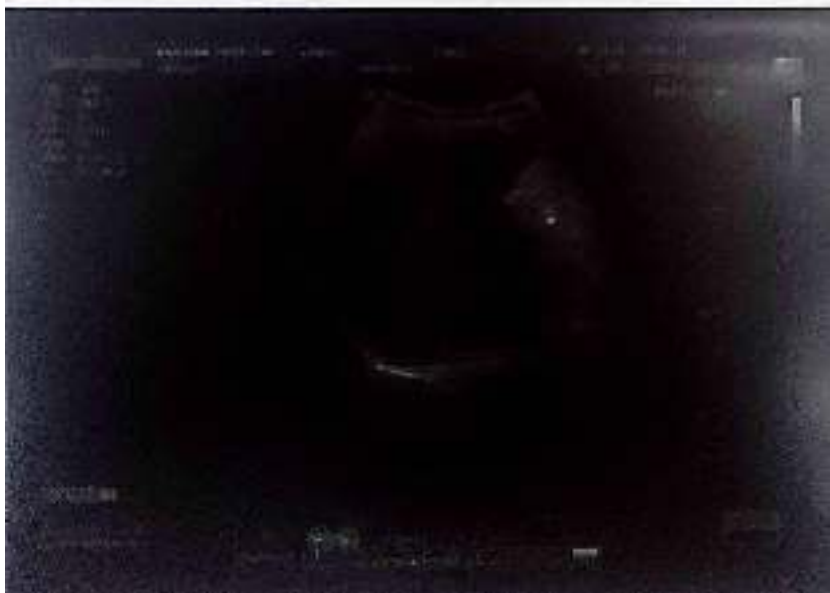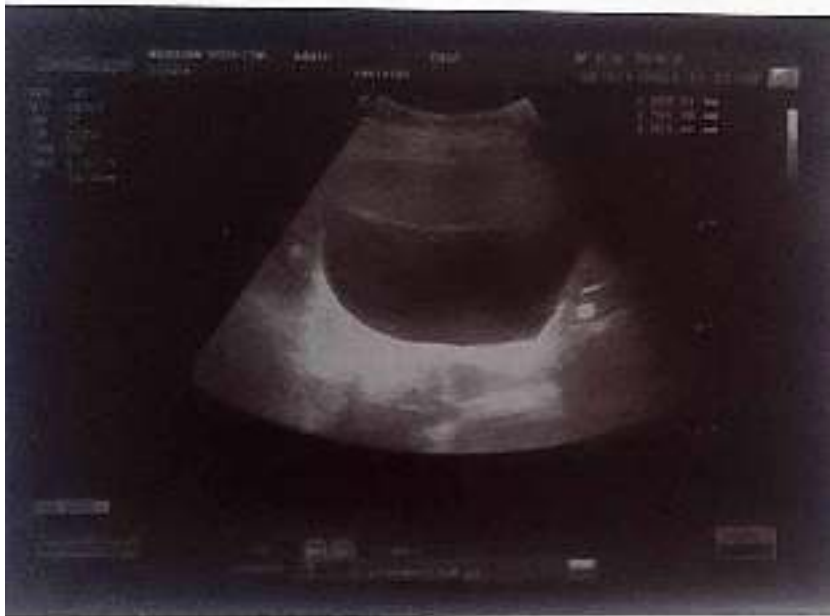No ascites present. No retroperitoneal lymphadenopathy present.

IMPRESSION:

No significant abnormality detected in the visualized abdominal organs.


CONSULTANT RADIOLOGIST,







MURUGAN HOSPITALS

HEALING HANDS



ECHO CARDIOGRAM REPORT

NAME : MS. KARTHIKA.R PATIENT ID : MH20240061463
AGE/SEX : 29-Years / Female IP / OP NO : OP21100685
CONSULTANT : DR. ARUN PRAKASH DATE : 26/10/2024

2D PLAX (mm)

RV - 20 mm
AO - 20 mm
LA - 23 mm

M-Mode (mm)

IVS - 06 mm
PW - 08 mm
LVD - 41 mm
LVS - 23 mm
EF - 74 %
FS - 43 %

COLOR DOPPLER

Normal

DOPPLER (m/sec)

MITRAL E - 0.6 m/s
MITRAL A - 0.4 m/s
PULMONARY - 0.7 m/s
AORTIC - 0.9 m/s
TRICUSPID - 0.6 m/s

IMPRESSION:

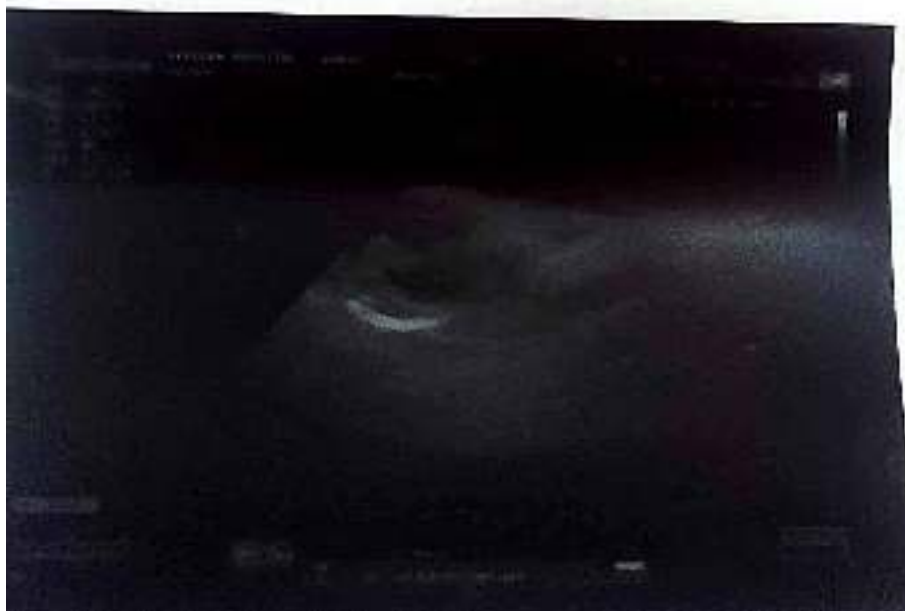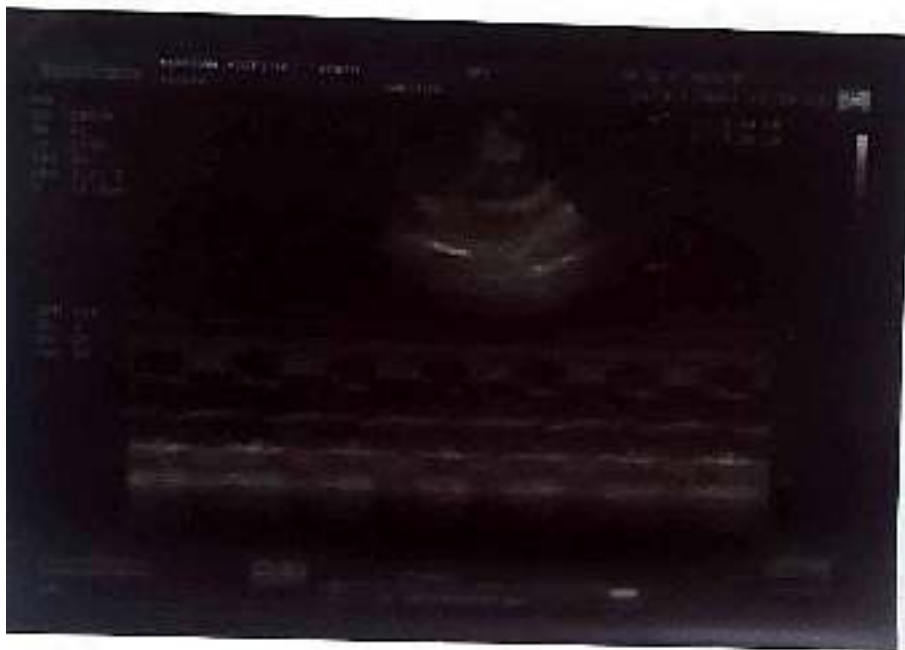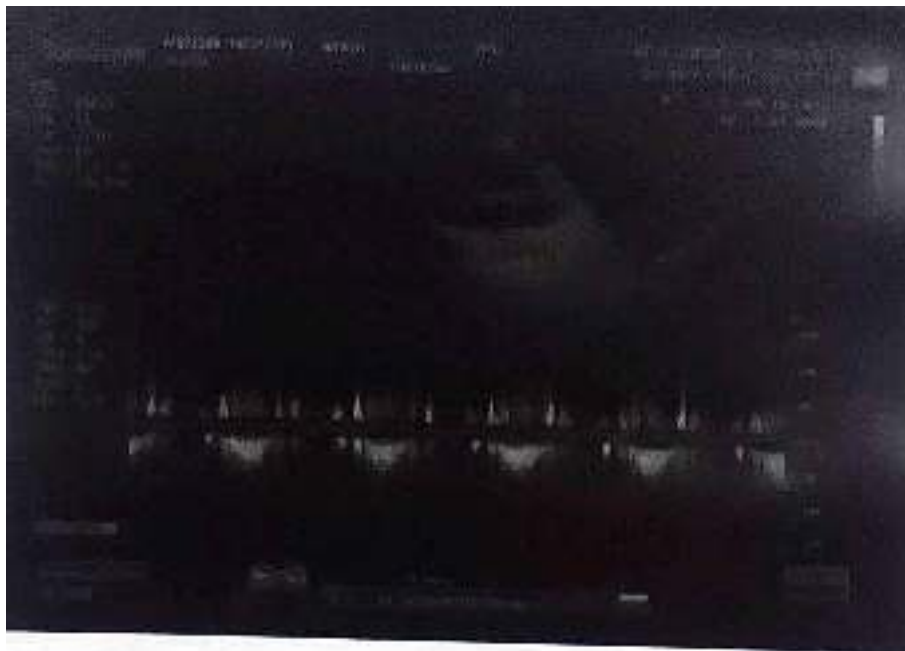No RWMA
Normal biventricular function
No pulmonary hypertension
No pericardial effusion
No clot/ Vegetation.

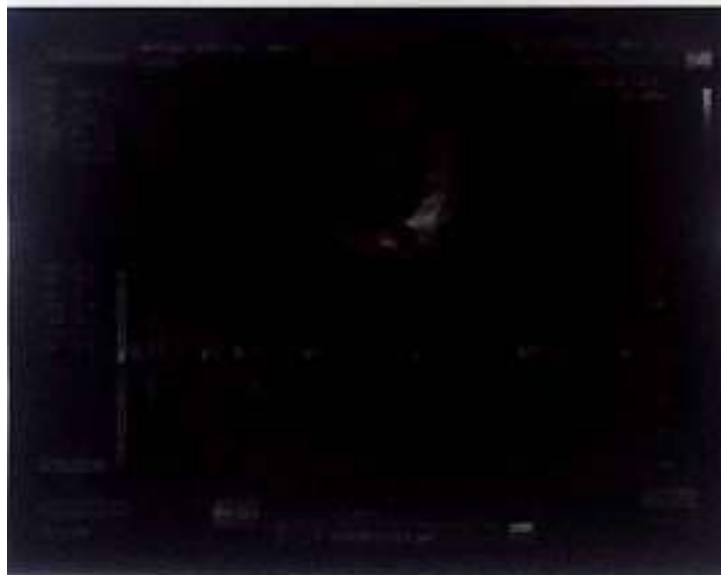
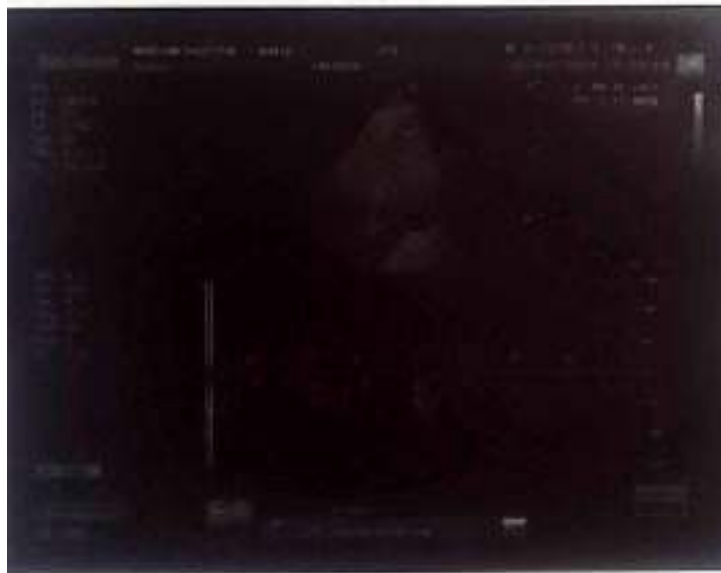
CONSULTANT CARDIOLOGIST

Healing Hearts and Lives

264/125, Kilpauk Garden Road, Kilpauk, Chennai - 600 010.
Phone : +91 44 4644 8989 / 75500 53335 | Email : muruganhosp@gmail.com
Website : www.muruganhospitals.in





ID: 2410260004

Date/Time: 2024-10-26 12:10

Patient ID

Name

Sex

Age

BP

Divisions:

HR

P Dur

PR

int

int

QRS Dur

int

QT

QTc

int

P

QRS

T axis

24 61 52 °

Age

BP

Bed No.

RV5 SV1 amp

RV5+SV1 amp

RV6 SV2 amp

RV5 SV1 amp

RV6 SV2 amp

RV5+SV1 amp

RV6 SV2 amp

RV5+SV1 amp

RV6 SV2 amp

RV5+SV1 amp

RV6 SV2 amp

RV5+SV1 amp

RV6 SV2 amp

RV5+SV1 amp

RV6 SV2 amp

RV5+SV1 amp

RV6 SV2 amp

RV5+SV1 amp

RV6 SV2 amp

RV5+SV1 amp

RV6 SV2 amp

RV5+SV1 amp

RV6 SV2 amp

RV5+SV1 amp

RV6 SV2 amp

RV5+SV1 amp

RV6 SV2 amp

RV5+SV1 amp

RV6 SV2 amp

RV5+SV1 amp

RV6 SV2 amp

RV5+SV1 amp

RV6 SV2 amp

RV5+SV1 amp

RV6 SV2 amp

RV5+SV1 amp

RV6 SV2 amp

RV5+SV1 amp

RV6 SV2 amp

RV5+SV1 amp

RV6 SV2 amp

RV5+SV1 amp

RV6 SV2 amp

RV5+SV1 amp

RV6 SV2 amp

RV5+SV1 amp

RV6 SV2 amp

RV5+SV1 amp

RV6 SV2 amp

RV5+SV1 amp

RV6 SV2 amp

RV5+SV1 amp

RV6 SV2 amp

RV5+SV1 amp

RV6 SV2 amp

RV5+SV1 amp

RV6 SV2 amp

RV5+SV1 amp

RV6 SV2 amp

RV5+SV1 amp

RV6 SV2 amp

RV5+SV1 amp

RV6 SV2 amp

RV5+SV1 amp

RV6 SV2 amp

RV5+SV1 amp

RV6 SV2 amp

RV5+SV1 amp

RV6 SV2 amp

RV5+SV1 amp

RV6 SV2 amp

RV5+SV1 amp

RV6 SV2 amp

RV5+SV1 amp

RV6 SV2 amp

RV5+SV1 amp

RV6 SV2 amp

RV5+SV1 amp

RV6 SV2 amp

RV5+SV1 amp

RV6 SV2 amp

RV5+SV1 amp

RV6 SV2 amp

RV5+SV1 amp

RV6 SV2 amp

Height

Weight

Hospital No.

Minnesota Code

9-4-1 (V3)

cm

kg

Hospital

Diagnosis Info

800. Sinus Rhythm

Normal ECG

RV5 SV1 amp

RV5+SV1 amp

RV6 SV2 amp

RV5 SV1 amp

RV5+SV1 amp

RV6 SV2 amp

RV5 SV1 amp

RV5+SV1 amp

RV6 SV2 amp

RV5 SV1 amp

RV5+SV1 amp

RV6 SV2 amp

RV5 SV1 amp

RV5+SV1 amp

RV6 SV2 amp

RV5 SV1 amp

RV5+SV1 amp

RV6 SV2 amp

RV5 SV1 amp

RV5+SV1 amp

RV6 SV2 amp

RV5 SV1 amp

RV5+SV1 amp

RV6 SV2 amp

RV5 SV1 amp

RV5+SV1 amp

RV6 SV2 amp

RV5 SV1 amp

RV5+SV1 amp

RV6 SV2 amp

RV5 SV1 amp

RV5+SV1 amp

RV6 SV2 amp

RV5 SV1 amp

RV5+SV1 amp

RV6 SV2 amp

RV5 SV1 amp

RV5+SV1 amp

RV6 SV2 amp

RV5 SV1 amp

RV5+SV1 amp

RV6 SV2 amp

RV5 SV1 amp

RV5+SV1 amp

RV6 SV2 amp

RV5 SV1 amp

RV5+SV1 amp

RV6 SV2 amp

RV5 SV1 amp

RV5+SV1 amp

RV6 SV2 amp

RV5 SV1 amp

RV5+SV1 amp

RV6 SV2 amp

RV5 SV1 amp

RV5+SV1 amp

RV6 SV2 amp

RV5 SV1 amp

RV5+SV1 amp

RV6 SV2 amp

RV5 SV1 amp

RV5+SV1 amp

RV6 SV2 amp

RV5 SV1 amp

RV5+SV1 amp

RV6 SV2 amp

RV5 SV1 amp

RV5+SV1 amp

RV6 SV2 amp

RV5 SV1 amp

RV5+SV1 amp

RV6 SV2 amp

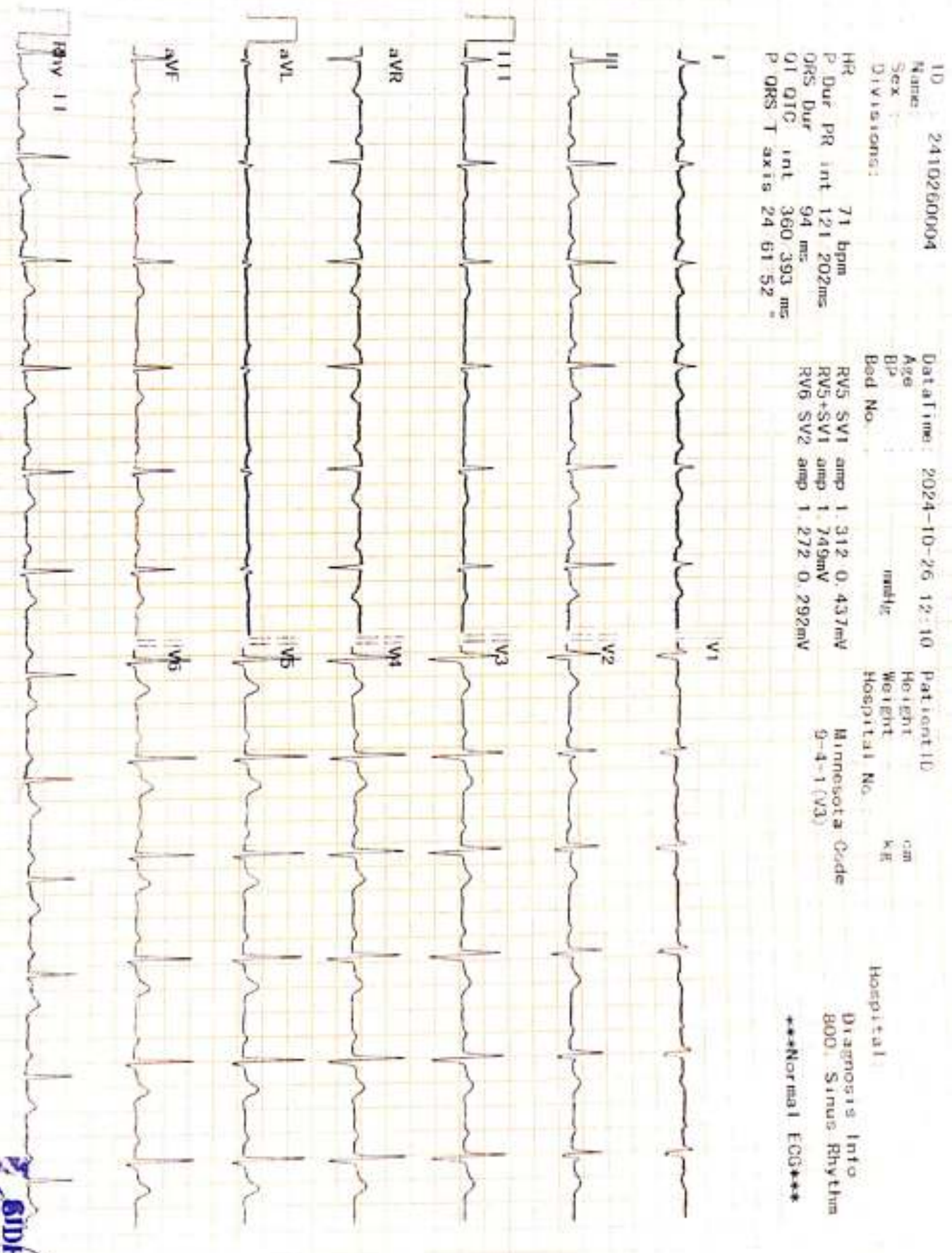
RV5 SV1 amp

RV5+SV1 amp

RV6 SV2 amp

RV5 SV1 amp

RV5+SV1 amp



Diagnosis for reference. ask your doctor to confirm.
 AUTO PRINT 6X2+1R 71bpm 10 mm mV 0.50Hz-25Hz AD 50Hz 25 mm sec Confirmed By

SIDHARTHAN MD
 Consultant Cardiologist
 Reg. No. 62379



MURUGAN HOSPITALS

HEALING HANDS



LAB REPORT

Patient Name : Ms. KARTHIKA.R
Age / Gender : 29-Years / Female
UHID ID : MH20240061463
Doctor Name : Dr. ARUN PRAKASH

OP Report No. : INVA2117757
Bill No. : INV2407713
Sample Date : 26/10/2024 - 09:00 AM
Report Date : 26/10/2024 - 04:02 PM

Test Name	Result	Units	Reference Interval
-----------	--------	-------	--------------------

HAEMATOLOGY

COMPLETE BLOOD CELL COUNT(CBC)

HAEMOGLOBIN	12.6	gms/dl	male : 13.0 - 17.0 female : 12.0 - 15.0
PACKED CELL VOLUME	38.4	%	male : 40 - 50 female : 36 - 46
RBC COUNT	4.52	millions cells/cu.mm	female: 3.8 - 4.8 male : 4.5 - 5.5
TOTAL WBC	5,580	Cells/Cumm	4,000 - 11,000
Differential Count			
NEUTROPHILS	56.7	%	40 - 65
LYMPHOCYTES	36.0	%	30-50
EOSINOPHILS	1.9	%	01-06
MONOCYTES	5.4	%	1-10
BASOPHILS	00	%	0-2
ESR 60 MTS	12	mm	5 - 20
PLATELET COUNT	2.96	Lakhs/cumm	1.5 - 4.5
MCV	84.9	fL	76 - 96
MCH	27.8	pg	27 - 32
MCHC	32.8	gms/dl	30 - 36
BLOOD GROUPING & RH TYPING	" B " POSITIVE		

Page 1 of 4

Healing Hearts and Lives

264/125, Kilpauk Garden Road, Kilpauk, Chennai - 600 010.
Phone : +91 44 4844 8989 / 75500 53335 | Email : muruganhosp@gmail.com
Website : www.muruganhospitals.in



MURUGAN HOSPITALS

HEALING HANDS



LAB REPORT

Patient Name : Ms. KARTHIKAR
Age / Gender : 29-Years / Female
UHID ID : MH20240061463
Doctor Name : Dr. ARUN PRAKASH

OP Report No. : INVA2117757
Bill No. : INV2407713
Sample Date : 26/10/2024 - 09:00 AM
Report Date : 26/10/2024 - 04:02 PM

Test Name	Result	Units	Reference Interval
-----------	--------	-------	--------------------

BIO CHEMISTRY

BLOOD SUGAR FASTING	104	mgs/dl	70-110
BLOOD SUGAR POST PRANDIAL	108	mgs/dl	80- 160
SERUM CREATININE	0.8	mg/dl	0.6-1.4
SERUM URIC ACID	4.1	mg/dl	male 3.1-7.0 , female 2.5-5.6
LIPID PROFILE			
TOTALCHOLESTEROL	232	mg/dl	< 200
TRIGLYCERIDE	80	mg/dl	< 150
HDL	48	mg/dl	35 - 80
VLDL	16	mg/dl	2 to 30
LDL	168	mg/dl	<130
CHOLESTEROL/ HDL RATIO	4.8	mg/dl	



LAB REPORT

Patient Name : Ms. KARTHIKA,R
Age / Gender : 29-Years / Female
UHID ID : MH20240061463
Doctor Name : Dr. ARUN PRAKASH

OP Report No. : INVA2117757
Bill No. : INV2407713
Sample Date : 26/10/2024 - 09:00 AM
Report Date : 26/10/2024 - 04:02 PM

Test Name	Result	Units	Reference Interval
-----------	--------	-------	--------------------

LIVER FUNCTION TEST

BILLIRUBIN(TOTAL)	0.5	mg/dl	0.0 -1.0
BILLIRUBIN(DIRECT)	0.2	mg/dl	0.1 - 0.30
BILLIRUBIN(INDIRECT)	0.3	mg/dl	0.2-0.8
SGOT	35	IU/L	0-38
SGPT	<u>53</u>	IU/L	0.0-40
ALKALINE PHOSPHATASE	<u>207</u>	IU/L	40-140 4-6Years 93-309 13-15Years 74-390
TOTAL PROTEIN	7.8	gm/dl	6.6-8.7
ALBUMIN	3.9	gm/dl	3.5 - 5.5
GLOBULIN	<u>3.9</u>	gm/dl	2.0-3.5
AG RATIO	1.0		
GAMMA G T	163.9	U/L	< 55 U/L
BLOOD UREA NITROGEN	7.4	mg/dl	7-21
HBA1C	5.7	%	normal: <6.0 good control: 6.1-7.0 fair control: 7.1- 8.0 poor control:8.1 -10.0 unsatisfactory: >10.0



LAB REPORT

Patient Name : Ms. KARTHIKA.R
Age / Gender : 29-Years / Female
LHiD ID : MH20240061463
Doctor Name : Dr. ARUN PRAKASH

OP Report No. : INVA2117757
Bill No. : INV2407713
Sample Date : 26/10/2024 - 09:00 AM
Report Date : 26/10/2024 - 04:02 PM

Test Name	Result	Units	Reference Interval
-----------	--------	-------	--------------------

CLINICAL PATHOLOGY

URINE SUGAR (F)	NIL		
URINE SUGAR (PP)	NIL		
URINE ROUTINE			
COLOUR	PALE YELLOW		
APPEARANCE	CLEAR		
REACTION	ACIDIC		
SUGAR	NIL		
ALBUMIN	NIL		
DEPOSITES			
FUS CELLS	2 - 3	/ HPF	
EPI CELLS	1 - 2	/ HPF	
RBC COUNT	NIL	/ HPF	
CAST	NIL		
CRYSTALS	NIL		
OTHERS	NIL		

KAVIYARASAN

Verified by

*** End of Report ***

Authorized Signature



MURUGAN HOSPITALS

HEALING HANDS



LAB REPORT

Patient Name : Ms. KARTHIKA.R
Age / Gender : 29-Years / Female
UHID ID : MH20240061463
Doctor Name : Dr. ARUN PRAKASH

OP Report No. : INVA2117757
Bill No. : INV2407713
Sample Date : 26/10/2024 - 09:00 AM
Report Date : 26/10/2024 - 11:49 PM

Test Name	Result	Units	Reference Interval
-----------	--------	-------	--------------------

ENDOCRINOLOGY

T3	0.937	ng/ml	0.52-1.85
T4	8.163	ug/dl	5.0-13.0 ug/dl
TSH	0.702	uIU/ml	0.39 - 6.16 uIU/ml

KAVIYARASAN

Verified by

*** End of Report ***

Authorized Signature

Healing Hearts and Lives



MURUGAN HOSPITALS
HEALING HANDS



NAME : MS. KARTHIKA.R
AGE / SEX : 29Y/FEMALE
CONSULTANT: DR.ARUN PRAKASH

UHID : MH20240061463
OP/IP : OP
DATE : 26.10.2024

CHEST XRAY PA VIEW

- Trachea is in midline.
- Hila appear Normal.
- Mediastinal shadow appears normal.
- Costophrenic&Cardiophrenic angles appear free.
- Cardiothoracic ratio is within normal limits.
- Lungs fields appear clear
- Bony thorax and soft tissue appear normal

IMPRESSION:

- **No significant abnormality noted.**

CONSULTANT RADIOLOGIST



264/125, Kilpauk Garden Road, Kilpauk, Chennai - 600 010.

☎ : +91 44 46448989 / 7550053335
email : muruganhospitals@gmail.com