

आयकर विभाग
INCOME TAX DEPARTMENT



भारत सरकार
GOVT. OF INDIA

MUDDALA PRASANTHI
SUDHAKAR MUDDALA
24/08/1984



Permanent Account Number

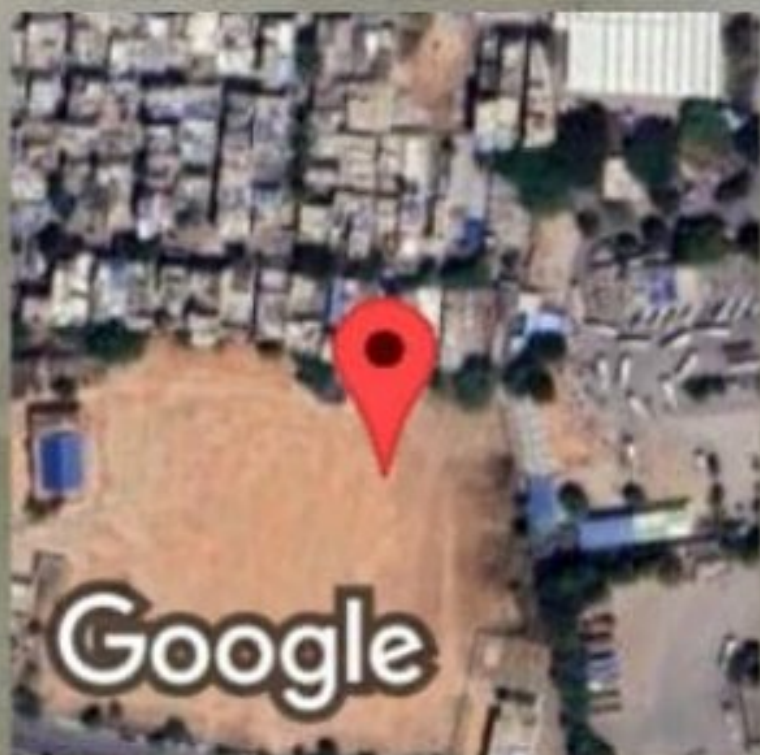DBTPM0081E

M. Prasanthi

Signature



GPS Map Camera



Ananthapur, Andhra Pradesh, India

13-3-187, Adimurthy Colony, Kamala Nagar, Ananthapur,


Anantapur, Andhra Pradesh 515001, India

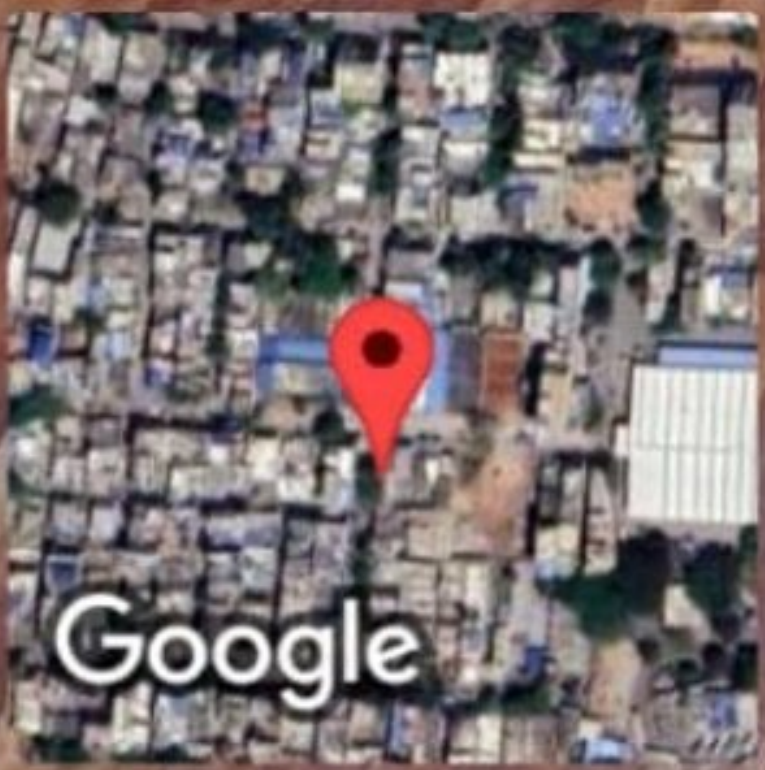Lat 14.685002°

Long 77.599013°

09/03/24 08:35 AM GMT +05:30



 **GPS Map Camera**

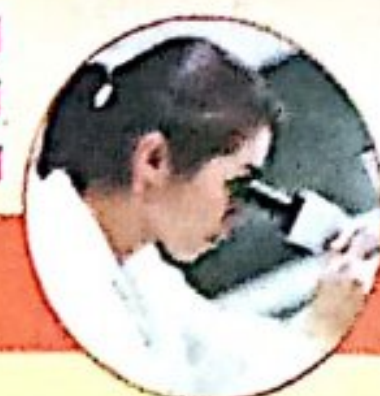

Anantapur, Andhra Pradesh, India
MHPX+GG7, Opp. Balaji Kalyana Mandapam Reliance Smart Road, Azad Nagar, Srinivas Nagar, Anantapur, Andhra Pradesh 515001, India
Lat 14.6863°
Long 77.598807°
09/03/24 08:36 AM GMT +05:30



AMRUTHA SAI DIAGNOSTIC CENTRE

email : amruthasailab@gmail.com



ISO.9001 : 2015 Certificate Number : 1080551126

Name :- Mrs M Prashanthi

Age/Sex :- 39 Y/Female Date :- 09-02-2024

Ref.by :- Mediwheel

ID.No:- D4/2024, BOBE-11597 , , BC-284938

EMPLOYEE MEDICAL CHEK UP FORM

Physical Examination :-

Height :- 159 cms.

Weight :- 82 kgs.

Abdomen (CMS) : 97 cms

Chest Expir(CMS):- 86

Chest Insp(CMS) : 90

Body mass index(BMI) :- 32.4

Pulse Rate :- 74 minute. (Regular / Abnormal)

Skin :- Normal Open Lesions :- Nil

Oral Hygeine : Normal

Complaints if Any :- Nil

Family History :- Nil

Complaints if Any :- Nil

Systemic Examination (Abnormality - if Yes Please Explain) :-

CVS - Yes / No

CNS - Yes/ No

Gi Tract - Yes/No

Abdomen - Yes/ No

Respiratory Tract - Yes/ No

INVESTIGATIONS : (N= Normal, R= See Report)

Complete Blood Picture With ESR = Normal

Complete Urine Examination = Normal

FBS, PLBS = Normal

USG = Normal

Chest X-Ray = Normal

* ECG = Normal

* LFT = Normal

* Cholesterol = Normal

* 2D ECHO = Normal

Diagnosis (If Any) :- Nil

RECOMMENDATIONS / IMPRESION :- Nil

PHYSICIAN SIGNATURE
Dr. V. Narayanappa,
M.B.B.S,FCGP.
PHYSICIAN & SURGEON
Regd.No. 88543
Authorised Doctor,
For State Bank of India
AMRUTHA SAI

Under AP Govt. Regd. Diagnostic Centre R.No.860/2022

Genuineness is our gene



AMRUTHA SAI DIAGNOSTIC CENTRE



email : amruthasallab@gmail.com

ISO.9001 : 2015 Certificate Number : 1080551126

Patient Name : Mrs M Prashanthi

Sex : Female Age : 39 Yrs

Id.No : 04/24

Bill Date : 09-03-2024

Report Date : 09-03-2024

Ref. by : Mediwheel

Address : A T P

LAB REPORT

Blood For :-

Parameter	Findings	Reference Range
Complete Haemogram (CBP) :-		
Haemoglobin % (C M G)	: 10.6 gm %	F : 11.0 - 16.0 gm %
Total WBC Count	: 12100 ce/cu mm	A : 4000 - 11000 ce/cu mm
Differential WBC Count	: Neutrophils - 40 % Lymphocytes - 41 % Eosinophils - 18 % Monocytes - 01 % Basophils - 00 %	45 - 65 % 25 - 45 % 01 - 06 % 02 - 08 % 00 - 01 %
E S R (Westergren Method)	: 25 mm/ 1 hr	F : 02 - 20 mm/ 1 hr
RBC Count	: 3.9 mill/cu mm	F : 3.5 - 5.5 mill/cu mm
Platelet Count	: 3.88 Lach/cu mm	1.5 - 4.0 Lach/cu mm
Packed Cell Volume (PCV)	: 43.1 %	F : 36 - 47 %
Mean Corpuscular Volume (MCV)	: 82.2 fl	82 - 92 fl
Mean Corpuscular Haemoglobin (MCH)	: 27.9 pg	27 - 32 pg
Mean Corpuscular Haemoglobin Concentration (MCHC)	: 30.5 %	32 - 36 %
Blood Group & Rh Type	: "O" Positive(+Ve)	

TEST NAME	METHOD	VALUE	UNITS
GLYCOSYLATED HAEMOGLOBIN (Hb A1 c) %	H.P.L.C	6.43	%

Bio.Ref.Interval. :-

Bio.Re.Interval. : As Per ADA Guidelines

Below 5.7 %	: Normal
5.7 % - 6.4 %	: Pre Diabetic
> = 6.5 %	: Diabetic

Guidance For Known Diabetics

BELOW 6.5 %	- Good Control
6.5 % - 7.0 %	- Fair Control
7.0 % - 8.0 %	- Unsatisfactory Control
> 8 %	- Poor Control

Method : Fully Automated H.P.L.C method.

@ Suggested clinical Correlation, If there is need, kindly discuss.

S. Vijaya Lakshmi
LAB INCHARGE

S. Vijaya Lakshmi
M.Sc (Biochemistry)

Under AP Govt. Regd. Diagnostic Centre R.No.860/2022

Genuineness is our gene



AMRUTHA SAI DIAGNOSTIC CENTRE

email : amruthasailab@gmail.com



ISO.9001 : 2015 Certificate Number : 1080551126

Patient Name : Mrs M Prashanthi

Sex : Female Age : 39 Yrs

Id.No : 04/24

Bill Date : 09-03-2024

Report Date : 09-03-2024

Ref. by : Mediwheel

Address : A T P

LAB REPORT

Blood For :-

Parameter	Findings	Reference Range
LIPID PROFILE :-		
Cholesterol Total	: 180 mg/dl	150 - 260 mg/dl
H D L Cholesterol	: 35 mg/dl	F : 45 - 65 mg/d
L D L Cholesterol	: 101 mg/dl	66 - 178 mg/dl
V L D L Cholesterol	: 44 mg/dl	5 - 40 mg/dl
Triglycerides	: 195 mg/dl	36 - 165 mg/dl
Fasting Blood Sugar	: 105 mg/dl	65 - 110 mg/dl
Post Prandial Blood Sugar	: 159 mg/dl	80 - 160 mg/dl

Renal Function Test (RFT) :-

B U N	: 11 mg/dl	7 - 18 mg/dl
Blood Urea	: 25 mg/dl	15 - 45 mg/dl
Serum Creatinine	: 1.0 mg/dl	0.7 - 1.4 mg/dl
Serum Uric Acid	: 4.5 mg/dl	3.0 - 5.7 mg/dl

LIVER FUNCTION TEST (LFT) :-

Bilirubin Total	: 0.5 mg/dl	0.1 - 1.0 mg/dl
Bilirubin Direct	: 0.11 mg/dl	0.0 - 0.25 mg/dl
Bilirubin Indirect	: 0.4 mg/dl	0.2 - 0.8 mg/dl
Total Proteins	: 6.8 gm/dl	6.0 - 8.0 gm/dl
Albumin	: 4.1 gm/dl	3.7 - 5.3 gm/dl
Globulins	: 3.4 gm/dl	2.5 - 4.5 gm/dl
A / G Ratio	: 2.0 : 1	1.2 - 2.5 : 1
S G O T (A S T)	: 20 IU/L	Upto - 40 IU/L
S G P T (A L T)	: 28 IU/L	Upto - 47 IU/L
Alkaline Phosphatase (ALP)	: 174 IU/L	A : 100 - 290 IU/L
Gamma Glutamyl Transferase (GGT)	: 22 IU/L	F : Upto - 30 IU/L

@ Suggested clinical Correlation, If there is need, kindly discuss.

S. Vijaya Lakshmi
LAB INCHARGE
S. Vijaya Lakshmi
M.Sc (Biochemistry)

Under AP Govt. Regd. Diagnostic Centre R.No.860/2022

Genuineness is our gene



AMRUTHA SAI DIAGNOSTIC CENTRE

email : amruthasailab@gmail.com



ISO.9001 : 2015 Certificate Number : 1080551126

Patient Name : Mrs M Prashanthi

Sex : Female Age : 39 Yrs

Id.No : 04/24

Bill Date : 09-03-2024

Report Date : 09-03-2024

Ref. by : Mediwheel

Address : A T P

LAB REPORT

Complete Urine Analysis(C U A) :-

Physical Examination :-

Colour : Yellow
Reaction : Acidic
Sp.Gravity : 1.018

Transparency : Clear
Sediment : NIL
pH : 6.5

Chemical Examination :-

Sugar : Absent
Bile Salts : Absent
Urobilinogen : Normal
Blood : Absent

Proteins : Traces
Bile Pigments : Absent
Ketone Bodies : Negative

Microscopic Examination :-

Pus Cells : 6 - 8 /hpf
RBC's : Absent
Crystals : Absent
Bacteria : Absent

E.P.Cells : 8 - 10 /HPF
Casts : Absent
Deposits : Absent

@ Suggested clinical Correlation, If there is need, kindly discuss.

S. Vijaya Lakshmi
LAB INCHARGE

S. Vijaya Lakshmi
(M.Sc (Biochemistry))

Note:- **Amrutha Sai Diagnostic Centre . (Fully Automated A/C Laboratory)**
***** Since - 25 Years *****

Opp.Balaji Kalyana Mantapam, Near RTC Bus Stand, Reliance Mart Road,
Srenivasa Nagar, ANANTHAPURAM. CELL - 86 88 984900.

Under AP Govt. Regd. Diagnostic Centre R.No.860/2022

Genuineness is our gene



AMRUTHA SAI DIAGNOSTIC CENTRE

email : amruthasailab@gmail.com



ISO.9001 : 2015 Certificate Number : 1080551126

Patient Name : Mrs M Prashanthi

Sex : Female Age : 39 Yrs

Id.No : 04/24

Bill Date : 09-03-2024

Report Date : 09-03-2024

Ref. by : Mediwheel

Address : A T P

XRAY-CHEST (PA) VIEW

- Trachea is central
- Both th lung fields appear normal.
- Hilar shadows are with in normal limits.
- Pulmonary vasculatures are normal.
- Cardia is normal in size.
- Both domes of the diaphragm are smooth.
- Both costophrenic recesses are clear.
- Visualized bones and soft tissue shows appear normal.

IMPRESSION :- NORMAL X-RAY.

@ Suggested clinical Correlation, If there is need, kindly discuss.

10/3
D.K. RADHAKRISHNAN, MD
Specialist in Ultrasonography
Radio Diagnosis & C.T. Scan
Asst. Surgeon
Govt. Medical College &
General Hospital
ANANTHAPURAM

Note:- Amrutha Sai Diagnostic Centre . (Fully Automated A/C Laboratory)

***** Since - 25 Years *****

Opp. Balaji Kalyana Mantapam, Near RTC Bus Stand, Reliance Mart Road,
Srenivasa Nagar, ANANTHAPURAM. CELL - 86 88 984900.

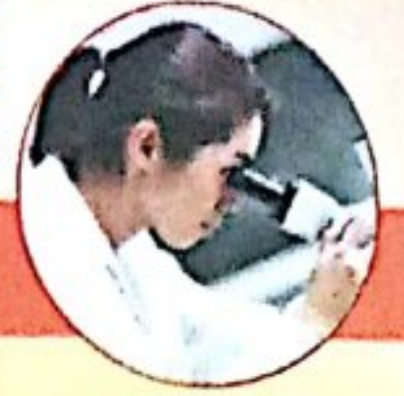Under AP Govt. Regd. Diagnostic Centre R.No.860/2022

Genuineness is our gene



AMRUTHA SAI DIAGNOSTIC CENTRE

email : amruthasailab@gmail.com



ISO.9001 : 2015 Certificate Number : 1080551126

Patient Name	: MRS. PRASHANTHI	Investigation Date	: Mar 09, 2024, 01:40 p.m.
Age / Sex	: 39 years / Female	Reporting Date	: Mar 09, 2024, 02:12 p.m.
Sample ID	: 006306924		
Ref. By	: AMRUTHA SAI DIAGNOSTIC CENTER		

PAP SMEAR

Cytopathology

Specimen Adequacy

Adequate

Epithelial component

Superficial squamous cells and intermediate squamous cells show benign cytomorphology. Also seen few dysplastic squames with mild irregular nuclear borders and moderate eosinophilic cytoplasm.

Glandular component

Present

Background

Polymorphs seen

Organisms

Nil

Impression

Low grade squamous intraepithelial lesion (LSIL)

Note: Suggested biopsy for confirmation

Dr. E. Divya MD
Consultant Pathologist

Under AP Govt. Regd. Diagnostic Centre R.No.860/2022 Page 1 of 1

Genuineness is our gene



PT NAME: MRS M PRASHANTHI

AGE/SEX: 34 Y/F

REF.BY: DR AMRUTH SAI DIAGNOSTICS

DATE: 09.03.2024

ULTRASOUND SCANNING OF WHOLE ABDOMEN

FINDINGS:

- LIVER** : Normal in size with normal echotexture, no focal lesions were seen
- PORTAL VEIN** : Normal
- GB** : Well distended, wall thickness within normal limit, no calculi /no sludge noted.
- CBD** : Normal
- SPLEEN** : Normal in size and echo texture, no focal lesions were seen
- PANCREAS** : Normal in size and echo texture, no focal lesions were seen
- PARAAORTIC & PARA ILIAC REGION:** Nil significant
- RIGHT KIDNEY:** Measures: 9.3 x 3.8 cm
Echogenicity: Normal
Hydronephrosis: Nil
Calculi: Nil
- LEFT KIDNEY** : Measures: 10.3 x 4.5 cm
Echogenicity: Normal
Hydronephrosis: Nil
Calculi: Nil
- URINARY BLADDER** : Well distended. Normal wall thickness.
- UTERUS** : Normal in size measuring 8.4 x 4.5 x 5.2 cm. ET is 6.0 mm. **E/o left lateral myometrial fibroid measuring 21 x 19 mm.**
- RIGHT OVARY** : Normal in size 3.5 x 2.4 cm, no adnexal mass / lesions
- LEFT OVARY** : Normal in size 2.6 x 1.8 cm, no adnexal mass / lesions
- FREE FLUID** : Nil
- No bowel wall thickening.

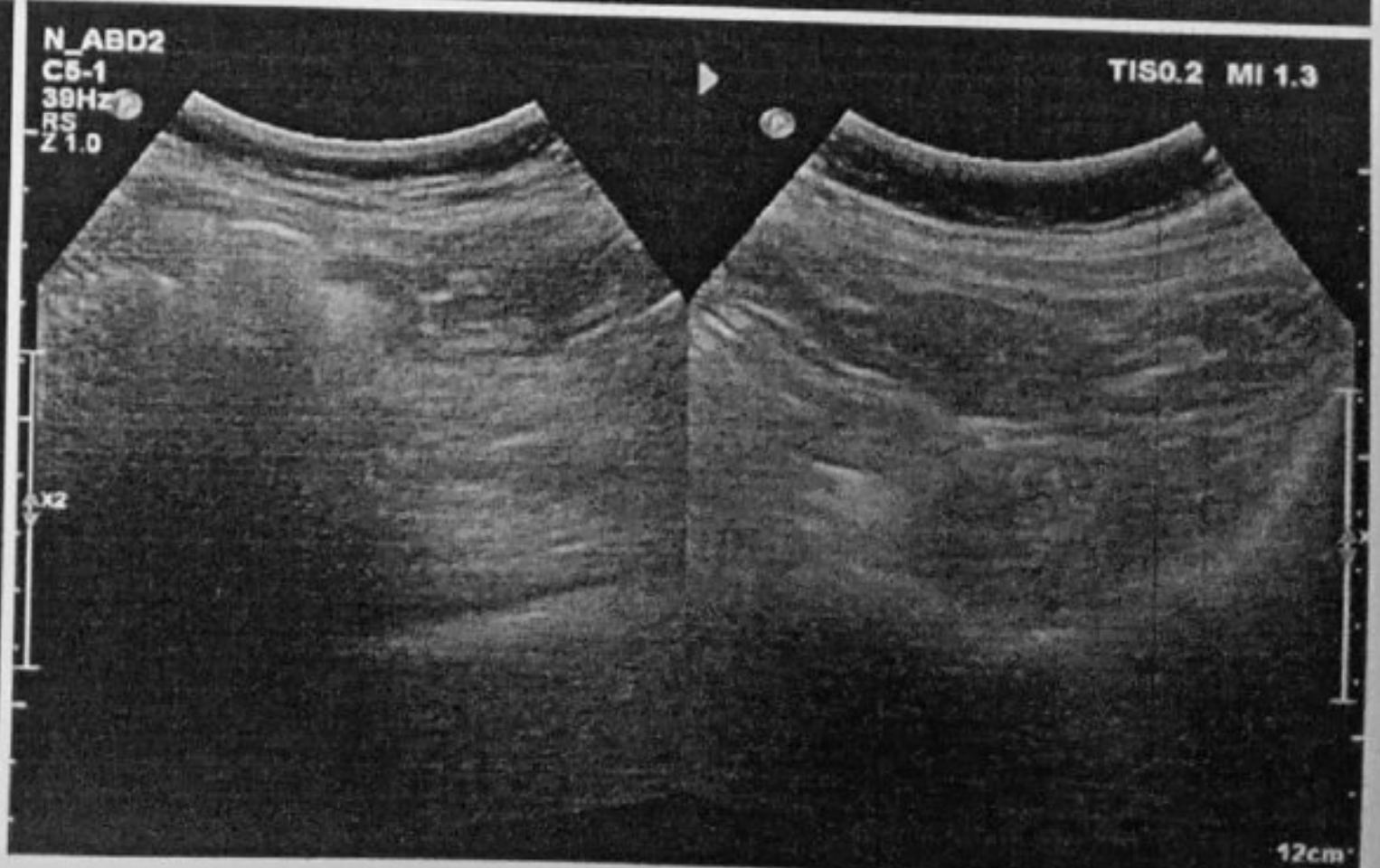
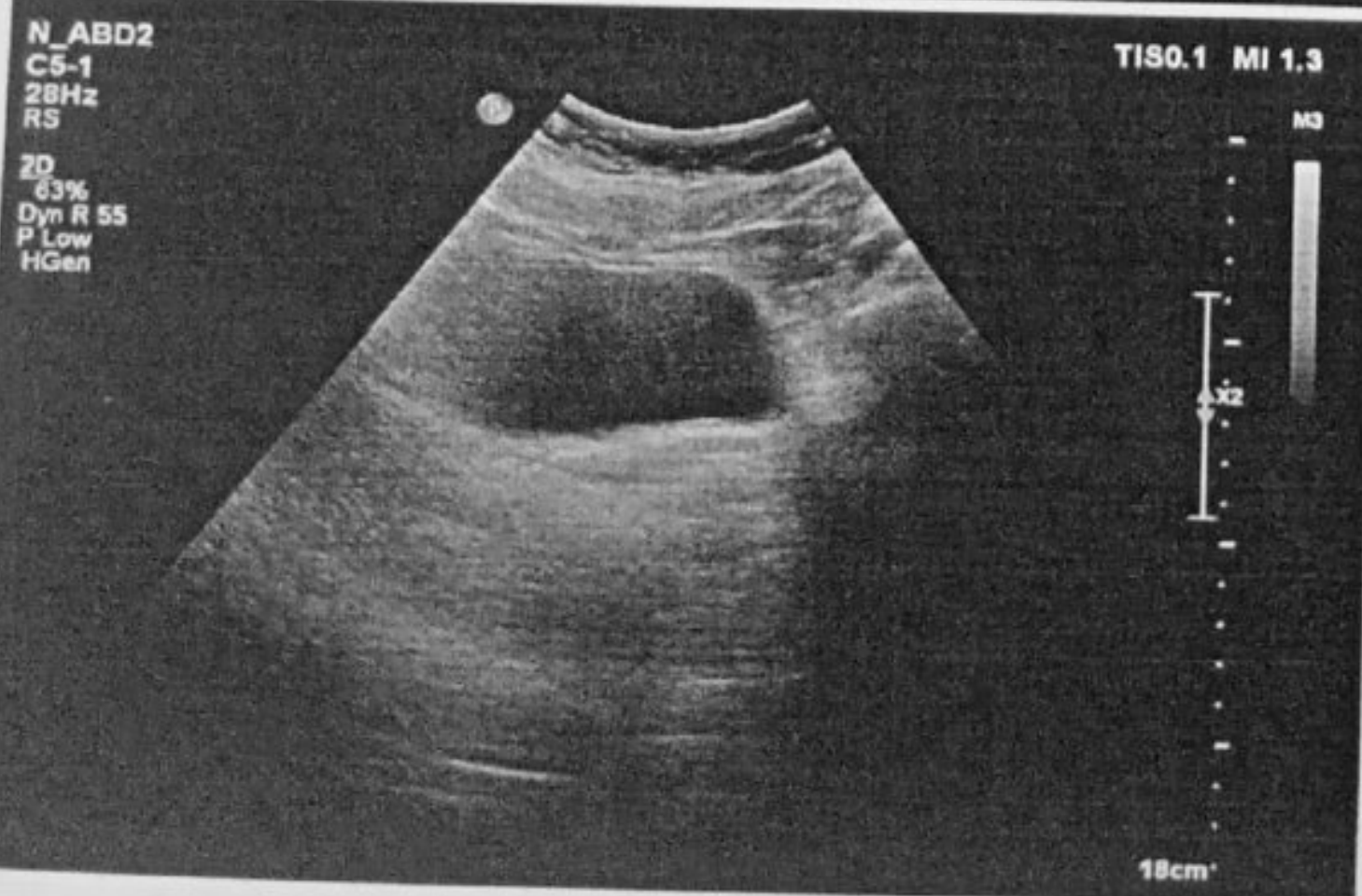
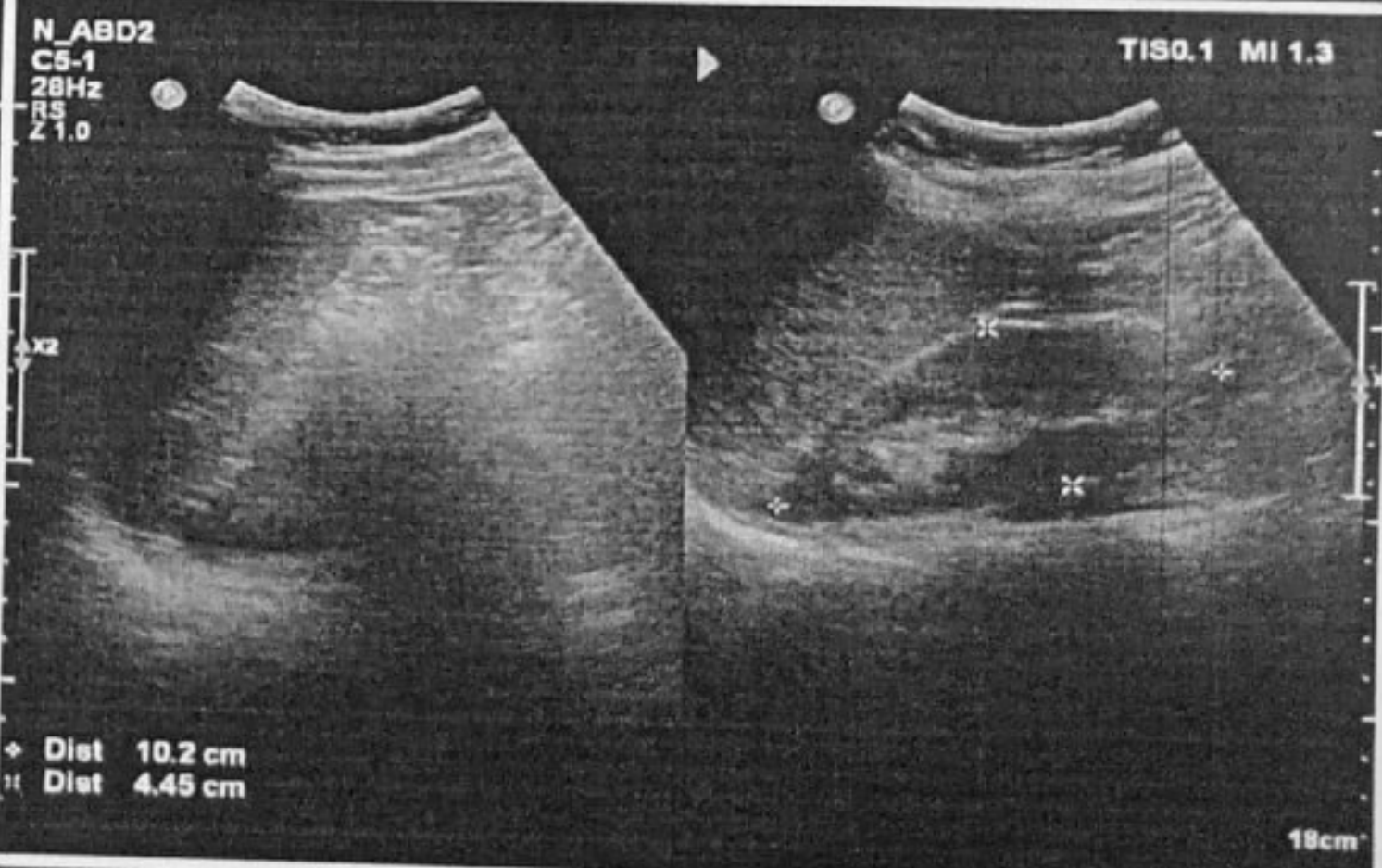
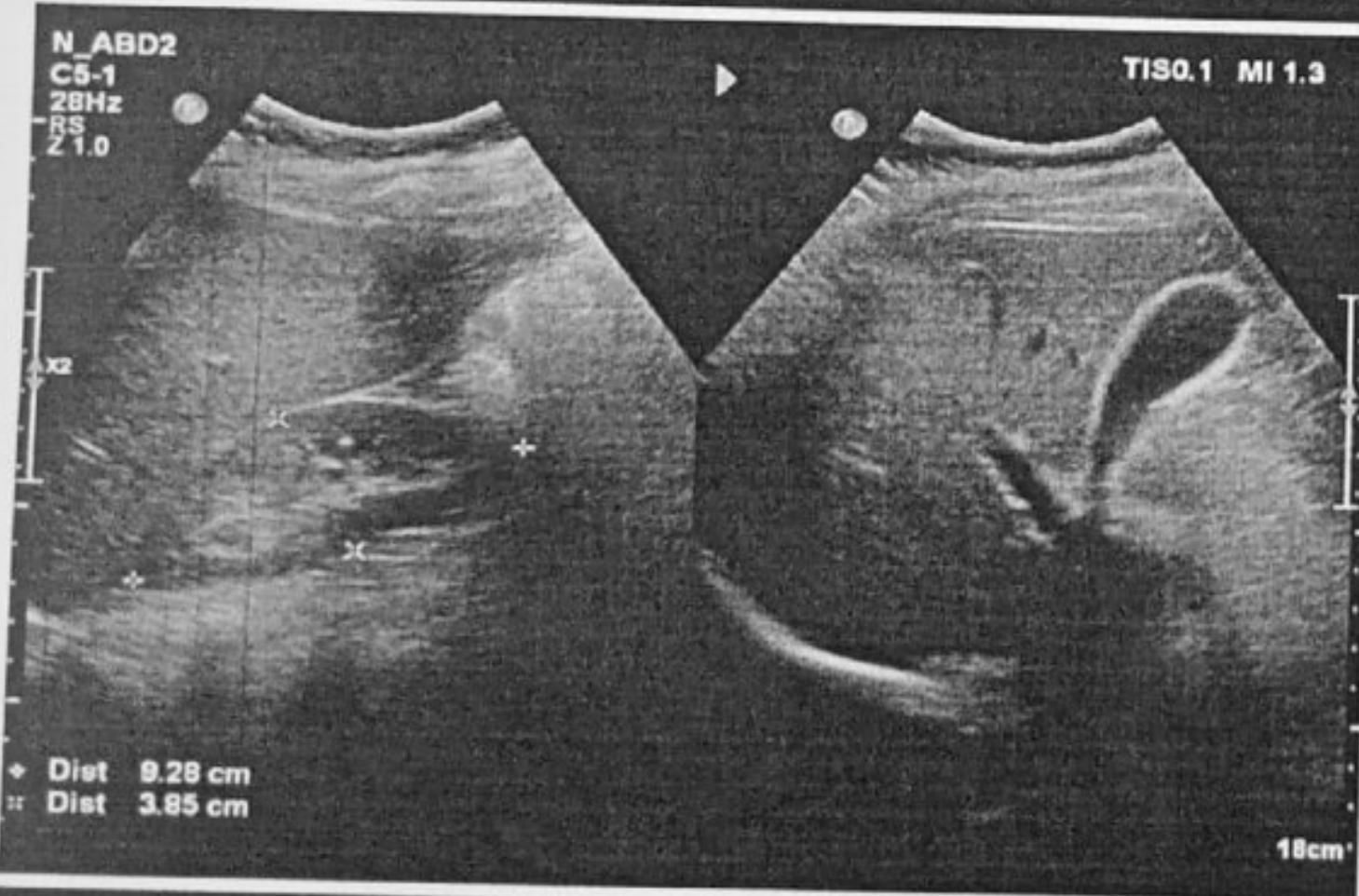
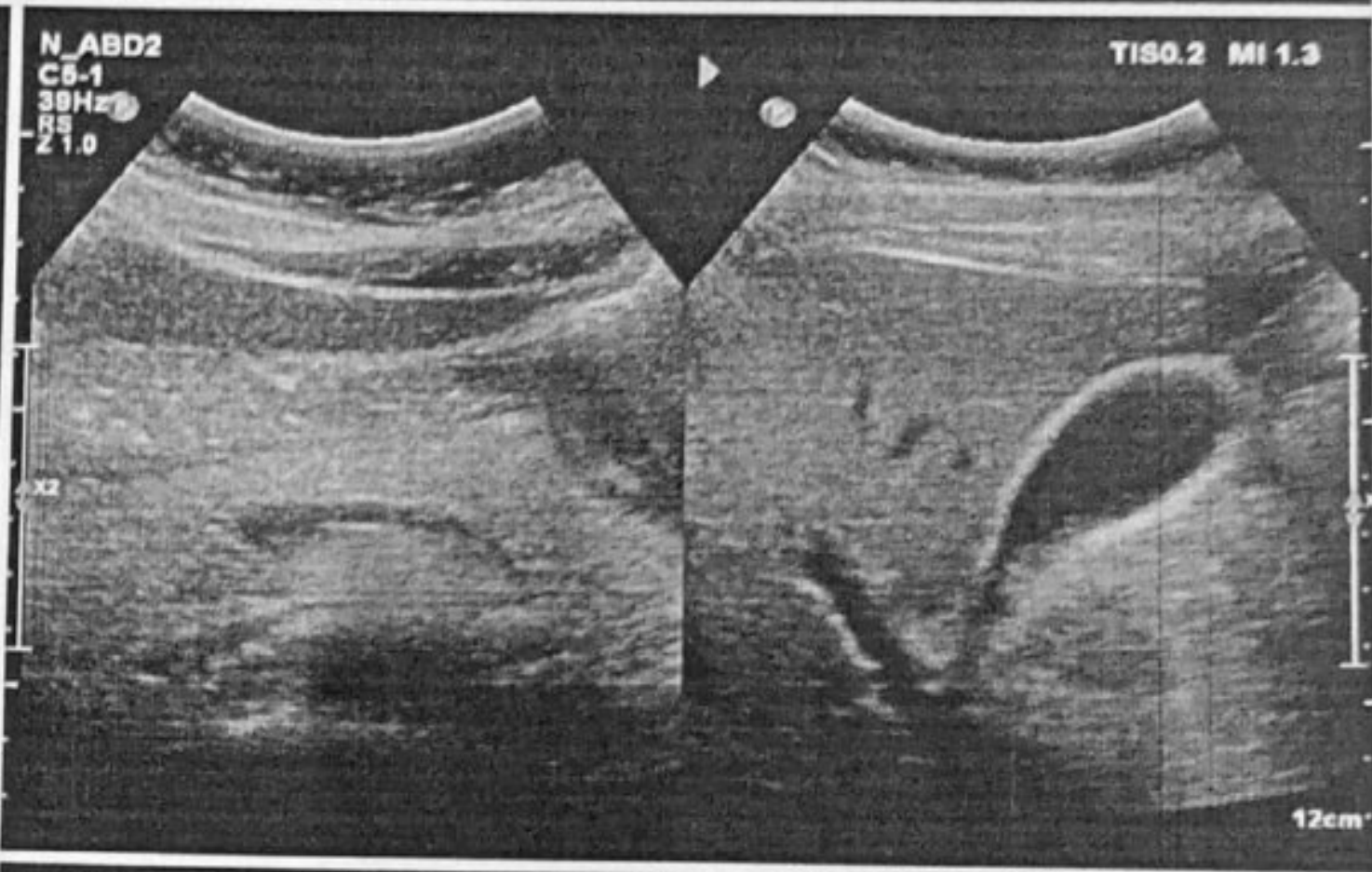
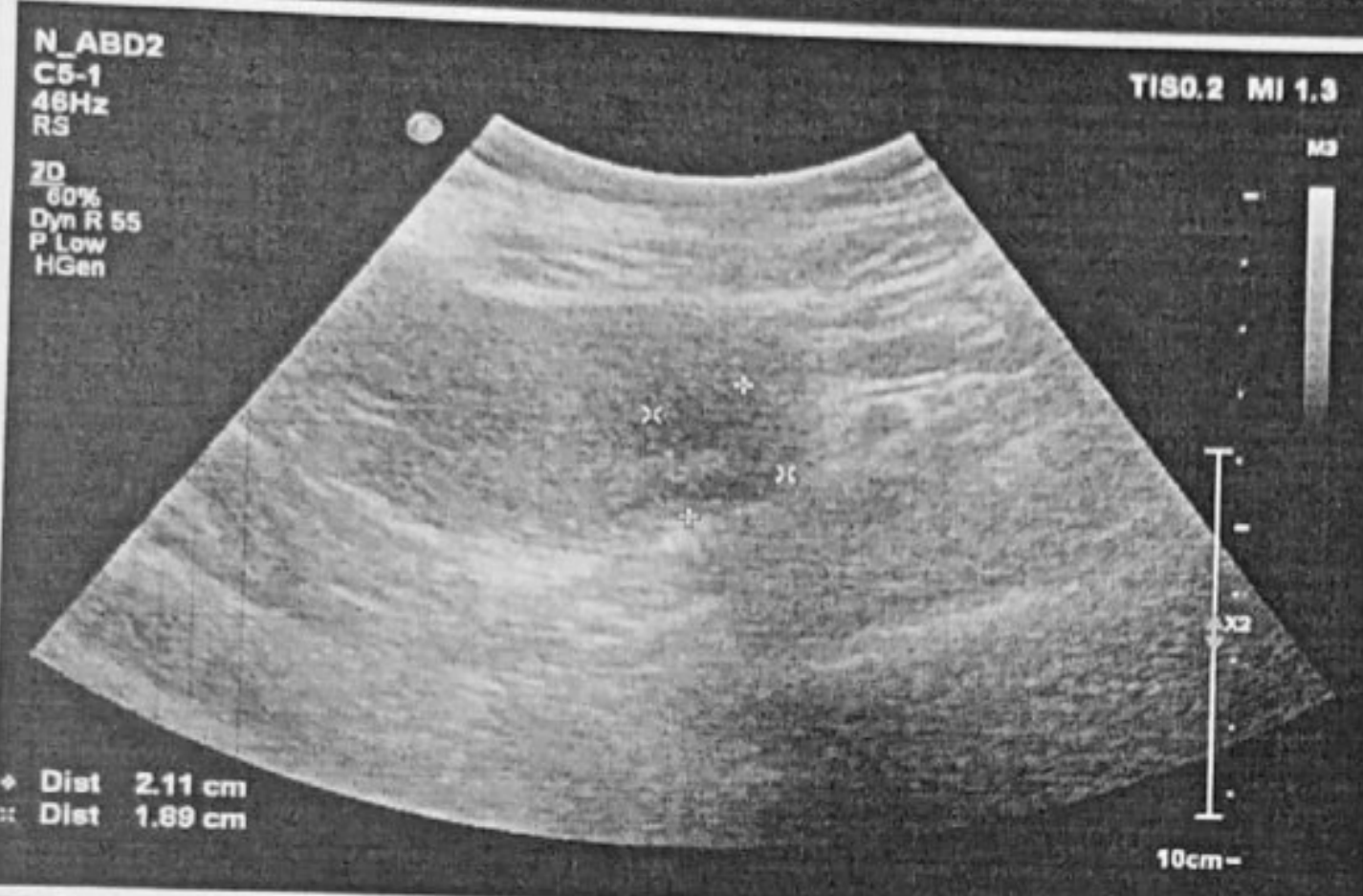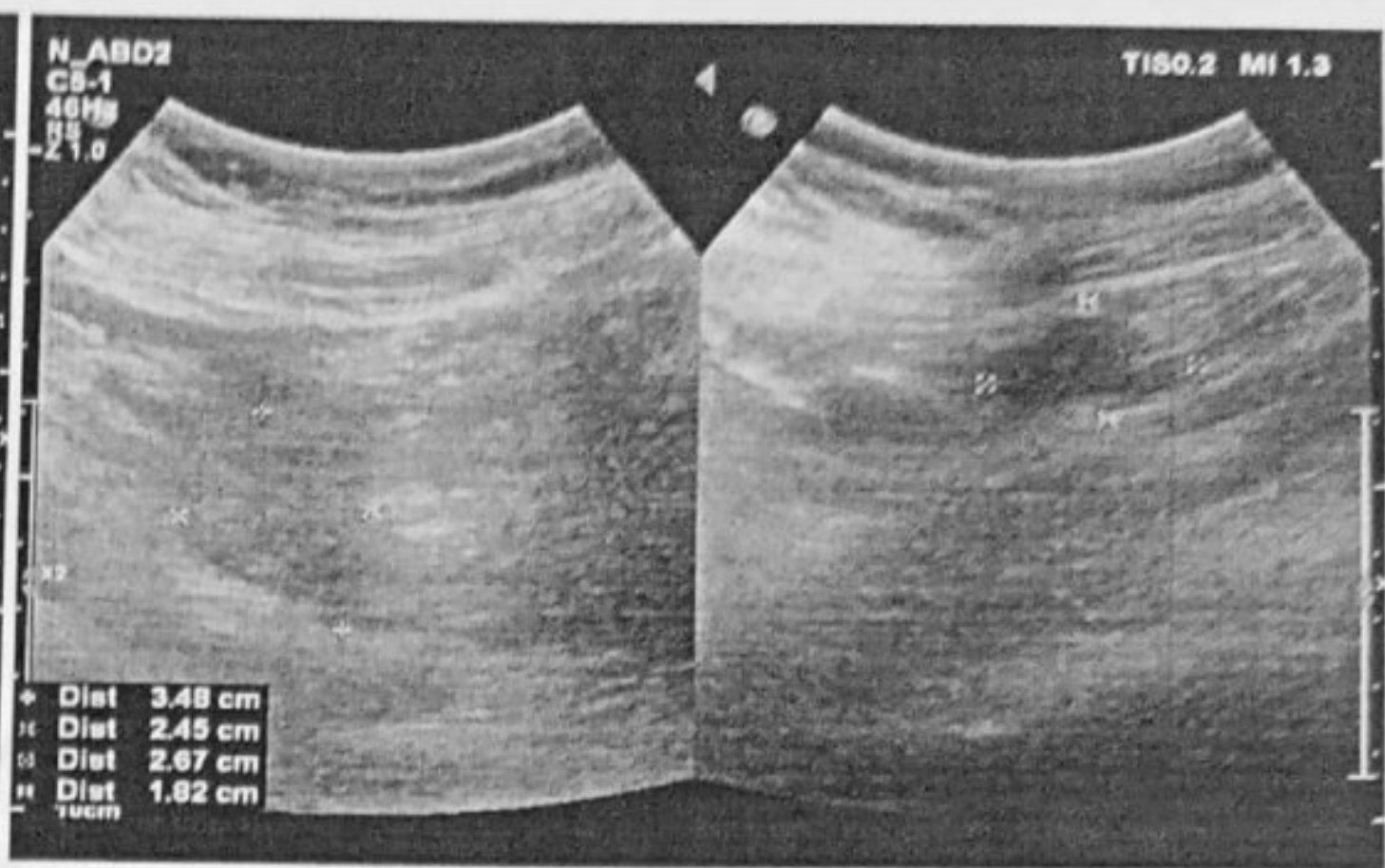
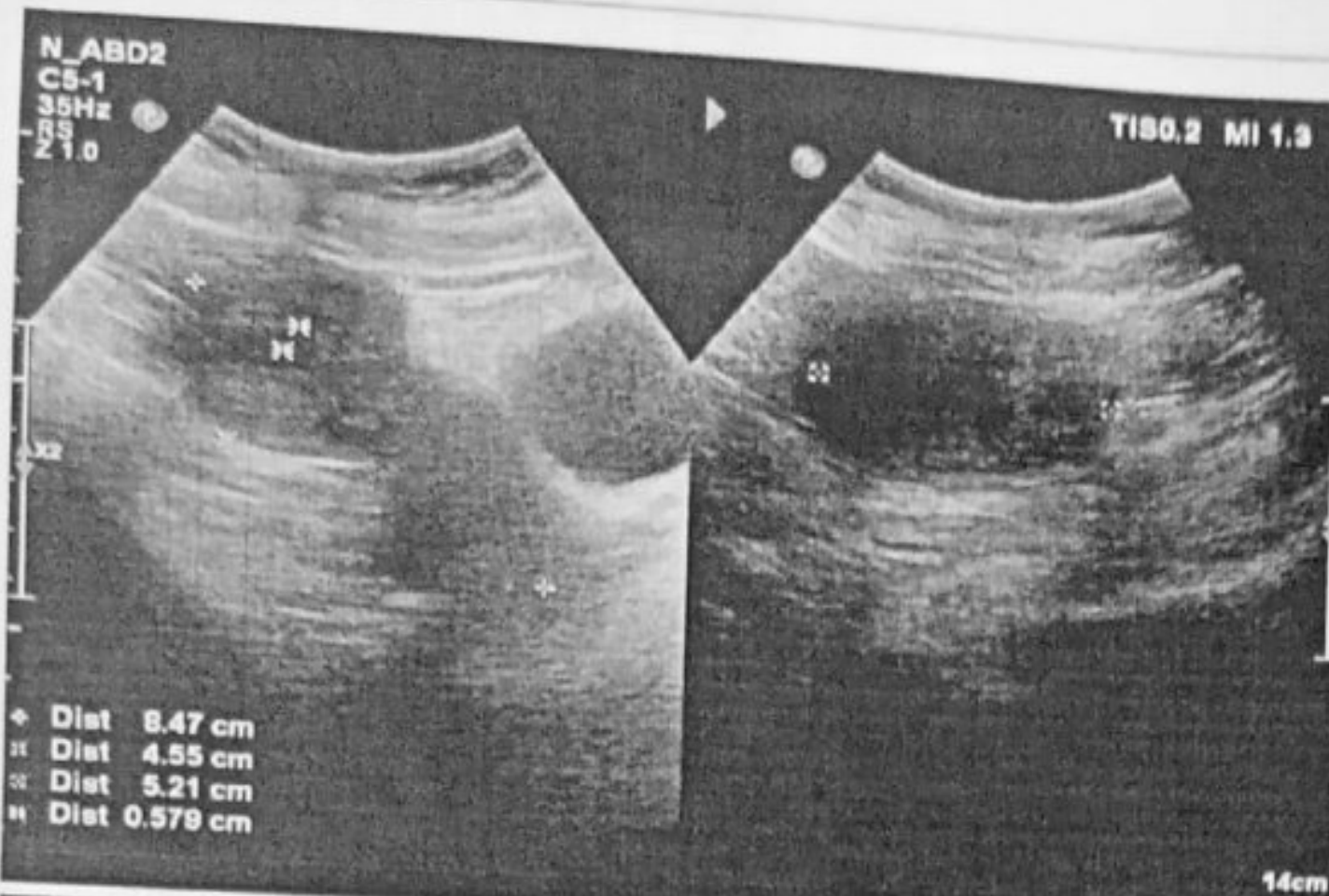
IMPRESSION:

- **SMALL LEFT LATERAL MYOMETRIAL INTRAUTERINE FIBROID.**

**Needs clinical correlation. Suggested further evaluation if clinically required.*

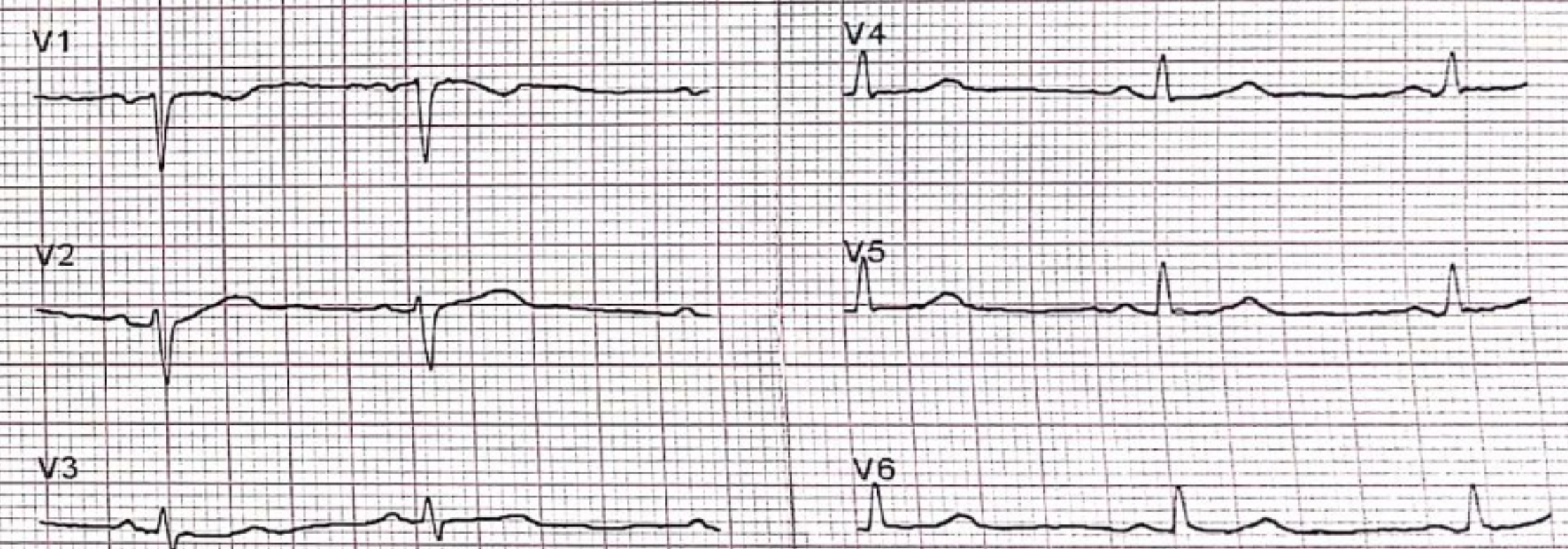
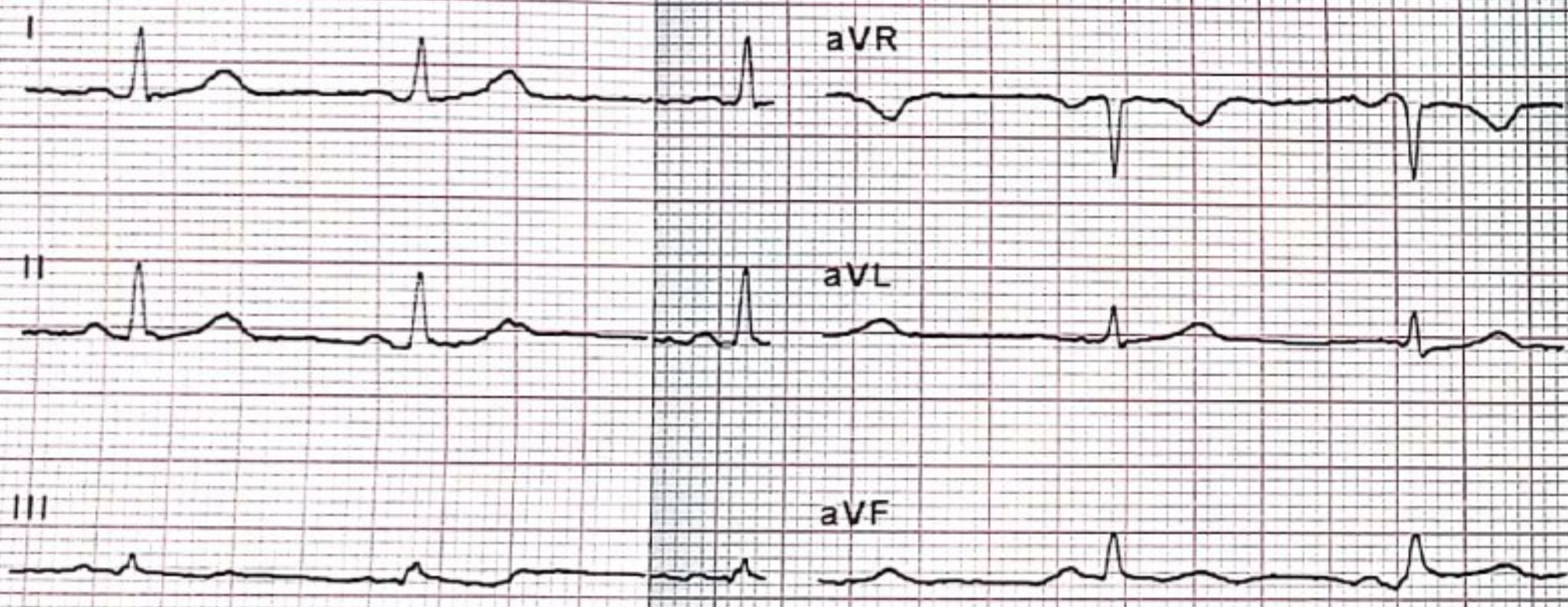
DR. **MADHAVA REDDY MD**
RADIOLOGIST
Consultant Radiologist
Regd.No. APMC/FMR/82797

Patient name	PRASHANTHI M	Age/Sex	- / Female
Patient ID	37381220240309	Visit no	1
Referred by		Visit date	09/03/2024



HR 65 /bpm

09.03.2024 11:24:02



25 mm/s, 10 mm/mV

LP 25 Hz, AC 50 Hz

Sequential

AT-1 G2 (1070.006301). 1.2.1

Part No.2.157044M © 0123 R.BD

SCHILLER Part No.2.157044M © 0123

SCHILLER Part No.2.157044M © 0123 R.BD

SCHILLER Part No.2.157044M © 0123

09.03.2024 11:24:02

Borderline ECG

Sinus rhythm
Normal electrical axis
Low limb lead voltage
Nonspecific T abnormality
Unconfirmed report

T. Pasawade

AT-1 G2 (1070.006301), 1.2.1

SCHILLER Part No.2.157044M € 0123 R.BD

A. Prashanthi

39y

Defc. 09/12/24

Dr. V. Narayanappa

SCHILLER Part No.2.157044M € 0123

HR 65 /bpm

RR 924 ms
P 92 ms
PR 132 ms
QRS 80 ms
QT 380 ms
QTc 395 ms
(Bazett)

Sokolow 1.23 mV
Cornell 0.49 mV
Lewis 0.46 mV
Romhilt -

P axis 58°
QRS axis 31°
T axis 24°

Dr. V. Narayanappa,

PHYSICIAN & SURGEON

Regd. No. 88543

Authorised Doctor,

For State Bank of India

ANANTAPUR

09.03.2024 11:24:02

Name

Patient ID

Date of Birth

Gender

Pacemaker

Height

M.B.B.S, FCGP

Weight

BP

Medication

Remark

AT-1 G2 (1070.006301), 1.2.1

SCHILLER Part No.2.157044M € 0123 R.BD

SCHILLER Part No.2.157044M € 0123

ru0
CHEST PA

AMRUTHA SAIDIAGNOSTIC
MRS M PRASHANTHI 39Y

03

08-Mar-04

Acq Tm: 12:52 AM

Left



3520 X 4280

W: 948 L: 561

MRS M PRASHANTHI 39Y 03 CHEST PA 08-Mar-04

AMRUTHA SAI DIAGNOSTIC CENTRE, OPP. BALAJI KALYANAMANDAPAM, SRINIVASA NAGAR, ANANTAPUR, 8688984900