



**MEDICOVER
HOSPITALS**

MEDICOVER HOSPITALS

MEDICAL HEALTH CHECK- UP ASSESMENT FORM

NAME : Mr / Mrs Abhimov Dubey

DATE: 29/4/24

AGE : 25 yrs

SEX: Male / Female

NMU: NMU000 51948

DOCTOR'S NAME:

Dr. Arun Pokharel

TEMP :	<u>97 ° f</u>	BP :	<u>117/70 mmHg</u>
PULSE :	<u>74 b/m</u>	HEIGHT :	<u>177 cm</u>
RR :	<u>22 b/m</u>	WEIGHT :	<u>76 kg</u>
SPO2 :	<u>99%</u>	HGT:	

REMARK:



MEDICOVER
HOSPITALS

NAVI MUMBAI

MEDICAL CERTIFICATE

I, Dr. Sachin Nalavade do hereby certify that I have carefully examined .

Sri./Smt. Ablinar K. Dubey , son / daughter.

Of Ashok K. Dubey is physically fit / ~~unfit~~ to join Organization .

Signature of Doctor: Sachin Nalavade

Registration No : 2005010710

Place : Kharghar

Date : 29/05/24

Dr. Sachin Nalavade
MD Medicine , FADM F-Echo, MBBS
Consultant Physician
Diabetologist & Intensivist
Regd. No- 2005/01/0410

Seal:





DEPARTMENT OF LABORATORY

NAVI MUMBAI

Patient Name : Mr. ABHINAV KUMAR DUBEY	Age / Gender : 25 Y(s)/Male
Bill No/ UMR No : NMBC68225/NMU0051948	Referred By : Dr. DMO
Received Dt : 29-Apr-24 09:42 am	Report Date : 29-Apr-24 01:21 pm

FINAL REPORT

<u>Parameter</u>	<u>Specimen</u>	<u>Result Values</u>	<u>Biological Reference</u>	<u>Method</u>
COMPLETE BLOOD COUNT				
RBC				
R B C COUNT	Blood	6.01	4.5 - 5.5 $10^6/\mu\text{L}$	
HEMOGLOBIN		18.3	13.0 - 17.0 g/dl	
PCV/HCT		53.6	40 - 50 % 36 - 46 %	
MCV		89	83 - 101 fl 83 - 101 fl	
MCH		30.4	27 - 32 pg	
MCHC		34.1	31.5 - 34.5 g/dL	
RDW(cv)		13.2	11.6 - 14.0 %	
PLATELETS				
PLATELET COUNT	Blood	135	150 - 400 $10^3/\mu\text{L}$	
MPV		10.1	7.5 - 11.5 fl	
WBC				
TC (TOTAL LEUCOCYTE COUNT)	Blood	7.1	4.0 - 11.0 $10^3/\mu\text{l}$	
DIFFERENTIAL COUNT				
NEUTROPHILS	Blood	55	40 - 80 %	
LYMPHOCYTES		35	20 - 40 %	
MONOCYTES		07	02 - 10 %	
EOSINOPHILS		03	00 - 06 %	
BASOPHILS		00	00 - 01 %	
PERIPHERAL SMEAR EXAMINATION		:		
RBC		Predominantly normocytic normochromic.		
WBC		Normal morphology.		
PLATELETS		Mildly reduced in smear.		
ESR	CITRATED BLOOD	02	0 - 10 mm/1st hour	WESTERGREN'S METHOD

*** End Of Report ***





MEDICOVER HOSPITALS

DEPARTMENT OF LABORATORY

NAVI MUMBAI

Patient Name : Mr. ABHINAV KUMAR DUBEY	Age / Gender : 25 Y(s)/Male
Bill No/ UMR No : NMBC68225/NMU0051948	Referred By : Dr. DMO
Received Dt : 29-Apr-24 09:42 am	Report Date : 29-Apr-24 11:17 am

Parameters

Specimen

Result

Biological Reference In Method





DEPARTMENT OF LABORATORY

NAVI MUMBAI

Patient Name : Mr. ABHINAV KUMAR DUBEY	Age /Gender : 25 Y(s)/Male
Bill No/ UMR No : NMBC68225/NMU0051948	Referred By : Dr. DMO
Received Dt : 29-Apr-24 09:43 am	Report Date : 29-Apr-24 11:05 am

FINAL REPORT

<u>Parameters</u>	<u>Specimen</u>	<u>Result</u>	<u>Biological Reference Intervals</u>	<u>Method</u>
FBS (FASTING BLOOD GLUCOSE)				
FASTING BLOOD GLUCOSE		93	Normal Range : 70 - 99 mg/dL	Hexokinase
SERUM CREATININE				
CREATININE		0.90	0.8 - 1.3 mg/dl	Method : jaffe
BUN(BLOOD UREA NITROGEN)				
BUN (Blood Urea Nitrogen.)		12	7.0 - 21.0 mg/dL	Calculated
SGPT (ALT)		17	<= 41 U/L	Method : UV without P5P
SERUM BILIRUBIN TOTAL		0.9	0.2 - 1.3 mg/dL	Jendrassik Grof
DIRECT BILIRUBIN		0.2	<= 0.20 mg/dL	Method: Diazo Method
INDIRECT BILIRUBIN		0.7	<= 1.0 mg/dL	

*** End Of Report ***

Lab Incharge

Chandana
Dr. VISHAL MEHROTRA, MD Pathology
Head, Laboratory Services

Verified By : : 022315

Test results related only to the item tested.

No part of the report can be reproduced without written permission of the laboratory.



Rate 71 . Sinus rhythm.....normal P axis, V-rate 50- 99
. ST elev, probable normal early repol pattern.....ST elevation, age<55

PR 167
QRSD 96
QT 362
QTc 394

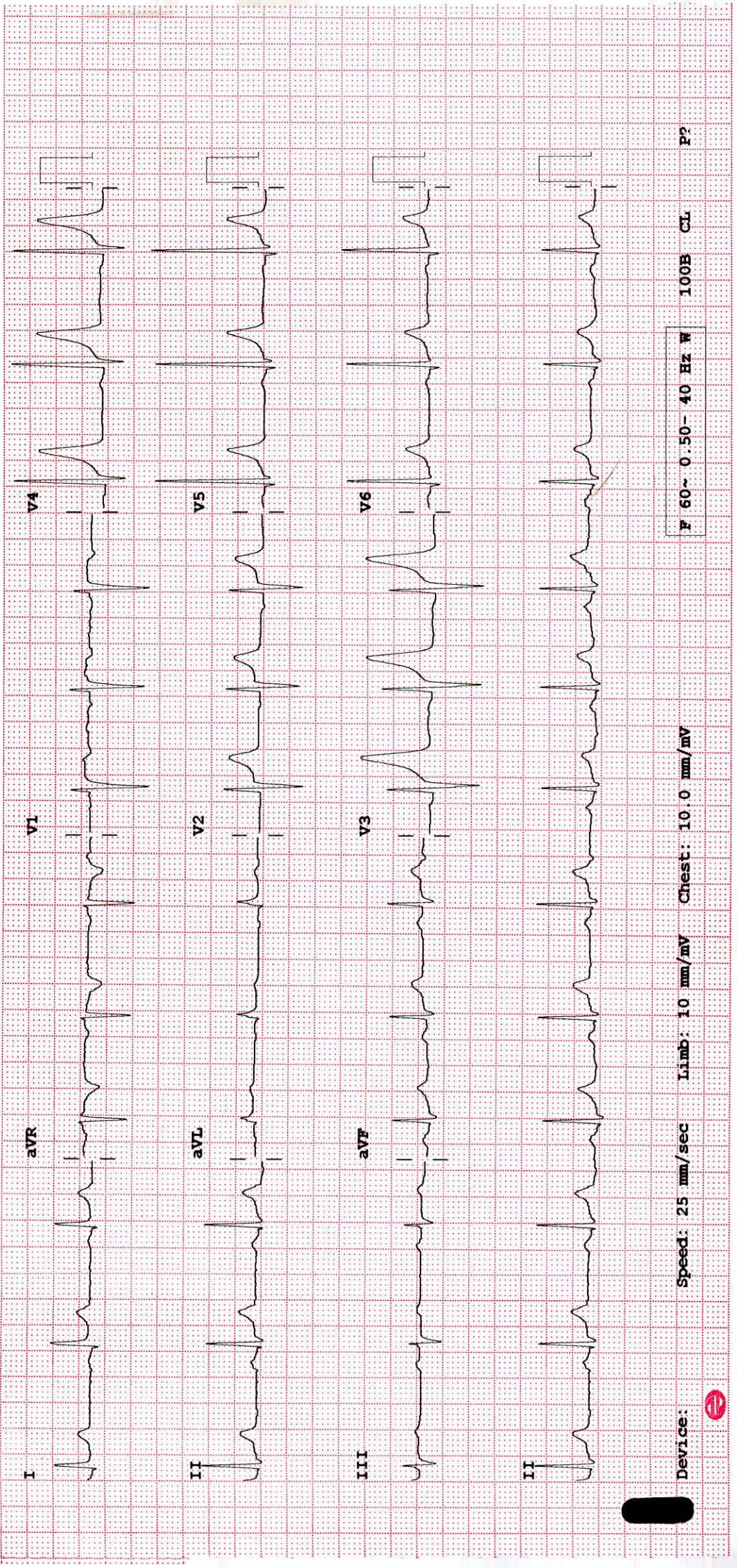
--AXIS--
P 71
QRS 26
T 43

12 Lead; Standard Placement

- NORMAL ECG -

Unconfirmed Diagnosis

M. Sathe
Dr. Anuj A. Sathe
DM Cardiology, MD (Med), MBBS
Consultant Interventional Cardiologist
Reg No 2005/03/1862



Device: Speed: 25 mm/sec Limb: 10 mm/mV Chest: 10.0 mm/mV

P 60~ 0.50- 40 Hz W 100B CL P?

Patient ID:	NMU0051948	Patient Name:	ABHINAV KUMAR DUBEY
Age:	26 Years	Sex:	M
Accession Number:	NMBC68225	Modality:	DX
Referring Physician:	DR.DMO	Study:	CHEST
Study Date:	29-Apr-2024		

X RAY CHEST PA VIEW

Both lungs are clear.

The frontal cardiac dimensions are normal.

The pleural spaces are clear.


Both hilar shadows are normal in position and density.

No diaphragmatic abnormality is seen.

The soft tissues and bony thorax are normal.

Impression:

No significant abnormality is seen.



DR JAMILA FANI
Consultant Radiologist
MBBS, MD

Date: 29-Apr-2024 15:07:30



DEPARTMENT OF OPHTHALMOLOGY

MEDICOVER HOSPITALS

DATE: 29/04/24

PATIENT NAME: Mr Abhinav. Dubey

AGE / SEX : 25 / M NAVI MUMBAI

UMR NO :

	RE	LE
VA (DISTANCE)	6/12 6/9	6/9 6/12
VA (NEAR)	N6 N6P	N6 N8
COLOUR VISION	Normal	Normal

VA
 cg100 (R) 6/6, N6
 (L) 6/6, N6

		SPHERE	CYLINDER	AXIS	VA
MRx	O D (R)	+1.50	—		6/6, N6
	O S (L)	+1.25	—		6/6, N6

HISTORY :

- H/o Spectacle use : 10 yrs
- NO H/o ocular trauma Allergies & surgeries.
- NO H/o systemic illness (DM, HTN, Thyroid)

OCULAR FINDINGS :

(BE) Ant. seg. WNL
 (M-dilated) Disc < 0.3
 0.4

ADVICE:

Refresh Tears 4x d'j'd 1777 X 1 month

AS
 CDR. ANUSHREE VANKAR

