

08/03/2024

Ajit Mharkhe

36yrs / male

No fresh complaints

No comorbidities.

No PH.

No SH.

FM - Mother - DM, HTN
Father - DM, HTN.

Height - 166 cm

Weight - 67 kg

BMI - 24.3 kg/m²

(Normal)

BP - 110/70 mmHg


P - 83/min

SpO₂ - 99%

pt is fit and can resume
w/ normal duties

consult with physician for blood changes
cholesterol, S.HDL, TG, LDL is raised
uric acid, SGPT, HBA1c

^{Adr}
2024/03/08





Siddhivinayak Hospital

Imaging Department
Sonography | Colour Doppler | 3D / 4D USG

HELPLINE
022 - 2588 3531

Name - Mr. Ajit Mhaske	Age - 36 Y/M
Ref by Dr.- Siddhivinayak Hospital	Date - 08/03/2024

USG ABDOMEN & PELVIS

FINDINGS: -

The **liver** dimension is normal in size. It appears normal in morphology with **raised echogenicity**. No evidence of intrahepatic ductal dilatation.

The **GB-gallbladder** is distended normally. Wall thickness is normal.

The **CBD- common bile duct** is normal. The portal vein is normal.

The **pancreas** appears normal in morphology.

The **spleen** is normal in size (9.4 cm) and morphology.

Both **kidneys** demonstrate normal morphology.

Both kidneys show normal cortical echogenicity.

The right kidney measures 9.7 X 4.3 cm

The left kidney measures 9.8 X 5.3 cm

Urinary bladder: -normally distended. Wall thickness - normal.

Prostate is normal in size and morphology Size:

No **free fluid** is seen.

IMPRESSION:-

- **Fatty liver (Grade I)**

DR. AMOL BENDRE
MBBS; DMRE
CONSULTANT RADIOLOGIST





Name - Mrs. AJIT MHATRE	Age - 36 Y/M
Ref by Dr.- Siddhivinayak Hospital	Date - 08 /03/2024

X- Ray chest (PA VIEW)

No obvious active parenchymal lesion seen in both lungs.

Cardiac and aortic shadows appear normal

No evidence of pleural of effusion is seen.

Both domes of diaphragm appear normal.

No obvious bony lesion is seen.

IMPRESSION:

- No significant abnormality seen.

Adv.: Clinical and lab correlation.

DR. AMOL BENDRE

MBBS; DMRE

CONSULTANT RADIOLOGIST

Note: The above report represents interpretation of various radiographic / sonographic shadows, and hence has its own limitations. This report has to be co-related clinic-pathologically by the referring / physician and it does NOT represent the sole diagnosis.



ID: 1059

AIIT mhast e
Female m Years

Req. No. :

BP - 110/70

SpO2 - 98%
PR - 83bpm

WT - 67kg

HT - 166

08-03-2024 10:17:49 AM

HR	: 83	bpm
P	: 99	ms
PR	: 151	ms
QRS	: 89	ms
QT/QTcBz	: 369/434	ms
P/QRS/T	: 60/262/42	ms
RV5/SV1	: 0.848/0.000	mV

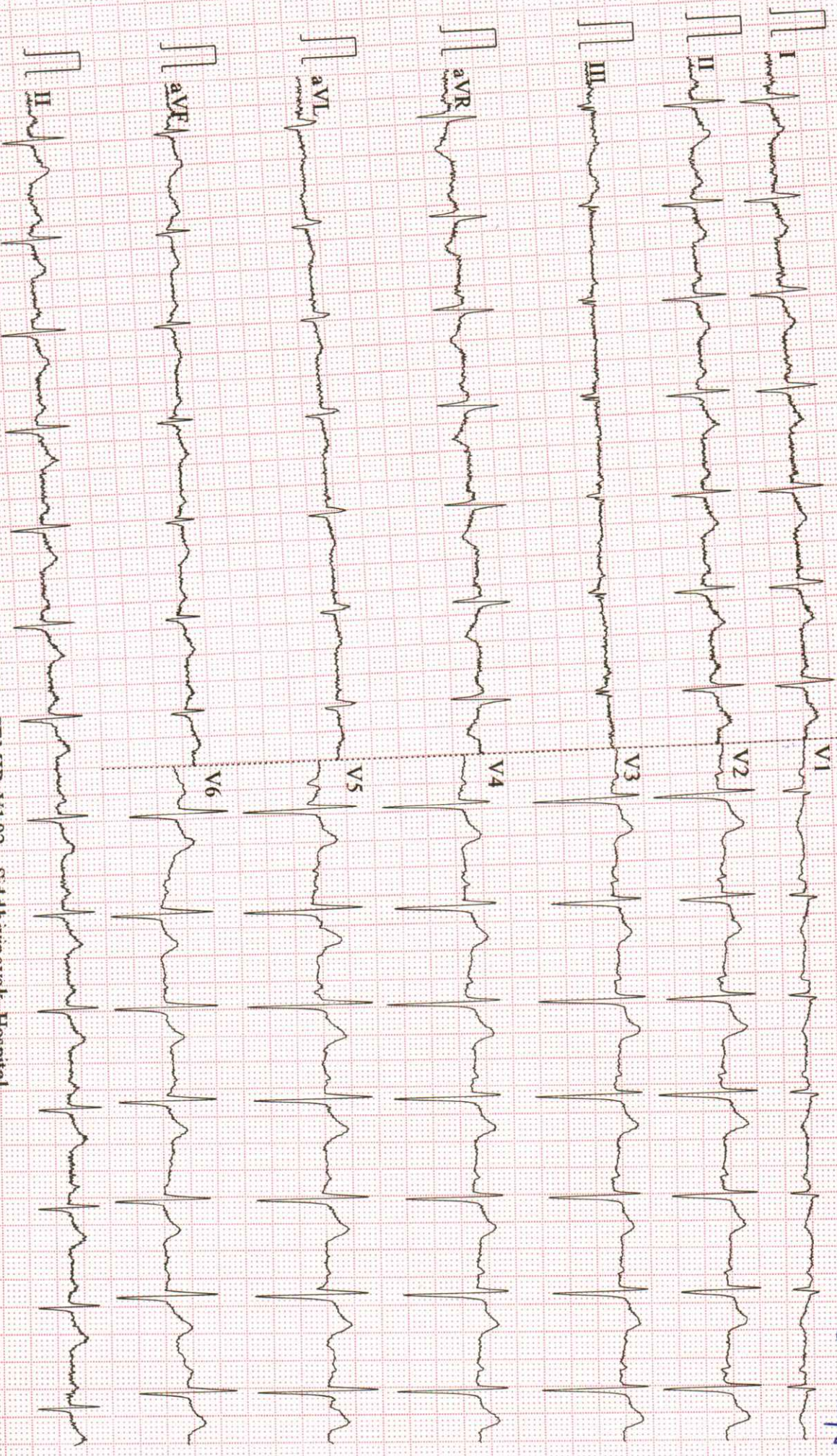
Diagnosis Information:

Sinus Rhythm
 Incomplete Right Bundle Branch Block
 Abnormal q Wave(V1)
 Right Ventricular Hypertrophy
 Indeterminate Axis

Report Confirmed by:

Adv
20 Dec 2024

Dr. Anant Ramkishanrao Munde
 MBBS, DNB, DM (Cardiology)
 Reg. No. 2005021228



0.15-45Hz AC50 25mm/s 10mm/mV 2*5.0s+1r V2.21 SEMIP V1.92 Siddhivinyak Hospital



ECHOCARDIOGRAM

NAME	MR. AJIT MHLASKE
AGE/SEX	36 YRS/M
REFERRED BY	SIDDHIVINAYAK HOSPITAL
DATE OF EXAMINATION	08/03/2024

2D/M-MODE ECHOCARDIOGRAPHY

VALVES: MITRAL VALVE: <ul style="list-style-type: none"> • AML: Normal • PML: Normal • Sub-valvular deformity: Absent AORTIC VALVE: Normal <ul style="list-style-type: none"> • No. of cusps: 3 PULMONARY VALVE: Normal TRICUSPID VALVE: Normal	CHAMBERS: LEFT ATRIUM: Normal <ul style="list-style-type: none"> • Left atrial appendage: Normal LEFT VENTRICLE: Normal <ul style="list-style-type: none"> • RWMA: No • Contraction: Normal RIGHT ATRIUM: Normal RIGHT VENTRICLE: Normal <ul style="list-style-type: none"> • RWMA: No • Contraction: Normal
GREAT VESSELS: <ul style="list-style-type: none"> • AORTA: Normal • PULMONARY ARTERY: Normal 	SEPTAE: <ul style="list-style-type: none"> • IAS: Intact • IVS: Intact
CORONARIES: Proximal coronaries normal CORONARY SINUS: Normal	VENACAVAE: <ul style="list-style-type: none"> • SVC: Normal • IVC: Normal and collapsing >20% with respiration
PULMONARY VEINS: Normal	PERICARDIUM: Normal

MEASUREMENTS:

AORTA		LEFT VENTRICLE STUDY		RIGHT VENTRICLE STUDY	
PARAMETER	OBSERVED VALUE	PARAMETER	OBSERVED VALUE	PARAMETER	OBSERVED VALUE
Aortic annulus	21 mm	Left atrium	35 mm	Right atrium	mm
Aortic sinus	mm	LVIDd	43.3 mm	RVd (Base)	mm
Sino-tubular junction	mm	LVIDs	28.5 mm	RVEF	%
Ascending aorta	mm	IVSd	8.9 mm	TAPSE	mm
Arch of aorta	mm	LVPWd	8.9 mm	MPA	mm
Desc. thoracic aorta	mm	LVEF	65 %	RVOT	mm
Abdominal aorta	mm	LVOT	mm	IVC	14 mm



COLOR - FLOW & DOPPLER ECHOCARDIOGRAPHY

NAME	MR. AJIT MHASKE
AGE/SEX	36 YRS/M
REFERRED BY	SIDDHIVINAYAK HOSPITAL
DATE OF EXAMINATION	08/03/2024

	MITRAL	TRICUSPID	AORTIC	PULMONARY
FLOW VELOCITY (m/s)			1.19	0.92
PPG (mmHg)				
MPG (mmHg)				
VALVE AREA (cm ²)				
DVI (ms)				
PR END DIASTOLIC VELOCITY (m/s)				
ACCELERATION/ DECELERATION TIME (ms)				
PHT (ms)				
VENA CONTRACTA (mm)				
REGURGITATION		TRJV= m/s PASP= mmHg		
E/A	1.5			
E/E'	7.9			

FINAL IMPRESSION: NORMAL STUDY

- No RWMA
- Normal LV systolic function (LVEF 65 %)
- Good RV systolic function
- Normal diastolic function
- All cardiac valves are normal
- All cardiac chambers are normal
- IAS/IVS intact
- No pericardial effusion/ clot/vegetations

ADVICE: Nil

ECHOCARDIOGRAPHER:

Dr. ANANT MUNDE

DNB, DM (CARDIOLOGY)

INTERVENTIONAL CARDIOLOGIST

Dr. Anant Ramkishanrao Munde
MBBS, DNB, DM (Cardiology)
Reg. No. 2005021228



Name : Mr. AJIT MHASKE (A) Collected On : 8/3/2024 9:16 am
Lab ID. : 186071 Received On : 8/3/2024 9:26 am
Age/Sex : 36 Years / Male Reported On : 9/3/2024 8:59 pm
Ref By : SIDDHIVINAYAK HOSPITAL CGHS /ESIS Report Status : FINAL



***LIPID PROFILE**

TEST NAME	RESULTS	UNIT	REFERENCE RANGE
TOTAL CHOLESTEROL (CHOLESTEROL OXIDASE, ESTERASE, PEROXIDASE)	247.0	mg/dL	Desirable blood cholesterol: - <200 mg/dl. Borderline high blood cholesterol: - 200 - 239 mg/dl. High blood cholesterol: - >239 mg/dl.
S.HDL CHOLESTEROL (DIRECT MEASURE - PEG)	34.7	mg/dL	Major risk factor for heart : <30 mg/dl. Negative risk factor for heart disease: >=80 mg/dl.
S. TRIGLYCERIDE (ENZYMATIC, END POINT)	284.2	mg/dL	Desirable level : <161 mg/dl. High : >= 161 - 199 mg/dl. Borderline High : 200 - 499 mg/dl. Very high : >499mg/dl.
VLDL CHOLESTEROL (CALCULATED VALUE)	57	mg/dL	UPTO 40
S.LDL CHOLESTEROL (CALCULATED VALUE)	155	mg/dL	Optimal: <100 mg/dl. Near Optimal: 100 - 129 mg/dl. Borderline High: 130 - 159 mg/dl. High : 160 - 189mg/dl. Very high : >= 190 mg/dl.
LDL CHOL/HDL RATIO (CALCULATED VALUE)	4.47		UPTO 3.5
CHOL/HDL CHOL RATIO (CALCULATED VALUE)	7.12		<5.0

Above reference ranges are as per ADULT TREATMENT PANEL III recommendation by NCEP (May 2015).

Result relates to sample tested, Kindly correlate with clinical findings.

----- END OF REPORT -----

Checked By
Priyanka_Deshmukh

DR. SMITA RANVEER.
M.B.B.S.M.D. Pathology(Mum)
Consultant Histocytopathologist





Name : Mr. AJIT MHASKE (A) Collected On : 8/3/2024 9:16 am
Lab ID. : 186071 Received On : 8/3/2024 9:26 am
Age/Sex : 36 Years / Male Reported On : 9/3/2024 8:59 pm
Ref By : SIDDHIVINAYAK HOSPITAL CGHS /ESIS Report Status : FINAL



COMPLETE BLOOD COUNT

TEST NAME	RESULTS	UNIT	REFERENCE RANGE
HEMOGLOBIN	15.8	gm/dl	13 - 18
HEMATOCRIT (PCV)	46.4	%	42 - 52
RBC COUNT	5.48	x10 ⁶ /uL	4.70 - 6.50
MCV	85	fl	80 - 96
MCH	28.8	pg	27 - 33
MCHC	34	g/dl	33 - 36
RDW-CV	13.0	%	11.5 - 14.5
TOTAL LEUCOCYTE COUNT	6800	/cumm	4000 - 11000
<u>DIFFERENTIAL COUNT</u>			
NEUTROPHILS	57	%	40 - 80
LYMPHOCYTES	32	%	20 - 40
EOSINOPHILS	05	%	0 - 6
MONOCYTES	06	%	2 - 10
BASOPHILS	00	%	0 - 1
PLATELET COUNT	400000	/cumm	150000 - 450000
MPV	10.3	fl	6.5 - 11.5
PDW	16.4	%	9.0 - 17.0
PCT	0.410	%	0.200 - 0.500
RBC MORPHOLOGY	Normocytic Normochromic		
WBC MORPHOLOGY	Normal		
PLATELETS ON SMEAR	Adequate		

Method : EDTA Whole Blood- Tests done on Automated Six Part Cell Counter.RBC and Platelet count by Electric Impedance ,WBC by SF Cube method and Differential by flow cytometry . Hemoglobin by Cyanide free reagent for hemoglobin test (Colorimetric Method).Rest are calculated parameters.

Result relates to sample tested, Kindly correlate with clinical findings.

----- END OF REPORT -----

Checked By
SHAISTA Q

DR. SMITA RANVEER.
M.B.B.S.M.D. Pathology(Mum)
Consultant Histocytopathologist





Name : Mr. AJIT MHASKE (A) Collected On : 8/3/2024 9:16 am
Lab ID. : 186071 Received On : 8/3/2024 9:26 am
Age/Sex : 36 Years / Male Reported On : 9/3/2024 8:59 pm
Ref By : SIDDHIVINAYAK HOSPITAL CGHS /ESIS Report Status : FINAL



URINE ROUTINE EXAMINATION

TEST NAME	RESULTS	UNIT	REFERENCE RANGE
<u>URINE ROUTINE EXAMINATION</u>			
<u>PHYSICAL EXAMINATION</u>			
VOLUME	20ml		
COLOUR	Pale Yellow		Pale Yellow
APPEARANCE	Clear		Clear
<u>CHEMICAL EXAMINATION</u>			
REACTION (methyl red and Bromothymol blue indicator)	Acidic		Acidic
SP. GRAVITY (Bromothymol blue indicator)	1.010		1.005 - 1.022
PROTEIN (Protein error of PH indicator)	Absent		Absent
BLOOD (Peroxidase Method)	Absent		Absent
SUGAR (GOD/POD)	Absent		Absent
KETONES (Acetoacetic acid)	Absent		Absent
BILE SALT & PIGMENT (Diazonium Salt)	Absent		Absent
UROBILINOGEN (Red azodye)	Normal		Normal
LEUKOCYTES (pyrrole amino acid ester diazonium salt)	Absent		Absent
NITRITE (Diazonium compound With tetrahydrobenzo quinolin 3-phenol)	Absent		Negative
<u>MICROSCOPIC EXAMINATION</u>			
RED BLOOD CELLS	Absent	/ HPF	Absent
PUS CELLS	1-2	/ HPF	0 - 5
EPITHELIAL	0-2	/ HPF	0 - 5
CASTS	Absent		

Checked By
SHAISTA Q

DR. SMITA RANVEER.
M.B.B.S.M.D. Pathology(Mum)
Consultant Histocytopathologist





Name : Mr. AJIT MHASKE (A) Collected On : 8/3/2024 9:16 am
Lab ID. : 186071 Received On : 8/3/2024 9:26 am
Age/Sex : 36 Years / Male Reported On : 9/3/2024 8:59 pm
Ref By : SIDDHIVINAYAK HOSPITAL CGHS /ESIS Report Status : FINAL



URINE ROUTINE EXAMINATION

TEST NAME	RESULTS	UNIT	REFERENCE RANGE
CRYSTALS	Absent		
BACTERIA	Absent		Absent
YEAST CELLS	Absent		Absent
ANY OTHER FINDINGS	Absent		

REMARK Result relates to sample tested. Kindly correlate with clinical findings.

Result relates to sample tested, Kindly correlate with clinical findings.

----- END OF REPORT -----

Checked By
SHAISTA Q

DR. SMITA RANVEER.
M.B.B.S.M.D. Pathology(Mum)
Consultant Histocytopathologist



Name	: Mr. AJIT MHASKE (A)	Collected On	: 8/3/2024 9:16 am
Lab ID.	: 186071	Received On	: 8/3/2024 9:26 am
Age/Sex	: 36 Years / Male	Reported On	: 9/3/2024 8:59 pm
Ref By	: SIDDHIVINAYAK HOSPITAL CGHS /ESIS	Report Status	: FINAL



IMMUNO ASSAY

TEST NAME	RESULTS	UNIT	REFERENCE RANGE
-----------	---------	------	-----------------

TFT (THYROID FUNCTION TEST)

SPECIMEN	Serum		
T3	88.55	ng/dl	84.63 - 201.8
T4	6.65	µg/dl	5.13 - 14.06
TSH	2.11	µIU/ml	0.270 - 4.20

DONE ON FULLY AUTOMATED ANALYSER COBAS e411.

INTERPRETATION T3 (Triiodo Thyronine) T4 (Thyroxine)

AGE	RANGE	AGE	RANGES
1-30 days	100-740	1-14 Days	11.8-22.6
1-11 months	105-245	1-2 weeks	9.9-16.6
1-5 years	105-269	1-4 months	7.2-14.4
6-10 years	94-241	4-12months	7.8-16.5
11-15 years	82-213	1-5 years	7.3-15.0
15-20 years	80-210	5-10 years	6.4-13.3
		11-15 years	5.6-11.7


TSH(Thyroid stimulating hormone)

AGE	RANGES
0-14 Days	1.0-39
2 weeks -5 months	1.7-9.1
6 months-20 years	0.7-6.4
Pregnancy	
1st Trimester	0.1-2.5
2nd Trimester	0.20-3.0
3rd Trimester	0.30-3.0

INTERPRETATION :

TSH stimulates the production and secretion of the metabolically active thyroid hormones, thyroxine (T4) and triiodothyronine (T3), by interacting with a specific receptor on the thyroid cell surface. The synthesis and secretion of TSH is stimulated by Thyrotropin releasing hormone (TRH), in response to low levels of circulating thyroid hormones. Elevated levels of T3 and T4 suppress the production of TSH via a classic negative feedback mechanism. Failure at any level of regulation of the hypothalamic-pituitary-thyroid axis will result in either underproduction (hypothyroidism) or overproduction (hyperthyroidism) of T4 and/or T3.

Checked By
SHAISTA Q



DR. SMITA RANVEER.
M.B.B.S.M.D. Pathology(Mum)
Consultant Histocytopathologist



Name : Mr. AJIT MHASKE (A) Collected On : 8/3/2024 9:16 am
Lab ID. : 186071 Received On : 8/3/2024 9:26 am
Age/Sex : 36 Years / Male Reported On : 9/3/2024 8:59 pm
Ref By : SIDDHIVINAYAK HOSPITAL CGHS /ESIS / Report Status : FINAL



* 1 8 6 0 7 1 *

Result relates to sample tested, Kindly correlate with clinical findings.

----- END OF REPORT -----

Checked By
SHAISTA Q

DR. SMITA RANVEER.
M.B.B.S.M.D. Pathology(Mum)
Consultant Histocytopathologist





Name : Mr. AJIT MHASKE (A) Collected On : 8/3/2024 9:16 am
Lab ID. : 186071 Received On : 8/3/2024 9:26 am
Age/Sex : 36 Years / Male Reported On : 9/3/2024 8:59 pm
Ref By : SIDDHIVINAYAK HOSPITAL CGHS /ESIS Report Status : FINAL



HAEMATOLOGY

TEST NAME	RESULTS	UNIT	REFERENCE RANGE
BLOOD GROUP			
SPECIMEN	WHOLE BLOOD EDTA & SERUM		
* ABO GROUP	'O'		
RH FACTOR	POSITIVE		
Method: Slide Agglutination and Tube Method (Forward grouping & Reverse grouping)			
Result relates to sample tested, Kindly correlate with clinical findings.			
----- END OF REPORT -----			

Checked By
SHAISTA Q

DR. SMITA RANVEER.
M.B.B.S.M.D. Pathology(Mum)
Consultant Histocytopathologist





Name : Mr. AJIT MHASKE (A) Collected On : 8/3/2024 9:16 am
Lab ID. : 186071 Received On : 8/3/2024 9:26 am
Age/Sex : 36 Years / Male Reported On : 9/3/2024 8:59 pm
Ref By : SIDDHIVINAYAK HOSPITAL CGHS /ESIS Report Status : FINAL



***RENAL FUNCTION TEST**

TEST NAME	RESULTS	UNIT	REFERENCE RANGE
BLOOD UREA (Urease UV GLDH Kinetic)	23.9	mg/dL	19 - 45
BLOOD UREA NITROGEN (Calculated)	11.17	mg/dL	5 - 20
S. CREATININE (Enzymatic)	0.94	mg/dL	0.6 - 1.4
S. URIC ACID (Uricase)	8.8	mg/dL	3.5 - 7.2
S. SODIUM (ISE Direct Method)	139.0	mEq/L	137 - 145
S. POTASSIUM (ISE Direct Method)	4.00	mEq/L	3.5 - 5.1
S. CHLORIDE (ISE Direct Method)	101.0	mEq/L	98 - 110
S. PHOSPHORUS (Ammonium Molybdate)	3.95	mg/dL	2.5 - 4.5
S. CALCIUM (Arsenazo III)	10.2	mg/dL	8.6 - 10.2
PROTEIN (Biuret)	7.58	g/dl	6.4 - 8.3
S. ALBUMIN (BGC)	4.52	g/dl	3.2 - 4.6
S.GLOBULIN (Calculated)	3.06	g/dl	1.9 - 3.5
A/G RATIO calculated	1.48		0 - 2

NOTE

BIOCHEMISTRY TEST DONE ON FULLY AUTOMATED (EM 200)
ANALYZER.

Result relates to sample tested, Kindly correlate with clinical findings.

----- END OF REPORT -----

Checked By
SHAISTA Q

DR. SMITA RANVEER.
M.B.B.S.M.D. Pathology(Mum)
Consultant Histocytopathologist



Name : Mr. AJIT MHASKE (A)
Lab ID. : 186071
Age/Sex : 36 Years / Male
Ref By : SIDDHIVINAYAK HOSPITAL CGHS /ESIS

Collected On : 8/3/2024 9:16 am
Received On : 8/3/2024 9:26 am
Reported On : 9/3/2024 8:59 pm
Report Status : FINAL



* 1 8 6 0 7 1 *

Peripheral smear examination

TEST NAME	RESULTS
SPECIMEN RECEIVED	Whole Blood EDTA
RBC	Normocytic Normochromic
WBC	Total leucocyte count is normal on smear. Neutrophils:55 % Lymphocytes:34 % Monocytes:06 % Eosinophils:05 % Basophils:00 %
PLATELET	Adequate on smear.
HEMOPARASITE	No parasite seen.

Result relates to sample tested, Kindly correlate with clinical findings.
----- END OF REPORT -----

Checked By
SHAISTA Q

DR. SMITA RANVEER.
M.B.B.S.M.D. Pathology(Mum)
Consultant Histocytopathologist





Name : Mr. AJIT MHASKE (A) Collected On : 8/3/2024 9:16 am
Lab ID. : 186071 Received On : 8/3/2024 9:26 am
Age/Sex : 36 Years / Male Reported On : 9/3/2024 8:59 pm
Ref By : SIDDHIVINAYAK HOSPITAL CGHS /ESIS Report Status : FINAL



LIVER FUNCTION TEST

TEST NAME	RESULTS	UNIT	REFERENCE RANGE
TOTAL BILLIRUBIN (Method-Diazo)	0.76	mg/dL	0.1 - 1.2
DIRECT BILLIRUBIN (Method-Diazo)	0.32	mg/dL	0.0 - 0.4
INDIRECT BILLIRUBIN Calculated	0.44	mg/dL	0 - 0.8
SGOT(AST) (UV without PSP)	34.7	U/L	0 - 37
SGPT(ALT) UV Kinetic Without PLP (P-L-P)	55.2	U/L	UP to 40
ALKALINE PHOSPHATASE (Method-ALP-AMP)	80.0	U/L	53 - 128
S. PROTIEN (Method-Biuret)	7.58	g/dl	6.4 - 8.3
S. ALBUMIN (Method-BCG)	4.52	g/dl	3.5 - 5.2
S. GLOBULIN Calculated	3.06	g/dl	1.90 - 3.50
A/G RATIO Calculated	1.48		0 - 2

Result relates to sample tested, Kindly correlate with clinical findings.

----- END OF REPORT -----

Checked By
SHAISTA Q

DR. SMITA RANVEER.
M.B.B.S.M.D. Pathology(Mum)
Consultant Histocytopathologist



Name : Mr. AJIT MHASKE (A) Collected On : 8/3/2024 9:16 am
Lab ID. : 186071 Received On : 8/3/2024 9:26 am
Age/Sex : 36 Years / Male Reported On : 9/3/2024 8:59 pm
Ref By : SIDDHIVINAYAK HOSPITAL CGHS /ESIS Report Status : FINAL



* 1 8 6 0 7 1 *

HAEMATOLOGY

TEST NAME	RESULTS	UNIT	REFERENCE RANGE
ESR			
ESR	10	mm/1hr.	0 - 20

METHOD - WESTERGREN

Result relates to sample tested, Kindly correlate with clinical findings.

----- END OF REPORT -----

Checked By
SHAISTA Q

DR. SMITA RANVEER.
M.B.B.S.M.D. Pathology(Mum)
Consultant Histocytopathologist



Name	: Mr. AJIT MHASKE (A)	Collected On	: 8/3/2024 9:16 am
Lab ID.	: 186071	Received On	: 8/3/2024 9:26 am
Age/Sex	: 36 Years / Male	Reported On	: 9/3/2024 8:59 pm
Ref By	: SIDDHIVINAYAK HOSPITAL CGHS /ESIS	Report Status	: FINAL



BIOCHEMISTRY

TEST NAME	RESULTS	UNIT	REFERENCE RANGE
GAMMA GT	64.3	U/L	13 - 109
<u>GLYCOCELATED HEMOGLOBIN (HBA1C)</u>			
HBA1C (GLYCOSALATED HAEMOGLOBIN)	6.8	%	Hb A1c > 8 Action suggested < 7 Goal < 6 Non - diabetic level
AVERAGE BLOOD GLUCOSE (A. B. G.)	148.5	mg/dL	NON - DIABETIC : <=5.6 PRE - DIABETIC : 5.7 - 6.4 DIABETIC : >6.5

METHOD Particle Enhanced Immunoturbidimetry
 HbA1c : Glycosylated hemoglobin concentration is dependent on the average blood glucose concentration which is formed progressively and irreversibly over a period of time and is stable till the life of the RBC/erythrocytes. Average Blood Glucose (A.B.G) is calculated value from HbA1c : Glycosylated hemoglobin concentration in whole Blood. It indicates average blood sugar level over past three months.

BLOOD SUGAR FASTING

* FASTING BLOOD GLUCOSE	95.4	mg/dL	74 - 100
-------------------------	------	-------	----------

INTERPRETATION

- Normal glucose tolerance : 70-110 mg/dl
- Impaired Fasting glucose (IFG) : 110-125 mg/dl
- Diabetes mellitus : >=126 mg/dl

POSTPRANDIAL/POST GLUCOSE (75 grams)

- Normal glucose tolerance : 70-139 mg/dl
- Impaired glucose tolerance : 140-199 mg/dl
- Diabetes mellitus : >=200 mg/dl

CRITERIA FOR DIAGNOSIS OF DIABETES MELLITUS


- Fasting plasma glucose >=126 mg/dl
- Classical symptoms + Random plasma glucose >=200 mg/dl
- Plasma glucose >=200 mg/dl (2 hrs after 75 grams of glucose)
- Glycosylated haemoglobin > 6.5%

***Any positive criteria should be tested on subsequent day with same or other criteria.

Result relates to sample tested, Kindly correlate with clinical findings.

----- END OF REPORT -----

Checked By
 SHAISTA Q



DR. SMITA RANVEER.
M.B.B.S.M.D. Pathology(Mum)
Consultant Histocytopathologist

