



# PANACEA HOSPITAL

B 36/44 F.K KABIR NAGAR, DURGAKUND  
TOLLFREE NO-18001233070. Whatsapp No - 8795832852  
www.piire.org  
panaceaquery@gmail.com|panaceahospital@gmail.com



## OP Slip

Print Date : 09-Mar-2024 09:36AM



**UHID No** :- UD-23240006696      **OP No** :- OP-23240020561      **OP Date** :- 09 Mar 2024 9:33AM  
**Patient Name** :- Mr VINAY PRAKASH MAURYA      **Age/Sex** :- 39 Y/Male      **Mobile No** :- 8600108474  
**Father** :- RAM NARESH MAURYA      **Department** :- GENERAL MEDICINE  
**Pay Type** :- Cash      **Consultant** :- Dr Pallavi Mishra (MBBS,MD,MBBS)  
**Token No** :- NOR. - 4      **Paid/Bal** :- 0.00 /30.00  
**Patient Type** :- Normal  
**Address** :- J 12/135A 6 DHOOP CHANDI - 2210022,varanasi

**BP** :- 120/80  
**height** :- 172  
**Weight (kg)** :- 76  
**BMI** :- 25.68

Rx

△ hereditary Dyslipidemia

4524 - 6.2  
 Cho - 1711  
 TG = 168

CH - 98  
 NL - 99  
 WC - 95  
 PR - 83  
 SPO<sub>2</sub> - 99  
 PEF - 600

R LOS 5gm < 0

Tab. Diabimox 10mg OD

Tab. Romy 20mg 1mn

one LOR (500mg)

~~Es. fit to fiber 20~~

1mn per

Mr. Arvind

Printed By : Mr Siddhant Dwivedi

Created By : Mr Siddhant Dwivedi

Es. fit to fiber < 0

DR. Pallavi Mishra  
 MBBS, MD(GENERAL MEDICINE)  
 MCI Reg. No.52033



# PANACEA HOSPITAL

B 36/44 F.K KABIR NAGAR, DURGAKUND  
TOLLFREE NO-18001233070. Whatsapp No - 8795832852  
www.piire.org  
panaceaquery@gmail.com|panaceahospital@gmail.com



## OP Slip

Print Date : 09-Mar-2024 09:34AM



**UHID No** :- UD-23240006696      **OP No** :- OP-23240020561      **OP Date** :- 09 Mar 2024 9:33AM  
**Patient Name** :- Mr VINAY PRAKASH MAURYA      **Age/Sex** :- 39 Y/Male      **Mobile No** :- 8600108474  
**Father** :- RAM NARESH MAURYA      **Department** :- DENTAL  
**Pay Type** :- Cash      **Consultant** :- Dr SHRUTI MISHRA (AA)  
**Token No** :- NOR. - 2      **Paid/Bal** :- 0.00 /30.00  
**Patient Type** :- Normal  
**Address** :- J 12/135A 6 DHOOP CHANDI - 2210022, varanasi

**BP** :-  
**height** :-  
**Weight (kg)** :-  
**BMI** :-

**Rx** patient came for routine dental checkup.

p/c - stains / calculus ++

c/c - proximal caries

t/c - full mouth scaling

*Shruti*  
**Dr. SHRUTI MISHRA**  
BDS, (DENTIST)  
MCI Reg. No. (A-09784)

Printed By : Mr Siddhant Dwivedi

Created By : Mr Siddhant Dwivedi



# PANACEA HOSPITAL

B 36/44 F.K KABIR NAGAR, DURGAKUND  
TOLLFREE NO-18001233070. Whatsapp No - 8795832852  
www.piire.org  
panaceaquery@gmail.com|panceahospital@gmail.com



## OP Slip

Print Date : 09-Mar-2024 09:36AM



<b>UHID No</b> :- UD-23240006696	<b>OP No</b> :- OP-23240020561	<b>OP Date</b> :- 09 Mar 2024 9:33AM
<b>Patient Name</b> :- Mr VINAY PRAKASH MAURYA	<b>Age/Sex</b> :- 39 Y/Male	<b>Mobile No</b> :- 8600108474
<b>Father</b> :- RAM NARESH MAURYA	<b>Department</b> :- OPHTHALMOLOGY	
<b>Pay Type</b> :- Cash	<b>Consultant</b> :- Dr Santosh Verma (MBBS,MS)	
<b>Token No</b> :- NOR. - 2	<b>Paid/Bal</b> :- 0.00 /30.00	
<b>Patient Type</b> :- Normal		
<b>Address</b> :- J 12/135A 6 DHOOP CHANDI - 2210022,varanasi		

BP :-  
height :-  
Weight (kg) :-  
BMI :-

**Rx**

L 6/6      ~~7/8~~  
R 6/6      ~~7/8~~

L NB  
R NB

RE. All camp

7  
Comp 2 FORTÉ PLUS 1000 10 days  
B/E

G. CLEAR EYE TDS  
G. LUBSTAME ULTRA TDS

Adv. - 210 days

Printed By : Mr Siddhant Dwivedi  
Created By : Mr Siddhant Dwivedi

**Dr. SANTOSH VERMA**  
MBBS, MS (Ophthalmologist)  
MCI Reg. No. 09-34327 of 1



# PANACEA HOSPITAL

B 36/44 F.K KABIR NAGAR, DURGAKUND  
TOLLFREE NO-18001233070. Whatsapp No - 8795832852  
www.piire.org  
panaceaquery@gmail.com|panceahospitalit@gmail.com



## OP Slip

Print Date : 09-Mar-2024 09:35AM



<b>UHID No</b> :- UD-23240006696	<b>OP No</b> :- OP-23240020561	<b>OP Date</b> :- 09 Mar 2024 9:33AM
<b>Patient Name</b> :- Mr VINAY PRAKASH MAURYA	<b>Age/Sex</b> :- 39 Y/Male	<b>Mobile No</b> :- 8600108474
<b>Father</b> :- RAM NARESH MAURYA	<b>Department</b> :- DERMATOLOGY	
<b>Pay Type</b> :- Cash	<b>Consultant</b> :- Dr DR ASHUTOSH MISHRA (MBBS,MD)	
<b>Token No</b> :- NOR. - 2	<b>Paid/Bal</b> :- 0.00 /30.00	
<b>Patient Type</b> :- Normal		
<b>Address</b> :- J 12/135A 6 DHOOP CHANDI - 2210022,varanasi		

BP :-  
height :-  
Weight (kg) :-  
BMI :-

Rx

*Handwritten notes:*  
 Rx  
 mhwadul s... C?  
 Derm... report... AID  
 Hair ... B/w

*Handwritten signature:* 30day



Printed By : Mr Siddhant Dwivedi  
Created By : Mr Siddhant Dwivedi

**Facilities:**

All clinical Biomedical & Hematology Investigations including Bone Marrow Examination  
VPT, Podiascan & Complete Foot Care (First Time in Purvanchal)  
All Hormonal Investigation by Chemiluminescent Method  
Visceral Fat by (AB-140) Ambulatory BP Monitoring  
CGMS & Insulin Pump Available  
PFT, 2D-ECHO (Color Doppler), Holter, TMT, Cardiac-3 available  
VIA, VILI, Colposcopy available  
Special Endocrinological Investigation Protocols.

ISO 9001:2008 Certified  
Mobile: 9389994334, 9554572190, 9453837595



# Panacea Pathology

## Clinical Reference Lab

Persistence, Preparedness and Precision  
EQAS (CMC Vellore Attached) & IQAS System  
पूर्वांचल की सर्वोत्तम गुणवत्ता वाली पैथोलॉजी

**UHID No** :- UD-23240006696 **Booking No/Date** :- 75 / 09-Mar-2024 02:24 PM  
**Patient Name** :- Mr VINAY PRAKASH MAURYA **Age/Sex** :- 39 Y/M  
**Father** :- RAM NARESH MAURYA **OP No** :- OP-23240020561  
**Address** :- J 12/135A 6 DHOOP CHANDI - 2210022, varanasi **Mobile No** :- 8600108474  
**Consultant** :- Dr Pallavi Mishra (MBBS,MD)

Investigations	Observations	Biological Ref. Interval	Unit
----------------	--------------	--------------------------	------

### HAEMATOLOGY

Investigations	Observations	Biological Ref. Interval	Unit
<b>CBC</b>			
HAEMOGLOBIN <small>DefaultMethod / test Machine</small>	13.9	13.00 - 16.00	gm/dl
TLC <small>Methology / Carm</small>	7,500	4000.00 - 11000.00	Cells/cumm.
DLC DIFFERENTIAL LEUCOCYTE COUNT			
NEUTROPHILS	68	40.00 - 75.00	%
LYMPHOCYTES	25	20.00 - 45.00	%
EOSINOPHILS	04	1.00 - 6.00	%
MONOCYTES	03	2.00 - 10.00	%
BASOPHILS	00	&lt;1-2	%
PLATELET COUNT	2.05	1.50 - 4.10	lacs /cumm
PCV	40.2	33.00 - 42.00	%
RBC <small>Methology / Carm</small>	4.36	4.50 - 5.50	million/cumm
MCV(MEAN CELL VOLUME)	94.0	83.00 - 101.00	fl
MCH(MEAN CELL HAEMOGLOBIN)	29.0	27.00 - 32.00	pg
MCHC	33.7	31.50 - 35.00	gm%

### URINE EXAMINATION

#### URINE ROUTINE EXAMINATION

Consulting Pathologist

DR. UMESH KUMAR  
MBBS (DIPLOMA IN PATHOLOGY)  
MCI Reg. No. 41413

Lab Technician

Timing : 24/7 hrs

This Report is not valid for medico legal purpose

Note: These tests have technical limitations. Clinico-pathological interpretation is necessary. In case of any disparity test may be repeated immediately.

Address : 36/44 FK Kabir Nagar, Durgakund, Varanasi – 221005

Email: [dramishra@gmail.com](mailto:dramishra@gmail.com), [drpallaviojha@gmail.com](mailto:drpallaviojha@gmail.com) Website: [panaceahospital.org](http://panaceahospital.org)

**Facilities:**

All clinical Biomedical & Hematology Investigations including Bone Marrow Examination  
VPT, Podiascan & Complete Foot Care (First Time in Purvanchal)  
All Hormonal Investigation by Chemiluminescent Method  
Visceral Fat by (AB-140) Ambulatory BP Monitoring  
CGMS & Insulin Pump Available  
PFT, 2D-ECHO (Color Doppler), Holter, TMT, Cardiac-3 available  
VIA, VILI, Colposcopy available  
Special Endocrinological Investigation Protocols.

ISO 9001:2008 Certified  
Mobile: 9389994334, 9554572190, 9453837595



# Panacea Pathology

## Clinical Reference Lab

Persistence, Preparedness and Precision  
EQAS (CMC Vellore Attached) & IQAS System  
पूर्वाचल की सर्वोत्तम गुणवत्ता वाली पैथोलॉजी

**UHID No** :- UD-23240006696 **Booking No/Date** :- 75 / 09-Mar-2024 02:24 PM  
**Patient Name** :- Mr VINAY PRAKASH MAURYA **Age/Sex** :- 39 Y/M  
**Father** :- RAM NARESH MAURYA **OP No** :- OP-23240020561  
**Address** :- J 12/135A 6 DHOOP CHANDI - 2210022 , varanasi **Mobile No** :- 8600108474  
**Consultant** :- Dr Pallavi Mishra (MBBS,MD)

Investigations	Observations	Biological Ref. Interval	Unit
<b><u>PHYSICAL EXAMINATION</u></b>			
QUANTITY	25		ml
COLOR <i>Methology</i>	STRAW	CLEAR YELLOW	
APPEARANCE <i>DefaultMethod</i>	CLEAR	CLEAR	
<b><u>CHEMICAL EXAMINATION</u></b>			
SPECIFIC GRAVITY	1.015	1.01 - 1.03	
PH	6.0	4.60 - 8.00	
GLUCOSE	NIL	60.00 - 100.00	mg/dl
PROTEIN-	NIL		
<b><u>MICROSCOPIC EXAMINATION</u></b>			
PUS CELLS	01-02	2.00 - 3.00	/HPF
RBCS ( RED BLOOD CELLS)	NIL	4.50 - 5.50	/HPF
EPITHELIAL CELLS	NIL		/HPF
CASTS	ABSENT	ABSENT	
CRYSTALS	ABSENT	ABSENT	

### **HAEMATOLOGY**

**ESR** 12.0 0.00 - 15.00 mm at 1 hr

### **BLOOD GROUP ABO & RH FACTOR**

Lab Technician

Timing : 24/7 hrs

Consulting Pathologist

Dr. Umesh Kumar  
M.D. Pathology  
MBBS, MCh (Pathology)  
MCI Reg. No. 41413

This Report is not valid for medico legal purpose

Note: These tests have technical limitations. Clinico-pathological interpretation is necessary. In case of any disparity test may be repeated immediately.

Address : 36/44 FK Kabir Nagar, Durgakund, Varanasi – 221005

Email: [dramishra@gmail.com](mailto:dramishra@gmail.com), [drpallaviojha@gmail.com](mailto:drpallaviojha@gmail.com) Website: [panaceahospital.org](http://panaceahospital.org)

**Facilities:**

All clinical Biomedical & Hematology Investigations including Bone Marrow Examination  
 VPT, Podiascan & Complete Foot Care (First Time in Purvanchal)  
 All Hormonal Investigation by Chemiluminescent Method  
 Visceral Fat by (AB-140) Ambulatory BP Monitoring  
 CGMS & Insulin Pump Available  
 PFT, 2D-ECHO (Color Doppler), Holter, TMT, Cardiac-3 available  
 VIA, VILI, Colposcopy available  
 Special Endocrinological Investigation Protocols.

ISO 9001:2008 Certified  
 Mobile: 9389994334, 9554572190, 9453837595



# Panacea Pathology

## Clinical Reference Lab

Persistence, Preparedness and Precision  
 EQAS (CMC Vellore Attached) & IQAS System  
 पूर्वांचल की सर्वोत्तम गुणवत्ता वाली पैथोलॉजी

**UHID No** :- UD-23240006696 **Booking No/Date** :- 75 / 09-Mar-2024 02:24 PM  
**Patient Name** :- Mr VINAY PRAKASH MAURYA **Age/Sex** :- 39 Y/M  
**Father** :- RAM NARESH MAURYA **OP No** :- OP-23240020561  
**Address** :- J 12/135A 6 DHOOP CHANDI - 2210022 , varanasi **Mobile No** :- 8600108474  
**Consultant** :- Dr Pallavi Mishra (MBBS,MD)

Investigations	Observations	Biological Ref. Interval	Unit
BLOOD GROUP	"A"		
RH FACTOR	POSITIVE		
<b>HBA1C -(BY GOLD STANDARD METHOD :HPLC)</b>	6.2	Normal: 4.0 - 5.4 Prediabetic : 5.5 -6.3 Diabetes mellitus := 6.4	%
<b><u>BIOCHEMISTRY</u></b>			
<b>BUN</b>	11.0	7.00 - 21.00	mg/dl
<b>URIC ACID</b>			
URIC ACID	4.6	3.60 - 7.70	mg/dl
<b><u>IMMUNOLOGY</u></b>			
<b>THYROID PROFILE (T3,T4,TSH)</b>			
T3	0.98	0.60 - 1.81	ng/ml
T4	6.2	4.50 - 10.90	ug/dl
TSH	1.02	0.39 - 6.10	uIU/mL
<b><u>BIOCHEMISTRY</u></b>			
<b>BLOOD SUGAR FASTING</b>			
GLUCOSE	<b>143.0</b>	60.00 - 100.00	mg/dl
PRE-DIABETICS(IMPAIRED FASTING TOLER)	-	100.00 - 125.00	mg/dl
DIABETICS	-	upto 126	mg/dl

  
 Consulting Pathologist

**DR. UMESH KUMAR**  
 MBBS, MD (PATHOLOGIST)  
 MCI Reg. No. 41413

Lab Technician

Timing : 24/7 hrs

This Report is not valid for medico legal purpose

Note: These tests have technical limitations. Clinico-pathological interpretation is necessary. In case of any disparity test may be repeated immediately.

Address : 36/44 FK Kabir Nagar, Durgakund, Varanasi – 221005

Email: [dramishra@gmail.com](mailto:dramishra@gmail.com), [drpallaviojha@gmail.com](mailto:drpallaviojha@gmail.com) Website: [panaceahospital.org](http://panaceahospital.org)

**Facilities:**

All clinical Biomedical & Hematology Investigations including Bone Marrow Examination  
VPT, Podiascan & Complete Foot Care (First Time in Purvanchal)  
All Hormonal Investigation by Chemiluminescent Method  
Visceral Fat by (AB-140) Ambulatory BP Monitoring  
CGMS & Insulin Pump Available  
PFT, 2D-ECHO (Color Doppler), Holter, TMT, Cardiac-3 available  
VIA, VILI, Colposcopy available  
Special Endocrinological Investigation Protocols.

ISO 9001:2008 Certified

Mobile: 9389994334, 9554572190, 9453837595

**Panacea Pathology****Clinical Reference Lab**

Persistence, Preparedness and Precision  
EQAS (CMC Vellore Attached) & IQAS System  
पूर्वांचल की सर्वोत्तम गुणवत्ता वाली पैथोलॉजी

**UHID No** :- UD-23240006696 **Booking No/Date** :- 75 / 09-Mar-2024 02:24 PM  
**Patient Name** :- Mr VINAY PRAKASH MAURYA **Age/Sex** :- 39 Y/M  
**Father** :- RAM NARESH MAURYA **OP No** :- OP-23240020561  
**Address** :- J 12/135A 6 DHOOP CHANDI - 2210022 , varanasi **Mobile No** :- 8600108474  
**Consultant** :- Dr Pallavi Mishra (MBBS,MD)

Investigations	Observations	Biological Ref. Interval	Unit
TARGET IN DM	-	80.00 - 130.00	mg/dl

**BIOCHEMISTRY****PPBS(POST PRANDIAL BLOOD SUGAR)**

POST PRANDIAL BLOOD GLUCOSE(2 HR AFTER MEAL)	<b>232.0</b>	110.00 - 150.00	mg/dl
IGT(2 HR 75GM GLUCOSE)	-	140.00 - 199.00	mg/dl
DIABETES	-	upto200	mg/dl
TARGET IN DM	-	80.00 - 130.00	mg/dl

**BIOCHEMISTRY****LIPID PROFILE**

TOTAL CHOLESTROL	171.0	Desirable : - &lt; 200 mg/dL Borderline: - 200 - 239 mg/dL High : - &gt; 240mg/dL	mg/dl
TRIGLYCERIDES	<b>168.0</b>	35.00 - 160.00	mg/dl
HDL CHOLESTROL	48.0	35.30 - 79.50	mg/dl
LDL CHOLESTROL	89.4	&lt;130	mg/dl
VLDL	33.60	&lt;40	mg/dl
CHOLESTROL/ HDL RATIO	3.56	&lt;3.0 LOW RISK, 3.0-5.0 AVG RISK, &gt;5.0 HIGH RISK	ratio
LDL/HDL RATIO	1.86	&lt;3	ratio

  
Consulting Pathologist

DR. UMESH KUMAR  
MBBS, MD, (PATHOLOGIST)  
MCI Reg. No. 41413

Lab Technician

Timing : 24/7 hrs

This Report is not valid for medico legal purpose

Note: These tests have technical limitations. Clinico-pathological interpretation is necessary. In case of any disparity test may be repeated immediately.

Address : 36/44 FK Kabir Nagar, Durgakund, Varanasi - 221005

Email: [dramishra@gmail.com](mailto:dramishra@gmail.com), [drpallaviojha@gmail.com](mailto:drpallaviojha@gmail.com) Website: [panaceahospital.org](http://panaceahospital.org)



**Facilities:**

All clinical Biomedical & Hematology Investigations  
including Bone Marrow Examination  
VPT, Podiascan & Complete Foot Care (First Time in Purvanchal)  
All Hormonal Investigation by Chemiluminescent Method  
Visceral Fat by (AB-140) Ambulatory BP Monitoring  
CGMS & Insulin Pump Available  
PFT, 2D-ECHO (Color Doppler), Holter, TMT, Cardiac-3 available  
VIA, VILI, Colposcopy available  
Special Endocrinological Investigation Protocols.

ISO 9001:2008 Certified

Mobile: 9389994334, 9554572190, 9453837595

**Panacea Pathology****Clinical Reference Lab**

Persistence, Preparedness and Precision  
EQAS (CMC Vellore Attached) & IQAS System  
पूर्वांचल की सर्वोत्तम गुणवत्ता वाली पैथोलॉजी

**UHID No** :- UD-23240006696 **Booking No/Date** :- 75 / 09-Mar-2024 02:24 PM  
**Patient Name** :- Mr VINAY PRAKASH MAURYA **Age/Sex** :- 39 Y/M  
**Father** :- RAM NARESH MAURYA **OP No** :- OP-23240020561  
**Address** :- J 12/135A 6 DHOOP CHANDI - 2210022 , varanasi **Mobile No** :- 8600108474  
**Consultant** :- Dr Pallavi Mishra (MBBS,MD)

Investigations	Observations	Biological Ref. Interval	Unit
<b>LFT (LIVER FUNCTION TESTS)</b>			
TOTAL BILIRUBIN	0.72	0.00 - 1.20	mg/dl
DIRECT BILIRUBIN	0.25	0.00 - 0.30	
INDIRECT BILIRUBIN	0.47	0.20 - 0.70	mg/dl
SGOT	28.0	2.00 - 31.00	U/L
SGPT	32.0	10.00 - 45.00	U/L
ALKALINE PHOSPHATASE	64.0	25.00 - 140.00	U/L
TOTAL PROTIENS	7.34	6.60 - 8.70	g/dl
ALBUMIN	4.10	3.50 - 5.20	gm%
GLOBULIN	3.24	1.50 - 3.60	gms/dl
A/G RATIO	1.26	2:1	RATIO
YGGT	21.0	10.00 - 50.00	U/L
<b>S.CREATININE</b>	0.89	0.60 - 1.40	mg/dl

**PARASITOLOGY****STOOL ROUTINE****GROSS EXAMINATON**

COLOR METHology YELLOW CLEAR YELLOW  
CONSISTANCY NORMAL

Lab Technician

Consulting Pathologist

DR: UMESH KUMAR  
MBBS, MD (PATHOLOGIST)  
MCI Reg. No. 41413

Timing : 24/7 hrs

This Report is not valid for medico legal purpose

Note: These tests have technical limitations. Clinico-pathological interpretation is necessary. In case of any disparity test may be repeated immediately.

Address : 36/44 FK Kabir Nagar, Durgakund, Varanasi – 221005

Email: [dramishra@gmail.com](mailto:dramishra@gmail.com), [drpallaviojha@gmail.com](mailto:drpallaviojha@gmail.com) Website: [panaceahospital.org](http://panaceahospital.org)

**Facilities:**

All clinical Biomedical & Hematology Investigations including Bone Marrow Examination  
 VPT, Podiascan & Complete Foot Care (First Time in Purvanchal)  
 All Hormonal Investigation by Chemiluminescent Method  
 Visceral Fat by (AB-140) Ambulatory BP Monitoring  
 CGMS & Insulin Pump Available  
 PFT, 2D-ECHO (Color Doppler), Holter, TMT, Cardiac-3 available  
 VIA, VILI, Colposcopy available  
 Special Endocrinological Investigation Protocols.

ISO 9001:2008 Certified  
 Mobile: 9389994334, 9554572190, 9453837595



# Panacea Pathology

## Clinical Reference Lab

Persistence, Preparedness and Precision  
 EQAS (CMC Vellore Attached) & IQAS System  
 पूर्वांचल की सर्वोत्तम गुणवत्ता वाली पैथोलॉजी

**UHID No** :- UD-23240006696 **Booking No/Date** :- 75 / 09-Mar-2024 02:24 PM  
**Patient Name** :- Mr VINAY PRAKASH MAURYA **Age/Sex** :- 39 Y/M  
**Father** :- RAM NARESH MAURYA **OP No** :- OP-23240020561  
**Address** :- J 12/135A 6 DHOOP CHANDI - 2210022 , varanasi **Mobile No** :- 8600108474  
**Consultant** :- Dr Pallavi Mishra (MBBS,MD)

Investigations	Observations	Biological Ref. Interval	Unit
BLOOD	ABSENT		
MUCUS	ABSENT		
<b><u>MICROSCOPIC EXAMINATION</u></b>			
OVA OR EGGS OF HELMINTHS	ABSENT		
CYST OF PROTOZOA	ABSENT		
VEG. FORMS OF PROTOZOA	ABSENT		
PUS CELLS	03-04	2.00 - 3.00	/HPF
RBC <i>Methology / Carm</i>	NIL	4.50 - 5.50	million/cumm

\* END OF REPORT \*

Consulting Pathologist

DR. UMESH KUMAR  
 MBBS, MD (PATHOLOGY)  
 MCI Reg. No. 41413

Lab Technician

Timing : 24/7 hrs

This Report is not valid for medico legal purpose

Note: These tests have technical limitations. Clinico-pathological interpretation is necessary. In case of any disparity test may be repeated immediately.

Address : 36/44 FK Kabir Nagar, Durgakund, Varanasi – 221005

Email: [dramishra@gmail.com](mailto:dramishra@gmail.com), [drpallaviojha@gmail.com](mailto:drpallaviojha@gmail.com) Website: [panaceahospital.org](http://panaceahospital.org)



# PANACEA HOSPITAL



*A shelter for many hearts A Home for many lives*

(An ISO 9001:2008 Certified Organisation)  
Lab Attached with CMC Under EQAS Scheme

Dept. of Radiodiagnosis - 32 Slice CT Scan, 3D/4D USG, 2D ECHO, Colour Doppler, Intervention Procedures, Digital X-Ray

PATIENT'S NAME : VINAY PRAKASH MAURYA

AGE/SEX: 39 Y/M

REF. BY : Dr. ASHUTOSH MISHRA (MD)

Saturday, March 09, 2024

## Echo - Cardiography

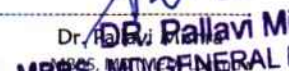
MITRAL VALVE Doppler	AML - normal morphology MV Flow - E - 0.5 A-0.4 E/A=1.61	PML - normal morphology MVA - 3.0 cm <sup>2</sup> Mitral Regurgitation - No
TRICUSPID VALVE Doppler	Normal TV Flow -No	Tricuspid Regurgitation -No
PULMONARY VALVE Doppler	Normal PV Flow -No	Pulmonary Regurgitation - No
AORTIC VALVE Doppler	Trileaflet-No AV Flow - no	Aortic Regurgitation - no
MEASUREMENT	Aorta - 24.0 (20-38) mm IVS ed - 8.6 (6 -12) mm LVID ed -44.0 (35 - 55) mm LVPW ed - 13.0 (6 -12) mm OA - 7 (> 5) mm	LA - 26.3 (24-32) mm IVS es -10.9 (6 - 12) mm LVID es - 30.3 (24 - 40) mm LVPW es -12.0 (6 -12) mm EPSS - 4 (< 9) mm

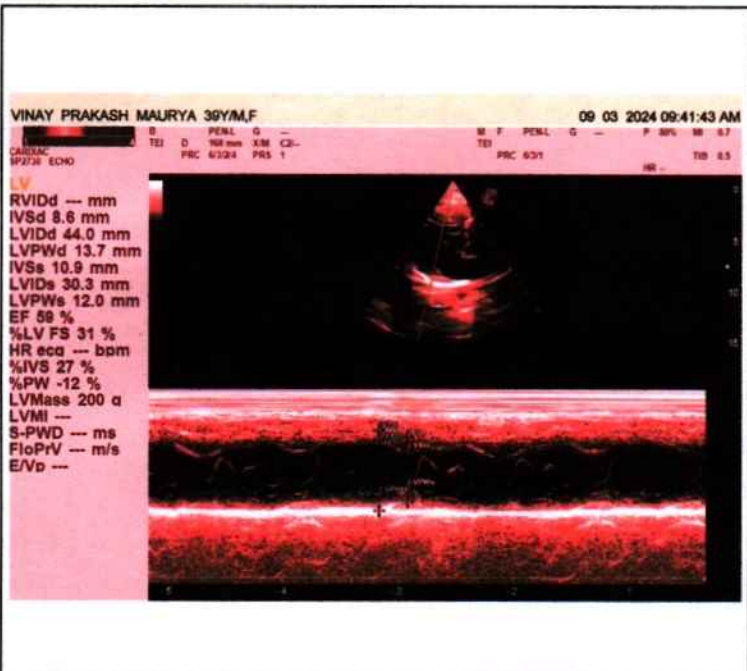
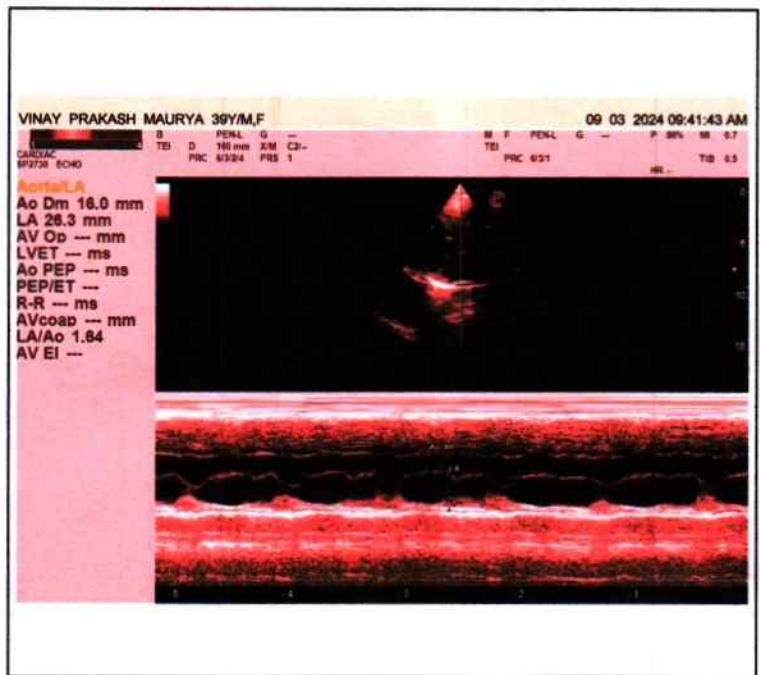
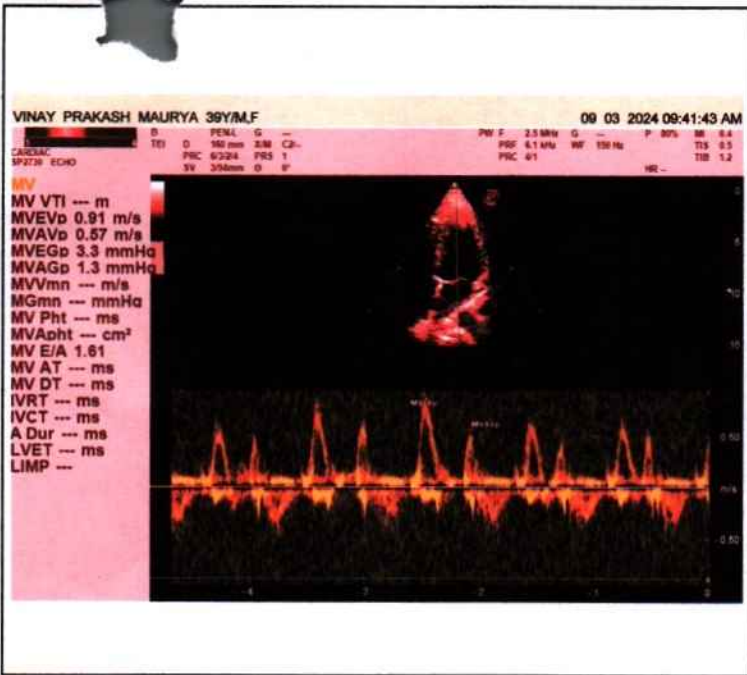
**CONCLUSION**

All cardiac chamber dimensions are WNL  
No valvular abnormalities  
Good LV systolic function present Modified Simpson's method (4C, 2C) (LVEF=59%)  
No diastolic dysfunction present (E/A = 1.61)  
No RWMA  
No pericardial effusion  
Intact IAS / IV  
No PAH  
No intra cardiac mass /thrombus /vegetation

**IMPRESSION** **Normal Echocardiogram**

  
Niraj Mishra  
Physician Assistant  
(PIIRE)

  
Dr. Pallavi Misra  
MBBS, MD (GENERAL MEDICINE)  
Echocardiography speciality  
MCI Reg. No: 52033  
Non-invasive cardiologist  
Women Cardiologist  
Diabetocardiologist





# PANACEA HOSPITAL



*A shelter for many hearts A Home for many lives*

(An ISO 9001:2008 Certified Organisation)  
Lab Attached with CMC Under EQAS Scheme

Dept. of Radiodiagnosis - 32 Slice CT Scan, 3D/4D USG, 2D ECHO, Colour Doppler, Intervention Procedures, Digital X-Ray

NAME: VINAY PRAKASH MAURYA  
REF.DR. DR.ASHUTOSH MISHRA(MD)

AGE/SEX: 39 YRS/MALE  
DATE: 09/03/2024

## ULTRA SOUND WHOLE ABDOMEN REPORT

**Liver:** Normal in size, shape & echogenicity. Intra & extra hepatic biliary Radicals & Vascular structures are normal. Margins are smooth and regular.

**Gall bladder:** Normally distended with echo free lumen.

**Portal vein:** Normal in course and caliber.

**CBD diameter:** Visualized part normal in course & caliber.

**Pancreas:** Normal in size, shape & echogenicity. Margins are smooth & regular. No diffuse/ focal lesion seen. Pancreatic duct not visualized.

**Spleen:** Normal in size, shape & echogenicity. Margins are smooth & regular.  
No diffuse / focal lesion seen. Splenic vessels at hilum is normal.

**Kidney:** Both normal in size, shape echogenicity & position. Cortical-medullary differentiation is maintained. Pelvicalyceal system normal. No evidence of any calculus/mass lesion seen  
No hydronephrosis/ hydroureter seen. No suprarenal mass lesion.

**Urinary bladder:** Normally distended with normal wall thickness. No echogenic foci lumen or diverticula seen.  
Both VUJ appears normal. No evidence of calculus / mass lesion seen.

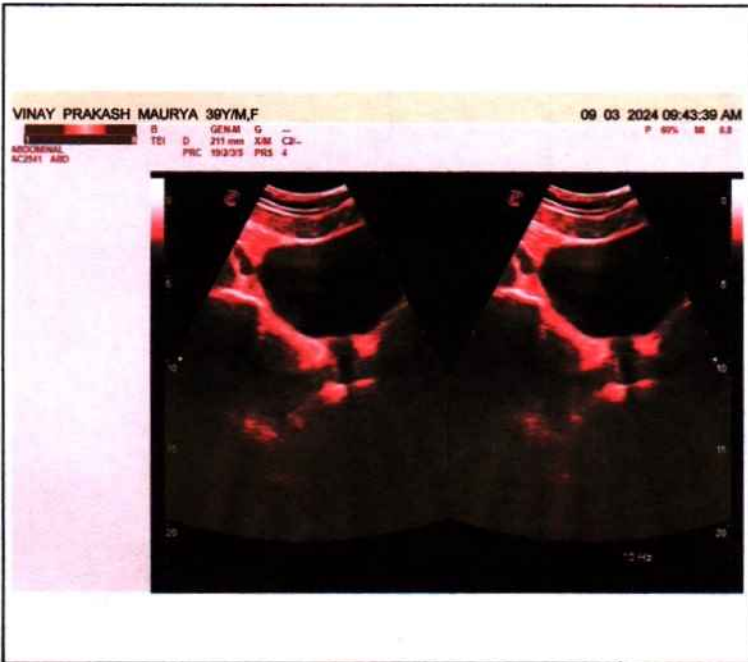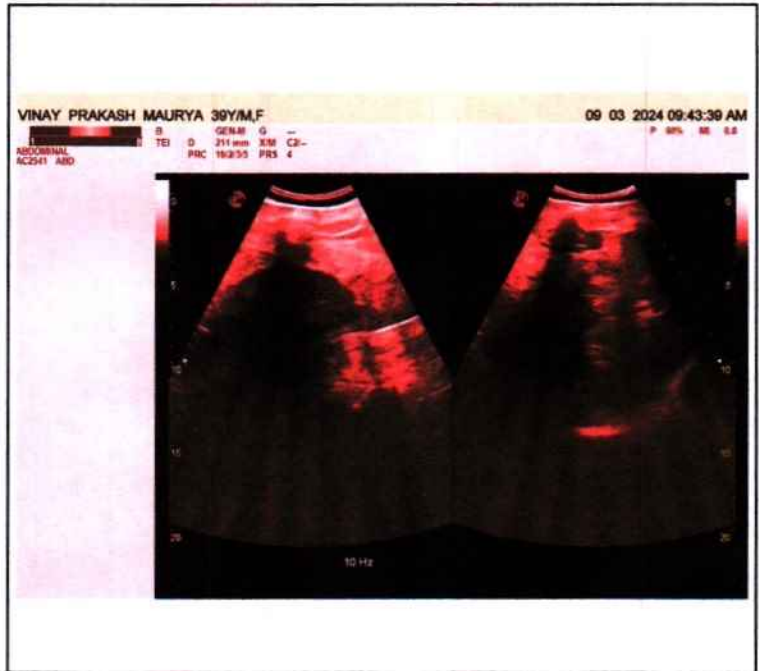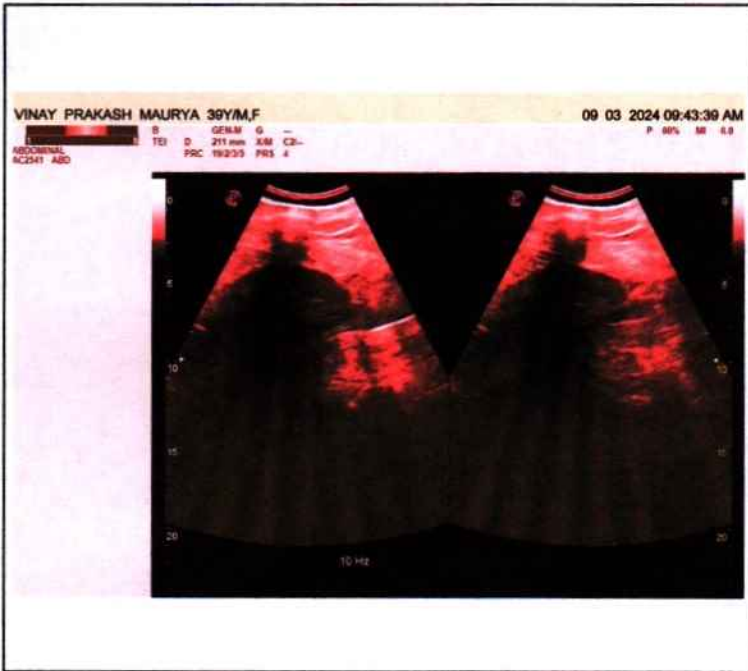
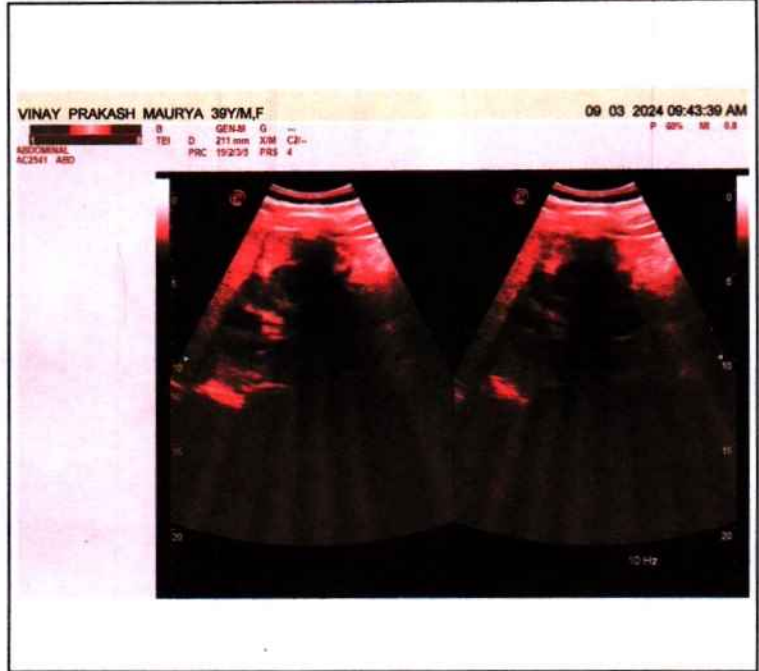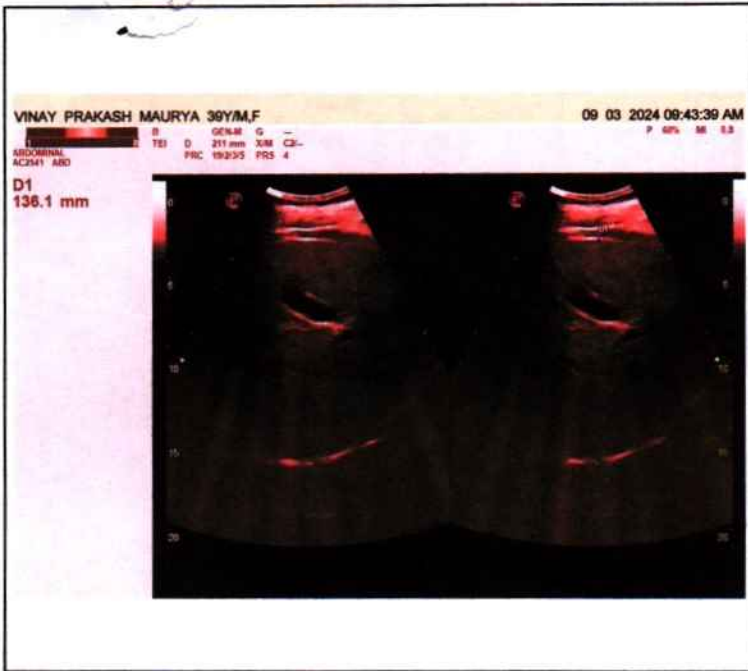**Prostate:** Normal in size, shape & echogenicity..

**Others:** No free fluid in peritoneal cavity.  
No free fluid in bilateral pleural cavity.  
No evidence of significantly enlarged retroperitoneal/ mesenteric lymph nodes noted.

**IMPRESSION: -** **NO OBVIOUS SONOLOGICAL ABNORMALITY SEEN.**

Please correlate clinically and further investigations.

*R*  
Radiologist  
Dr. Rahul Kumar Tiwari  
MBBS, MD (Radio Diagonosis)  
Reg. No. 57557





# PANACEA HOSPITAL



*A shelter for many hearts    A Home for many lives*

(An ISO 9001:2008 Certified Organisation)  
Lab Attached with CMC Under EQAS Scheme

Dept. of Radiodiagnosis - 32 Slice CT Scan, 3D/4D USG, 2D ECHO, Colour Doppler, Intervention Procedures, Digital X-Ray

<b>PATIENT'S NAME</b>	: <b>VINAY PRAKASH MAURYA</b>	<b>AGE</b> 39Y/ <b>SEX</b> :M
<b>REF. BY</b>	: <b>Dr. ASHUTOSH MISHRA(MD)</b>	<b>DATE</b> :09/03/2024

## X-RAY CHEST (PA VIEW)

- Bilateral lung fields appear normal.
- Trachea and mediastinum appear normal in position.
- Both hila appear normal in size and are symmetrical.
- Transverse cardiac diameter is within normal limits.
- Great vessels appear normal
- Both CP angles appear clear. Normal position and contour diaphragms noted.
- Bony rib cage and soft tissue shadows appear normal.

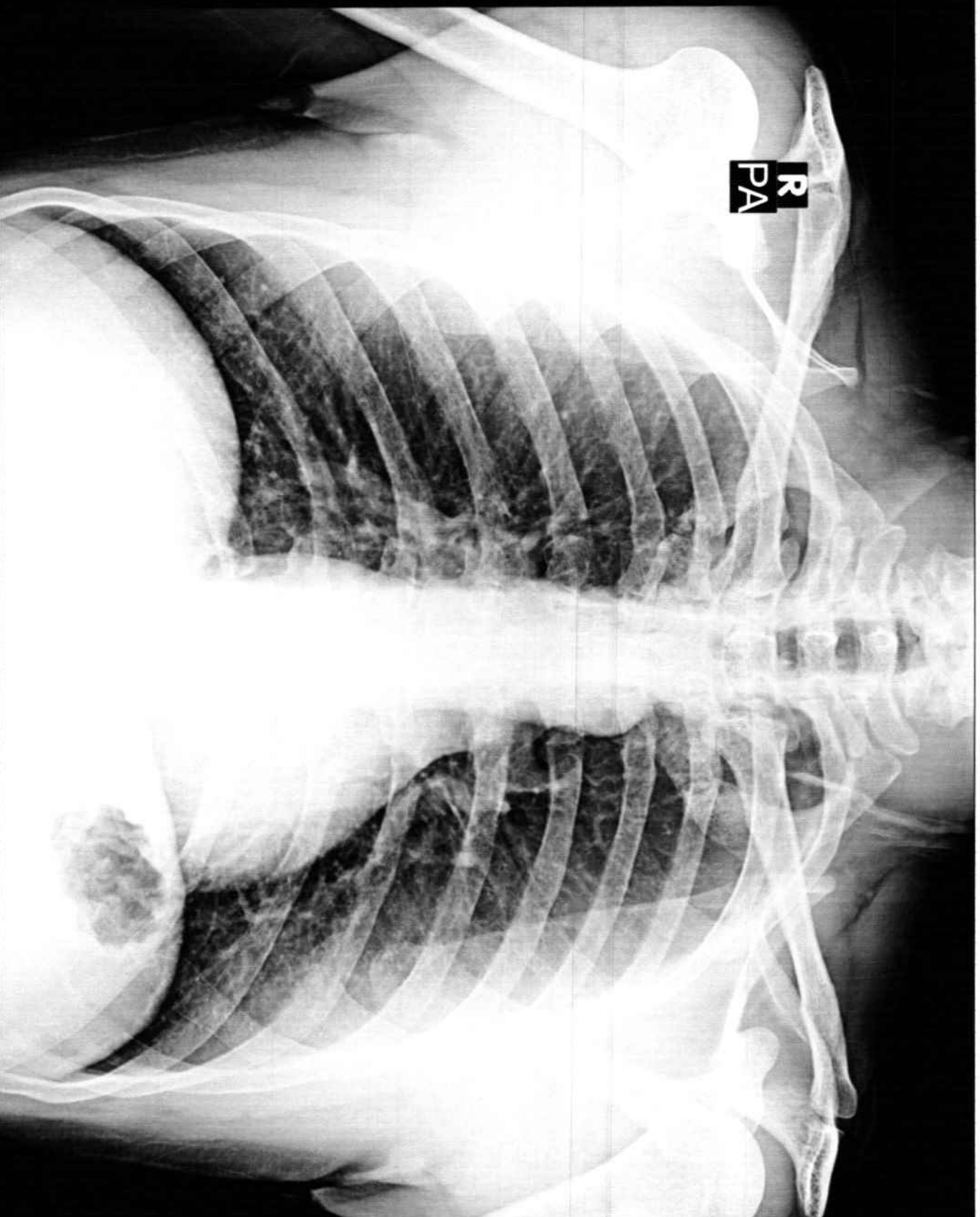
## IMPRESSION

- **No obvious abnormality noted in the chest radiograph.**

*Thanks for reference.*

*Radiologist*

Dr. Rahul Kumar Tiwan  
MBBS, MD (Radio Diagonosis)  
Reg. No. 57557



VINAY PRAKASH MAURYA 39Y/M 6696 M CHEST P.A. 09-Mar-24 10:28 AM

PANACEA HOSPITAL, KABIR NAGAR, DURGAKUND, VARANASI



10mm/mV

10mm/mV

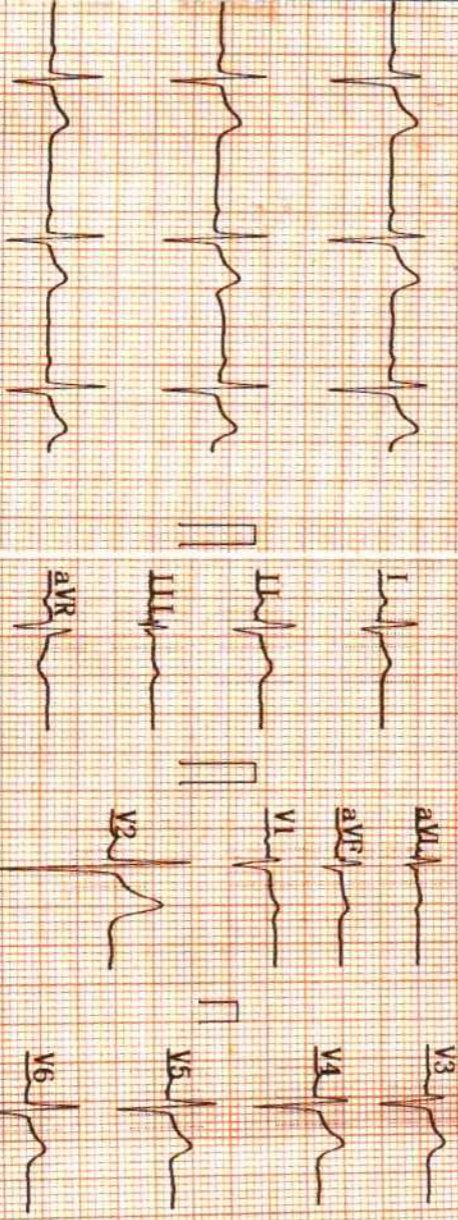
5mm/mV

2024-03-09 10:13

<< Conclusions >>

Normal Sinus Rhythm;  
Cardiac electric axis normal;

\*\*Report need physician confirm\*\*



ID	:	
Name	:	Vinay Prakash Mishra
Sex	:	M
Height	:	172
SYS	:	
DIA	:	
HR	:	74 [bpm]
PR Interval	:	154 [ms]
P Duration	:	106 [ms]
QRS Duration	:	76 [ms]
T Duration	:	183 [ms]
QT/QTc	:	332/368 [ms]
P/QRS/T Axis	:	30.1/53.4/51.7 [deg]
R(V5)/S(V1)	:	1.28/0.46 [mV]
R(V5)/S(V1)	:	

DR. Pallavi Misra  
 MBBS, MD/GENERAL MEDICINE  
 MCI Reg. No. 52033  
 Physicist  
 9838889966

25mm/s

PPKAR HEALTH CARE INDIA PVT. LTD. VNS. CELL  
 9838889966

AUTO 10mm/mV

10mm/mV

10mm/mV

5mm/mV



aVR



V4



aVL



V5



aVF



V6



V1



V3



25mm/s AC50Hz