



Mediwheel
...Your wellness partner

Arcofemi Healthcare Pvt Ltd

(Formerly known as Arcofemi Healthcare Ltd)

F-701A, Lado Sarai, Mehrauli, New Delhi - 110030

Email: wellness@mediwheel.in, Website: www.mediwheel.in

Tel: +91-11-41195959, Fax: +91-11-29523020

CIN: U24240DL2011PTC216307

MEDICAL FITNESS CERTIFICATE

(To be signed by a registered medical practitioner holding a Medical degree)

This is to certify that **Mr. Saubhagya Bhowmick** aged, **24yr**. Based on the examination, I certify that he is in good mental and physical health and it is free from any physical defects such as deafness, colour blindness, and any chronic or contagious diseases.

Place: Mumbai

Date: 17/05/2024

Dr. Nitesh Kumar
Nitesh Kumar
MBBS
BCMR 47093
Name & Signature of
Medical officer

MEDICAL HEALTH CHECK- UP ASSESMENT FORM

NAME: Mr / Mrs Saubhagya Bhomick DATE: 17/05/24

AGE: 24 Yrs / M

SEX: Male / Female

NMU: NMU000 53539

DOCTOR'S NAME:

TEMP :	<u>97.3</u>	° f	BP :	<u>129 / 71</u>	mmHg
PULSE :	<u>87</u>	b/m	HEIGHT :	<u>172</u>	cm
RR :	<u>20</u>	b/m	WEIGHT :	<u>75.3</u>	kg
SPO2 :	<u>98</u> %		HGT:	<u>—</u>	

REMARK:



MEDICOVER
HOSPITALS

NAVI MUMBAI

MEDICAL CERTIFICATE

I, Dr. Ahmed Khan.....do hereby certify that I have carefully examined .

Sri./Smt. Saubhagya..... , son / daughter.

Of Samiran..... is physically fit / unfit to join Organization .

Signature of Doctor: .....

Registration No :

Dr. AHMED KHAN
MBBS, MD (Internal Medicine)
Reg. No. MMC 2015/01/0236

Place : Chandigarh.....

Date : 17/1/20.....

Seal :



Patient ID:	NMU0053539	Patient Name:	SAUBHAGYA BHOMICK
Age:	24 Years	Sex:	M
Accession Number:	NMBC70687	Modality:	DX
Referring Physician:	DR.DMO	Study:	CHEST
Study Date:	17-May-2024		

X RAY CHEST PA VIEW

Both lungs are clear.

The frontal cardiac dimensions are normal.

The pleural spaces are clear.

Both hilar shadows are normal in position and density.

No diaphragmatic abnormality is seen.

The soft tissues and bony thorax are normal.

Impression:

- **No significant abnormality is seen.**



DR. SUYOG SANGALE
MBBS DMRE
CONSULTANT RADIOLOGIST

Date: 17-May-2024 12:00:32



DEPARTMENT OF LABORATORY

NAVI MUMBAI

Patient Name : Mr. SAUBHAGYA BHOMICK	Age / Gender : 24 Y(s)/Male
Bill No/ UMR No : NMBC70687/NMU0053539	Referred By : Dr. DMO
Received Dt : 17-May-24 10:09 am	Report Date : 17-May-24 02:45 pm

FINAL REPORT

<u>Parameters</u>	<u>Specimen</u>	<u>Result</u>	<u>Biological Reference Intervals</u>	<u>Method</u>
CUE(COMPLETE URINE EXAMINATION)				
<u>PHYSICAL EXAMINATION</u>				
VOLUME	Urine	20 ml		
COLOUR		PALE YELLOW	PALE YELLOW	
APPEARANCE		SLIGHTLY HAZY	CLEAR	
DEPOSIT		ABSENT	ABSENT	
<u>CHEMICAL EXAMINATION</u>				
SPECIFIC GRAVITY	Urine	1.010	1.000 - 1.030	Dipstick
PH		7.0	5.0 - 8.0	Dipstick
PROTEIN		NEGATIVE	NEGATIVE	Dipstick/Heat coagulation test
GLUCOSE		ABSENT	ABSENT	Dipstick/Benedict's test
UROBILINOGEN		NORMAL	NORMAL	Dipstick
KETONE		NEGATIVE	NEGATIVE	Dipstick/Rothera's Nitroprusside test.
BLOOD		NEGATIVE	NEGATIVE	Dipstick/Microscopy
BILIRUBIN		NEGATIVE	NEGATIVE	Dipstick/Fouchet's test
BILE SALT		NEGATIVE	NEGATIVE	Hay's sulphur powder test
BILE PIGMENT		NEGATIVE	NEGATIVE	Fouchet test
NITRITE		NEGATIVE	NEGATIVE	Dipstick
LEUCOCYTE ESTERASE		NEGATIVE	NEGATIVE	
<u>MICROSCOPIC EXAMINATION</u>				
PUS CELLS	Urine	1-2	0 - 5 /hpf	
RBC		NIL	0 - 5 /hpf	
EPITHELIAL CELLS		Occasional	0 - 5 /hpf	
CRYSTALS		NIL	NIL	
CASTS		NIL	NIL	
BACTERIA		ABSENT		MICROSCOPIC EXAMINATION
YEAST		ABSENT		MICROSCOPIC EXAMINATION
AMORPHOUS DEPOSITS		ABSENT		MICROSCOPIC EXAMINATION
SPERMATOZOA				MICROSCOPIC EXAMINATION
MUCUS THREAD		ABSENT		MICROSCOPIC EXAMINATION





MEDICOVER HOSPITALS

DEPARTMENT OF LABORATORY

NAVI MUMBAI

Patient Name : Mr. SAUBHAGYA BHOMICK	Age / Gender : 24 Y(s)/Male
Bill No/ UMR No : NMBC70687/NMU0053539	Referred By : Dr. DMO
Received Dt : 17-May-24 10:09 am	Report Date : 17-May-24 02:45 pm

Parameters
NOTE

Specimen

Result

Biological Reference In Method

Microscopic examination of urine is carried out on centrifuged urinary sediment.

*** End Of Report ***





DEPARTMENT OF LABORATORY

NAVI MUMBAI

Patient Name : Mr. SAUBHAGYA BHOMICK	Age / Gender : 24 Y(s)/Male
Bill No/ UMR No : NMBC70687/NMU0053539	Referred By : Dr. DMO
Received Dt : 17-May-24 10:09 am	Report Date : 17-May-24 01:59 pm

FINAL REPORT

<u>Parameter</u>	<u>Specimen</u>	<u>Result Values</u>	<u>Biological Reference</u>	<u>Method</u>
COMPLETE BLOOD COUNT				
RBC				
R B C COUNT	Blood	5.06	4.5 - 5.5 $10^6/\mu\text{L}$	
HEMOGLOBIN		15.4	13.0 - 17.0 g/dl	
PCV/HCT		46.1	40 - 50 % 36 - 46 %	
MCV		91	83 - 101 fl 83 - 101 fl	
MCH		30.5	27 - 32 pg	
MCHC		33.4	31.5 - 34.5 g/dL	
RDW(cv)		12.5	11.6 - 14.0 %	
PLATELETS				
PLATELET COUNT	Blood	155	150 - 400 $10^3/\mu\text{L}$	
MPV		13.8	7.5 - 11.5 fl	
WBC				
TC (TOTAL LEUCOCYTE COUNT)	Blood	6.4	4.0 - 11.0 $10^3/\mu\text{l}$	
DIFFERENTIAL COUNT				
NEUTROPHILS	Blood	53	40 - 80 %	
LYMPHOCYTES		37	20 - 40 %	
MONOCYTES		05	02 - 10 %	
EOSINOPHILS		05	00 - 06 %	
BASOPHILS		00	00 - 01 %	
PERIPHERAL SMEAR EXAMINATION		:		
WBC			Normal morphology.	
PLATELETS			Adequate in smear. Giant platelets are seen. Some small platelet aggregates are also noted.	
ESR	CITRATED BLOOD	05	0 - 10 mm/1st hour	WESTERGREN`S METHOD
BLOOD GROUPING AND RH				
BLOOD GROUP		" B "		TUBE AGGLUTINATION
RH TYPE		POSITIVE		

*** End Of Report ***





MEDICOVER
HOSPITALS

DEPARTMENT OF LABORATORY

NAVI MUMBAI

Patient Name : Mr. SAUBHAGYA BHOMICK	Age / Gender : 24 Y(s)/Male
Bill No/ UMR No : NMBC70687/NMU0053539	Referred By : Dr. DMO
Received Dt : 17-May-24 10:09 am	Report Date : 17-May-24 12:26 pm

Parameters

Specimen

Result

TUBE AGGLUTINATI





DEPARTMENT OF LABORATORY

NAVI MUMBAI

Patient Name : Mr. SAUBHAGYA BHOMICK **Age / Gender** : 24 Y(s)/Male
Bill No/ UMR No : NMBC70687/NMU0053539 **Referred By** : Dr. DMO
Received Dt : 17-May-24 10:09 am **Report Date** : 17-May-24 11:57 am

FINAL REPORT

<u>Parameters</u>	<u>Specimen</u>	<u>Result</u>	<u>Biological Reference Intervals</u>	<u>Method</u>
SERUM CREATININE				
CREATININE		0.75	0.8 - 1.3 mg/dl	Method : jaffe
BUN(BLOOD UREA NITROGEN)				
BUN (Blood Urea Nitrogen.)		8	7.0 - 21.0 mg/dL	Calculated
SGPT (ALT)		63	<= 41 U/L	Method : UV without P5P
SERUM BILIRUBIN TOTAL				
DIRECT BILIRUBIN		0.2	0.2 - 1.3 mg/dL	Jendrassik Grof
INDIRECT BILIRUBIN		0.5	<= 0.20 mg/dL	Method: Diazo Method
FBS (FASTING BLOOD GLUCOSE)				
FASTING BLOOD GLUCOSE		93	Normal Range : 70 - 99 mg/dL	Hexokinase
PLBS (POST LUNCH BLOOD GLUCOSE)		78	Norma Range : - < 140 mg/dL Impaired Glucose Tolerance : 140 - 199 mg/dL Diabetes Mellitus : - > 200 mg/dL	Hexokinase

*** End Of Report ***

Lab Incharge


Dr. PALLAVI SAXENA, MBBS MD(PATHOLOGY)
CONSULTANT PATHOLOGIST

Verified By : : 022633

Test results related only to the item tested.

No part of the report can be reproduced without written permission of the laboratory.



HC 53539
24 Years

SAUBHAGYA BHOUMICK
Male

5/17/2024 9:52:05 AM

Rate 76 . Sinus rhythm.....normal P axis, V-rate 50- 99
. Consider left atrial enlargement.....wide or notched P waves
PR 157 . Baseline wander in lead(s) V1
QRSD 90
QT 360
QTc 405

NIR
S

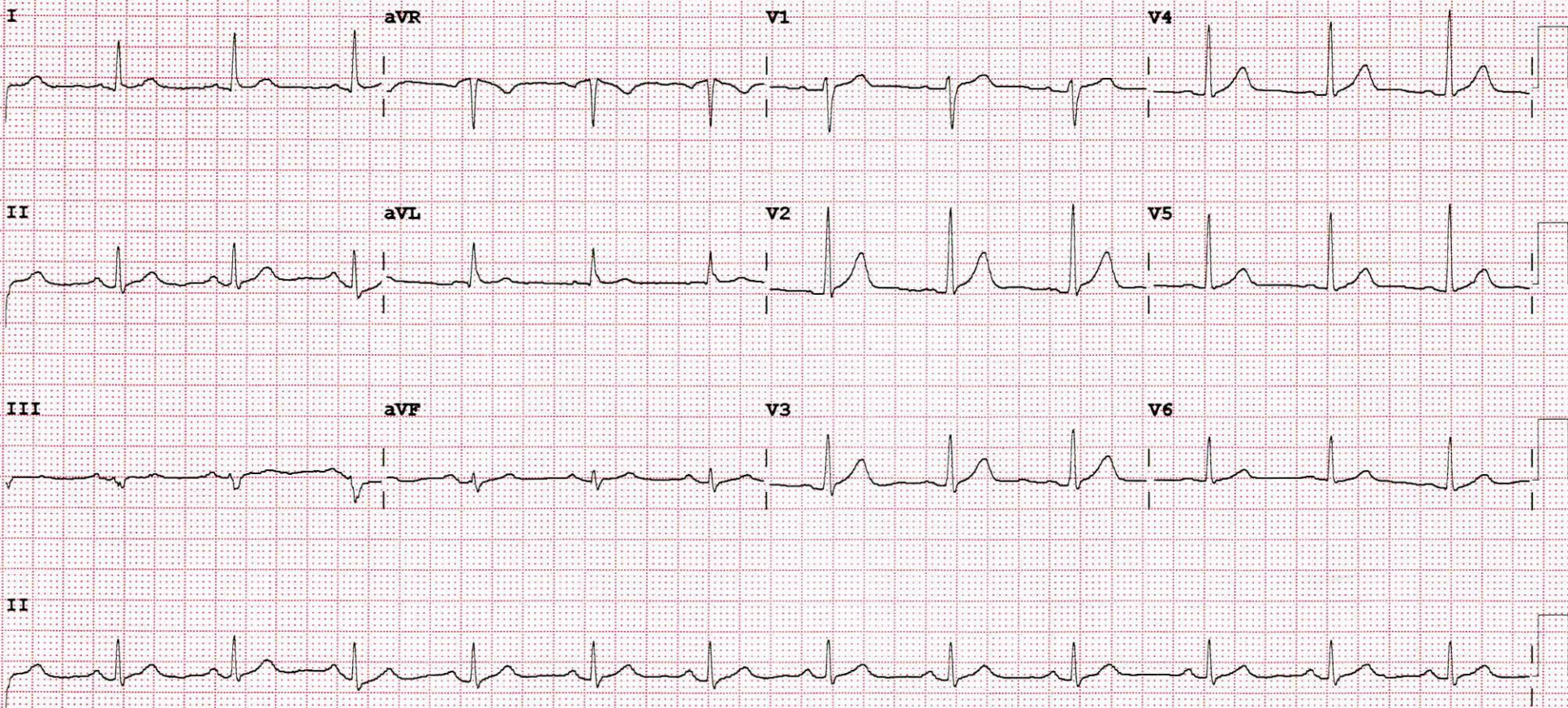
--AXIS--

P 63
QRS 6
T 41

- OTHERWISE NORMAL ECG -

12 Lead; Standard Placement

Unconfirmed Diagnosis



Device: Speed: 25 mm/sec Limb: 10 mm/mV Chest: 10.0 mm/mV F 60~ 0.50- 40 Hz W 100B CL P?



17/1/20


Ranbhagya Gulm

Routine check-up
no complaints
vitals stable
no co-morbidities.



MEDICOVER
HOSPITALS

NAVI MUMBAI


Dr. AHMED KHAN
MBBS, MD (Internal Medicine)
Reg. No. MMC 2015/01/0236





DEPARTMENT OF OPHTHALMOLOGY

MEDICOVER HOSPITALS

DATE: 17/01/24
 PATIENT NAME: Mrs Saebhagya Bhami AGE / SEX: 24 / M
 UMR NO: NMU0053539

	RE	LE
VA (DISTANCE)	6/6 (CB)	6/6
VA (NEAR)	Ng	Ng
COLOUR VISION	Normal	Normal

		SPHERE	CYLINDER	AXIS	VA
MRx	O D	+	-0.50	180°	6/6, Ng
	O S	Plano	_____		6/6, Ng

HISTORY :

- NO H/O spectacle use.
- NO H/O DM or HTN thyroid
- NO H/O Ocular trauma Allergies & surgeries.

OCULAR FINDINGS :

H/O migraine (3-4 times a week, currently not taking).

Ant seg (BE) - WNL BEI - Dry eyes.

(undilated) Disc < 0.2
 0.3, Tilted disc, temporal crescent (+)

ADVICE:

Refresh Tears 4x daily 1777 X (month).

AS
 CDR. ANUSHREE VANIKAR

