


**भारत सरकार**  
Government of India

**भारतीय विशिष्ट पहचान प्राधिकरण**  
Unique Identification Authority of India

नामांकन क्रम/ Enrolment No.: 0653/02707/06461

To:  
रधे श्याम  
Radhey Shyam  
S/O Narhau,  
H-1043 BAGIYA ROAD,  
AVAS VIKAS NO.-1 KALYANPUR,  
VTC: kalyanpur,  
PO: Baini,  
District: Kampur Nagar,  
State: Uttar Pradesh,  
PIN Code: 208017,  
Mobile: 8528884641




Signature valid

**आपका आधार क्रमांक / Your Aadhaar No. :**  
**6573 5167 5573**  
VID : 9182 9382 0214 2221

**मेरा आधार, मेरी पहचान**

---

**भारत सरकार**  
Government of India



नाम श्याम  
Radhey Shyam  
जन्म तिथि/DOB: 01/10/1964  
पुरुष/ MALE

आधार पहचान का प्रमाण है, नागरिकता या जन्मतिथि का नहीं। इसका उपयोग वास्तव में (ऑनलाइन प्रमाणीकरण, या क्यूआर कोड/ऑफलाइन प्रमाणीकरण की सहायता के साथ किया जाना चाहिए।)  
Aadhaar is proof of identity, not of citizenship or date of birth. It should be used with verification (online authentication, or scanning of QR code / offline XML).

**6573 5167 5573**  
**मेरा आधार, मेरी पहचान**

**सूचना / INFORMATION**


- आधार पहचान का प्रमाण है, नागरिकता या जन्मतिथि का नहीं। जन्मतिथि आधार अंतर धारक द्वारा प्रस्तुत सूचना और विनिश्चय में विशिष्ट जन्मतिथि के प्रमाण के दस्तावेज पर आधारित है।
- इस अध्याय पत्र को पुनर्हार्डकोपीय प्रमाण प्रमाणीकरण एजेंसी के ऑनलाइन प्रमाणीकरण के द्वारा सत्यापित किया जाना चाहिए या ऐप स्टोर में उपलब्ध एमआधार या आधार क्यूआर कोड रीडर ऐप से क्यूआर कोड स्कैन करके या [www.uidai.gov.in](http://www.uidai.gov.in) पर उपलब्ध सुरक्षित क्यूआर कोड रीडर का उपयोग करके सत्यापित किया जाना चाहिए।
- आधार विशिष्ट और सुरक्षित है।
- पहचान और पते के सशोधन में दस्तावेजों को आधार के लिए नामांकन की तारीख से प्रत्येक 10 वर्ष में कम से कम एक बार आधार में अपडेट करना चाहिए।
- आधार विभिन्न सरकारी और गैर-सरकारी फायदों/सेवाओं का लाभ लेने में सहायता करता है।
- आधार में अपना मोबाइल नंबर और ईमेल आईडी अपडेट रखें।
- आधार सेवाओं का लाभ लेने के लिए एमआधार ऐप डाउनलोड करें।
- आधार/बायोमेट्रिक्स का उपयोग न करने के समय सुरक्षा सुनिश्चित करने के लिए आधार/बायोमेट्रिक्स लॉक/अनलॉक सुविधा का उपयोग करें।
- आधार की मांग करने वाले सभ्यता लेने के लिए बाध्य हैं।
- Aadhaar is proof of identity, not of citizenship or date of birth (DOB). DC is based on information supported by proof of DOB document specified regulations, submitted by Aadhaar number holder.
- This Aadhaar letter should be verified through either online authentication by UIDAI-appointed authentication agency or QR code scanning using mAadhaar or Aadhaar QR Scanner app available in app stores or using secure QR code reader app available on [www.uidai.gov.in](http://www.uidai.gov.in).
- Aadhaar is unique and secure.
- Documents to support identity and address should be updated in Aadhaar after every 10 years from date of enrolment for Aadhaar.
- Aadhaar helps you avail of various Government and Non-Government benefits/services.
- Keep your mobile number and email id updated in Aadhaar.
- Download mAadhaar app to avail of Aadhaar services.
- Use the feature of Lock/Unlock Aadhaar/biometrics to ensure security when not using Aadhaar/biometrics.
- Entities seeking Aadhaar are obligated to seek consent.

---

**भारतीय विशिष्ट पहचान प्राधिकरण**  
Unique Identification Authority of India

पता:  
S/O नरहू, एच-१०४३ बागिया रोड, आवास विकास नं.-१  
कल्यानपुर, कल्यानपुर, बैरी, कानपुर नगर,  
उत्तर प्रदेश - २०८०१७

Address:  
S/O Narhau, H-1043 BAGIYA ROAD, AVAS  
VIKAS NO.-1, KALYANPUR, kalyanpur, PO:  
Baini, DIST: Kampur Nagar,  
Uttar Pradesh - 208017



**6573 5167 5573**  
VID : 9182 9382 0214 2221

1047 | [help@uidai.gov.in](mailto:help@uidai.gov.in) | [www.uidai.gov.in](http://www.uidai.gov.in)

ORIGINAL SEEN AND VERIFIED ON 14.09.2024

*RShyam*  
POLICY HOLDER SIGNATURE  
(Radhey Shyam)

*RShyam*  
EC No 55343  
(Radhey Shyam)  
C/o Bank of Baroda  
Bindki





# Affiliated with CGHS / CAPF TOURUS HOSPITAL

(A Unit of Taurus Medicare Pvt. Ltd.)

208, Safipur 1st Ramadevi, G. T. Road, Kanpur-208 007

Ph.: 0512-2400779, 2400774, 2400737, 8601955058 • E-mail: tourushospital@gmail.com



<i>Patient Name</i>	<b>RADHEY SHYAM</b>	<i>Patient ID</i>	<b>140924-2</b>
<i>Age/D.O.B</i>	<b>51 YRS</b>	<i>Gender</i>	<b>M</b>
<i>Ref Doctor</i>	<b>SELF</b>	<i>Date</i>	<b>14 Sep 24</b>

## XRAY RADIOGRAPH CHEST - PA

### Observations

Prominent bronchovascular markings are noted in bilateral lung fields.

The cardiac silhouette is normal.

Both hila are normal.

No focal lung lesion is seen.

Soft tissues of the chest wall are normal.

No mediastinal abnormality is visible.

Cardiothoracic ratio is normal.

### Impression

Prominent bronchovascular markings are noted in bilateral lung fields.

Reported By,

Dr. Aditi Agarwal



Consultant Radiologist

TSMC - TSMC/FMR/30641





# TAURUS HOSPITAL

(A Unit of Taurus Medicare Pvt. Ltd.)

208. Safipur 1st Ramadevi G. T. Road, Kanpur-208 007



Phone  
0512 -2400779  
0512 -2400774  
0512 -2400737  
8601955058

## Pathology Report

Lab. No. : 1026	Date : 14/Sep/2024
Patient Name : Mr. RADHEY SHYAM	Guardian Name : C/O SANJEEV
Age/Sex : 59 Years/Male	Address : KANPUR,
Reffered By : SELF	
0	

Test Name	Observed Values	Unit	Normal Values
-----------	-----------------	------	---------------

### Blood Chemistry

<b>KFT</b>			
CRET	0.99	mg/dl	0.70 - 1.40 mg/dl
UREA	20.38	mg/dl	15.00 - 45.00 mg/dl
BUN	9.17	mg/dl	5.00 - 25.00 mg/dl
UAC	5.80	mg/dl	2.50 - 7.50 mg/dl

### Haematology

ESR-Wintrobe (Erythrocyte Sedimentation Rate)	06	mm/hr.	
<b>CBC (Complete Blood Counts)</b>			
HB	14.80	mg/dl	11.50 - 17.50 mg/dl
TLC	7100	/CU MM	4000-11000
DLC		%	
NEUTROPHILL	62	%	40.0-80.0
LYMPHOCYTE	29	%	20.0-40.0
MONOCYTE	04	%	2.0-10.0
EOSINOPHILL	05	%	1.0-6.0
BASOPHILL		%	2.00 - 2.00 %
RBC	4.42	U/L	4.7-7.1
PCV	42.2	%	36.0-46.0
MCV	95.5	FL	83.0-101.0
MCH	33.5	%	11-20
MCHC	35.1	g/dl	31.5-34.5
PLatelet count	1.93	lakh/cum	1.50-4.0
RDW-CV	12.8	%	11.6-14.0



Dr. Vishakha Pal  
(MD. Path)



# TAURUS HOSPITAL

(A Unit of Taurus Medicare Pvt. Ltd.)

208. Safipur 1st Ramadevi G. T. Road, Kanpur-208 007



Phone  
0512 -2400779  
0512 -2400774  
0512 -2400737  
8601955058

## Pathology Report

Lab. No. : 1026	Date : 14/Sep/2024
Patient Name : Mr. RADHEY SHYAM	Guardian Name : C/O SANJEEV
Age/Sex : 59 Years/Male	Address : KANPUR,
Referred By : SELF	
0	

Test Name	Observed Values	Unit	Normal Values
<b>Biochemistry</b>			
BLOOD S/F	74.23	mg/dl	70-100
<b>Clinical</b>			
<b>URINE R/M</b>			
Colour	straw		
Appearance	clear		
Specific Gravity	1.010		1.005-1.030
Ph	5.0		4.5-8.0
Protien	Nil		Nil
Glucose	Nil		Nil
Pus Cells	1-2	/hpf	0-5
Epithelial Cells	1-2	/hpf	0-5
RBC	Nil	/hpf	Nil
Casts	Not Seen		Not Seen
Crystals	Not Seen		Not Seen
<b>Haematology</b>			
HbA1C	6.1	g/dl	< 5.6 % Normal 5.7-6.4% Pre-Diabetes >6.5 % Diabetes 6.5-7.0% Good control 7.0-8.0% Poor control >8.0% Bad control
<b>Hormones &amp; Related Test</b>			
<b>T3, T4 (Total) &amp; TSH 3rd Generation</b>			
T3	2.12		1.30-3.10nmol/L
T4	89.66		66.00-181.00nmol/L
TSH	3.24		0.45-4.50MIU/L



Dr. Vishakha Pal.  
(MD. Path)





# TAURUS HOSPITAL

(A Unit of Taurus Medicare Pvt. Ltd.)

208. Safipur 1st Ramadevi G. T. Road, Kanpur-208 007



Phone  
0512 -2400779  
0512 -2400774  
0512 -2400737  
8601955058

## Pathology Report

Lab. No. : 1026	Date : 14/Sep/2024
Patient Name : Mr. RADHEY SHYAM	Guardian Name : C/O SANJEEV
Age/Sex : 59 Years/Male	Address : KANPUR,
Reffered By : SELF	
0	

Test Name	Observed Values	Unit	Normal Values
-----------	-----------------	------	---------------

### Biochemistry

#### Lipid Profile (With Direct - HDL & L)

Cholestrol	162.00	mg/dl	0.00 - 200.00 mg/dl
triglycerides	89.00	mg/dl	0.00 - 150.00 mg/dl
HDL	51.00	mg/dl	30.00 - 65.00 mg/dl
LDL	101.00	mg/dl	0.00 - 130.00 mg/dl
VLDL	19.0	mg/dl	2.00-30.00
Cholesterol/HDI Ratio	3.17		<4.00
LDL/HDL cholesterol Ratio	1.98		<3.50
HDL/LDL Cholestrol Ratio	0.50		<3.50

### Blood Chemistry

#### L.F.T.

BILI TOTAL	0.52	mg/dl	0-2.0 mg/dl
BILI DIRECT	0.11	mg/dl	0-0.20 mg/dl
BILI (IND)	0.41	mg/dl	0.20-0.60mg/dl
SGPT(ALT)	31.82	IU/L	up-45 U/L
SGOT	30.06	IU/L	up-35 IU/L
ALP(ALKALINE PHOSPHATASE)	79.33	IU/L	54-119 IU/L
TOTAL PROTEIN	6.36	g/dl	6.4-8.3 g/dl
ALBUMIN(ALB)	3.60	g/dl	3.5-4.6 g/dl



Dr. Vishakha Pal  
(MD. Path)



# Affiliated with CGHS / CAPF TOURUS HOSPITAL

(A Unit of Taurus Medicare Pvt. Ltd.)

208, Safipur 1st Ramadevi, G. T. Road, Kanpur-208 007

Ph.: 0512-2400779, 2400774, 2400737, 8601955058 • E-mail: tourushospital@gmail.com



14/9/24

RADHEY SHYAM

59/m

2 DECHO

Normal size LA/LV, RA/RV

NO RWMA

Trace TR IMR ⊕

mild concentric LVH ⊕

NO PE / Apical clot

INC → 12 mm, collapsing  
→ 50% Resp

LVCF - 60%







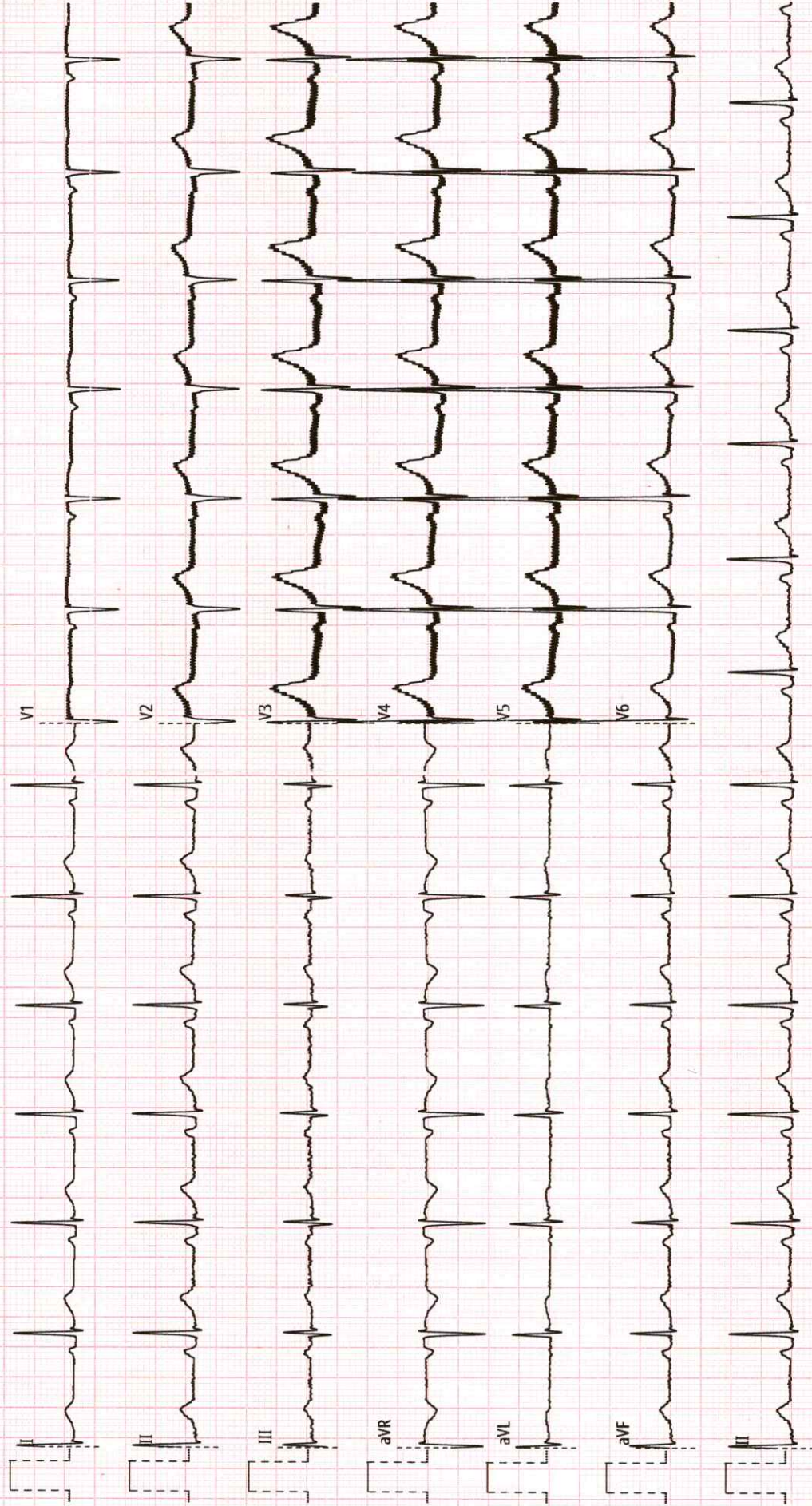
# ECG report

<<Interpretations >>  
Sinus rhythm  
— Interpretation made without knowing patient's gender/age —  
Q in V1/V2 may be due to lead placement error though septal infarct cannot be excluded  
Borderline ECG

HR : 79 bpm  
PR : 136 ms  
QRS : 68 ms  
QT/QTc : 348/381 ms  
P/QRS/T : 58/30/52°  
RV5/SV1 : 2.459/0.796 mv  
RV5+SV1 : 3.255 mv

ID : 20240914085347  
Name : Mr Radhey Shyam  
Gender : M  
Age : 59 Years  
Dept :  
Bed No :

Confirm and sign:







# RAJNI HOSPITAL

A Unit of Shrimati Rajani Dwivedi Charitable Society  
1518/5, Daheli Sujapur, By Pass Road, Kanpur-208013  
(Near Koyla Nagar Police Chowki)  
GST NO:- 09AARTS9188A1ZR



Helpline No.:  
+91 -8004991414  
+91 -8004991515  
+91 -8004991616  
+91 -8933048215

Web : www.rajnihospitalin  
Email : rajnihospitalknp@gmail.com

Patient Name : Mr. RADHEY SHYAM  
Referred By : Dr. SELF  
Investigation : USG Whole Abdomen

Age : 59years/M  
Date : 14/09/2024

## Liver:

- Liver is enlarged in size mea(153mm). with hyper echoic Echogenicity fatty change. Multiple small calcification seen in the right lobe in liver. It one mea(5.1mm). No focal or diffuse lesion seen. Hepatic veins appear normal. No dilation of intrahepatic biliary ducts is seen.

## Gall bladder:

- Gall bladder is normal in size and show echo free lumen. Wall thickness is with in normal limit. No calculus & mass lesion seen in GB.

## Portal vein:

- Normal in size (mm) and shows normal appearance.

## C.B.D.:

- Normal in size (mm) and shows normal caliber.

## Pancreas:

- Pancreas is normal in size. No calcification or mass lesion seen.

## Spleen:

- Spleen is normal in size. Splenic vein appears normal. No mass seen.

## Right kidney:

- Normal in size (92x41mm) seen in respective renal areas.  
- Cortico - medullary differentiation appears to be normal.  
- No calculus or mass lesion seen. No hydronephrosis is seen.







# RAJNI HOSPITAL

A Unit of Shrimati Rajani Dwivedi Charitable Society  
1518/5, Daheli Sujapur, By Pass Road, Kanpur-208013  
(Near Koyla Nagar Police Chowki)  
GST NO:- 09AARTS9188A1ZR



Helpline No.:

+91 -8004991414

+91 -8004991515

+91 -8004991616

+91 -8933048215

Web : [www.rajnihospitalin](http://www.rajnihospitalin)

Email : [rajnihospitalknp@gmail.com](mailto:rajnihospitalknp@gmail.com)

## Left kidney:

- Normal in size (87x50mm) seen in respective renal areas.
- Cortico - medullary differentiation appears to be normal.
- No calculus or mass lesion seen. No hydronephrosis is seen.

## Ureter:

- Both ureters are normal.

## Urinary bladder:

- Normal in shape and size. Wall thickness is within normal limit.
- No calculus & mass lesion seen.

## Prostate:

- Prostate is normal in shape and size. No calculus or mass lesion noted.

## Peritoneum/Retroperitoneum:

- Dilated bowel loops with gas shadow seen in whole abdomen.
- No ascitis or fluid is seen. No lymphadenopathis seen.

## Impression:

- HEPATOMEGALY WITH FATTY & CALCIFICATION
- DILATED BOWEL LOOPS WITH GAS

**ADV: CT- Scan** Please correlate clinically.

