

Patient Name : Mrs.MAMI PRADHAN	Collected : 09/Nov/2024 11:54AM
Age/Gender : 48 Y 4 M 13 D/F	Received : 09/Nov/2024 01:49PM
UHID/MR No : CKOR.0000181797	Reported : 09/Nov/2024 03:21PM
Visit ID : CKOROPV431200	Status : Final Report
Ref Doctor : Self	Sponsor Name : ARCOFEMI HEALTHCARE LIMITED
Emp/Auth/TPA ID : 22S36954	

DEPARTMENT OF CLINICAL PATHOLOGY

ARCOFEMI - MEDIWHEEL - FULL BODY ANNUAL PLUS CHECK ADVANCED - FEMALE - 2D ECHO - PAN INDIA - FY232

Test Name	Result	Unit	Bio. Ref. Interval	Method
URINE GLUCOSE(POST PRANDIAL)	NEGATIVE		NEGATIVE	GOD-POD

Dr. Vidya Aniket Gore
M.B.B.S,M.D(Pathology)
Consultant Pathologist

Dr Priya Murthy
M.B.B.S,M.D(Pathology)
Consultant Pathologist



Patient Name	: Mrs. MAMI PRADHAN	Age	: 48Yrs 4Mths 14Days
UHID	: CKOR.0000181797	OP Visit No.	: CKOROPV431200
Printed On	: 09-11-2024 05:29 AM	Advised/Pres Doctor	: --
Department	: Radiology	Qualification	: --
Referred By	: Self	Registration No.	: --
Employer Id	: 22S36954		

DEPARTMENT OF RADIOLOGY

ULTRASOUND ABDOMEN AND PELVIS

Liver is normal in size and shows normal echo pattern. No biliary dilatation. No focal lesion

Portal vein is normal in size, course and caliber. CBD is not dilated.

Gall bladder is normal without evidence of calculi, wall thickening or pericholecystic fluid

Pancreas to the extent visualized, appears normal in size, contour and echogenicity

Spleen is normal in size, shape, contour and echopattern. No evidence of mass or focal lesion.

Right kidney is normal in size, position, shape and echopattern. Corticomedullary differentiation is maintained. No evidence of calculi or hydronephrosis.

Left kidney is normal in size, position, shape and echopattern. corticomedullary differentiation is maintained. No evidence of calculi or hydronephrosis.

Urinary Bladder is well distended. wall thickness is normal. No internal echoes.

Uterus: is normal in size. There is a 9 mm anterior intramural seedling fibroid. Endometrial echoes are normal

Endometrium: measures 7.0mm.

Left ovary is normal in size and echopattern. Right ovary is not visualized.

Both adnexa: Normal, no mass seen.

There is no ascites.

IMPRESSION: SEEDLING FIBROID UTERUS

---End Of The Report---

P.J. Vinod

Dr.VINOD P JOSEPH
MBBS, DNB, DMRD
25487
Radiology

Patient Name	: Mrs. MAMI PRADHAN	Age	: 48Yrs 4Mths 14Days
UHID	: CKOR.0000181797	OP Visit No.	: CKOROPV431200
Printed On	: 09-11-2024 05:42 AM	Advised/Pres Doctor	: --
Department	: Radiology	Qualification	: --
Referred By	: Self	Registration No.	: --
Employee Id	: 22S36954		

DEPARTMENT OF RADIOLOGY

SONOMAMMOGRAPHY

Both breast shows normal parenchymal echotexture. There is no evidence of distortion of parenchymal architecture.

There is no evidence of focal solid, cystic lesions or calcifications seen.

The nipple and areolar region show no abnormality.

The bilateral axillary region shows no abnormality and there is no evidence of enlarge lymph nodes.

IMPRESSION: NORMAL SONOMAMMOGRAPHY STUDY – BIRADS 1

---End Of The Report---

P.J. Vinod

Dr.VINOD P JOSEPH
MBBS, DNB, DMRD
25487
Radiology

Patient Name	: Mrs. MAMI PRADHAN	Age	: 48Yrs 4Mths 14Days
UHID	: CKOR.0000181797	OP Visit No.	: CKOROPV431200
Printed On	: 09-11-2024 07:02 AM	Advised/Pres Doctor	: --
Department	: Radiology	Qualification	: --
Referred By	: Self	Registration No.	: --
Employer Id	: 22S36954		

DEPARTMENT OF RADIOLOGY

X RAY CHEST PA

Both lungs fields appear normal.

Both hilae are normal.

Both costophrenic and cardiophrenic angles are normal.

The cardiac and mediastinal shadows appear normal.

Bones and soft tissues appear normal.

IMPRESSION : NORMAL STUDY.

---End Of The Report---



Dr.VINOD P JOSEPH
MBBS, DNB, DMRD
25487
Radiology

Patient Name	: Mrs. MAMI PRADHAN	Age	: 48Yrs 4Mths 17Days
UHID	: CKOR.0000181797	OP Visit No.	: CKOROPV431200
Printed On	: 12-11-2024 07:21 AM	Advised/Pres Doctor	: --
Department	: Cardiology	Qualification	: --
Referred By	: Self	Registration No.	: --
Employer Id	: 22S36954		

DEPARTMENT OF CARDIOLOGY

ECHO

---End Of The Report---



Dr.MOHAN MURALI
MBBS, DNB General Medicine, DrNB Cardiology
ANP20130001911KTK
Cardiology

Patient Name	: Mrs. MAMI PRADHAN	Age	: 48Yrs 4Mths 14Days
UHID	: CKOR.0000181797	OP Visit No.	: CKOROPV431200
Printed On	: 09-11-2024 06:31 AM	Advised/Pres Doctor	: --
Department	: Cardiology	Qualification	: --
Referred By	: Self	Registration No.	: --
Employer Id	: 22S36954		

DEPARTMENT OF CARDIOLOGY

Observation :-

1. Normal Sinus Rhythm.
2. Heart rate is 83 beats per minutes.
3. No pathological Q wave or ST-T changes seen.
4. Normal P,QRS,T waves and axis.
5. No evidence of chamber, hypertrophy or enlargement seen.

Impression:

NORMAL RESTING ECG.

NOTE:KINDLY TAKE A PHOTOCOPY OF THE GRAPH FOR FUTURE REFERENCE IF NEEDED

---End Of The Report---



Dr.MOHAN MURALI
MBBS, DNB General Medicine, DrNB Cardiology
ANP20130001911KTK
Cardiology



Apollo Clinic

Consent Form

Patient Name: Mami Pradhan Age: 48

UHID Number: Company Name:

I Mr/Mrs/Miss: Employee of

(Company) want to inform you that I am ~~not~~ getting the consultation on
Test which is a part of health check package. Monday

Reason If any:

And I claim the above statement in my full consciousness.

Patient Signature: Mami Pradhan Date: 9-11-2024

OPHTHAL REPORT

NAME: Ms. Nami Pradhan
AGE: 48 GENDER: MALE/FEMALE

RIGHT EYE

	SPH	CYL	AXIS	VA
DV	±	100	90	6/6
NV Add	+1.75			

LEFT EYE

	SPH	CYL	AXIS	VA
DV	±	100	90	6/6
NV	+1.75			

REMARK:

DATE: 9.11.2024

Shiv
OPTOMETRIST

BRING THIS PRESCRIPTION IN YOUR NEXT VISIT



DR VIJAYA LAKSHMI M
M.B.B.S, D.L.O, D.N.B(ENT)
Phone No.9972044580,080-25633823/24/23

HEALTH CHECK- ENT

09/11/23

NAME: *MAMI PRADHAN*

AGE: *40 yr*

EAR:

RE:

LE:

EXTERNAL EAR

MIDDLE EAR

INNER EAR (FN)

Normal

HEARING ASSESSMENT:

RE:

LE:

RHINNE

WEBER

ABC

NOSE

Normal

THROAT

AIRWAY

SEPTUM

TURBINATES

OTHERS

NECK

Normal

ORAL CAVITY

OROPHARYNX

PHARYNX

LARYNX

Normal

NECK NODES

OTHER

Normal

AUDIOMETRY

IMPRESSION

Normal

[Signature]

SIGNATURE:

NAME: Mrs. MAMI PRADHAN

AGE: 48Y

SEX: FEMALE

DATE: 09/11/2024

ECHOCARDIOGRAPHY REPORT

MEASUREMENT

AO - 25 (20 - 35) mm	LIVD d - 38 (36-52) mm	IVS - 10 (06 - 11) mm
LA - 26 (19- 40) mm	LVID s 26 (23- 39) mm	PWD - 11 (06- 11) mm
EF - 60 (>50%)	RVID-20	

VALVES

Mitral Valve	: NORMAL
Aortic Valve	: NORMAL
Tricuspid Valve	: Normal,
Pulmonary Valve	: Normal,

CHAMBERS

Left Atrium	: Normal
Right Atrium	: Normal
Left Ventricle	: Normal
Right Ventricle	: Normal

SEPTAE

IVS	: Intact
IAS	: Intact

GREAT ARTERIES

Aorta : Normal
Pulmonary Artery : Normal

DOPPLER DATA

Mitral : E < A , 0.6 / 0.5
Aortic : Normal , 1.0 m/s,
Tricuspid : Normal , 0.4 / 0.6
Pulmonary : Normal, 1.10, TRIVIAL PR

WALL MOTION ABNORMALITIES : No RWMA

Pericardium : Normal

FINAL DIAGNOSIS

**NORMAL CHAMBERS AND DIMENSIONS
NO RWMA , NORMAL LV EF -60%
LV DIASTOLIC DYFUNCTION
NO OBVIOUS CLOTS/ EFFUSION/ VEGETATION**


**DR. MOHAN MURALI
DNB(MED), DNB(CARDIOLOGY)
CONSULTANT CARDIOLOGIST**

Date : 9/11/24
 MR No :
 Name : M. M. M.
 Age/Gender : 48YM
 Mobile no :

nk

Department : OBSTETRICS & GYNAECOLOGY
 Consultant : DR JYOTHI RAJESH
 REG NO; KMC-42823
 Qualification : DGO, (DNB)
 Consulting Timings: 9.30am TO 12.00PM
 phone no: 9972044580, 7338064558

Height :	Weight :	BMI :	Waist Circum :
Temp :	Pulse :	Resp :	B.P :

General Examination / Allergies
History

Clinical Diagnosis & Management Plan

clt Irregular periods 4 months
 LMP 13/10
 OBNI P.L.U K TO D W - 20YM
 Past Hx over
 Family Hx - Father - DM
 O/E P/A - soft
 P/S - Co
 Vaginal @ UBC Exams

z

Follow up date:

Doctor Signature

Patient Name : Mrs. Mami Pradhan

Patient ID: 181797

Age : 48Year(s)

Sex: Female

Referring Doctor : H/C

Date:09.11.2024

ULTRASOUND ABDOMEN AND PELVIS

Liver is normal in size and shows normal echo pattern. No biliary dilatation .No focal lesion

Portal vein is normal in size, course and caliber. CBD is not dilated.

Gall bladder is normal without evidence of calculi, wall thickening or pericholecystic fluid

Pancreas to the extent visualized, appears normal in size, contour and echogenicity

Spleen is normal in size, shape, contour and echopattern. No evidence of mass or focal lesion.

Right kidney is normal in size, position, shape and echopattern. Corticomedullary differentiation is maintained. No evidence of calculi or hydronephrosis.

Left kidney is normal in size, position, shape and echopattern.corticomedullary differentiation is maintained. No evidence of calculi or hydronephrosis.

Urinary Bladder is well distended. wall thickness is normal. No internal echoes.

Uterus: is normal in size. There is a 9 mm anterior intramural seedling fibroid. Endometrial echoes are normal

Endometrium: measures 7.0mm.

Left ovary is normal in size and echopattern. Right ovary is not visualized.

Both adnexa: Normal, no mass seen.

There is no ascites.

IMPRESSION: SEEDLING FIBROID UTERUS

**DR VINOD JOSEPH DNB,DMRD
RADIOLOGIST**



Patient Name : Mrs. Mami Pradhan

Patient ID: 181797

Age : 48Years

Sex: Female

Referring Doctor : H/C

Date: 09.11.2024

SONOMAMMOGRAPHY

Both breast shows normal parenchymal echotexture. There is no evidence of distortion of parenchymal architecture.

There is no evidence of focal solid, cystic lesions or calcifications seen.

The nipple and areolar region show no abnormality.

The bilateral axillary region shows no abnormality and there is no evidence of enlarge lymph nodes.

IMPRESSION: NORMAL SONOMAMMOGRAPHY STUDY – BIRADS 1

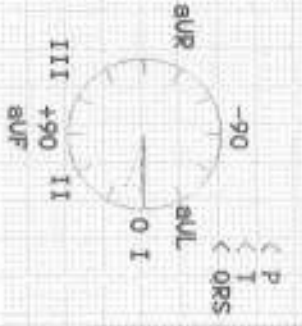

**DR VINOD JOSEPH DNB,DMRD
RADIOLOGIST**

ArnoW ©

HR 83 bpm

83 bpm

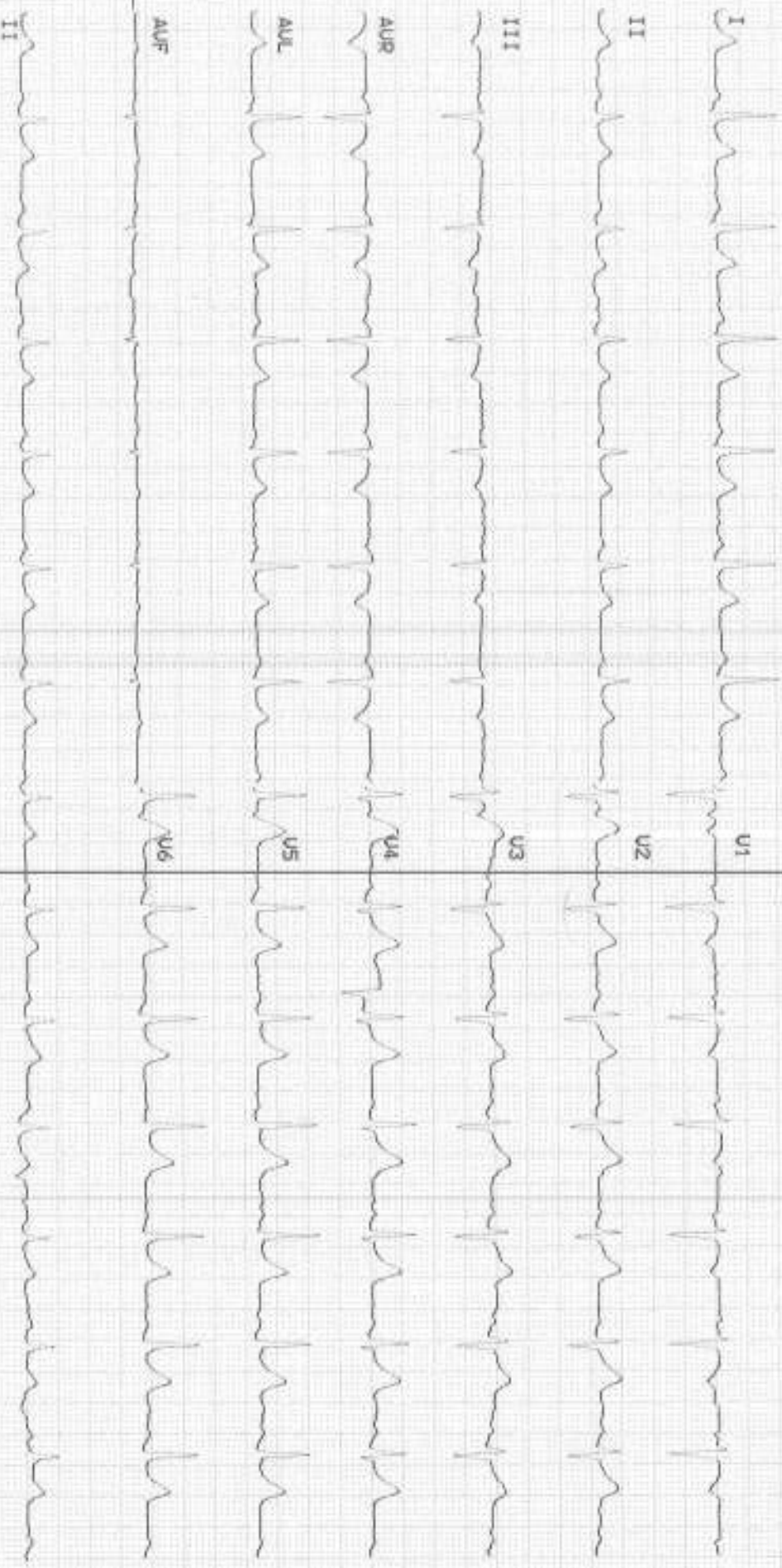
AGE: 48
 Female
 Measurement Results:
 CRS : 92 ms
 QT/QTcB : 360 / 425 ms
 PR : 138 ms
 P : 104 ms
 RR/PP : 718 / 715 ms
 P/QRS/T : 20 / 0 / 5 degrees
 QTd/QTcBd : 32 / 38 ms
 Sokolow : 1.6 mV
 NK : 11



Interpretation:

Unconfirmed report.

MSR 4



Patient Name	: Mrs. MAMI PRADHAN	Age	: 48Yrs 4M
UHID	: CKOR.0000181797	OP Visit No.	: CKOROPV431200
Printed On	: 09-11-2024 12:01 PM	Advised/Pres Doctor	: ---
Department	: Cardiology	Qualification	: ---
Referred By	: Self	Registration No.	: ---
Employer Id	: 22S36954		

DEPARTMENT OF CARDIOLOGY

Observation :-

1. Normal Sinus Rhythm.
2. Heart rate is 83 beats per minutes.
3. No pathological Q wave or ST-T changes seen.
4. Normal P,QRS,T waves and axis.
5. No evidence of chamber, hypertrophy or enlargement seen.

Impression:

NORMAL RESTING ECG.

NOTE:KINDLY TAKE A PHOTOCOPY OF THE GRAPH FOR FUTURE REFERENCE IF NEEDED

---End Of The Report---



Dr.MOHAN MURALI
MBBS, DNB General Medicine, DrNB Cardiology
ANP20130001911KTK
Cardiology



Apollo Medical Centre
Expertise. Closer to you

Patient Name	: Mrs. MAMI PRADHAN	Age	: 48Yrs 4Mths 13Days
UHID	: CKOR.0000181797	OP Visit No.	: CKOROPV431200
Printed On	: 09-11-2024 12:32 PM	Advised/Pres Doctor	: --
Department	: Radiology	Qualification	: --
Referred By	: Self	Registration No.	: --
Employer Id	: 22S36954		

DEPARTMENT OF RADIOLOGY

X RAY CHEST PA

Both lungs fields appear normal.

Both hilae are normal.

Both costophrenic and cardiophrenic angles are normal.

The cardiac and mediastinal shadows appear normal.

Bones and soft tissues appear normal.

IMPRESSION : NORMAL STUDY.

---End Of The Report---

P.J. Vinod

Dr.VINOD P JOSEPH
MBBS, DNB, DMRD
25487
Radiology

Apollo Health and Lifestyle Limited

(CIN - U85110TG2000PLC046089) Regd. Office: #7-1-617/A, 615 & 616, Imperial Towers, 7th Floor; Ameerpet, Hyderabad, Telangana - 500 038 | Email ID: enquiry@apollohl.com

APOLLO CLINICS NETWORK KARNATAKA

Bangalore (Basavanagudi | Bellandur | Electronics City | HSR Layout | Indira Nagar | JP Nagar | Kundalahalli | Koramangala | Sarjapur Road) Mysore (Kalidasa Road)

Online appointments: www.apollohospitals.com

TO BOOK AN APPOINTMENT

1860 500 7788

Fwd: Health Check up Booking Confirmed Request(22S36954),Package Code-PKG10000376, Beneficiary Code-296646

From CHANDRA SEKHAR PRADHAN <sairam.csp1971@gmail.com>
Date Sat 09-11-2024 08:15
To Koramangala Apolloclinic <koramangala@apolloclinic.com>

----- Forwarded message -----

From: **Mediwheel** <wellness@mediwheel.in>
Date: Fri, 8 Nov, 2024, 12:28 pm
Subject: Health Check up Booking Confirmed Request(22S36954),Package Code-PKG10000376, Beneficiary Code-296646
To: <sairam.csp1971@gmail.com>
Cc: <customercare@mediwheel.in>

011-41195959

Dear **Chandra Sekhar Pradhan**,

We are pleased to confirm your health checkup booking request with the following details

Hospital Package Name : Mediwheel Full Body Annual Plus Check Advanced - Female
Name of Diagnostic/Hospital : Apollo Medical Centre - Koramangala
Address of Diagnostic/Hospital : Apollo Medical centre, Plot 51 5th Block, Opp. Jyothi Nivas College, Koramangala - 560095
City : Bangalore
State : Karnataka
Pincode : 560095
Appointment Date : 09-11-2024
Confirmation Status : Booking Confirmed
Preferred Time : 08:00 AM - 08:30 AM
Booking Status : Booking Confirmed

Member Information		
Booked Member Name	Age	Gender
Mami pradhan	48 year	Female

Note - Please note to not pay any amount at the center,
Instructions to undergo Health Check:




भारत सरकार
Government of India

भारतीय विशिष्ट पहचान प्राधिकरण
Unique Identification Authority of India

नामांकन क्रम/ Enrolment No.: 0000/00883/12606

To
ಮಾಮಿ ಪ್ರಧಾನ
Mami Pradhan
W/O Chandra Sekhar Pradhan
B-604, Kumaradhara block
National Games Village
Indoor Stadium
Koramangala
Viveknagar
Bengaluru Karnataka - 560047
9113062951



आपका आधार क्रमांक / Your Aadhaar No :

9494 8149 2160

VID : 9161 4547 3208 4865

मेरा आधार, मेरी पहचान



भारत सरकार
Government of India



ಮಾಮಿ ಪ್ರಧಾನ
Mami Pradhan
जन्म तिथि/DOB: 27/06/1976
महिला/ FEMALE

9494 8149 2160

VID : 9161 4547 3208 4865

मेरा आधार, मेरी पहचान



Government of India



AADHAAR

सूचना

- आधार पहचान का प्रमाण है, नागरिकता का नहीं।
- सुरक्षित QR कोड / ऑफलाइन XML / ऑनलाइन ऑथेंटिकेशन से पहचान प्रमाणित करें।
- यह एक इलेक्ट्रॉनिक प्रक्रिया द्वारा बना हुआ पत्र है।

INFORMATION

- Aadhaar is a proof of identity, not of citizenship.
- Verify identity using Secure QR Code/ Offline XML/ Online Authentication.
- This is electronically generated letter.

- आधार देश भर में मान्य है।
- आधार कई सरकारी और गैर सरकारी सेवाओं को पाना आसान बनाता है।
- आधार में मोबाइल नंबर और ईमेल ID अपडेट रखें।
- आधार को अपने स्मार्ट फोन पर रखें, mAadhaar App के साथ।

- Aadhaar is valid throughout the country.
- Aadhaar helps you avail various Government and non-Government services easily.
- Keep your mobile number & email ID updated in Aadhaar.
- Carry Aadhaar in your smart phone – use mAadhaar App.




भारतीय विशिष्ट पहचान प्राधिकरण
Unique Identification Authority of India



पता:
श्री. चंद्रा सेखर प्रधन, बी-604, कुमारधारा ब्लॉक,
राष्ट्रीय खेल विलेज, इंदोर स्टेडियम, कोरमंगला,
बेंगलूर, भारत,
कर्नाटक - 560047

Address:
W/O Chandra Sekhar Pradhan, B-604,
Kumaradhara block, National Games Village,
Indoor Stadium, Koramangala, Viveknagar,
Bengaluru,
Karnataka - 560047



9494 8149 2160

VID : 9161 4547 3208 4865



1947



help@uidai.gov.in



www.uidai.gov.in