



PANACEA HOSPITAL

B 36/44 F.K KABIR NAGAR, DURGAKUND
TOLLFREE NO-18001233070. Whatsapp No - 8795832852
www.piire.org
panaceaquery@gmail.com|panaceahospitalit@gmail.com



OP Slip

Print Date : 26-Oct-2024 11:04AM



UHID No	:- UD-24250004006	OP No	:- OP-24250012062	OP Date	:- 26 Oct 2024 11:04AM
Patient Name	:- Mr RAM MILAN	Age/Sex	:- 27 Y/Male	Mobile No	:- 9598937097
Father	:- RAMLADAITE	Department	:- GENERAL MEDICINE		
Pay Type	:- Cr	Consultant	:- Dr R C TRIVEDI (MBBS,MD)		
Token No	:- NOR. - 8	Paid/Bal	:- 0.00 /30.00		
Patient Type	:- Normal				
Address	:- JALALPUR MATOULI KANNAUJ 209733,UTTAR PRADESH				

BP :- 104/67
 height :- 160
 Weight (kg) :- 72.7
 BMI :-

SPO2 - 99%
 PR - 84 b/m
 NC - 37
 WC - 94
 CH - 96
 PEF - 450

Rx

Es. Doxolin. (400) OD

Es. Gurencectm R

HA 1 month

DR. R C TRIVEDI
 MBBS, MD, (General Medicine)
 Reg. No. -26622

Printed By : Ms. Anjali Prajapati
 Created By : Ms. Anjali Prajapati



PANACEA HOSPITAL

B 36/44 F.K KABIR NAGAR, DURGAKUND
TOLLFREE NO-18001233070. Whatsapp No - 8795832852
www.piire.org
panaceaquery@gmail.com|panaceahospitalit@gmail.com



OP Slip

Print Date : 26-Oct-2024 11:05AM



UHID No	:- UD-24250004006	OP No	:- OP-24250012063	OP Date	:- 26 Oct 2024 11:04AM
Patient Name	:- Mr RAM MILAN	Age/Sex	:- 27 Y/Male	Mobile No	:- 9598937097
Father	:- RAMLADAITE	Department	:- DENTAL		
Pay Type	:- Cr	Consultant	:- Dr SHRUTI MISHRA (AA)		
Token No	:- NOR. - 8	Paid	:- 0.00		
Patient Type	:- Normal				
Address	:- JALALPUR MATOULI KANNAUJ 209733,UTTAR PRADESH				

BP :- 104/67
 height :- 160
 Weight (kg) :- 72.7
 BMI :-
 SpO2 - 99%
 PR - 84 b/m
 TC - 37
 WC - 94
 CH - 96
 PEF - 450

Rx C(=> patient came for routine dental check up.
 o/e => stain/calculus => +/+
 Plv => chronic gingivitis

Shruti
Dr. SHRUTI MISHRA
 BDS, (DENTIST)
 MCI Reg. No. (A-09784)

Printed By : Ms. Anjali Prajapati
 Created By : Ms. Anjali Prajapati

Facilities:

All clinical Biomedical & Hematology Investigations including Bone Marrow Examination VPT, Podiascan & Complete Foot Care (First Time in Purvanchal) All Hormonal Investigation by Chemiluminescent Method Visceral Fat by (AB-140) Ambulatory BP Monitoring CGMS & Insulin Pump Available PFT, 2D-ECHO (Color Doppler), Holter, TMT, Cardiac-3 available VIA, VILI, Colposcopy available Special Endocrinological Investigation Protocols.

ISO 9001:2008 Certified
Mobile: 9389994334, 9554572190, 9453837595



Panacea Pathology

Clinical Reference Lab

Persistence, Preparedness and Precision
EQAS (CMC Vellore Attached) & IQAS System
पूर्वांचल की सर्वोत्तम गुणवत्ता वाली पैथोलॉजी

UHID No :- UD-24250004006 **Booking No/Date** :- 163 / 26-Oct-2024 08:02 PM
Patient Name :- Mr RAM MILAN **Age/Sex** :- 27 Y/M
Father :- RAMLADAITE **OP No** :- OP-24250012063
Address :- JALALPUR MATOULI KANNAUJ 209733, UTTAR PRADESH **Mobile No** :- 9598937097
Consultant :- Dr R C TRIVEDI (MBBS)

Investigations	Observations	Biological Ref. Interval	Unit
HAEMATOLOGY			
CBC			
HAEMOGLOBIN <small>DefaultMethod / test Machine</small>	15.2	13.00 - 16.00	gm/dl
TLC <small>Methology / Carm</small>	4,800	4000.00 - 11000.00	Cells/cumm.
DLC DIFFERENTIAL LEUCOCYTE COUNT			
NEUTROPHILS	55	40.00 - 75.00	%
LYMPHOCYTES	40	20.00 - 45.00	%
EOSINOPHILS	03	1.00 - 6.00	%
MONOCYTES	02	2.00 - 10.00	%
BASOPHILS	00	<1-2	%
PLATELET COUNT	1.61	1.50 - 4.10	lacs /cumm
PCV	45.0	33.00 - 42.00	%
RBC <small>Methology / Carm</small>	4.59	4.50 - 5.50	million/cumm
MCV(MEAN CELL VOLUME)	97.9	83.00 - 101.00	fl
MCH(MEAN CELL HAEMOGLOBIN)	33.1	27.00 - 32.00	pg
MCHC	33.8	31.50 - 35.00	gm%
RDW-CV	13.8	11.00 - 16.00	%
RDW-SD	55.1	37.00 - 57.00	fl

Lab Technician

Timing : 24/7 hrs

Consulting Pathologist
Dr. Umesh Kumar
M.D. Pathology
MCI Reg. No. 41413

This Report is not valid for medico legal purpose

Note: These tests have technical limitations. Clinico-pathological interpretation is necessary. In case of any disparity test may be repeated immediately.

Address : 36/44 FK Kabir Nagar, Durgakund, Varanasi – 221005

Email: dramishra@gmail.com, drpallaviojha@gmail.com Website: panaceahospital.org

Facilities:

All clinical Biomedical & Hematology Investigations including Bone Marrow Examination VPT, Podiascan & Complete Foot Care (First Time in Purvanchal) All Hormonal Investigation by Chemiluminescent Method Visceral Fat by (AB-140) Ambulatory BP Monitoring CGMS & Insulin Pump Available PFT, 2D-ECHO (Color Doppler), Holter, TMT, Cardiac-3 available VIA, VILI, Colposcopy available Special Endocrinological Investigation Protocols.

ISO 9001:2008 Certified
Mobile: 9389994334, 9554572190, 9453837595



Panacea Pathology

Clinical Reference Lab

Persistence, Preparedness and Precision
EQAS (CMC Vellore Attached) & IQAS System
पूर्वांचल की सर्वोत्तम गुणवत्ता वाली पैथोलॉजी

UHID No :- UD-24250004006 **Booking No/Date** :- 163 / 26-Oct-2024 08:02 PM
Patient Name :- Mr RAM MILAN **Age/Sex** :- 27 Y/M
Father :- RAMLADAITE **OP No** :- OP-24250012063
Address :- JALALPUR MATOULI KANNAUJ 209733, UTTAR PRADESH **Mobile No** :- 9598937097
Consultant :- Dr R C TRIVEDI (MBBS)

Investigations	Observations	Biological Ref. Interval	Unit
HAEMATOLOGY			
HBA1C -(BY GOLD STANDARD METHOD :HPLC)	5.1	Normal: 4.0 - 5.4 Prediabetic : 5.5 -6.3 Diabetes mellitus := 6.4	%
BLOOD GROUP ABO & RH FACTOR			
BLOOD GROUP	" O"		
RH FACTOR	POSITIVE		
ESR	12.0	0.00 - 15.00	mm at 1 hr
BIOCHEMISTRY			
LFT (LIVER FUNCTION TESTS)			
TOTAL BILIRUBIN	0.54	0.00 - 1.20	mg/dl
DIRECT BILIRUBIN	0.23	0.00 - 0.30	
INDIRECT BILIRUBIN	0.31	0.20 - 0.70	mg/dl
SGOT	26.0	2.00 - 31.00	U/L
SGPT	38.0	10.00 - 45.00	U/L
ALKALINE PHOSPHATASE	83.0	25.00 - 140.00	U/L
TOTAL PROTIENS	6.9	6.60 - 8.70	g/dl
ALBUMIN	3.6	3.50 - 5.20	gm%
GLOBULIN	3.3	1.50 - 3.60	gms/dl

Umesh Kumar

Lab Technician

Consulting Pathologist
Dr. UMESH KUMAR
M.B.B.S, M.D. (Pathologist)
M.D., Pathology

Timing : 24/7 hrs

This Report is not valid for medico legal purpose

Note: These tests have technical limitations. Clinico-pathological interpretation is necessary. In case of any disparity test may be repeated immediately.

Address : 36/44 FK Kabir Nagar, Durgakund, Varanasi – 221005

Email: dramishra@gmail.com, drpallaviojha@gmail.com Website: panaceahospital.org

Facilities:

All clinical Biomedical & Hematology Investigations including Bone Marrow Examination
VPT, Podiascan & Complete Foot Care (First Time in Purvanchal)
All Hormonal Investigation by Chemiluminescent Method
Visceral Fat by (AB-140) Ambulatory BP Monitoring
CGMS & Insulin Pump Available
PFT, 2D-ECHO (Color Doppler), Holter, TMT, Cardiac-3 available
VIA, VILI, Colposcopy available
Special Endocrinological Investigation Protocols.

ISO 9001:2008 Certified
Mobile: 9389994334, 9554572190, 9453837595



Panacea Pathology

Clinical Reference Lab

Persistence, Preparedness and Precision
EQAS (CMC Vellore Attached) & IQAS System
पूर्वांचल की सर्वोत्तम गुणवत्ता वाली पैथोलॉजी

UHID No :- UD-24250004006 **Booking No/Date** :- 163 / 26-Oct-2024 08:02 PM
Patient Name :- Mr RAM MILAN **Age/Sex** :- 27 Y/M
Father :- RAMLADAITE **OP No** :- OP-24250012063
Address :- JALALPUR MATOULI KANNAUJ 209733, UTTAR PRADESH **Mobile No** :- 9598937097
Consultant :- Dr R C TRIVEDI (MBBS)

Investigations	Observations	Biological Ref. Interval	Unit
A/G RATIO	1.09	2:1	RATIO
RFT (RENAL FUNCTION TESTS)			
BLOOD UREA	24.0	10.00 - 50.00	mg/dl
SERUM CREATININE	0.81	0.60 - 1.60	mg/dl
URIC ACID	4.31	3.60 - 7.70	mg/dl
ALKALINE PHOSPHATASE	83.0	25.00 - 140.00	U/L
TOTAL PROTIENS	6.9	6.60 - 8.70	g/dl
ALBUMIN	3.6	3.50 - 5.20	gm%
SERUM GLOBULIN	3.3	2.30 - 3.50	g/dl
CALCIUM	8.89	8.80 - 10.20	
PHOSPHORUS	4.33	2.50 - 5.00	
SERUM SODIUM NA+	141.3	135.00 - 155.00	mEq/Ltr
SERUM POTASIUM K+	3.49	3.60 - 5.50	mEq/Ltr
ICALCIUM	1.24	1.10 - 1.35	mmol/L
SERUM CHLORIDE CL+	101.9	98.00 - 110.00	mEq/Ltr

LIPID PROFILE

Lab Technician

Timing : 24/7 hrs

This Report is not valid for medico legal purpose

Consulting Pathologist

Dr. Umesh Kumar

M.B.B.S., M.D. (Pathologist)

MCI Reg. No. 41413

Note: These tests have technical limitations. Clinico-pathological interpretation is necessary. In case of any disparity test may be repeated immediately.

Address : 36/44 FK Kabir Nagar, Durgakund, Varanasi – 221005

Email: dramishra@gmail.com, drpallaviojha@gmail.com Website: panaceahospital.org

Facilities:

All clinical Biomedical & Hematology Investigations including Bone Marrow Examination VPT, Podiascan & Complete Foot Care (First Time in Purvanchal) All Hormonal Investigation by Chemiluminescent Method Visceral Fat by (AB-140) Ambulatory BP Monitoring CGMS & Insulin Pump Available PFT, 2D-ECHO (Color Doppler), Holter, TMT, Cardiac-3 available VIA, VILI, Colposcopy available Special Endocrinological Investigation Protocols.

ISO 9001:2008 Certified
Mobile: 9389994334, 9554572190, 9453837595



Panacea Pathology

Clinical Reference Lab

Persistence, Preparedness and Precision
EQAS (CMC Vellore Attached) & IQAS System
पूर्वांचल की सर्वोत्तम गुणवत्ता वाली पैथोलॉजी

UHID No :- UD-24250004006 **Booking No/Date** :- 163 / 26-Oct-2024 08:02 PM
Patient Name :- Mr RAM MILAN **Age/Sex** :- 27 Y/M
Father :- RAMLADAITE **OP No** :- OP-24250012063
Address :- JALALPUR MATOULI KANNAUJ 209733 , **Mobile No** :- 9598937097
UTTAR PRADESH
Consultant :- Dr R C TRIVEDI (MBBS)

Investigations	Observations	Biological Ref. Interval	Unit
TOTAL CHOLESTROL	129.0	Desirable : - < 200 mg/dL Borderline: - 200 - 239 mg/dL High : - > 240mg/dL	mg/dl
TRIGLYCERIDES	171.0	35.00 - 160.00	mg/dl
HDL CHOLESTROL	39.0	35.30 - 79.50	mg/dl
LDL CHOLESTROL	55.8	< 130	mg/dl
VLDL	34.20	< 40	mg/dl
NON HDL	90.0	0.00 - 100.00	mg/dl
REMNANT CHOLESTROL	34.2	11.40 - 25.70	mg/dL
CHOLESTROL/ HDL RATIO	3.31	< 3.0 LOW RISK, 3.0-5.0 AVG RISK, > 5.0 HIGH RISK	ratio
LDL/HDL RATIO	1.43	< 3	ratio

BIOCHEMISTRY

PPBS(POST PRANDIAL BLOOD SUGAR)

POST PRANDIAL BLOOD GLUCOSE(2 HR AFTER MEAL)	103.0	110.00 - 150.00	mg/dl
IGT(2 HR 75GM GLUCOSE)	--	140.00 - 199.00	mg/dl
DIABETES	---	upto200	mg/dl
TARGET IN DM	---	80.00 - 130.00	mg/dl

Consulting Pathologist

Dr. Umesh Kumar

M.D., Pathology

MCI Reg. No. 41413

Lab Technician

Timing : 24/7 hrs

This Report is not valid for medico legal purpose

Note: These tests have technical limitations. Clinico-pathological interpretation is necessary. In case of any disparity test may be repeated immediately.

Address : 36/44 FK Kabir Nagar, Durgakund, Varanasi - 221005

Email: dramishra@gmail.com, drpallaviojha@gmail.com Website: panaceahospital.org

Facilities:

All clinical Biomedical & Hematology Investigations including Bone Marrow Examination
 VPT, Podiascan & Complete Foot Care (First Time in Purvanchal)
 All Hormonal Investigation by Chemiluminescent Method
 Visceral Fat by (AB-140) Ambulatory BP Monitoring
 CGMS & Insulin Pump Available
 PFT, 2D-ECHO (Color Doppler), Holter, TMT, Cardiac-3 available
 VIA, VILI, Colposcopy available
 Special Endocrinological Investigation Protocols.

ISO 9001:2008 Certified
 Mobile: 9389994334, 9554572190, 9453837595



Panacea Pathology

Clinical Reference Lab

Persistence, Preparedness and Precision
 EQAS (CMC Vellore Attached) & IQAS System
 पूर्वांचल की सर्वोत्तम गुणवत्ता वाली पैथोलॉजी

UHID No :- UD-24250004006 **Booking No/Date** :- 163 / 26-Oct-2024 08:02 PM
Patient Name :- Mr RAM MILAN **Age/Sex** :- 27 Y/M
Father :- RAMLADAITE **OP No** :- OP-24250012063
Address :- JALALPUR MATOULI KANNAUJ 209733, UTTAR PRADESH **Mobile No** :- 9598937097
Consultant :- Dr R C TRIVEDI (MBBS)

Investigations	Observations	Biological Ref. Interval	Unit
----------------	--------------	--------------------------	------

IMMUNOLOGY

THYROID PROFILE (T3,T4,TSH)

T3	0.94	0.60 - 1.81	ng/ml
T4	5.72	4.50 - 10.90	ug/dl
TSH	1.98	0.39 - 6.10	uIU/mL

BIOCHEMISTRY

BLOOD SUGAR FASTING

GLUCOSE	87.0	60.00 - 100.00	mg/dl
PRE-DIABETICS(IMPAIRED FASTING TOLER)	---	100.00 - 125.00	mg/dl
DIABETICS	---	upto 126	mg/dl
TARGET IN DM	---	80.00 - 130.00	mg/dl

* END OF REPORT *

Lab Technician

Consulting Pathologist
Dr. Umesh Kumar
 MBBS, MD (Pathologist)
 M.D., Pathology

Timing : 24/7 hrs

This Report is not valid for medico legal purpose

Note: These tests have technical limitations. Clinico-pathological interpretation is necessary. In case of any disparity test may be repeated immediately.

Address : 36/44 FK Kabir Nagar, Durgakund, Varanasi – 221005

Email: dramishra@gmail.com, drpallaviojha@gmail.com Website: panaceahospital.org

Facilities:

All clinical Biomedical & Hematology Investigations including Bone Marrow Examination
 VPT, Podiascan & Complete Foot Care (First Time in Purvanchal)
 All Hormonal Investigation by Chemiluminescent Method
 Visceral Fat by (AB-140) Ambulatory BP Monitoring
 CGMS & Insulin Pump Available
 PFT, 2D-ECHO (Color Doppler), Holter, TMT, Cardiac-3 available
 VIA, VILI, Colposcopy available
 Special Endocrinological Investigation Protocols.

ISO 9001:2008 Certified
 Mobile: 9389994334, 9554572190, 9453837595



Panacea Pathology

Clinical Reference Lab

Persistence, Preparedness and Precision
 EQAS (CMC Vellore Attached) & IQAS System
 पूर्वांचल की सर्वोत्तम गुणवत्ता वाली पैथोलॉजी

UHID No	:- UD-24250004006	Booking No/Date	:-163 / 26-Oct-2024 08:02 PM
Patient Name	:- Mr RAM MILAN	Age/Sex	:- 27 Y/M
Father	:- RAMLADAITE	OP No	:- OP-24250012063
Address	:- JALALPUR MATOULI KANNAUJ 209733 , UTTAR PRADESH	Mobile No	:- 9598937097
Consultant	:- Dr R C TRIVEDI (MBBS)		

Investigations	Observations	Biological Ref. Interval	Unit
----------------	--------------	--------------------------	------

URINE EXAMINATION

URINE ROUTINE EXAMINATION

PHYSICAL EXAMINATION

QUANTITY	25		ml
COLOR <i>Methology</i>	STRAW	CLEAR YELLOW	
APPEARANCE <i>DefaultMethod</i>	CLEAR	CLEAR	

CHEMICAL EXAMINATION

SPECIFIC GRAVITY	1.015	1.01 - 1.03	
PH	6.0	4.60 - 8.00	
GLUCOSE	NIL	60.00 - 100.00	mg/dl
PROTEIN-	NIL		

MICROSCOPIC EXAMINATION

PUS CELLS	01-02	2.00 - 3.00	/HPF
RBCS (RED BLOOD CELLS)	NIL	4.50 - 5.50	/HPF
EPITHELIAL CELLS	NIL		/HPF
CASTS	ABSENT	ABSENT	
CRYSTALS	ABSENT	ABSENT	

Consulting Pathologist

Dr. Umesh Kumar
 M.D., Pathology
 MBBS, MD (Pathologist)

Lab Technician

Timing : 24/7 hrs

This Report is not valid for medico legal purpose

Note: These tests have technical limitations. Clinico-pathological interpretation is necessary. In case of any disparity test may be repeated immediately.

Address : 36/44 FK Kabir Nagar, Durgakund, Varanasi – 221005

Email: dramishra@gmail.com, drpallaviojha@gmail.com Website: panaceahospital.org

Facilities:

All clinical Biomedical & Hematology Investigations including Bone Marrow Examination
 VPT, Podiascan & Complete Foot Care (First Time in Purvanchal)
 All Hormonal Investigation by Chemiluminescent Method
 Visceral Fat by (AB-140) Ambulatory BP Monitoring
 CGMS & Insulin Pump Available
 PFT, 2D-ECHO (Color Doppler), Holter, TMT, Cardiac-3 available
 VIA, VILI, Colposcopy available
 Special Endocrinological Investigation Protocols.

ISO 9001:2008 Certified
 Mobile: 9389994334, 9554572190, 9453837595



Panacea Pathology

Clinical Reference Lab

Persistence, Preparedness and Precision
 EQAS (CMC Vellore Attached) & IQAS System
 पूर्वांचल की सर्वोत्तम गुणवत्ता वाली पैथोलॉजी

UHID No	:- UD-24250004006	Booking No/Date	:-163 / 26-Oct-2024 08:02 PM
Patient Name	:- Mr RAM MILAN	Age/Sex	:- 27 Y/M
Father	:- RAMLADAITE	OP No	:- OP-24250012063
Address	:- JALALPUR MATOULI KANNAUJ 209733 , UTTAR PRADESH	Mobile No	:- 9598937097
Consultant	:- Dr R C TRIVEDI (MBBS)		

Investigations	Observations	Biological Ref. Interval	Unit
<u>PARASITOLOGY</u>			
STOOL ROUTINE			
<u>GROSS EXAMINATON</u>			
COLOR <i>Methology</i>	YELLOW	CLEAR YELLOW	
CONSISTANCY	NORMAL		
BLOOD	ABSENT		
MUCUS	ABSENT		
<u>MICROSCOPIC EXAMINATON</u>			
OVA OR EGGS OF HELMINTHS	ABSENT		
CYST OF PROTOZOA	ABSENT		
VEG. FORMS OF PROTOZOA	ABSENT		
PUS CELLS	03-04	2.00 - 3.00	/HPF
RBC <i>Methology / Carm</i>	NIL	4.50 - 5.50	million/cumm

* END OF REPORT *

Consulting Pathologist
Dr. UMESH KUMAR
 Dr. Umesh Kumar
 MBBS, MD (Pathologist)
 M.D., Pathology

Lab Technician

Timing : 24/7 hrs

This Report is not valid for medico legal purpose

Note: These tests have technical limitations. Clinico-pathological interpretation is necessary. In case of any disparity test may be repeated immediately.

Address : 36/44 FK Kabir Nagar, Durgakund, Varanasi – 221005

Email: dramishra@gmail.com, drpallaviojha@gmail.com Website: panaceahospital.org



PANACEA HOSPITAL



A shelter for many hearts A Home for many lives

(An ISO 9001:2008 Certified Organisation)
Lab Attached with CMC Under EQAS Scheme

Dept. of Radiodiagnosis - 32 Slice CT Scan, 3D/4D USG, 2D ECHO, Colour Doppler, Intervention Procedures, Digital X-Ray

NAME: RAM MILAN

AGE/SEX: 27YRS/MALE

REF.DR. DR.ASHUTOSH MISHRA(MD)

DATE: 26/10/2024


Echo - Cardiography

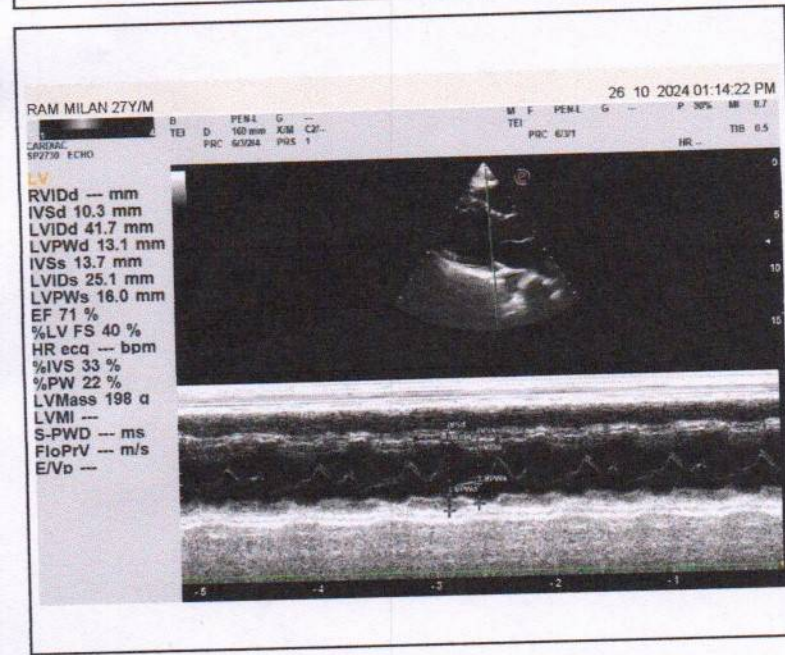
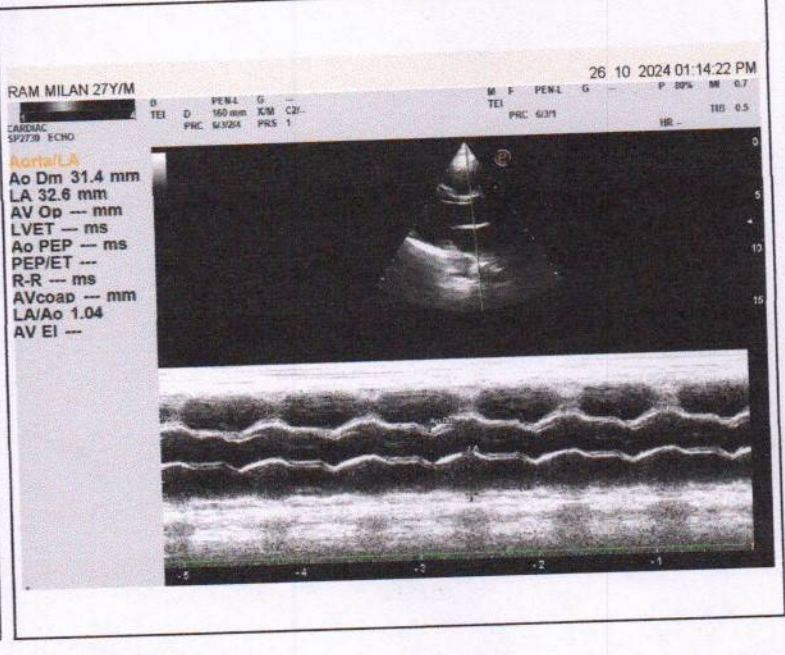
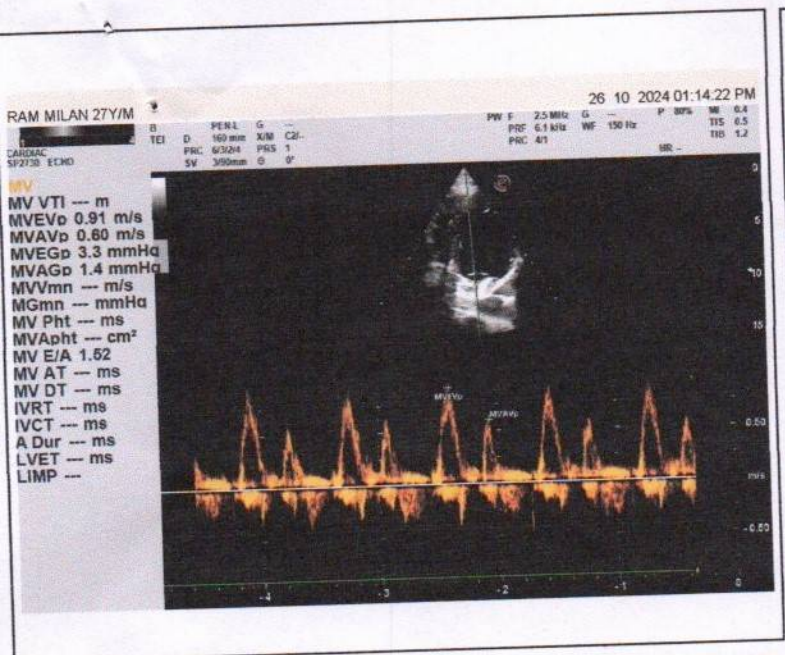
MITRAL VALVE Doppler	AML - normal morphology MV Flow - E - 0.9 A-0.6 E/A=1.52	PML - normal morphology MVA - 3.0 cm ² Mitral Regurgitation - No
TRICUSPID VALVE Doppler	Normal TV Flow -No	Tricuspid Regurgitation - No
PULMONARY VALVE Doppler	Normal PV Flow -No	Pulmonary Regurgitation - No
AORTIC VALVE Doppler	Trileaflet-No AV Flow - no	Aortic Regurgitation - No
MEASUREMENT	Aorta - 31.4 (20-38) mm IVS ed -10.3 (6-12) mm LVID ed -41.7 (35-55) mm LVPW ed - 13.1 (6-12) mm OA - 7 (> 5) mm	LA -32.6 (24-32) mm IVS es -13.7 (6-12) mm LVID es -25.1 (24-40) mm LVPW es - 16.0 (6-12) mm EPSS - 4 (< 9) mm

CONCLUSION All cardiac chamber dimensions are WNL
No valvular abnormalities
Good LV systolic function present Modified Simpson's method (4C, 2C) (LVEF-71%)
No diastolic dysfunction present (E/A = 1.52)
No pericardial effusion
No RWMA
Intact IAS / IV
No PAH
No intra cardiac mass /thrombus /vegetation

IMPRESSION Normal echocardiogram


Niraj Mishra
Physician Assistant
(PIIRE)


Dr. Pallavi Misra
MBBS, MD (MED) Lucknow
MBBS, MD (General Medicine)
Non-invasive Cardiologist, MIAE
MCT Reg. No. 52033
Women Cardiologist
Diabetocardiologist





PANACEA HOSPITAL



A shelter for many hearts A Home for many lives

(An ISO 9001:2008 Certified Organisation)
Lab Attached with CMC Under EQAS Scheme

Dept. of Radiodiagnosis - 32 Slice CT Scan, 3D/4D USG, 2D ECHO, Colour Doppler, Intervention Procedures, Digital X-Ray

NAME: RAM MILAN
REF.DR. ASHUTOSH MISHRA(MD)

AGE/SEX: 27 YRS/MALE
DATE: 26/10/2024

ULTRASOUND WHOLE ABDOMEN REPORT

Liver: Normal in size(134mm), shape, & echogenicity. Intra & extra hepatic biliary radicals & vascular structures are normal. Margins are smooth and regular.

Gall bladder: Normally distended with echo free lumen.

Portal vein: Normal in course and caliber.

CBD diameter: Visualized part normal in course & caliber.

Pancreas: Normal in size, shape & echogenicity. Margins are smooth & regular. No diffuse/ focal lesion seen. Pancreatic duct not visualized.

Spleen: Normal in size(9.5cm), shape & echogenicity. Margins are smooth & regular. No diffuse / focal lesion seen.

Kidney: Right kidney: 8.3x4.8cm, Left kidney: 9.7x4.9 cm.
Both normal in size, shape echogenicity & position. Cortical-medullary differentiation is maintained. Pelvicalyceal system normal. No evidence of any calculus/mass lesion seen
No hydronephrosis/ hydroureter seen. No suprarenal mass lesion.

Urinary bladder: Normally distended with normal wall thickness. No echogenic foci lumen or diverticula seen.
Both VUJ appears normal. No evidence of calculus / mass lesion seen.

Prostate: Normal in size, shape & echogenicity.

Others: No free fluid in peritoneal cavity.
No free fluid in bilateral pleural cavity.
No evidence of significantly enlarged retroperitoneal/ mesenteric lymph nodes noted.

IMPRESSION: - **NO OBVIOUS SONOLOGICAL ABNORMALITY SEEN.**

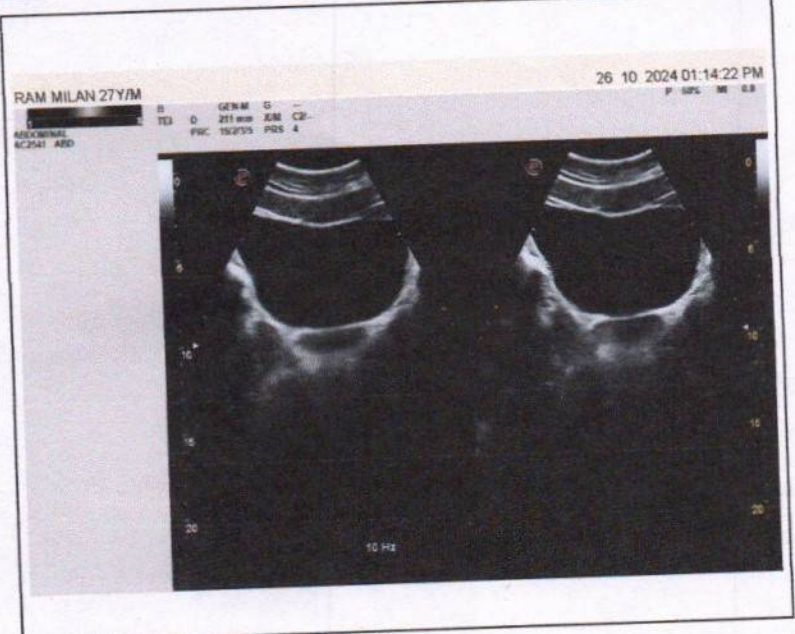
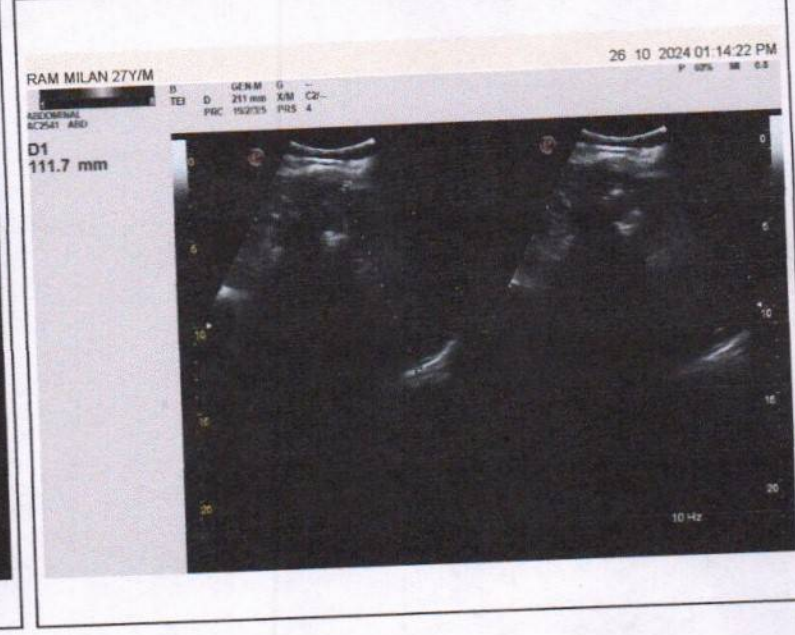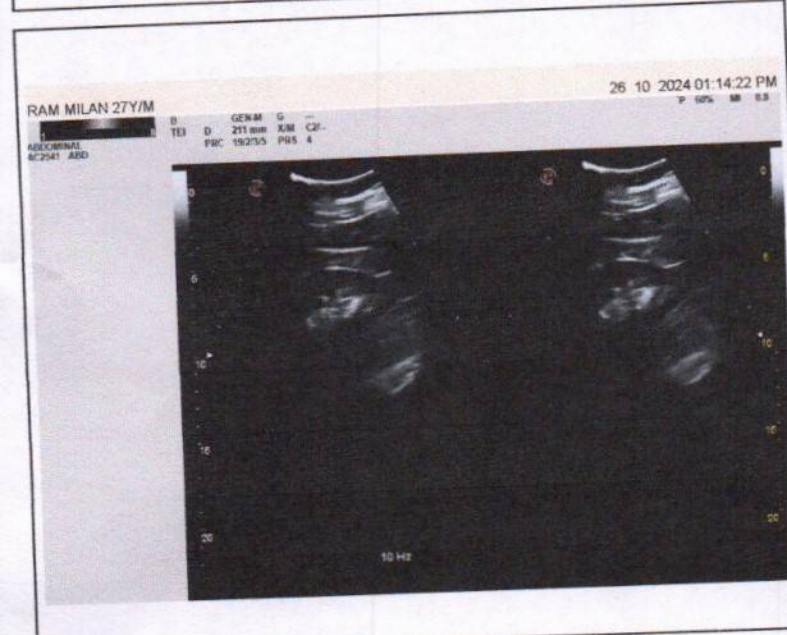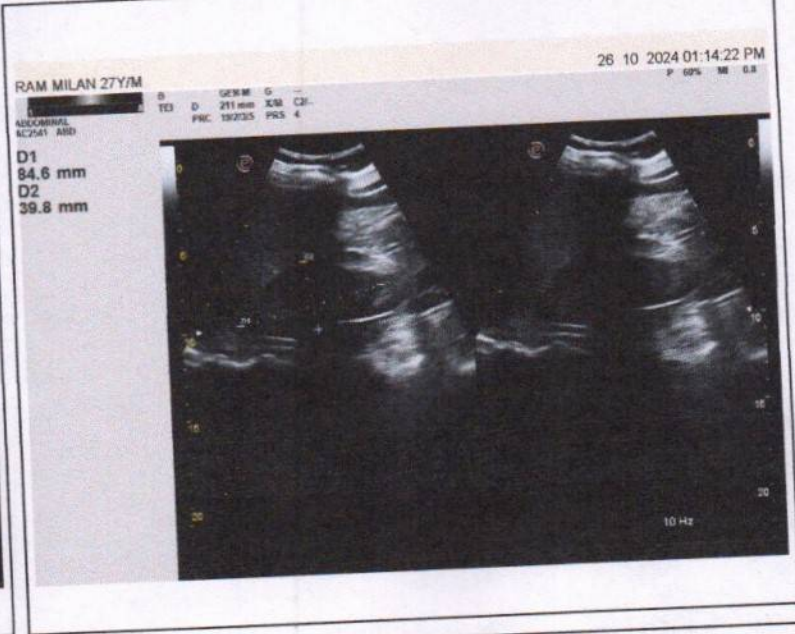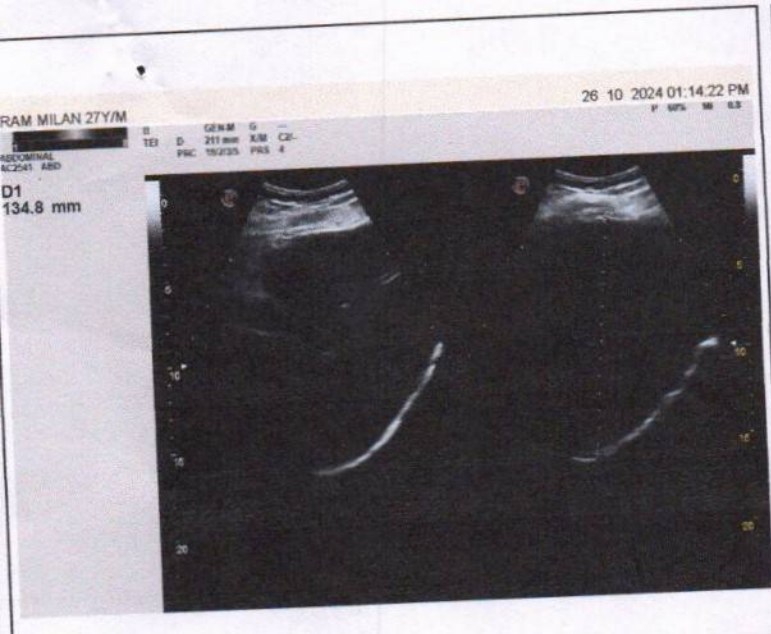
Please correlate clinically and further investigations.

Note: (1) This report is not valid for medico-legal purposes.
(2) In case of any discrepancy due typing error, please get it Rectified immediately.


Sonologist
Dr. Rahul Kumar Tiwari
MBBS, MD (Radio Diagnosis)
MCI Reg. No. 57557

Disclaimer: This report is not valid for Madicolegal or Judicial Purpose. Radiological diagnosis is solely interpretation of Images produced by tissue & may not be always conclusive.

Address : B36/44 B4 Kabir Nagar (Near Sanjay Shiksha Niketan), Durgakund, Varanasi
Mobile : 9554572190 / 9453837595 / Recpn, 9389994334
Email : dramishra@gmail.com, drpallaviojha@gmail.com, Website : www.piire.org





Call Now - 1800-123-3070

PANACEA HOSPITAL



A shelter for many hearts A Home for many lives

(An ISO 9001:2008 Certified Organisation)
Lab Attached with CMC Under EQAS Scheme

Dept. of Radiodiagnosis - 32 Slice CT Scan, 3D/4D USG, 2D ECHO, Colour Doppler, Intervention Procedures, Digital X-Ray

NAME:MR.RAM MILAN

AGE/SEX: 27 YRS / MALE

REF BY: DR. ASHUTOSH MISHRA (MD)

DATE:26/10/2024

X-RAY CHEST (PA VIEW)

- **B/L Hyperinflated lung show hazy opacities in both parahilar zone with prominent brochopulmonary markings and narrow mediastinum.**
- Rest of the bilateral lung fields appear normal.
- Trachea and mediastinum appear normal in position.
- Both hila appear normal in size and are symmetrical.
- Transverse cardiac diameter is within normal limits.
- Both CP angles appear clear. Normal position and contour diaphragms noted.
- Bony rib cage and soft tissue shadows appear normal.

Thanks for reference.

Rcl
Dr. Randeep Kumar Tiwari
Radiologist
MBBS, MD (Radio Diagnosis)
MCI Reg. No. 57557

Disclaimer: This report is not valid for Madicolegal or Judicial Purpose. Radiological diagnosis is solely interpretation of images produced by tissue & may not be always conclusive.

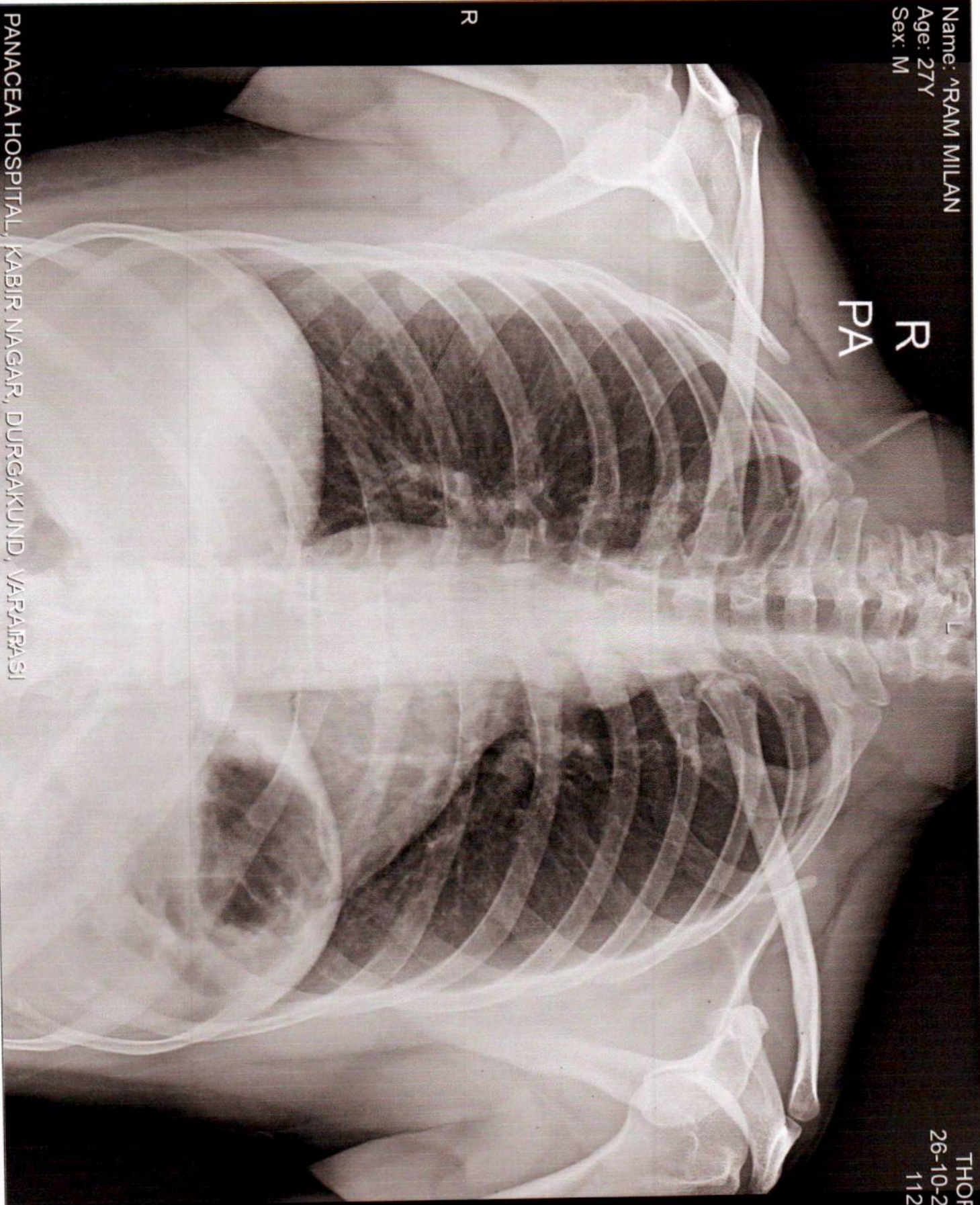
Address : B36/44 B4 Kabir Nagar (Near Sanjay Shiksha Niketan), Durgakund, Varanasi

Mobile : 9554572190 / 9453837595 / Recpn, 9389994334

Email : dramishra@gmail.com, drpallaviojha@gmail.com, Website : www.paire.org

Name: RAM MILAN
Age: 27Y
Sex: M

R
PA



PANACEA HOSPITAL, KABIR NAGAR, DURGAKUND, VARANASI

THORAX
26-10-2024
112918

20 cm L



Call Now - 1800-123-3070

PANACEA HOSPITAL



A shelter for many hearts A Home for many lives

(An ISO 9001:2008 Certified Organisation)
Lab Attached with CMC Under EQAS Scheme

Dept. of Radiodiagnosis - 32 Slice CT Scan, 3D/4D USG, 2D ECHO, Colour Doppler, Intervention Procedures, Digital X-Ray

NAME:RAM MILAN**AGE/SEX: 27YRS/MALE****REF.DR. DR.ASHUTOSH MISHRA(MD)****DATE: 26/10/2024**

Echo - Cardiography

MITRAL VALVE Doppler	AML - normal morphology MV Flow - E - 0.9 A-0.6 E/A=1.52	PML - normal morphology MVA - 3.0 cm ² Mitral Regurgitation - No
TRICUSPID VALVE Doppler	Normal TV Flow -No	Tricuspid Regurgitation - No
PULMONARY VALVE Doppler	Normal PV Flow -No	Pulmonary Regurgitation - No
AORTIC VALVE Doppler	Trileaflet-No AV Flow - no	Aortic Regurgitation - No
MEASUREMENT	Aorta - 31.4 (20-38) mm IVS ed -10.3 (6-12) mm LVID ed -41.7 (35-55) mm LVPW ed - 13.1 (6-12) mm OA - 7 (> 5) mm	LA -32.6 (24-32) mm IVS es -13.1 (6-12) mm LVID es -25.1 (24-40) mm LVPW es - 16.0 (6-12) mm EPSS - 4 (< 9) mm

CONCLUSION All cardiac chamber dimensions are WNL
No valvular abnormalities
Good LV systolic function present Modified Simpson's method (4C, 2C) (LVEF-71%)
No diastolic dysfunction present (E/A = 1.52)
No pericardial effusion
No RWMA
Intact IAS / IV
No PAH
No intra cardiac mass /thrombus /vegetation

IMPRESSION Normal echocardiogram

Niraj Mishra
Niraj Mishra
Physician Assistant
(PIIRE)

Dr. Pallavi Misra
Dr. Pallavi Misra
MBBS, MD (General Medicine)
MCI Reg. No. 52033
MBBS, MD (MED) Lucknow
Echocardiography Specialist, MIAE
Non-invasive cardiologist
Women Cardiologist
Diabetocardiologist

Disclaimer: This report is not valid for Madicolegal or Judicial Purpose. Radiological diagnosis is solely interpretation of images produced by tissue & may not be always conclusive.

Address : B36/44 B4 Kabir Nagar (Near Sanjay Shiksha Niketan), Durgakund, Varanasi

Mobile : 9554572190 / 9453837595 / Recpn, 9389994334

Email : dramishra@gmail.com, drpallaviojha@gmail.com, Website : www.piire.org

