



Patient's name : JHA PRAVIN KUMAR
 Age/Sex : 49 Years/Male
 Referred by : MEDI WHEEL
 Collection Time : 09:12

Reg. ID : P-6501-23
 Accession : 23574
 Order Dt/time : 08/03/2024 09:12

Complete Blood Count

Sample Type: EDTA

Test Name	Result	Units	Biological Reference Interval
Blood Counts			
Haemoglobin :	12.6	Gms%	13.5 - 18.0
Total R.B.C. :	4.03	mill/c.mm	4.7 - 6.0
Total W. B. C. :	5970	/cu mm	4000 - 10500
Platelet Count :	161000	/cu.mm	1,50,000 - 4,50,000
Differential Count			
Neutrophils :	55	%	40 - 70
Lymphocytes :	40	%	20 - 40
Eosinophils :	03	%	1 - 4
Monocytes :	02	%	2 - 6
Basophils :	00	%	0 - 01
Blood Indices			
P. C. V. :	38.9	%	42 - 52
M. C. V. :	96.5	fl	78 - 100
M.C.H :	31.2	pg	27 - 31
M. C. H. C. :	32.3	%	32 - 36
R.D.W :	13.2	%	11.5 - 14.0
E.S.R.(Westergren Method)			
After one hour :	04	mm/hr	1 - 7

TESTS DONE ON FULLY AUTOMATED HEMATOLOGY ANALYZER.

Dr. Gayatri M. Mehta
 M.D. (Patho)

Reg. No. G-22215

DR GAYATRI MEHTA
 MD(PATHOLOGY)

DR. ANAND D. PARIKH
 MD(PATHOLOGY)

LAB USE ONLY (Entered by :GM Enter Date/Time 08/03/2024 16:57:00) (Verify by :GM Verify Date/Time 08/03/2024 16:57:00)



Vidhi Diagnostics | Pathology Department

L-86, Swatantra Senani Nagar, Opp. Akhbarnagar Petrol Pump, Nr. Akhbarnagar Circle, Nava-Vadaj, Ahmedabad - 380 013.

M. - Pathology : 8849893954, Ph. : 079-27621406, M. 98799 29406, 98250 09406, E-mail : vidhidiagnostics@gmail.com, Web. : www.vidhidiagnostics.com

Time (Pathology) : Mon. to Sat. 8.30 am to 8.00 pm, Sunday 9 am to 12 Noon

Pathology means science behind medicine

CT SCAN & CBCT FACILITY NOW AVAILABLE



Pathology Department



Patient's name : JHA PRAVIN KUMAR
Age/Sex : 49 Years/Male
Referred by : MEDI WHEEL
Collection Time : 09:12

Reg. ID : P-6501-23
Accession : 23574
Order Dt/time : 08/03/2024 09:12

Blood Group

Sample Type: EDTA sample.

Test Name	Result
BG :	" O "
RH :	POSITIVE
Remarks	Done by forward grouping method.

Blood Glucose

Sample Type: Serum

Test Name	Result	Units	Biological Reference Interval
Fasting Blood Glucose :	88.1	mg/dl	70 - 110
Urine Sugar :	NIL		Absent
<i>GOD-POD Method.</i>			

Blood Glucose

Sample Type: Serum

Test Name	Result	Units	Biological Reference Interval
Post Prandial Blood Glucose After 2hr. :	96.7	mg/dl	80 - 140
Urine Sugar :	NIL		Absent
<i>GOD-POD Method.</i>			

Dr. Gayatri M. Mehta

M. D. (Patho)

Reg. No. G-32215

DR. GAYATRI MEHTA
MD(PATHOLOGY)

DR. ANAND D. PARIKH
MD(PATHOLOGY)

LAB USE ONLY (Entered by :GM Enter Date/Time:08/03/2024 16:57:00) (Verify by :GM Verify Date/Time:08/03/2024 16:57:00)



Vidhi Diagnostics | Pathology Department

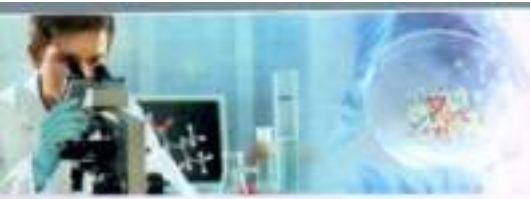L-86, Swatantra Senani Nagar, Opp. Akharnagar Petrol Pump, Nr. Akharnagar Circle, Nava-Vadaj, Ahmedabad - 380 013.

M. - Pathology : 8849893954, Ph. : 079-27621406, M. 98799 29406, 98250 09406, E-mail : vidhidiagnostics@gmail.com, Web. : www.vidhidiagnostics.com

Time (Pathology) : Mon. to Sat. 8.30 am to 8.00 pm, Sunday 9 am to 12 Noon

Pathology means science behind medicine

CT SCAN & CBCT FACILITY NOW AVAILABLE



Pathology Department



Patient's name : JHA PRAVIN KUMAR
Age/Sex : 49 Years/Male
Referred by : MEDI WHEEL
Collection Time : 09:12

Reg. ID : P-6501-23
Accession : 23574
Order Dt/time : 08/03/2024 09:12

Lipid Profile

Sample Type: Serum

Test Name	Result	Units	Biological Reference Interval
S. Cholesterol : <small>Oxidase-esterase method.</small>	145	mg/dl	0 - 200
S. Triglyceride : <small>Enzymatic Colorimetry method</small>	166.1	mg/dL	0 - 200
S. HDL - Cholesterol : <small>Serum by Enzymatic method.</small>	40.3	mg/dL	35 - 65
S. LDL - Cholesterol : <small>Serum by Enzymatic method</small>	71.48	mg/dL	0 - 130
S. VLDL - Cholesterol :	33.22	mg/dL	0 - 30
S. Chole/HDL.Ratio :	3.6		1 - 6
S. LDL / HDL Cholesterol Ratio :	1.77		0 - 3.5

Dr. Gayatri M. Mehta
M. D. (Pathology)
Reg. No. G-32215
DR GAYATRI MEHTA
MD(PATHOLOGY)

DR. ANAND D. PARIKH
MD(PATHOLOGY)

LAB USE ONLY (Entered by :GM Enter Date/Time:08/03/2024 16:57:00) (Verify by :GM Verify Date/Time:08/03/2024 16:57:00)



Vidhi Diagnostics | Pathology Department

L-86, Swatantra Senani Nagar, Opp. Akhbarnagar Petrol Pump, Nr. Akhbarnagar Circle, Nava-Vadaj, Ahmedabad - 380 013.

M. - Pathology : 8849893954, Ph. : 079-27621406, M. 98799 29406, 98250 09406, E-mail : vidhidiagnostics@gmail.com, Web. : www.vidhidiagnostics.com
Time (Pathology) : Mon. to Sat. 8.30 am to 6.00 pm, Sunday 9 am to 12 Noon

Pathology means science based medicine

CT SCAN & CBCT FACILITY NOW AVAILABLE



Pathology Department



Patient's name : JHA PRAVIN KUMAR
Age/Sex : 49 Years/Male
Referred by : MEDI WHEEL
Collection Time : 09:12

Reg. ID : P-6501-23
Accession : 23574
Order Dt/time : 08/03/2024 09:12

HbA1C

Sample Type: EDTA

Test Name	Result	Units	Biological Reference Interval
HbA1C :	4.5	%	Non-diabetic: 4.2-6.2 Pre-diabetic : 6.3-7.2 Diabetic : 7.3-8.2
Mean Blood Glucose of Last 03 months.	82	mg/dl	

Comment *As per the new 2009 update of American Diabetes Association regarding HbA1C & Mean Blood Glucose relationship.
NOTE: This test is used to monitor diabetic patients compliance with the therapeutic regimen and logo It's level is proportional to both the average blood glucose concentration and the life span of the red blood cells (RBC) in circulation. HbA1c values are free of day to day glucose fluctuations and are unaffected by exercise or recent food intake.

Dr. Gayatri M. Mehta

M. D. (Patho)

Reg. No. G-32215
DR GAYATRI MEHTA
MD(PATHOLOGY)

DR. ANAND D. PARIKH
MD(PATHOLOGY)

LAB USE ONLY (Entered by :GM Enter Date/Time:08/03/2024 16:57:00) (Verify by :GM Verify Date/Time:08/03/2024 16:57:00)



Vidhi Diagnostics | Pathology Department

L-86, Swatantra Senani Nagar, Opp. Akhbarnagar Petrol Pump, Nr. Akhbarnagar Circle, Nava-Vadaj, Ahmedabad - 380 013.

M. - Pathology : 8849893954, Ph. : 079-27621406, M. 98799 29406, 98250 09406, E-mail : vidhidiagnostics@gmail.com, Web. : www.vidhidiagnostics.com

Time (Pathology) : Mon. to Sat. 8.30 am to 8.00 pm, Sunday 9 am to 12 Noon

Pathology means science behind medicine

CT SCAN & CBCT FACILITY NOW AVAILABLE



Pathology Department



Patient's name : JHA PRAVIN KUMAR
Age/Sex : 49 Years/Male
Referred by : MEDI WHEEL
Collection Time : 09:12

Reg. ID : P-6501-23
Accession : 23574
Order Dt/time : 08/03/2024 09:12

BIOCHEMISTRY

Sample type :Serum

Table with 4 columns: Test Name, Result, Units, Biological Reference Interval. Rows include Urea, S.Uric acid, Bun, Creatinine, S.G.P.T (ALT), S.G.O.T (AST), ALK.PHOSPHATASE, G.G.T, BILIRUBIN (Total, Direct, Indirect), and SERUM PROTEINS (Total Protein, Albumin, Globulins, A/G Ratio).

Dr. Gayatri M. Mehta
M. D. (Patho)

DR GAYATRI MEHTA
MD(PATHOLOGY)

DR. ANAND D. PARIKH
MD(PATHOLOGY)

LAB USE ONLY (Entered by :GM Enter Date/Time:08/03/2024 18:56:00) (Verify by :GM Verify Date/Time:08/03/2024 18:56:00)



Vidhi Diagnostics | Pathology Department

L-86, Swatantra Senani Nagar, Opp. Akhbarnagar Petrol Pump, Nr. Akhbarnagar Circle, Nava-Vadaj, Ahmedabad - 380 013.

M. - Pathology : 8849893954, Ph. : 079-27621406, M. 98799 29406, 98250 09406, E-mail : vidhidiagnostics@gmail.com, Web. : www.vidhidiagnostics.com

Time (Pathology) : Mon. to Sat. 8.30 am to 8.00 pm, Sunday 9 am to 12 Noon

Pathology means science behind medicine

CT SCAN & CBCT FACILITY NOW AVAILABLE



Pathology Department



Patient's name : JHA PRAVIN KUMAR
Age/Sex : 49 Years/Male
Referred by : MEDI WHEEL
Collection Time : 09:12

Reg. ID : P-6501-23
Accession : 23574
Order Dt/time : 08/03/2024 09:12

Thyroid Function Test

Sample Type: Serum

Table with 4 columns: Test Name, Result, Units, Biological Reference Interval. Rows include TOTAL T3, TOTAL T4, and TSH(Ultra sensitive).

Dr. Gayatri M. Mehta
M. D. (Patho)
Reg. No. G-32215

DR GAYATRI MEHTA
MD(PATHOLOGY)

DR. ANAND D. PARIKH
MD(PATHOLOGY)

LAB USE ONLY (Entered by :GM Enter Date/Time:08/03/2024 18:58:00) (Verify by :GM Verify Date/Time:08/03/2024 18:58:00)



Vidhi Diagnostics | Pathology Department

L-86, Swatantra Senani Nagar, Opp: Akhbarnagar Petrol Pump, Nr. Akhbarnagar Circle, Nava-Vadaj, Ahmedabad - 380 013.

M. - Pathology : 8849893954, Ph. : 079-27621406, M. 98799 29406, 98250 09406, E-mail : vidhidiagnostics@gmail.com, Web. : www.vidhidiagnostics.com

Time (Pathology) : Mon. to Sat. 8.30 am to 8.00 pm, Sunday 9 am to 12 Noon

Pathology means science behind medicine

CT SCAN & CBCT FACILITY NOW AVAILABLE



Pathology Department



Patient's name : JHA PRAVIN KUMAR
 Age/Sex : 49 Years/Male
 Referred by : MEDI WHEEL
 Collection Time : 09:12

Reg. ID : P-6501-23
 Accession : 23574
 Order Dt/time : 08/03/2024 09:12

Urine Analysis

Sample Type: Urine

Test Name	Result	Units	Biological Reference Interval
<u>Physical Examination</u>			
Quantity :	10	ml	0 - 500 ml
Colour :	Yellow		Pale Yellow
Transparency :	Slight Turbid.		Clear
Reaction :	Acidic		4.6 - 8.0
Specific Gravity :	1.030		1.016 - 1.022
Sediment :	Present		
<u>Chemical Examination</u>			
Albumin :	Present (Trace)		Absent
Sugar :	NIL		Absent
Acetone :	Absent		Absent
Bile Salts :	Absent		Absent
Bile Pigments :	Absent		Absent
Urobilogen :	Absent		Absent
Nitrites :	Absent		Absent
<u>Microscopic Examination</u>			
Red blood Cells :	1-2	/h.p.f	Absent
Pus Cells :	2-3	/h.p.f	Absent
Epithelial Cells :	2-3	/h.p.f	< 10.0
Amorphous :	Absent	/h.p.f	Absent
Bacteria :	Absent	/h.p.f	Absent
Crystals :	Absent	/h.p.f	Absent
Casts :	Absent	/h.p.f	Absent
Fungus :	Not seen	/h.p.f	Absent

Dr. Gayatri M. Mehta

M. D. (Patho)

Reg. No. G-32215

DR GAYATRI MEHTA
MD(PATHOLOGY)

DR. ANAND D. PARIKH
MD(PATHOLOGY)



(Entered by : GM Enter Date/Time: 08/03/2024 18:59:00) (Verify by : GM Verify Date/Time: 08/03/2024 18:59:00)

Vidhi Diagnostics | Pathology Department

L-86, Swatantra Senani Nagar, Opp. Akhbarnagar Petrol Pump, Nr. Akhbarnagar Circle, Nava-Vadaj, Ahmedabad - 380-013.

M. - Pathology : 8849893954, Ph. : 079-27621406, M. 98799 29406, 98250 09406. E-mail : vidhidiagnostics@gmail.com, Web. : www.vidhidiagnostics.com

Time (Pathology) : Mon. to Sat. 8.30 am to 8.00 pm, Sunday 9 am to 12 Noon

Pathology means science behind medicine

CT SCAN & CBCT FACILITY NOW AVAILABLE



Patient's name : JHA PRAVIN KUMAR
Age/Sex : 49 Years/Male
Referred by : MEDI WHEEL
Collection Time : 09:12

Reg. ID : P-6501-23
Accession : 23574
Order Dt/time : 08/03/2024 09:12

Stool Examination

Sample Type: Stool

Test Name	Result	Units	Biological Reference Interval
-----------	--------	-------	-------------------------------

PHYSICAL EXAMINATION

Quantity	30 gms
Colour	Brown
Consistency	Solid
Mucus	Nil
Occult Blood	Negative
Peroxidase Reaction with o-Dianisidine	
Reaction	Acidic
pH Strip Method	

MICROSCOPIC EXAMINATION

Pus Cells	Occasional/hpf
RBCs	Nil
Vegetable Cells	Absent
Trophozoites	Nil
Cysts	Nil
Ova	Nil
Fat Globules	Nil

----- End Of Report -----

Dr. Gayatri M. Mehta

M. D. (Patho)

Reg. No. G-32215

DR GAYATRI MEHTA
MD(PATHOLOGY)

DR. ANAND D. PARIKH
MD(PATHOLOGY)

LAB USE ONLY (Entered by :GM Enter Date/Time 08/03/2024 18:59:00) (Verify by :GM Verify Date/Time 08/03/2024 18:59:00)



Vidhi Diagnostics | Pathology Department

L-86, Swatantra Senani Nagar, Opp. Akhbarnagar Petrol Pump, Nr. Akhbarnagar Circle, Nava-Vadaj, Ahmedabad - 380 013.

M. - Pathology : 8849893954, Ph. : 079-27621406, M. 98799 29406, 98250 09406, E-mail : vidhidiagnostics@gmail.com, Web. : www.vidhidiagnostics.com

Time (Pathology) : Mon. to Sat. 8.30 am to 8.00 pm, Sunday 9 am to 12 Noon

Pathology means science behind medicine

CT SCAN & CBCT FACILITY NOW AVAILABLE

Health Check up Booking Request(bobE12659), Beneficiary Code-138693

1 message

Mediwheel <wellness@mediwheel.in>
To: vidhidiagnostics@gmail.com
Cc: customercare@mediwheel.in

2 March 2024 at 12:50



Mediwheel
...Your wellness partner

011-41195959

Dear VIDHI DIAGNOSTICS

We have received a booking request with the following details. Provide your confirmation by clicking on the Yes button.

You confirm this booking? Yes No

Name : MR. JHA PRAVIN KUMAR

Hospital Package Name : Mediwheel Full Body Health Checkup Male Above 40

Appointment Date : 08-03-2024

Member Information		
Booked Member Name	Age	Gender
MR. JHA PRAVIN KUMAR	49 year	Male


Tests included in this Package -

- Stool Test
- Thyroid Profile
- ESR
- Blood Glucose (Fasting)
- General Physician Consultation
- TMT OR 2D ECHO
- Blood Group
- Blood Glucose (Post Prandial)
- Chest X-ray
- ECG
- USG Whole Abdomen
- Eye Check-up consultation
- Urine Sugar Fasting
- Urine Sugar PP
- Dental Consultation
- Urine analysis
- CBC
- HbA1c
- Lipid Profile
- Kidney Profile
- Liver profile
- Prostate Specific Antigen (PSA Male)

Thanks,

Mediwheel Team

Please Download Mediwheel App



You have received this mail because your e-mail ID is registered with **Arcofemi Healthcare Limited** This is a system-generated e-mail please don't reply to this message.

Please visit to our [Terms & Conditions](#) for more informaion. [Click here to unsubscribe.](#)



સાથે રહેશે

શ્રી પ્રવીણ કુમાર
જન્મ તારીખ: 01/01/1975
લિંગ: MALE




9199 6740 8980

VID: 9199.1676.6274.3928

મહી ઝાઠુર, મહી ઝાઠુર

Vidhi Diagnostics
L-36, Chhantara-Senani Nagar,
Opp. Ashramnagar Bus Terminal,
Nr. Ashramnagar Circle,
New Wodej, Ahmedabad-13.

Povin Jha



Ahmedabad, Gujarat, India

15, Pragatinagar, Nimay Nagar, Ahmedabad, Gujarat 380061, India

Lat 23.068114°

Long 72.561721°

08/03/24 09:41 AM GMT +05:30

Google

GPS Map Camera

Vidhi Diagnostics
L-59, Swasthika, Bani Nagar,
Opp. Ashramnagar Bus Terminal,
Nr. Ashramnagar Circle,
New Vadaj, Ahmedabad-13.

Dr. Dinesh S. Modh

M.D., D.M.R.E. (Radiodiagnosis)
Consultant Radiologist & Sonologist
Ex. Junior Lecturer, B.J. Medical College, Civil Hospital, A'bad.

VIDHI
DIAGNOSTICS



08/03/2024

Shri Paavim kumar
4948/male

Height! - 162cm

Weight! - 74kg

BP! - 112/76 mmHg.

Pulse! - 66 per min

T! - (D)

RS } (N)
CVS }

SpO2 L - 98

Asymptomatic

H/O HTN since 7 yr

NO H/O DM, HTN, Thyroid or TB.

★ Eye-check VP! -

Color-vision! - Normal

Distance! - 6/6 with spectacles

Near! - N/6 with spectacles

★ Dental: -

Oral Hygiene normal
No H/O Caries & Givities

Adv! - He is medically fit

Vidhi Diagnostics

L-05, Sankro-Sanki Nagar,
C.P. Akhbarnagar Bus Terminals, ISO 9001:2015 Certified Diagnostics Center
Nr. Akhbarnagar Circle,
New Vada, Ahmedabad-43
Vidhi Imaging Center

Dr. Vidhi D. Modh
MBBS
Reg. No.: G-74540

L-05, Sankro-Sanki Nagar, Opp. Indian Oil Petrol Pump, Akhbarnagar Circle, Nava Vada, Ahmedabad - 380 013.
Phone : (Radiology) 079-2762 1406 | M. 98799 29406, 98250 09406 | Time (Radiology) : Mon. to Sat. 9 am to 2 pm, 5 to 9 pm, Sunday 9 am to 12 Noon
E-mail : vidhidiagnostics@gmail.com, Website : www.vidhidiagnostics.com

Multislice CT Scan | CBCT-Dental Scan | Live 3D-4D Sonography | Colour Doppler | Echo Cardiography | Interventional Radiology | Maxillofacial Radiology | Fetal Medicine
Digital X-Ray | Digital Mammography | Digital OPG / TMJ | ECG / TMT / PFT / EEG / EMG | Audiometry | Pathology Laboratory | Health Check Up Plans | Pre Employment Check Up

CT SCAN & CBCT FACILITY NOW AVAILABLE

ID: 12889

Name: pravin kumar

Age: 49yrs

Sex: Male

Hospital:

Dr. Avinash Bhasin
Vishal D-C
G-45946

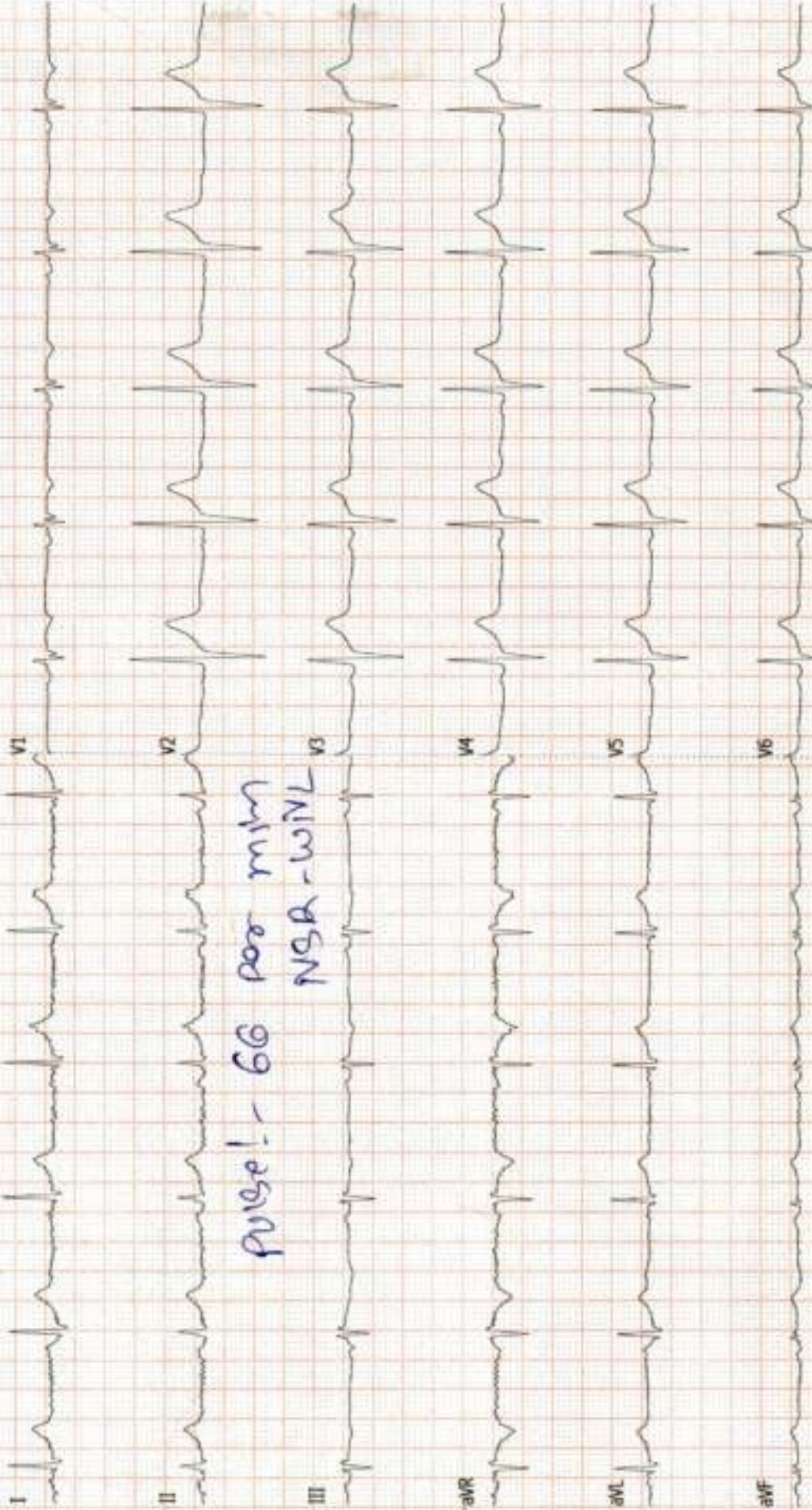
HR : 66 bpm
PR : 154 ms
QRS : 96 ms
QT/QTc : 366/382 ms
P/QRS/T : 59/13/26 deg
RV5/SV1 : 1.038/-0.284 mv
RV5+SV1 : 1.322 mv

Vidhi Diagnostics

L-88, Santanza-Gensari Nagar,
Opp. Akhbarwadi Bus Terminals,
Nr. Akhbarwadi Circle,
New Wadaj, Ahmedabad-13.

Need to be confirmed by doctor. Doctor Name:

0.67Hz - 35Hz AC 50Hz 25 mm/s 10 mm/mv



Dr. Dinesh S. Modh

M.D., D.M.R.E. (Radiodiagnosis)

Consultant Radiologist & Sonologist

Ex. Junior Lecturer, B.J. Medical College, Civil Hospital, A'bad.

VIDHI
DIAGNOSTICS



Patient's name : PRAVINKUMAR JHA
Reg. ID : R-14087-23
Referred by : MEDI WHEEL

Age/Sex : 49 Years/Male
Accession : 23586
Date : 08/03/2024

2D- ECHO REPORT

FINAL CONCLUSION:

LV IS NORMAL SIZE. GOOD LV SYSTOLIC FUNCTION NO RWMA.

LVEF - 60%. MILD CONCENTRIC LVH.

NORMAL LV COMPLIANCE.

LA IS NORMAL SIZE. NO LA CLOT.

RV IS NORMAL SIZE. GOOD RV SYSTOLIC FUNCTION.

RA IS NORMAL SIZE.

MITRAL VALVE IS NORMAL. NO MS. MILD MR (20%). NO MVP.

AORTIC VALVE IS NORMAL. NO AS. NO AR.

TRICUSPID VALVE IS NORMAL. MILD TR. RVSP-28 mmHg. NO PAH.

NO CLOT, NO VEGETATION, NO PERICARDIAL EFFUSION.

DIMENSIONS:

AORTA	2.8 C.M
LEFT ATRIUM	2.7 C.M
LVDD	4.9 C.M.
IVSD	1.1 C.M
PWD	1.1 C.M
LVDS	2.8 C.M.

COLOUR DOPPLER FINDING:

STRUCTURE	VELOCITY m/sec
	Max
PULMONARY VALVE	0.8
MITRAL VALVE	E : 0.9 A : 0.6
AORTIC VALVE	1.0

Dr. Avinash Bhaskar
Dr. Avinash Bhaskar
MBBS D-Cardio
G-45946

DR AVINASH BHASKAR
CLINICAL CARDIOLOGIST
9924836431

ISO 9001:2015 Certified Diagnostics Center

Vidhi Imaging Center

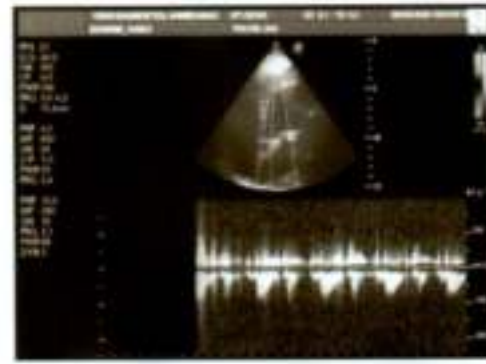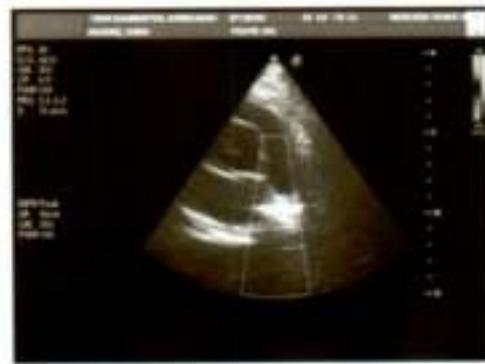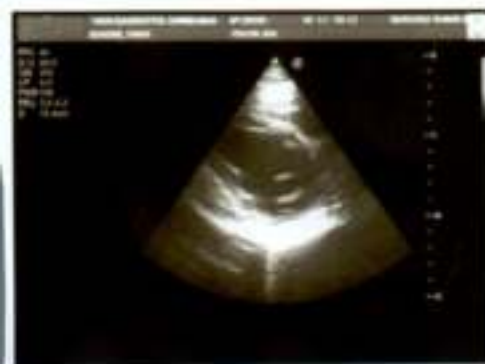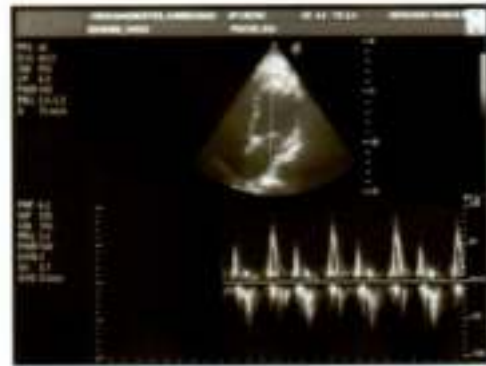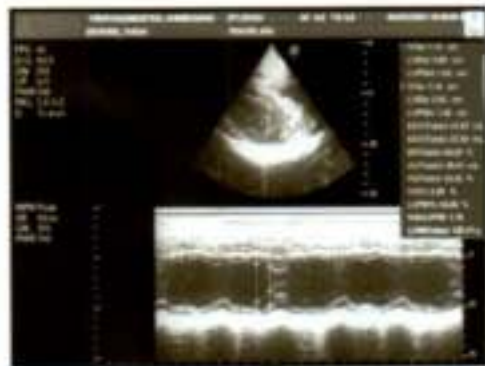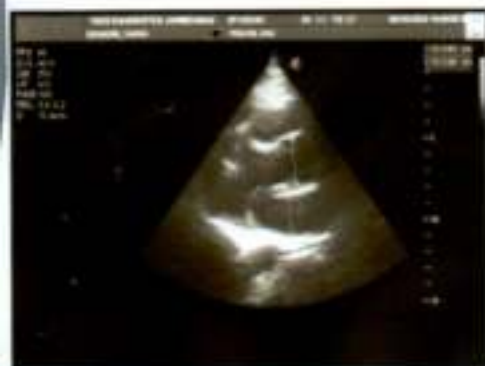L-86, Swatantra Senani Nagar, Opp. Indian Oil Petrol Pump, Akhbarnagar Circle, **Nava Vada**, Ahmedabad - 380 013.

Phone : (Radiology) 079-2762 1406 | M. 98799 29406, 98250 09406 | Time (Radiology) : Mon. to Sat. 9 am to 2 pm, 5 to 9 pm, Sunday 9 am to 12 Noon

E-mail : vidhidiagnostics@gmail.com, Website : www.vidhidiagnostics.com

Multislice CT Scan | CBCT-Dental Scan | Live 3D-4D Sonography | Colour Doppler | Echo Cardiography | Interventional Radiology | Maxillofacial Radiology | Fetal Medicine
Digital X-Ray | Digital Mammography | Digital OPG/TMJ | ECG/TMT/PFT/EEG/EMG | Audiometry | Pathology Laboratory | Health Check Up Plans | Pre Employment Check Up

CT SCAN & CBCT FACILITY NOW AVAILABLE



Dr. Dinesh S. Modh

M.D., D.M.R.E. (Radiodiagnosis)

Consultant Radiologist & Sonologist

Ex. Junior Lecturer, B.J. Medical College, Civil Hospital, A'bad.



Patient's name : PRAVINKUMAR JHA
Reg. ID : R-14087-23
Referred by : MEDI WHEEL

Age/Sex : 49 Years/Male
Accession : 23586
Date : 08/03/2024

USG ABDOMEN

LIVER:- Liver appears normal in size & echo texture. No evidence of focal lesion is seen. IHBR appear normal. Portal vein and CBD appear normal. No e/o calculus is seen in bile duct.

GALL BLADDER:- Gall bladder is distended & appears normal. No evidence of calculus or cholecystitis is seen.

SPLEEN:- Spleen appears normal in size & shows normal echo texture. No evidence of diffuse or focal lesion is seen.

PANCREAS:- Pancreas appears normal size and echo pattern. No e/o diffuse or focal lesion is seen. Main pancreatic duct appears normal.

KIDNEY:- Both Kidneys appear normal in size & echo texture.

- No e/o calculus or hydronephrosis/ hydroureter is seen on both sides.

Cortico-medullary differentiation is maintained on both sides.

Both suprarenal regions appear normal.

No evidence of pre & para aortic lymphadenopathy is seen.

Both suprarenal regions appear normal.

No evidence of pre & para aortic lymphadenopathy is seen.

RIF & BOWEL LOOPS (By high frequency probe):-Normal.

No evidence of dilated or thickened bowel loops is seen.

No evidence of free fluid is seen in abdomen.

Urinary bladder:- appears normal. No e/o calculus or mass lesion is seen in bladder.

Prostate appears normal size and echopattern.

Thanks for reference.

Dr. Dinesh S. Modh

MD DMRE (Radiodiagnosis)

DR DINESH S. MODH

M.D. DMRE(RADIODIAGNOSIS)

ISO 9001:2015 Certified Diagnostics Center

Vidhi Imaging Center

L-86, Swatantra Senani Nagar, Opp. Indian Oil Petrol Pump, Akharnagar Circle, Nava Vadaj, Ahmedabad - 380 013.

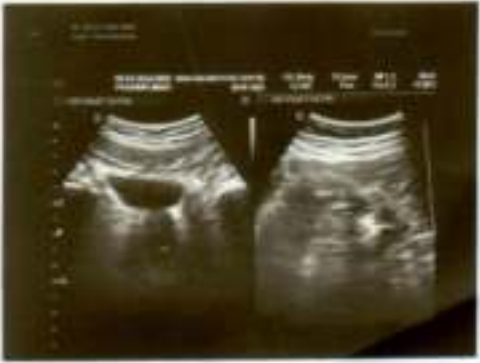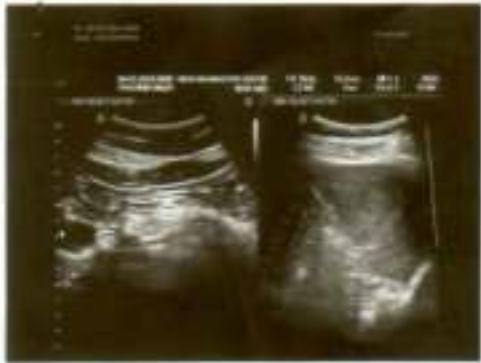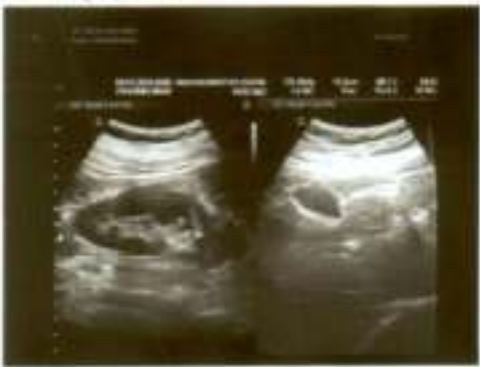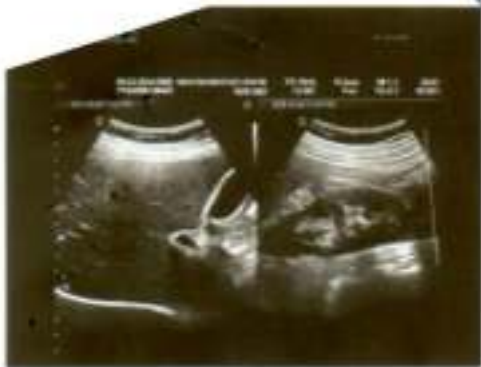Phone : (Radiology) 079-2762 1406 | M. 98799 29406, 98250 09406 | Time (Radiology) : Mon. to Sat. 9 am to 2 pm, 5 to 9 pm, Sunday 9 am to 12 Noon

E-mail : vidhidiagnostics@gmail.com, Website : www.vidhidiagnostics.com

Multislice CT Scan | CBCT-Dental Scan | Live 3D-4D Sonography | Colour Doppler | Echo Cardiography | Interventional Radiology | Maxillofacial Radiology | Fetal Medicine
Digital X-Ray | Digital Mammography | Digital OPG / TMJ | ECG / TMT / PFT / EEG / EMG | Audiometry | Pathology Laboratory | Health Check Up Plans | Pre Employment Check Up

CT SCAN & CBCT FACILITY NOW AVAILABLE

Posterior view of the heart



Dr. Dinesh S. Modh

M.D., D.M.R.E. (Radiodiagnosis)

Consultant Radiologist & Sonologist

Ex. Junior Lecturer, B.J. Medical College, Civil Hospital, A'bad.

VIDHI
DIAGNOSTICS



Patient's name: PRAVINKUMAR JHA

Reg. ID : R-14087-23

Referred by : MEDI WHEEL

Age/Sex : 49 Years/Male

Accession : 23586

Date : 08/03/2024

X-RAY CHEST (PA VIEW)

Both lung fields appear normal.
No e/o consolidation or cavitations is seen.
Both costo-phrenic angles appear clear.
Cardiac size is within normal limits.
Both domes of diaphragm appear normal.
Bony thoracic cage appears normal.

Thanks for reference.


Dr. Dinesh S. Modh
MD DMRE (Radiodiagnosis)
G-23825
DR DINESH S. MODH
M.D. DMRE(RADIODIAGNOSIS)

ISO 9001:2015 Certified Diagnostics Center

Vidhi Imaging Center

L-86, Swatantra Senani Nagar, Opp. Indian Oil Petrol Pump, Akhbaragar Circle, Nava Vadaj, Ahmedabad - 380 013.

Phone : (Radiology) 079-2762 1406 | M. 98799 29406, 98250 09406 | Time (Radiology) : Mon. to Sat. 9 am to 2 pm, 5 to 9 pm, Sunday 9 am to 12 Noon

E-mail : vidhidiagnostics@gmail.com, Website : www.vidhidiagnostics.com

Multislice CT Scan | CBCT-Dental Scan | Live 3D-4D Sonography | Colour Doppler | Echo Cardiography | Interventional Radiology | Maxillofacial Radiology | Fetal Medicine
Digital X-Ray | Digital Mammography | Digital OPG/TMJ | ECG/TMT/PFT/EEG/ENG | Audiometry | Pathology Laboratory | Health Check Up Plans | Pre Employment Check Up

CT SCAN & CBCT FACILITY NOW AVAILABLE