


MER- MEDICAL EXAMINATION REPORT

Date of Examination	13/11/2024		
NAME	MRS. AKANKSHA Singh		
AGE	36	Gender	female
HEIGHT(cm)	157 cm.	WEIGHT (kg)	67 kg
B.P.	120/70		
EKG	Normal		
X Ray	Normal		
Vision Checkup	-		
Present Ailments	-		
Details of Past ailments (If Any)	-		
Comments / Advice : She /He is Physically Fit	fit		
<p>BMI = 27.2 kg/m² (overweight)</p> <p>Sugar level high.</p>			

Signature with Stamp of Medical Examiner




Panel Medical Examiner
 Titrani Diagnostic & Research Centre
 Agrawal Plaza, B-7, H.I.G. Main Road,
 INDORE

Dr. Mukesh Dubey
 (MDS DCP)
 Registration No.-10632


 भारत सरकार
 Unique Identification Authority of India

पता: D/O राधे श्याम सिंह, वेस्टर्न रिंग रोड के पास, 173, ग्रेटर वैशाली, इंदौर, सुदामा नगर, मध्य प्रदेश, 452009	Address: D/O Radhe Shyam Singh, NEAR WESTERN RING ROAD, 173, GREATER VAISHALI, Indore, Sudama Nagar, Madhya Pradesh, 452009
--	--

5644 2028 3511

 1947	 help@uidai.gov.in	 www.uidai.gov.in
--	---	---


 भारत सरकार
 Government of India

	आकांक्षा सिंह Akanksha Singh जन्म तिथि / DOB : 07/03/1988 महिला / Female
---	---

5644 2028 3511

मेरा आधार, मेरी पहचान

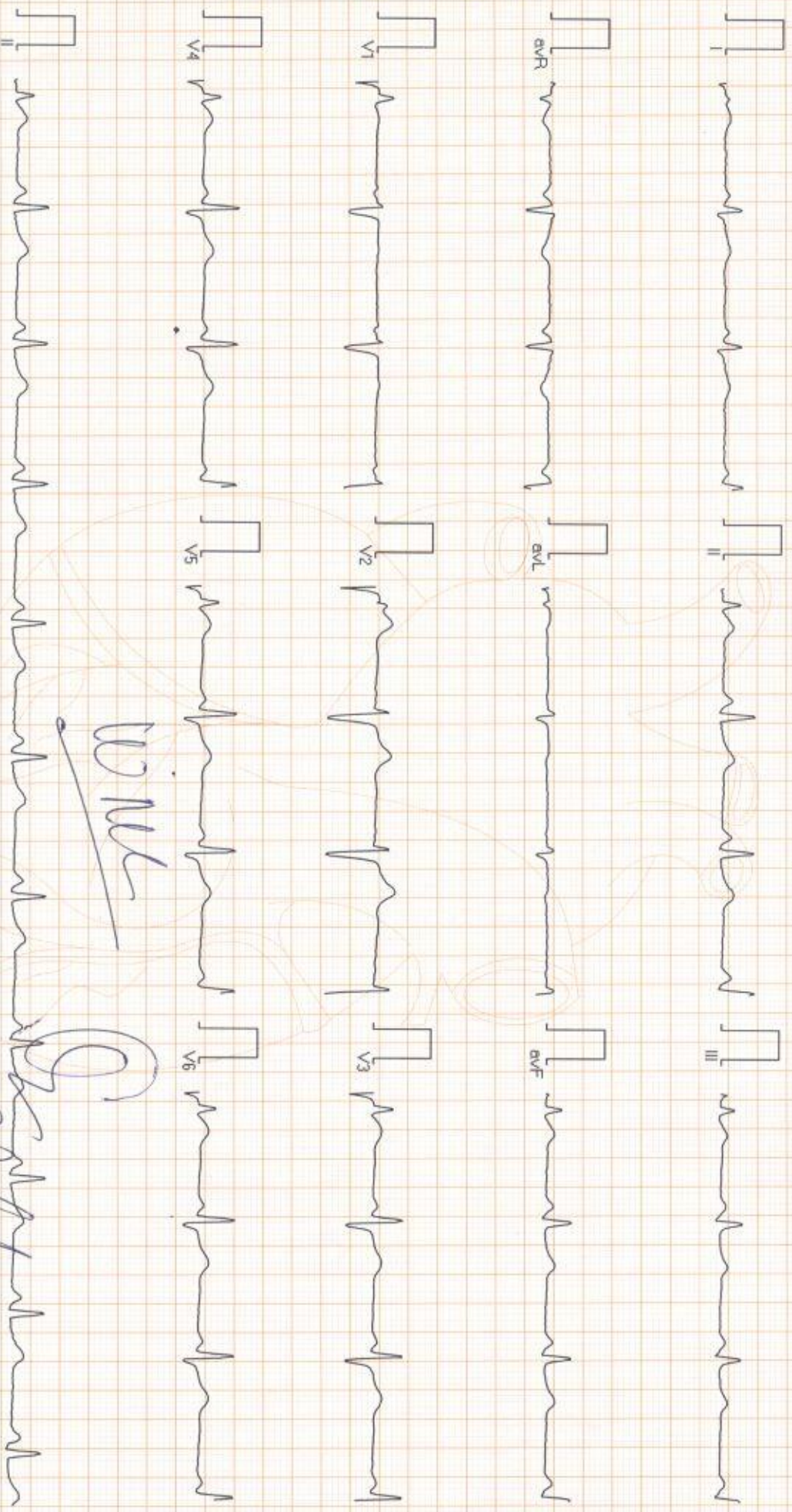
Panel Medical Examiner
 Trivani Diagnostic & Research Centre
 Agrawal Plaza, B-1, G. Indira Road,
 INDORE



TRIVENI DIAGNOSTIC AND RESEARCH CENTER INDORE

ECG

1359 / MRS AKANKASHA / 36 Yrs / F / Non Smoker
Heart Rate : 63 bpm / Tested On : 13-Nov-24 09:42:53 / HF 0.05 Hz - LF 20 Hz / Notch 50 Hz / Sn 1.00 Cm/mV / Sw 25 mm/s
/ Reifd By:..



Vent Rate : 63 bpm
PR Interval : 124 ms
QRS Duration: 106 ms
QT/QTc Int : 430/435 ms
P-QRS-T axis: 66.00 • 67.00 • 64.00 •

Panel Medical Examiner

Triveni Diagnostic & Research Centre
Agarwal Plaza, B-7, M.G. Road,
INDORE

[Handwritten Signature]

Reported By:



Triveni Diagnostic Centre

Reg No. : 98796 VISITID : O000103424
PATIENT NAME : MRS. AKANKSHA SINGH SPEC. NO : 1905433226
AGE/SEX : 36 YEARS/FEMALE SAMP. DATE : 13/11/2024 12:22:00
REF. BY : Dr. ARCOFEMI HEALTHCARE LIMITED RESULT DATE : 13/11/2024 14:02:16

HEMATOLOGY

CBC (COMPLETE BLOOD COUNT)

NAME OF TEST	RESULT VALUE	REFERENCE RANGE	UNIT
HAEMOGLOBIN	12	12.5 - 16	gm/dl
TOTAL RBC COUNT	4.2	4 - 6.5	mill/cummm
HAEMATOCRIT (PCV)	34.8	35.9 - 44.6	%
MEAN CORPUS VOL(MCV)	82.86	80 - 96	f l
MEAN CORPUS HB (MCH)	28.57	27.5 - 33.2	picograms
MEAN CORPUS HB CONC (MCHC)	34.48	33.4 - 35.5	%
RDW	12.8	11.5 - 15.5	%
PDW	15.5	-	f l
MPV	9.4	-	f l
PCT	0.21	-	%
P-LCR	32.7	-	%
TOTAL WBC	5600	4000 - 11000	/cummm
PLATELET COUNT	2.24	1.5 - 4.0	Lacs/cummm
DIFFERENTIAL COUNT			
NEUTROPHILS	63	40 - 70	%
LYMPHOCYTES	32	20 - 40	%
MONOCYTES	02	1 - 8	%
EOSINOPHILS	03	0 - 6	%
BASOPHILS	00	0 - 1	%
ABSOLUTE NEUTROPHILS	3528	4000 - 7500	/cummm
ABSOLUTE LYMPHOCYTES	1792	800 - 4950	/cummm
ABSOLUTE MONOCYTE	112	0 - 880	/cummm
ABSOLUTE EOSINOPHIL	168	40 - 400	/cummm
ABSOLUTE BASOPHIL	00	0 - 110	/cummm
ESR	10	0 - 20	mm at end of 1
MP (MALARIA PARASITE)	.	-	

METHOD:- By five part automated analyzer (sysmex XS1000 i) Japan

DR. MUKESH DUBEY
(MBBS. DCP) (DIRECTOR)

DR. VIJAY BHURIYA
MBBS DMRD

DR. YOGESH PAWDE
M. D. (CONS. PATHOLOGIST)

DR. P.S. TRIPATHI
M.D. (RADIO DIAGNOSIS)

DR. SANJAY YADAV
CON. MICROBIOLOGIST

Report Checked By:

Address : Agrawal Plaza, B-7, HIG Main Road, Indore Ph. : 0731-4289992-3
Website : www.trivenidiagnostic.com email : trivenidiagnostic@yahoo.co.in

Page 1 of 1




Triveni Diagnostic Centre

Reg No. : 98796 VISITID : 0000103424
PATIENT NAME : MRS. AKANKSHA SINGH SPEC. NO : 1905433222
AGE/SEX : 36 YEARS/FEMALE SAMP. DATE : 13/11/2024 12:22:00
REF. BY : Dr. ARCOFEMI HEALTHCARE LIMITED RESULT DATE : 13/11/2024 14:01:33

BIO-CHEMISTRY

RENAL PROFILE

NAME OF TEST	RESULT VALUE	REFERENCE RANGE	UNIT
UREA	23	10 - 40	mg / dl
CREATININE	0.78	0.6 - 1.2	mg / dl
SERUM SODIUM	148.2	135 - 155	mmol/L
SERUM POTASIUM	4.2	3.5 - 5.5	mmol/L



DR. MUKESH DUBEY
(MBBS, DCP) (DIRECTOR)

DR. VIJAY BHURIYA
MBBS DMRD

DR. YOGESH PAWDE
M. D. (CONS. PATHOLOGIST)

DR. P.S. TRIPATHI
M.D. (RADIO DIAGNOSIS)

DR. SANJAY YADAV
CON. MICROBIOLOGIST



Triveni Diagnostic Centre

Reg No. : 98796 VISITID : 0000103424
PATIENT NAME : MRS. AKANKSHA SINGH SPEC. NO : 1905433222
AGE/SEX : 36 YEARS/FEMALE SAMP. DATE : 13/11/2024 12:22:00
REF. BY : Dr. ARCOFEMI HEALTHCARE LIMITED RESULT DATE : 13/11/2024 14:03:26

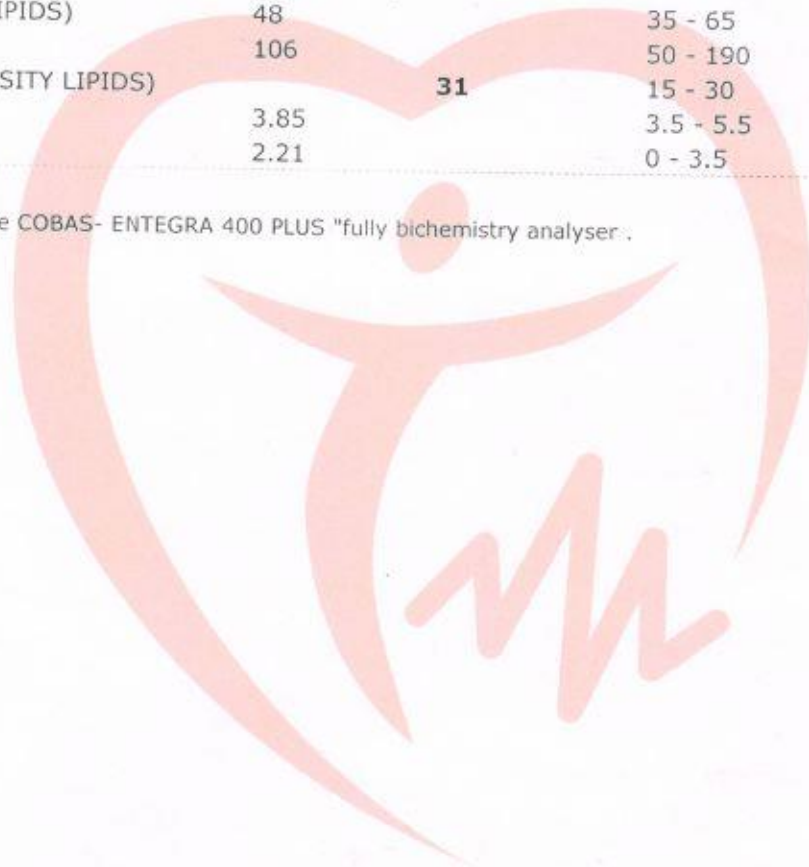
NAME OF TEST	RESULT VALUE		REFERENCE RANGE	UNIT
	IN RANGE	OUT RANGE		

LIPID PROFILE

CHOLESTEROL	185		0 - 200	mg / dl
TRIGLYCERIDES	155		50 - 190	mg / dl
HDL(HIGH DENSITY LIPIDS)	48		35 - 65	mg / dl
LDL	106		50 - 190	mg / dl
VLDL (VERY LOW DENSITY LIPIDS)		31	15 - 30	mg / dl
Cholestrol : HDL	3.85		3.5 - 5.5	
LDL : HDL	2.21		0 - 3.5	mg / dl

REMARKS :

Test done by -"Roche COBAS- ENTEGRA 400 PLUS "fully bichemistry analyser.:



DR. MUKESH DUBEY
(MBBS, DCP) (DIRECTOR)

DR. VIJAY BHURIYA
MBBS DMRD

DR. YOGESH PAWDE
M. D. (CONS. PATHOLOGIST)

DR. P.S. TRIPATHI
M.D. (RADIO DIAGNOSIS)

DR. SANJAY YADAV
CON. MICROBIOLOGIST

Report Checked By :

Address : Agrawal Plaza, B-7, HIG Main Road, Indore Ph. : 0731-4289992-3
Website : www.trivenidiagnostic.com email : trivenidiagnostic@yahoo.co.in



Triveni Diagnostic Centre

Reg No. : 98796 VISITID : 0000103424
PATIENT NAME : MRS. AKANKSHA SINGH SPEC. NO : 1905433222
AGE/SEX : 36 YEARS/FEMALE SAMP. DATE : 13/11/2024 12:22:00
REF. BY : Dr. ARCOFEMI HEALTHCARE LIMITED RESULT DATE : 13/11/2024 14:03:08

DEPARTMENT OF PATHOLOGY

NAME OF TEST	RESULT VALUE	REFERENCE RANGE	UNIT
FBS			
FBS	147	70 - 110	mg / dl

RESULT REMARKS : Test done by -"Roche COBAS- ENTEGRA 400 PLUS "fully bichemistry analyser .

HBA1 C (GLYCOSYLATED HEAMOGLOBIN)

HBA1 C (GLYCOSYLATED HEAMOGLOBIN)	6.8	Normal: 4-6 Good cntrol:6.1-7.0 Fair control :7.0-8.2 Unsatisfactory control: 8.0-10.2 Poor control: Above 10.0	%
-----------------------------------	-----	--	---

MEAN PLASMA GLUCOSE (MPG)	148	Exelent Control:90-120 Good Control:121-150 Avrege Control:151-180 Action Suggested:181-210 Panic value :>211	mg/dL
---------------------------	-----	---	-------

RESULT REMARKS : Test done by -"Roche COBAS- ENTEGRA 400 PLUS "fully bichemistry analyser .

METHOD BY: Turbidimetric inhibition immunoassay(TINIA)

Average blood glucose value is calculated from HBA1C value and indicates average blood sugar level over past three months.

PPBS

PPBS (POST PRANDIAL BLOOD SUGAR)	255	70 - 140	mg / dl
----------------------------------	-----	----------	---------

RESULT REMARKS : Test done by -"Roche COBAS- ENTEGRA 400 PLUS "fully bichemistry analyser .

Report Checked By :

Page 1 of 2



Triveni Diagnostic Centre

Reg No. : 98796 VISITID : 0000103424
PATIENT NAME : MRS. AKANKSHA SINGH SPEC. NO : 1905433222
AGE/SEX : 36 YEARS/FEMALE SAMP. DATE : 13/11/2024 12:22:00
REF. BY : Dr. ARCOFEMI HEALTHCARE LIMITED RESULT DATE : 13/11/2024 14:01:15

NAME OF TEST	RESULT VALUE		REFERENCE RANGE	UNIT
	IN RANGE	OUT RANGE		
LFT (LIVER FUNCTION TEST)				
TOTAL BILIRUBIN	0.60		0.2 - 1.3	mg/dL
DIRECT BILIRUBIN	0.34		0.2 - 0.65	mg / dl
INDIRECT BILIRUBIN	0.26		0.2 - 0.8	mg / dl
SGOT(AST)	25		0 - 40	U / L
SGPT(ALT)	30		0 - 40	U / L
ALKALINE PHOSPHATASE	101		37 - 143	U / L
PROTEINS	6.87		6 - 8.3	g / dl
ALBUMIN	4.12		3.5 - 5	gm/dl
GLOBULIN	2.75		1.9 - 3.5	g / dl
A.G.RATIO	1.49		0.5 - 2	mg / dl
PT (PROTHROMBIN TIME)		14	-	seconds
CONTROL		14	-	seconds
(INR) INTERNATIONALNARMLISED RATIO		1.0	-	seconds

REMARKS :

METHOD: BY COBAS INTEGRA 400 PLUS.

DR. MUKESH DUBEY
(MBBS, DCP) (DIRECTOR)

DR. VIJAY BHURIYA
MBBS DMRD

DR. YOGESH PAWDE
M. D. (CONS. PATHOLOGIST)

DR. P.S. TRIPATHI
M.D.(RADIO DIAGNOSIS)

DR. SANJAY YADAV
CON. MICROBIOLOGIST

Report Checked By :

Address : Agrawal Plaza, B-7, HIG Main Road, Indore, Ph : 0731 4280002



Triveni Diagnostic Centre

Reg No. : 98796 VISITID : 0000103424
PATIENT NAME : MRS. AKANKSHA SINGH SPEC. NO : 1905433222
AGE/SEX : 36 YEARS/FEMALE SAMP. DATE : 13/11/2024 12:22:00
REF. BY : Dr. ARCOFEMI HEALTHCARE LIMITED RESULT DATE : 13/11/2024 14:02:38

IMMUNO ASSAY

T3,T4 TSH

NAME OF TEST	RESULT VALUE	REFERENCE RANGE	UNIT
T3 (TRIIODOTHYRONINE)	1.01	Adults:- 0.60-1.58 Children:- 0-3 days:- 0.96- 2.92 1-11 months 0.81-2.81 1-5 years 0.83-2.52 6-10 years 0.92-2.19 11-15years 0.83-2.15	ng/ml
T4 (THYROXINE)	6.8	Adults:- 5.01-11.0 Children:- 0-3 days 11.80-22.60 4-30 days not Established 1-2 weeks 9.80-16.60 1-4 months 7.20-14.40 4-12 months 7.80-16.50	ug/dl
TSH (THYROID STIMULATING HORMONE)	2.71	Adults:- 0.38-4.31 Children:- 0-3 days:- 1.0-39.0 4-30 days:- 0.43-16.1 2-12 months:- 0.62-8.05 2-6 years:- 0.54-4.53 7-11 years:- 0.66-4.14 12-19 years:- 0.53-3.59	uIU/ml

Method: By AIA-360 (TOSOH) fully automated electro chemiluminescence immunoassay

INTERPRETATION: Suppressed TSH values are seen in hyperthyroid patients with the exception of hyperthyroidism caused by a TSH producing pituitary tumors. In addition TSH is suppressed in individuals treated with the exogenous thyroid hormones.

Elevated TSH values are seen in primary hypothyroidism with the exception of hypothyroidisms caused by pituitary disorders.

Note: Total T3 and T4 values may also be altered in other conditions due to changes in serum proteins or binding sites pregnancy, drugs (Androgens, Estrogen, O C pills, Phenyton) nephrosis etc. In such cases free T3 and T4 give corrected values.

DR. MUKESH DUBEY
(MBBS DCP) (DIRECTOR)

DR. VIJAY BHURIYA
MBBS DMRD

DR. YOGESH PAWDE
M. D. (CONS. PATHOLOGIST)

DR. P.S. TRIPATHI
M.D. (RADIO DIAGNOSIS)

DR. SANJAY YADAV
CON. MICROBIOLOGIST

Report Checked By:

Address : Agrawal Plaza, B-7, HIG Main Road, Indore Ph. : 0731-4289992-3

Page 1 of 1



Triveni Diagnostic Centre

Reg No. : 98796 VISITID : 0000103424
PATIENT NAME : MRS. AKANKSHA SINGH SPEC. NO : 1905433223
AGE/SEX : 36 YEARS/FEMALE SAMP. DATE : 13/11/2024 12:22:00
REF. BY : Dr. ARCOFEMI HEALTHCARE LIMITED RESULT DATE : 13/11/2024 14:01:51

CLINICAL-PATHOLOGY

URINE EXAMINATION

NAME OF TEST	RESULT VALUE	REFERENCE RANGE	UNIT
PHYSICAL EXAMINATION			
QUANTITY	20	-	ml
COLOUR	Pale Yellow	-	
APPEARANCE	Clear	-	
REACTION	Acidic	-	
Specific Gravity	1.010	-	
CHEMICAL EXAMINATION			
ALBUMIN	Nil	-	
URINE SUGAR	Nil	-	
Ketone Bodies	Nil	-	
BLOOD	Nil	-	
Bile Pigment	Nil	-	
Bile Salts	Nil	-	
MICROSCOPIC EXAMINATION			
Pus Cells	3-4 /HPF	2 - 5	/hpf
Epithelial Cells	2-3 /HPF	5 - 10	/hpf
RBCs	Nil	-	
Casts	Nil	-	/hpf
Crystals	Nil	-	
Spermatozoa	Nil	-	
Bacteria	Nil	-	
Others		-	

DR. MUKESH DUBEY
(MBBS DCP) (DIRECTOR)

DR. VIJAY BHURIYA
MBBS DMRD

DR. YOGESH PAWDE
M. D. (CONS. PATHOLOGIST)

DR. P.S. TRIPATHI
M.D. (RADIO DIAGNOSIS)

DR. SANJAY YADAV
CON. MICROBIOLOGIST

Report Checked By:



Triveni Diagnostic Centre

Reg. No. : 98796 Visit ID : O000103424
Patient Name : MRS. AKANKSHA SINGH
Age / Sex : 36 YEARS / FEMALE Order Date : 13/11/24 11:55AM
Ref. By : Dr. ARCOFEMI HEALTHCARE LIMITED Report Date : 13/11/24 12:18PM

X-RAY X-RAY CHEST PA

Trachea is central.


Bony rib cage and soft tissue wall of the thorax are normal.

Cardiac size is within normal limits.


Both lungs fields are clear. No pulmonary parenchymal lesion is seen.

Costo-phrenic angles are clear.

Kindly correlate.



DR. MUKESH DUBEY
(MBBS, DCP)


DR. VIJAY BHURIYA
MBBS DMRD

DR. AMIT SHANKHWAR
M.D. RADIO DIAGNOSIS

DR. P.S. TRIPATHI
M.D. (RADIO DIAGNOSIS)

DR. SANJAY YADAV
CONSULTANT MICROBIOLOGIST



Triveni Diagnostic Centre

Reg. No. : 98796 Visit ID : 000103424
Patient Name : MRS. AKANKSHA SINGH
Age / Sex : 36 YEARS / FEMALE Order Date : 13/11/24 11:55AM
Ref. By : Dr. ARCOFEMI HEALTHCARE LIMITED Report Date : 13/11/24 12:40PM

SONOGRAPHY

USG WHOLE ABDOMEN(FEMALE)

Liver is normal in size 11.9cm with smooth contour and **Focal fatty infiltration seen in the right lobe of liver**. Intra hepatic biliary radicals are not dilated. Portal & splenic veins are normal in caliber.

Gall bladder is normal in size with thin walls & lumen is free from calculi/polyp. CHD & CBD are not dilated.

Pancreas is normal shaped with homogenous echotexture.

Spleen is normal in size 9.1cm and echotexture.

Kidneys are normal in size (Rt 9.8 X 4.5 Lt.10.4 X 4.3 cms), contour, position and show normal cortical echogenicity & CMJ. No evidence of calculus or calcification on either sides. Pelvicalyceal systems & ureters are undilated.

No abdominal/ pelvic lymphadenopathy is seen.

Urinary bladder is adequately filled with anechoic contents.

Mucosa is smooth and wall thickness measures normal.

Uterus is normal in size, contour & antverted.

Endometrium is homogenous in echostructure.

Endometrial echo is central. Cervix appears to be normal.

Uterus Size 7.5 x 2.7 x 4.7 cm.

Endometrium is 6.9mm.

Ovaries are normal.

IMPRESSION:-Focal fatty liver.

Kindly correlate.

DR. MUKESH DUBEY
(MBBS, DCP)

DR. VIJAY BHURIYA
MBBS DMRD

DR. AMIT SHANKHWAR
M.D. RADIO DIAGNOSIS

DR. P.S. TRIPATHI
M.D. (RADIO DIAGNOSIS)

DR. SANJAY YADAV
CONSULTANT MICROBIOLOGIST