


MER- MEDICAL EXAMINATION REPORT

| | | | |
|---|--------------------|-------------|---------------|
| Date of Examination | 09/11/24 | | |
| NAME | MANSRAT SRIVASTAVA | | |
| AGE | 30 | Gender | M |
| HEIGHT(cm) | 176 | WEIGHT (kg) | 93 BMB - 31.0 |
| B.P. | 110/70 | | |
| ECG | normal | | |
| X Ray | normal | | |
| Vision Checkup | normal | | |
| Present Ailments | None | | |
| Details of Past ailments (If Any) | No | | |
| Comments / Advice : She /He is Physically Fit | MEDICALLY FIT | | |




 Dr. Smriti Rastogi
 M.D. DCP
 Reg. No. 37370
 Signature with Stamp of Medical Examiner

You have been informed that dental, dietician, ENT consultations is not available at our centre. if you are ready than test can be start .

2D echo test facility is not available at our centre, instead we do TMT **test**.

If you are ready then your test can be start.



Handwritten signature in blue ink, appearing to read "Hany" above a horizontal line, with "shih" written below it.

भारत सरकार
Government of India

हंसराज श्रीवास्तव
Hansraj Shrivastava
जन्म तिथि / DOB : 23/11/1993
पुरुष / MALE

4667 4507 2122

मेरा आधार, मेरी पहचान



भारतीय विशिष्ट पहचान प्राधिकरण
Unique Identification Authority of India

पता: S/O सुदेश कुमार श्रीवास्तव, निकट कैसर बाग बस स्टैंड, म.नं. 172/248 सुशीला सदन, बाजार झाऊ लाल, अमीनाबाद पार्क एस.ओ, लखनऊ, उत्तर प्रदेश, 226018
Address: S/O Sudesh Kumar Srivastava, NEAR KAISER BAGH BUS STAND, H.NO. 172/248 SUSHEELA SADAN, BAZAR JHAU LAL, Aminabad Park S.O, Lucknow, Uttar Pradesh, 226018

4667 4507 2122

1947 help@uidai.gov.in www.uidai.gov.in

Hansraj
09/11/2014

ECG

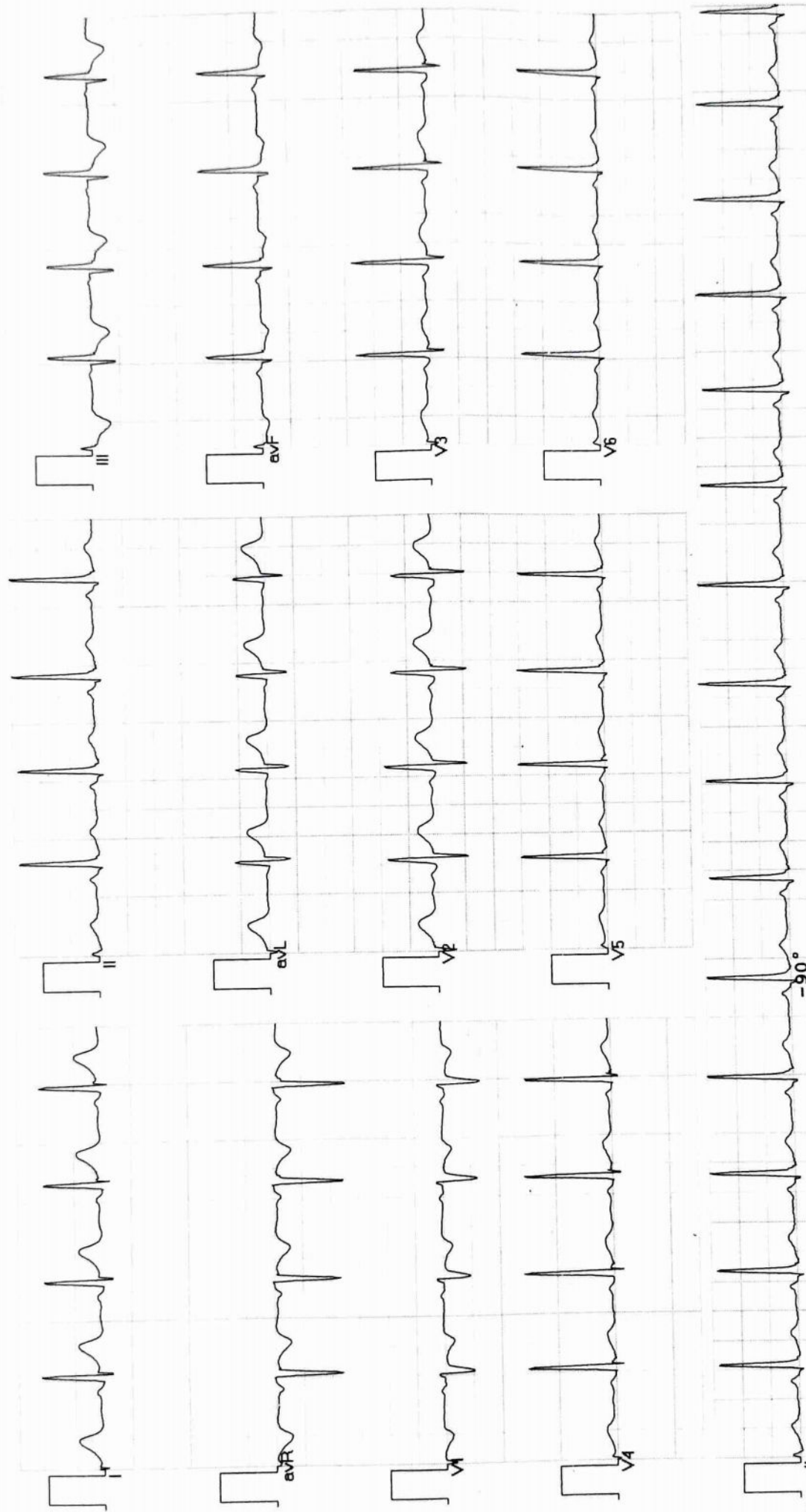


Modern Pathology And Diagnostic Centre

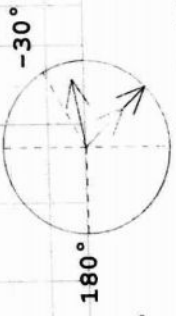
336 / HANSRAJ SRIVASTAVA / 31 Yrs / M / 176Cms. / 93Kgs. / Non Smoker

Heart Rate : 90 bpm / Tested On : 09-Nov-24 10:51:12 / HF 0.05 Hz - LF 100 Hz / Notch 50 Hz / Sn 1.00 Cm/mV / Sw 25 mm/s

/ Refd By.: APOLLO HEALTH



Vent Rate : 90 bpm
PR Interval : 96 ms
QRS Duration: 80 ms
QT/QTc Int : 330/381 ms
P-QRS-T axis: 46.00° 46.00° -11.00°



Allergens ECG (Pisces)(PIS215191030)

Normal ECG

[Signature]

Dr. AMIT MOHAN
MD
Reg. No. 4459



MODERN PATHOLOGY & DIAGNOSTIC CENTRE

DIAGNOSTIC CENTRE

Dr. R. P. Rastogi
M.B.B.S., M.D. (Path & Bact)



CLINIC :

1/4A, Vineet Khand, (Opp Jaipuria Management)
Gomti Nagar, Lucknow - 226 010
Ph.: 0522-4008184, 4308184 • 8112323230
Mob.: 7618884441, 9450389932, 8177063877

| | | | |
|--------|---------------------------------|-----|-----------|
| Date | : 09-Nov-2024 | | |
| Name | : Mr. HANSRAJ SRIVASTAVA | Age | : 30 Yrs. |
| Ref.By | : APOLLO HEALTH | Sex | : Male |

| | | | |
|--------------------------------------|----|-------|----------|
| Plasma Glucose - F GOD-POD Method | 92 | mg/dl | 70 - 110 |
|--------------------------------------|----|-------|----------|

| | | | |
|---------------------------------------|-----|-------|-----------|
| Plasma Glucose - PP GOD POD Method | 127 | mg/dl | 110 - 170 |
|---------------------------------------|-----|-------|-----------|

| | | | |
|------------------|--------------|--|--|
| Blood Group & Rh | "B" Positive | | |
|------------------|--------------|--|--|

| | | | |
|------------|------|------|------------|
| KFT | | | |
| UREA | 21.6 | mg % | 15 - 50 |
| CREATININE | 0.88 | mg % | 0.5 - 1.5 |
| URIC ACID | 5.1 | mg % | 2 - 7 |
| CALCIUM | 9.8 | mg % | 8.8 - 10.0 |

| | | | |
|--------------------|------------|------|--------------|
| LFT T&D | | | |
| Total Bilirubin | 0.60 | mg% | 0.2 - 1.0 |
| Direct Bilirubin | 0.19 | mg% | 0.0 to 0.40 |
| Indirect Bilirubin | 0.41 | mg% | 0.10 to 0.90 |
| S.G.P.T | 112 | IU/L | 5 - 40 |
| S.G.O.T | 96 | IU/L | 5 - 50 |
| ALP | 82 | IU/L | 40 to 129 |

| | | | |
|------------------|----|------|---------|
| Serum Gamma G.T. | 29 | IU/L | 11 - 50 |
|------------------|----|------|---------|

| | | | |
|-----------------------|-----|--|--|
| Urine Sugar (Fasting) | NIL | | |
|-----------------------|-----|--|--|

| | | | |
|------------------|-----|--|--|
| Urine Sugar (PP) | NIL | | |
|------------------|-----|--|--|

Dr. Sanjay Rastogi
M.B.B.S., DCP, CRIAT (BARC)

Dr. Smita Rastogi
Contd... M.B.B.S., DCP

Results, adhering to W.H.O. and International Federation of Clinical Chemists Quality Control Standards.

SAMPLE COLLECTION FACILITY AVAILABLE

Report needs clinicopathological correlation ♦ Not for Medico Legal Purpose

e-mail : mpdcgn@gmail.com ♦ For online reports - www.modernpath.in

♦ Please ask for your computerized bill ♦ Pay only the printed collection charges

CLINIC :

1/4A, Vineet Khand, (Opp Jaipuria Management)
Gomti Nagar, Lucknow - 226 010
Ph.: 0522-4008184, 4308184 • 8112323230
Mob.: 7618884441, 9450389932, 8177063877

| | | | |
|--------|---------------------------------|-----|-----------|
| Date | : 09-Nov-2024 | | |
| Name | : Mr. HANSRAJ SRIVASTAVA | Age | : 30 Yrs. |
| Ref.By | : APOLLO HEALTH | Sex | : Male |

THYROID TEST

| | | | |
|-----------------------------------|------|---------|--------------|
| Tri-iodothyronine (T3) | 1.80 | nmol/L | 0.50 to 2.50 |
| Thyroxine (T4) | 6.91 | mcg/dL | 5.0 to 12.5 |
| Thyroid Stimulating Hormone (TSH) | 3.12 | mIU/ ml | 0.3 to 6.0 |

=====

COMMENTS

=====

- 1) Primary hyperthyroidism is accompanied by elevated Serum T3 and T4 values along with depressed TSH levels.
- 2) Primary Hypothyroidism is accompanied by depressed serum T3 and T4 values and elevated serum TSH levels.
- 3) Normal T4 levels accompanied by high T3 levels are seen in patients with T3 thyrotoxicosis.
- 4) Slightly elevated T3 levels may be found in pregnancy and estrogen therapy, while depressed levels maybe encountered in severe illness, malnutrition, renal failure and during therapy with drugs like propranolol and propylthiouracil.
- 5) Elevated TSH levels may also be indicative of TSH secreting Pituitary Tumour.

Dr. Sanjay Rastogi
M.B.B.S., DCP, CRIAT (BARC)

Dr. Smita Rastogi
Contd... M.B.B.S., DCP

Results, adhering to W.H.O. and International Federation of Clinical Chemists Quality Control Standards.
SAMPLE COLLECTION FACILITY AVAILABLE

Report needs clinicopathological correlation ♦ Not for Medico Legal Purpose

e-mail : mpdcgn@gmail.com ♦ For online reports - www.modernpath.in

♦ Please ask for your computerized bill ♦ Pay only the printed collection charges

CLINIC :

1/4A, Vineet Khand, (Opp Jaipuria Management)
Gomti Nagar, Lucknow - 226 010
Ph.: 0522-4008184, 4308184 • 8112323230
Mob.: 7618884441, 9450389932, 8177063877

Date : 09-Nov-2024

Name : **Mr. HANSRAJ SRIVASTAVA**

Age : 30 Yrs.

Ref.By : APOLLO HEALTH

Sex : Male

LIPID PROFILE

| | | | |
|-------------------|-------|-----|-----------|
| Triglycerids | 172 | mg% | 70 - 190 |
| S. Cholestrol S. | 263 | mg% | 130 - 230 |
| S. HDL Cholestrol | 46.4 | mg% | 35 - 75 |
| S. LDL Cholestrol | 182.2 | mg% | 75 - 150 |
| VLDL | 34.4 | mg% | 0 - 34 |
| Chol / HDL factor | 5.67 | | |
| LDL / HDL Factor | 3.93 | | |

COMMENTS

- * Triglycerides (TG) are the main dietary lipids. Cholesterol constitutes a small part of the dietary lipids, it is mostly synthesised in the liver. Both TG and Chol. are transported through the plasma by lipoproteins (Chylomicrons, VLDL, LDL, IDL, HDL).
- * LDL is the major cholesterol particle in plasma and high levels are strongly implicated in the formation of atheroma. An increase in the LDL leads to hypercholesterolemia, and therefore a risk factor for IHD. LDL increases with age particularly in females. Oestrogen lowers LDL and raises HDL. Raised chol. in females is mostly due to disturbed thyroid function.
- * Increase in VLDL leads to hyperglyceridaemia. Raised TGs are associated with increased risk of CHD. Very high TGs increase the risk of Pancreatitis. Cholesterol is often raised due to Diabetes, Renal disease, Diuretic or Beta-blocker therapy.

TYPES OF HYPERLIPOPROTEINEMIAS

| | |
|---|--|
| TYPE 1: Normal cholesterol TG greatly raised | TYPE 3: Cholesterol increased TG increased |
| TYPE 2a: Cholesterol increased LDL increased TG normal | TYPE 4: Cholesterol normal /increased VLDL increased TG increased |
| TYPE 2b Chol. increased VLDL raised TG increased LDL increased | TYPE 5: Cholesterol increased LDL reduced VLDL increased TG greatly increased |

Dr. Sanjay Rastogi
M.B.B.S., DCP, CRIAT (BARC)

Dr. Smita Rastogi
Contd... M.B.B.S., DCP

Results, adhering to W.H.O. and International Federation of Clinical Chemists Quality Control Standards.

SAMPLE COLLECTION FACILITY AVAILABLE

Report needs clinicopathological correlation ♦ Not for Medico Legal Purpose

e-mail : mpdcgn@gmail.com ♦ For online reports - www.modernpath.in

♦ Please ask for your computerized bill ♦ Pay only the printed collection charges



MODERN PATHOLOGY & DIAGNOSTIC CENTRE

DIAGNOSTIC CENTRE

Dr. R. P. Rastogi
M.B.B.S., M.D. (Path & Bact)



CLINIC :

1/4A, Vineet Khand, (Opp Jaipuria Management)
Gomti Nagar, Lucknow - 226 010
Ph.: 0522-4008184, 4308184 • 8112323230
Mob.: 7618884441, 9450389932, 8177063877

| | | | |
|--------|---------------------------------|-----|-----------|
| Date | : 09-Nov-2024 | Age | : 30 Yrs. |
| Name | : Mr. HANSRAJ SRIVASTAVA | Sex | : Male |
| Ref.By | : APOLLO HEALTH | | |

Glycosylated Haemoglobin

| | | | |
|---------------------------------|-----|---|------------|
| Glycosylated Haemoglobin | 5.4 | % | 4.5 TO 6.0 |
|---------------------------------|-----|---|------------|


=====

INTERPRETATION AND COMMENTS

=====

- NON DIABETIC : 4.5 to 6.0 %
- GOOD CONTROL: 6.0 to 7.0
- FAIR CONTROLLED 7.0 AND 8.0
- UNCONTROLLED 8.0 AND ABOVE

Glycosylated haemoglobin is the adducted glucose in the haemoglobin of the red blood cells, this adduction is stable for the life time of the RBC (i.e 120 days). There fore the measure of glycosylated haemoglobin reflects the average blood glucose concentration over the preseding several weeks. The sudden change in blood glucose level would not effect the glycosylated haemoglobin level ,which serves as a better marker of long term metabolic control and the efficacy of therapy.



Dr. Sanjay Rastogi
M.B.B.S., DCP, CRIAT (BARC)

Dr. Smita Rastogi
Contd... M.B.B.S., DCP

Results, adhering to W.H.O. and International Federation of Clinical Chemists Quality Control Standards.

SAMPLE COLLECTION FACILITY AVAILABLE

Report needs clinicopathological correlation ♦ Not for Medico Legal Purpose

e-mail : mpdcgn@gmail.com ♦ For online reports - www.modernpath.in

♦ Please ask for your computerized bill ♦ Pay only the printed collection charges



MODERN PATHOLOGY & DIAGNOSTIC CENTRE

DIAGNOSTIC CENTRE

Dr. R. P. Rastogi
M.B.B.S., M.D. (Path & Bact)



CLINIC :

1/4A, Vineet Khand, (Opp Jaipuria Management)
Gomti Nagar, Lucknow - 226 010
Ph.: 0522-4008184, 4308184 • 8112323230
Mob.: 7618884441, 9450389932, 8177063877

| | | | |
|--------|---------------------------------|-----|-----------|
| Date | : 09-Nov-2024 | | |
| Name | : Mr. HANSRAJ SRIVASTAVA | Age | : 30 Yrs. |
| Ref.By | : APOLLO HEALTH | Sex | : Male |

Urine Examination

| | | | |
|--------------------|--------|------|--|
| PHYSICAL | | | |
| Colour | Straw | | |
| Turbidity | Nil | | |
| Deposit | Nil | | |
| Reaction | Acidic | | |
| *Specific Gravity | 1.010 | | |
| CHEMICAL | | | |
| Protein | Nil | | |
| Sugar | Nil | | |
| *Bile Salts | Nil | | |
| *Bile Pigments | Nil | | |
| Phosphate | Nil | | |
| MICROSCOPIC | | | |
| Pus Cells | Nil | /hpf | |
| Epithelial Cells | 0-1 | /hpf | |
| Red Blood Cells | Nil | /hpf | |
| Casts | Nil | | |
| Crystals | Nil | | |
| Others | Nil | | |

Dr. Sanjay Rastogi
Page 5 (End Of Report)
M.B.B.S., DCP, CRIAT (BARC)

Dr. Smita Rastogi
M.B.B.S., DCP

Results, adhering to W.H.O. and International Federation of Clinical Chemists Quality Control Standards.

SAMPLE COLLECTION FACILITY AVAILABLE

Report needs clinicopathological correlation ♦ Not for Medico Legal Purpose

e-mail : mpdcgn@gmail.com ♦ For online reports - www.modernpath.in

♦ Please ask for your computerized bill ♦ Pay only the printed collection charges



MODERN PATHOLOGY & DIAGNOSTIC CENTRE

DIAGNOSTIC CENTRE

Dr. R. P. Rastogi
M.B.B.S., M.D. (Path & Bact)

CLINIC :

1/4A, Vineet Khand, (Opp Jaipuria Management)
Gomti Nagar, Lucknow - 226 010
Ph.: 0522-4008184, 4308184 • 8112323230
Mob.: 7618884441, 9450389932, 8177063877



Date : 09-Nov-2024

Name : **Mr. HANSRAJ SRIVASTAVA**

Age : 30 Yrs.

Ref.By : APOLLO HEALTH

Sex : Male

General Blood Picture

RBCs RBCs are Normocytic & Normochromic.
No Normoblasts are seen.

WBCs TLC is within normal range.
DLC shows eosinophils are increased.
No immature cells of WBC seen.

PLATELETS Platelets are adequate in number and morphology.

OTHERS No haemoparasites are seen.

IMPRESSION MILD EOSINOPHILIA

DIAGNOSTIC CENTRE

Dr. Sanjay Rastogi
M.B.B.S., DCP, CRP (BARC)

Dr. Smita Rastogi
M.B.B.S., DCP

Results, adhering to W.H.O. and International Federation of Clinical Chemists Quality Control Standards.

SAMPLE COLLECTION FACILITY AVAILABLE

Report needs clinicopathological correlation ♦ Not for Medico Legal Purpose

e-mail : mpdcgn@gmail.com ♦ For online reports - www.modernpath.in

♦ Please ask for your computerized bill ♦ Pay only the printed collection charges



MODERN PATHOLOGY & DIAGNOSTIC CENTRE

DIAGNOSTIC CENTRE

Dr. R. P. Rastogi
M.B.B.S., M.D. (Path & Bact)



CLINIC :

1/4A, Vineet Khand, (Opp Jaipuria Management)
Gomti Nagar, Lucknow - 226 010
Ph.: 0522-4008184, 4308184 • 8112323230
Mob.: 7618884441, 9450389932, 8177063877

| | | | |
|--------|---------------------------------|-----|-----------|
| Date | : 09-Nov-2024 | | |
| Name | : Mr. HANSRAJ SRIVASTAVA | Age | : 30 Yrs. |
| Ref.By | : APOLLO HEALTH | Sex | : Male |

| | | | |
|-------------|------|-----|---------|
| Haemoglobin | 14.3 | gm% | 14 - 17 |
|-------------|------|-----|---------|

| | | | |
|-----------------------|------|-------------|------------|
| Total Leucocyte Count | 5600 | Cells/cumm. | 4000-11000 |
|-----------------------|------|-------------|------------|

| Differential Leucocyte Count | | | |
|------------------------------|-----------|---|---------|
| Polymorphs | 55 | % | 45 - 70 |
| Lymphocytes | 30 | % | 20 - 45 |
| Eosinophils | 08 | % | 0 - 6 |
| Monocytes | 07 | % | 0 - 8 |
| Basophils | 00 | % | 0 - 1 |

| Erythrocyte Sedimentation Rate (Wintrobe) | | | |
|---|------|---------------|---------|
| ESR | 08 | mm in 1st Hr. | 0 - 9 |
| PCV | 44.9 | cc% | 40 - 52 |
| Corrected ESR | 02 | mm in 1st Hr. | 0 - 9 |

| | | | |
|----------------|------|------------|-----------|
| Platelet Count | 1.87 | lakh/cumm. | 1.5 - 4.0 |
|----------------|------|------------|-----------|

| | | | |
|-----------------|------|-------------|--------------|
| Red Cells Count | 4.94 | million/cmm | 3.90 to 5.80 |
|-----------------|------|-------------|--------------|

| Absolute values | | | |
|-----------------|------|--------|---------|
| MCV | 90.9 | fL | 77 - 97 |
| MCH | 28.9 | pg | 27 - 31 |
| MCHC | 31.8 | gm /dl | 31 - 34 |

Dr. Sanjay Rastogi
M.B.B.S., DCP, CRIAT (BARC)

Dr. Smita Rastogi
M.B.B.S., DCP

Results, adhering to W.H.O. and International Federation of Clinical Chemists Quality Control Standards.
SAMPLE COLLECTION FACILITY AVAILABLE

Report needs clinicopathological correlation ♦ Not for Medico Legal Purpose

e-mail : mpdcgn@gmail.com ♦ For online reports - www.modernpath.in

♦ Please ask for your computerized bill ♦ Pay only the printed collection charges



MODERN PATHOLOGY & DIAGNOSTIC CENTRE

DIAGNOSTIC CENTRE
CLINIC :
1/4A, Vineet Khand, (Opp Jaipuria Management)
Gomti Nagar, Lucknow - 226 010
Ph.: 0522-4008184, 4308184 • 8112323200
Mob.: 7618884441, 9450389932, 8177063877

Dr. R. P. Rastogi
M.B.B.S., M.D. (Path & Bact)



| | | |
|--|------------------|----------------------|
| TEST REQUEST ID :012411090032 | SAMPLE DATE | :09/Nov/2024 10:12AM |
| NAME :Mr. HANSRAJ SRIVASTAVA | SAMPLE REC. DATE | :09/Nov/2024 10:12AM |
| AGE/SEX :30 YRS/MALE | REPORTED DATE | :09/Nov/2024 11:33AM |
| REFERRED BY : Apollo Health and Lifestyle Limited, | BARCODE NO | :01090032 |

USG WHOLE ABDOMEN-MALE

Liver: is enlarged in size (153 mm). Parenchymal echogenicity is increased. No focal echovariant lesion is seen. Intrahepatic biliary radicles are not dilated.

Gall Bladder: is well distended. Lumen is anechoic. Wall is of normal thickness.

CBD: is normal in diameter 3.7 mm. Portal vein is normal in diameter.

Pancreas: is normal in size, shape and echotexture. No focal echovariant lesion is seen. Pancreatic duct is not dilated.

Spleen: is normal in size (118 mm), shape and echotexture. No focal echovariant lesion is seen. Splenic vein is normal.

Right Kidney: is normal in size 105 mm, shape, position and excursion. Parenchymal echogenicity and echotexture is normal with maintained corticomedullary differentiation. No mass, cyst, or calculi is seen. Pelvicalyceal system is not dilated. Ureter is not dilated.

Left Kidney: is normal in size 104 mm, shape, position and excursion. Parenchymal echogenicity and echotexture is normal with maintained corticomedullary differentiation. No mass, cyst, or calculi is seen. Pelvicalyceal system is not dilated. Ureter is not dilated.



Pankaj Rastogi
M.B.B.S., DCP, CRIAT (BARC)

DR. PANKAJ UPADHYAYA
Consultant Radiologist

Dr. Smita Rastogi
M.B.B.S., DCP

Results, adhering to W.H.O. and International Federation of Clinical Chemists Quality Control Standards.
SAMPLE COLLECTION FACILITY AVAILABLE

Report needs clinicopathological correlation ♦ Not for Medico Legal Purpose

e-mail : mpdcgn@gmail.com ♦ For online reports - www.modernpath.in

♦ Please ask for your computerized bill ♦ Pay only the printed collection charges



MODERN PATHOLOGY & DIAGNOSTIC CENTRE

Dr. R. P. Rastogi
M.B.B.S., M.D. (Path & Bact)



CLINIC :
1/4A, Vineet Khand, (Opp Jaipuria Management)
Gomti Nagar, Lucknow - 226 010
Ph.: 0522-4008184, 4308184 • 8112323230
Mob.: 7618884441, 9450389932, 817706887

| | | | |
|-----------------|--|------------------|----------------------|
| TEST REQUEST ID | :012411090032 | SAMPLE DATE | :09/Nov/2024 10:12AM |
| NAME | :Mr. HANSRAJ SRIVASTAVA | SAMPLE REC. DATE | :09/Nov/2024 10:12AM |
| AGE/SEX | :30 YRS/MALE | REPORTED DATE | :09/Nov/2024 11:33AM |
| REFERRED BY | : Apollo Health and Lifestyle Limited, | BARCODE NO | :01090032 |

Urinary bladder: is well distended. Lumen is anechoic. Wall is of normal thickness. No mass or calculus is seen.

Prostate: is normal in size (27x28x34 mms, wt = 14.3 gms), shape and echotexture. No focal echovariant lesion is seen. Prostatic capsule appears to be intact. Median lobe is not projecting in UB lumen. Both seminal vesicles appear normal.

Both iliac fossae are clear. No obvious bowel pathology is noted. There is no free fluid in peritoneal cavity.

OPINION:

- HEPATOMEGALY WITH FATTY LIVER GRADE -I.

*** End Of Report ***



Sanjay Rastogi
M.B.B.S., DCP, CRIAT (BARC)

DR. PANKAJ UPADHYAYA
Consultant Radiologist

Dr. Smita Rastogi
M.B.B.S., DCP

Results, adhering to W.H.O. and International Federation of Clinical Chemists Quality Control Standards.

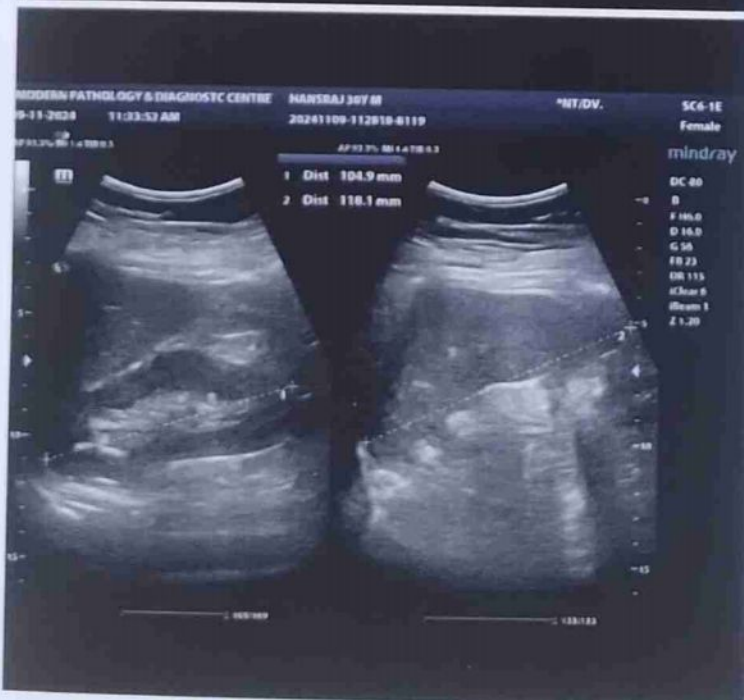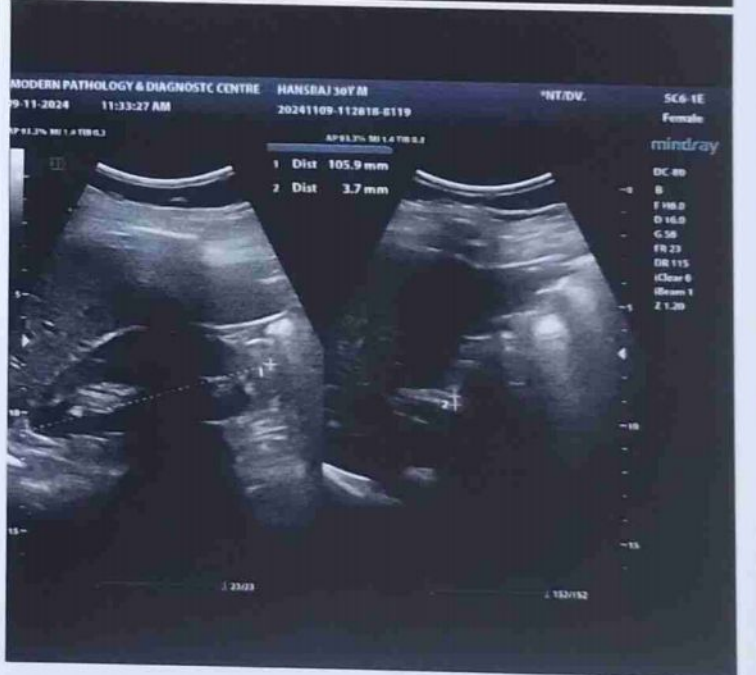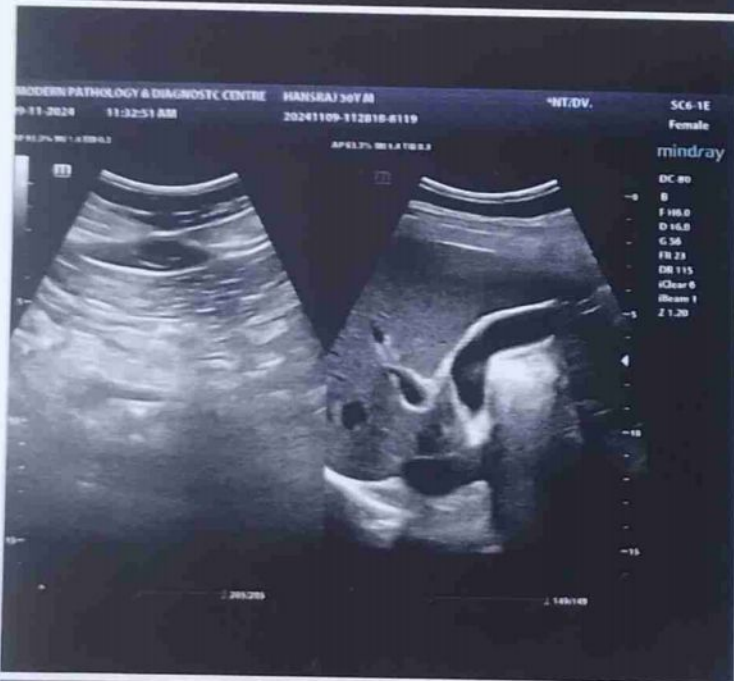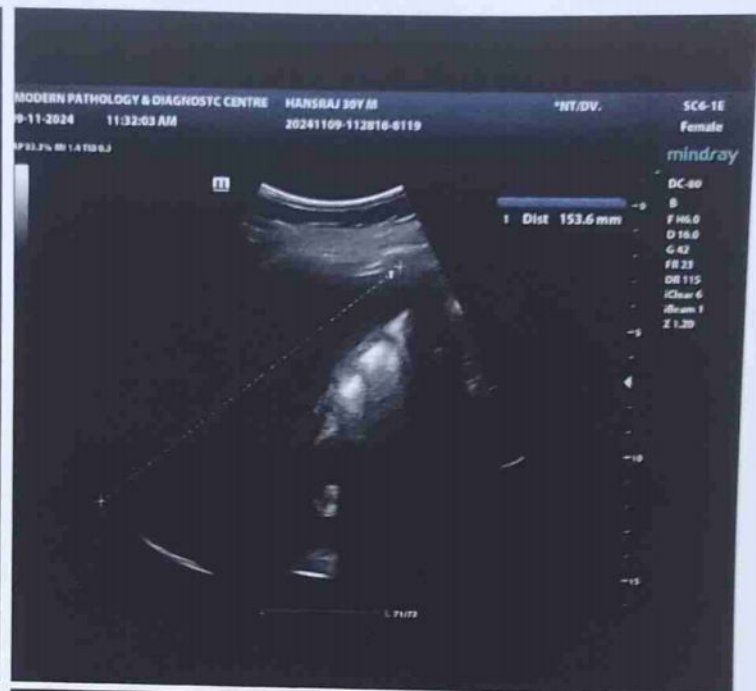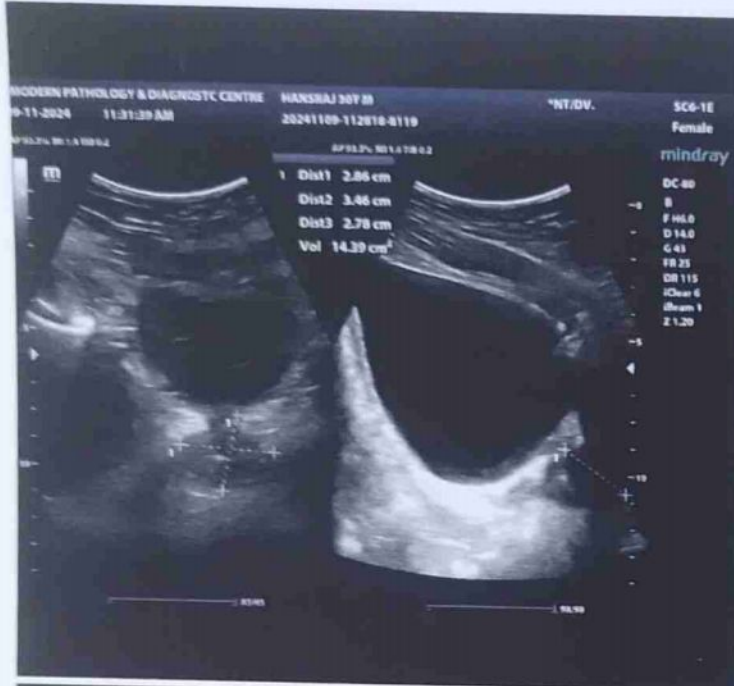SAMPLE COLLECTION FACILITY AVAILABLE

Report needs clinicopathological correlation ♦ Not for Medico Legal Purpose

e-mail : mpdcgn@gmail.com ♦ For online reports - www.modernpath.in

♦ Please ask for your computerized bill ♦ Pay only the printed collection charges

MODERN PATHOLOGY & DIAGNOSTIC CEN.





MODERN PATHOLOGY & DIAGNOSTIC CENTRE

Dr. R. P. Rastogi
M.B.B.S., M.D. (Path & Bact)



CLINIC :
1/4A, Vineet Khand, (Opp Jaipuria Management)
Gomti Nagar, Lucknow - 226 010
Ph.: 0522-4008184, 4308184 • 8112323230
Mob.: 7618884441, 9450389932, 8177063877



| | | |
|--|------------------|----------------------|
| TEST REQUEST ID :012411090032 | SAMPLE DATE | :09/Nov/2024 10:12AM |
| NAME :Mr. HANSRAJ SRIVASTAVA | SAMPLE REC. DATE | :09/Nov/2024 10:12AM |
| AGE/SEX :30 YRS/MALE | REPORTED DATE | :09/Nov/2024 12:19PM |
| REFERRED BY : Apollo Health and Lifestyle Limited, | BARCODE NO | :01090032 |

XRAY CHEST PA

- Trachea is central in position.
- Bilateral lung fields are normally aerated.
- Both hilar shadows are normal.
- Both C.P. angles are clear.
- Cardiac shadow is within normal limits.
- Bony cage appears normal.

OPINION: NORMAL STUDY.

Please correlate clinically.

*** End Of Report ***



Anjanay Rastogi
M.B.B.S., DCP, CRIAT (BARC)

Surbhi
Dr. Surbhi
MBBS, MD (Radiodiagnosis)

Dr. Smita Rastogi
M.B.B.S., DCP

Results, adhering to W.H.O. and International Federation of Clinical Chemists Quality Control Standards.

SAMPLE COLLECTION FACILITY AVAILABLE

Report needs clinicopathological correlation ♦ Not for Medico Legal Purpose

e-mail : mpdcgn@gmail.com ♦ For online reports - www.modernpath.in

Print Date Time: 09/11/2024 3:23 PM ♦ Please ask for your computerized bill ♦ Pay only the printed collection charges



MODERN PATHOLOGY & DIAGNOSTIC CENTRE

DIAGNOSTIC CENTRE

Dr. R. P. Rastogi
M.B.B.S., M.D. (Path & Bact)



CLINIC :
1/4A, Vineet Khand, (Opp Jaipuria Management)
Gomti Nagar, Lucknow - 226 010
Ph.: 0522-4008184, 4308184 • 8112323230
Mob.: 7618884441, 9450389932, 8177063877

=====

Registration Date 09/11/2024 Age : 30 Sex: M


Name : Mr Hansraj Srivastava

Ref By: Apollo Health

=====

EYES EXAMINATION REPORT

| EYE SIGHT | DISTANT VISION | | NEAR VISION | |
|--------------------------|--|------|-------------|------|
| | RIGHT | LEFT | RIGHT | LEFT |
| WITHOUT GLASSES | 6/16 | 6/6 | N-6 | N-6 |
| WITH GLASSES | | | | |
| POWER OF GLASSES IF USED | | | | |
| FUNDUS | NORMAL | | | |
| COLOR VISION | Present Normal according to ISHIHARA'S CHART | | | |
| PUPILS | Normally reacting to light and accommodation | | | |


 Dr. H. S. Khatia
 M.B.B.S., D.C.M.S.

Dr. Sanjay Rastogi
M.B.B.S., DCP, CRIAT (BARC)

Dr. Smita Rastogi
M.B.B.S., DCP

Results, adhering to W.H.O. and International Federation of Clinical Chemists Quality Control Standards.

SAMPLE COLLECTION FACILITY AVAILABLE

Report needs clinicopathological correlation ♦ Not for Medico Legal Purpose

e-mail : mpdcgn@gmail.com ♦ For online reports - www.modernpath.in

♦ Please ask for your computerized bill ♦ Pay only the printed collection charges

MODERN PATHOLOGY AND DIAGNOSTIC CENTER

Gomti Nagar lucknow

Report

AGHPL

HANSRAJ SRIVASTAVA / 31 Yrs / M / 176 Cms / 93 Kg

Date: 09 - 11 - 2024 Refd By : APOLLO HEALTH Examined By:

| Stage | Time | Duration | Speed(Kmph) | Elevation | METs | Rate | % THR | BP | RPP | PVC | Comments |
|---------------|-------|----------|-------------|-----------|------|------|-------|--------|-----|-----|----------|
| Supine | 00:04 | 0:04 | 00.0 | 00.0 | 01.0 | 085 | 45 % | 110/70 | 093 | 00 | |
| Standing | 00:07 | 0:03 | 00.0 | 00.0 | 01.0 | 080 | 42 % | 110/70 | 088 | 00 | |
| HV | 00:11 | 0:04 | 00.0 | 00.0 | 01.0 | 088 | 47 % | 110/70 | 096 | 00 | |
| ExStart | 00:25 | 0:14 | 00.0 | 00.0 | 01.0 | 088 | 47 % | 110/70 | 096 | 00 | |
| BRUCE Stage 1 | 03:25 | 3:00 | 02.7 | 10.0 | 04.7 | 121 | 64 % | 122/80 | 147 | 00 | |
| BRUCE Stage 2 | 06:25 | 3:00 | 04.0 | 12.0 | 07.1 | 144 | 76 % | 130/86 | 187 | 00 | |
| PeakEX | 07:30 | 1:05 | 05.5 | 14.0 | 08.2 | 160 | 85 % | 130/86 | 208 | 00 | |
| Recovery | 08:30 | 1:00 | 00.0 | 00.0 | 01.2 | 123 | 65 % | 124/82 | 152 | 00 | |
| Recovery | 09:30 | 2:00 | 00.0 | 00.0 | 01.0 | 109 | 58 % | 120/80 | 130 | 00 | |
| Recovery | 10:30 | 3:00 | 00.0 | 00.0 | 01.0 | 106 | 56 % | 118/80 | 125 | 00 | |
| Recovery | 10:55 | 3:25 | 00.0 | 00.0 | 01.0 | 109 | 58 % | 118/80 | 128 | 00 | |

FINDINGS :

Exercise Time : 07:05
 Max HR Attained : 160 bpm 85% of Target 189
 Max BP Attained : 130/86 (mm/Hg)
 Max WorkLoad Attained : 8.2 Fair response to induced stress
 Test End Reasons : Test Complete, Fatigue , Test Complete

REPORT :

CONCLUSIONS:

1. STRESS TEST IS NEGATIVE FOR EXERCISE INDUCED ISCHAEMIC HEART DISEASE.

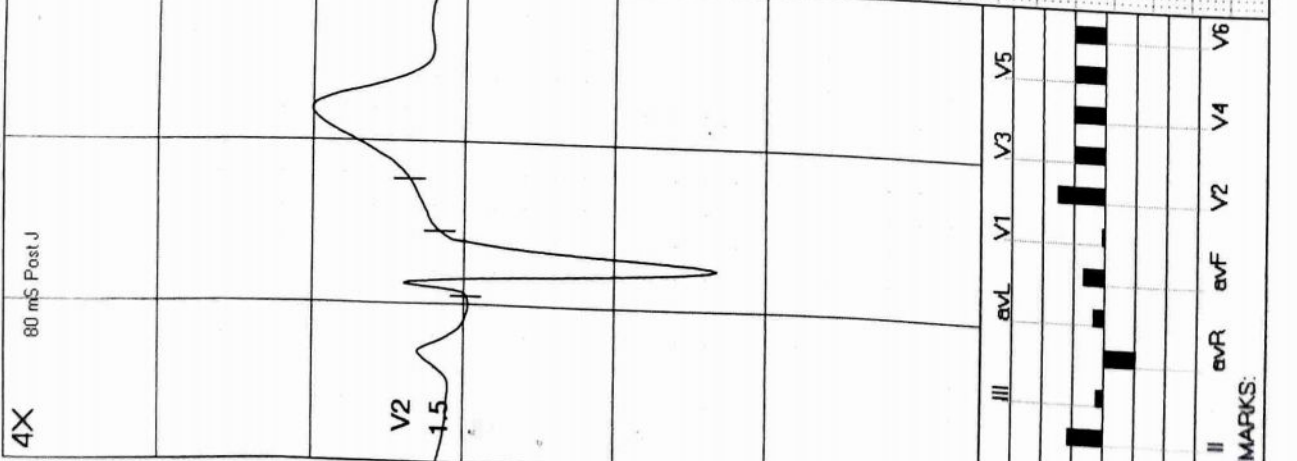
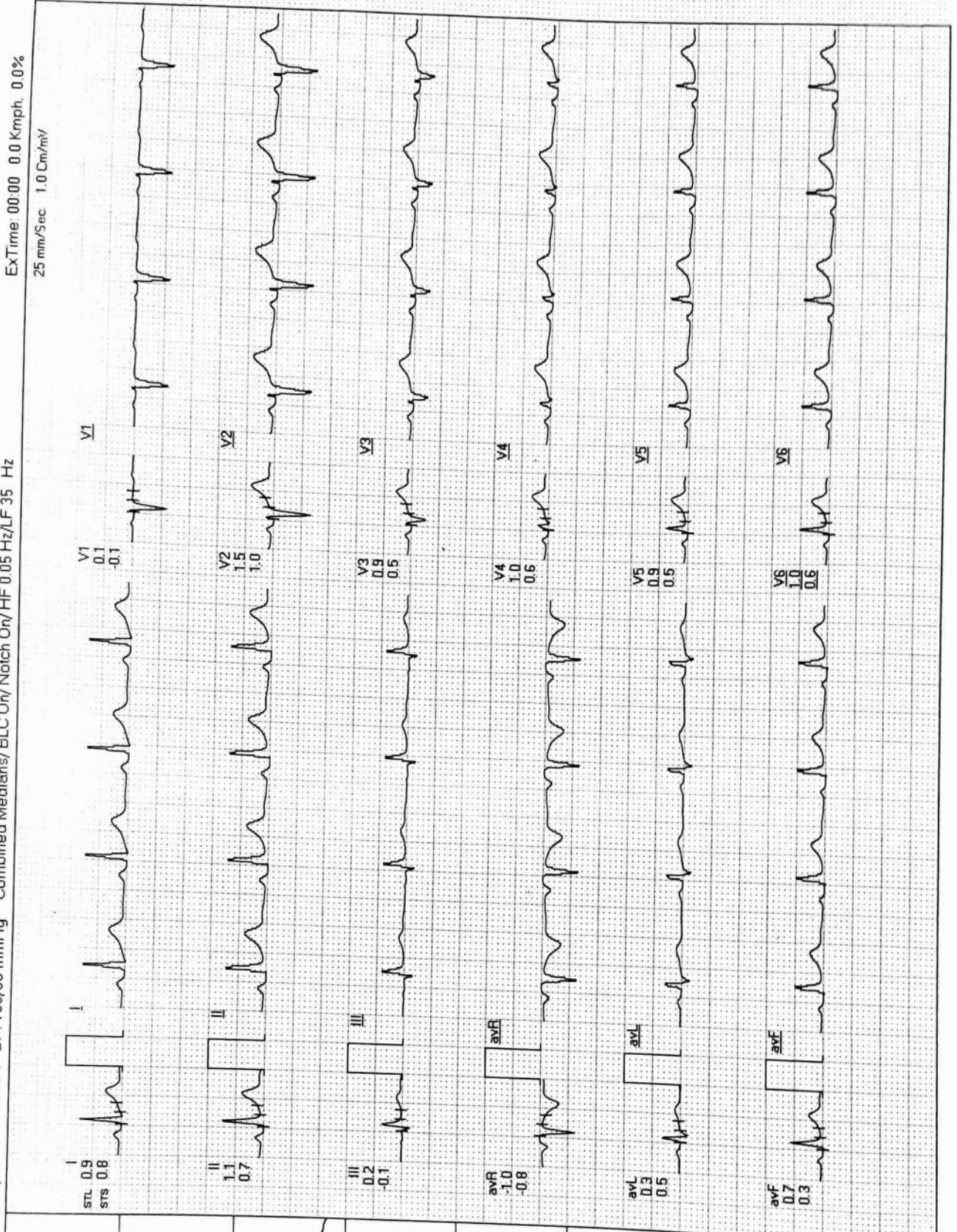
DR. ANKUR KUMAR
 M.D.
 Reg. No. 44539

Date: 09-11-2024

METS: 1.0/ 80 bpm 43% of THR BP: 100/60 mmHg Combined Medians/BLC On/ HF 0.05 Hz/LF 35 Hz

ExTime: 00:00 0.0 Kmph, 0.0%

25 mm/Sec 1.0 Cm/mV



REMARKS:

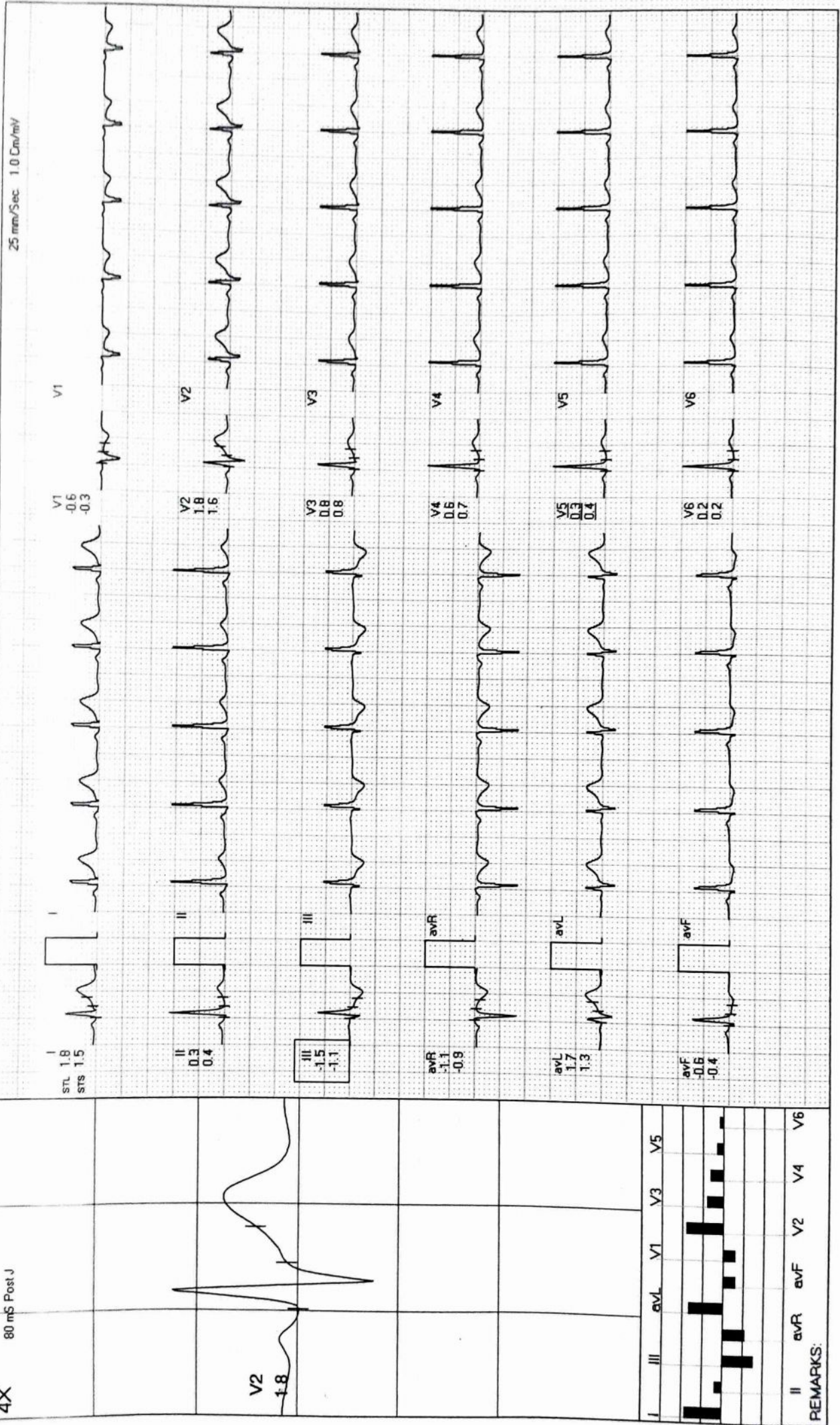
MODERN PATHOLOGY AND DIAGNOSTIC CENTER

HANSRAJ SRINIVASTAVA / 31 Yrs / M / 176 Cms / 93 Kg / HR : 85

BRUCE:Supine(0:04)

ACLDL

Date: 09-11-2024 METS: 1.0/85 bpm 45% of THR BP: 110/70 mmHg Combined Medians/ELC On/ Notch On/ HF 0.05 Hz/LF 35 Hz Ex Time 00:00 0.0 Km/ph 0.0%




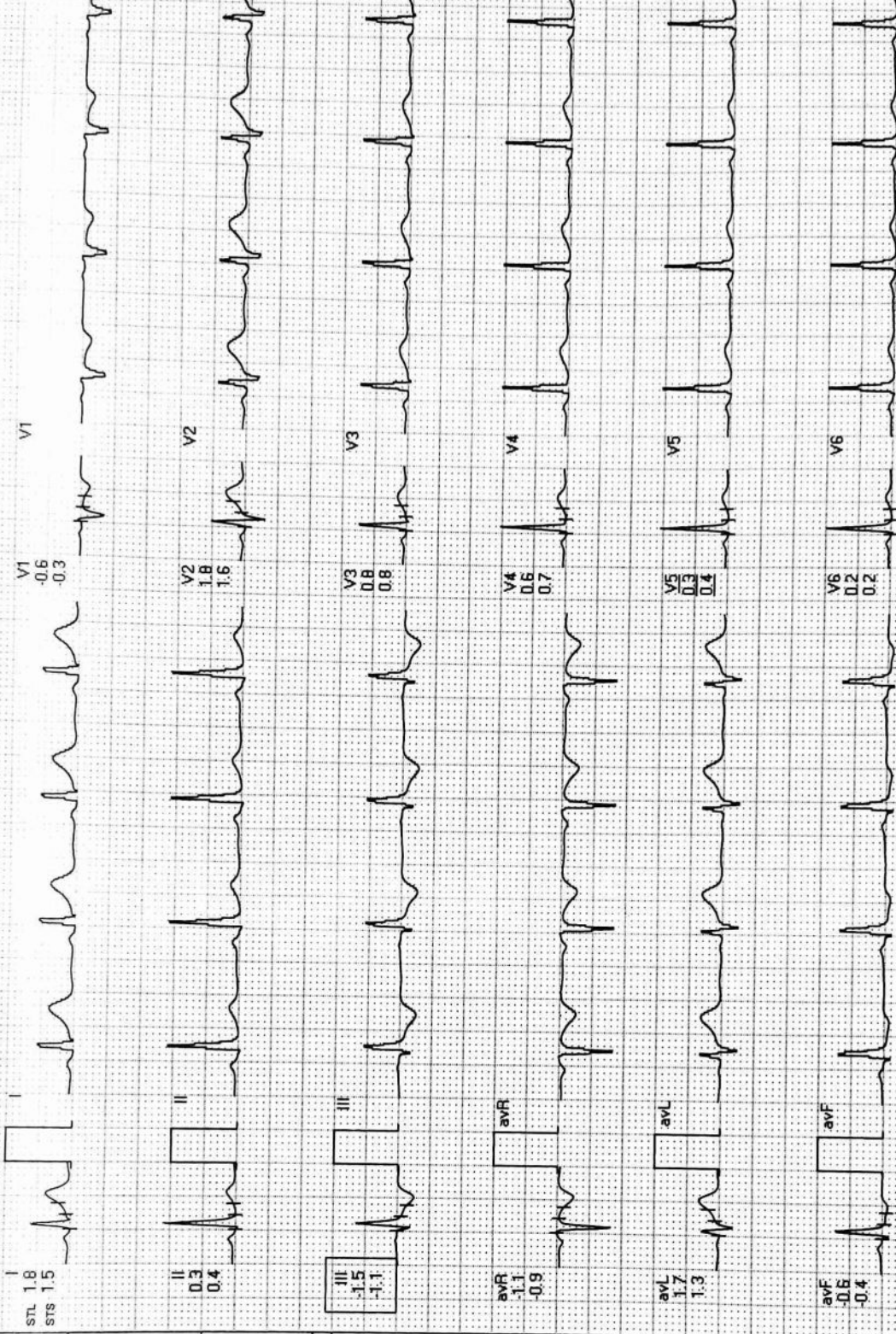
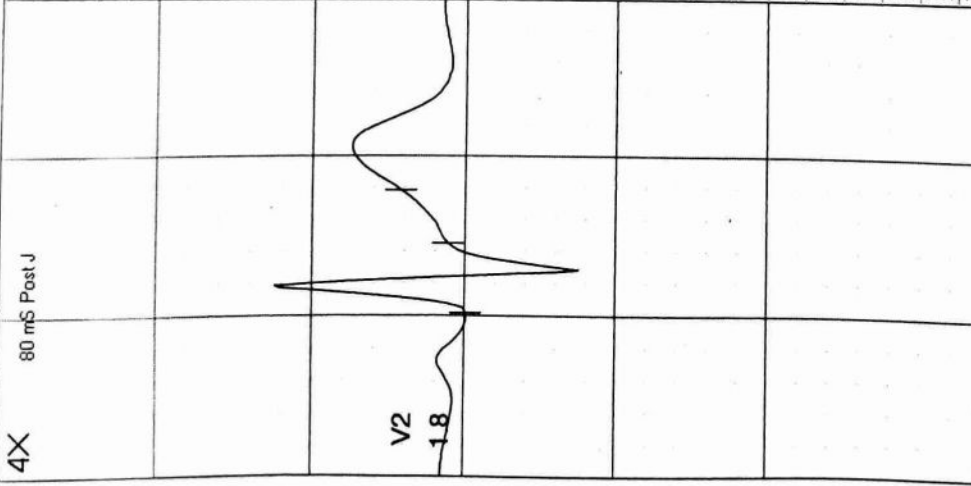
REMARKS:



Date 09-11-2024

METS: 1.0/80 bpm 42% of THR BP 110/70 mmHg Combined Medians/ BLC On/ Notch On/ HF 0.05 Hz/LF 35 Hz

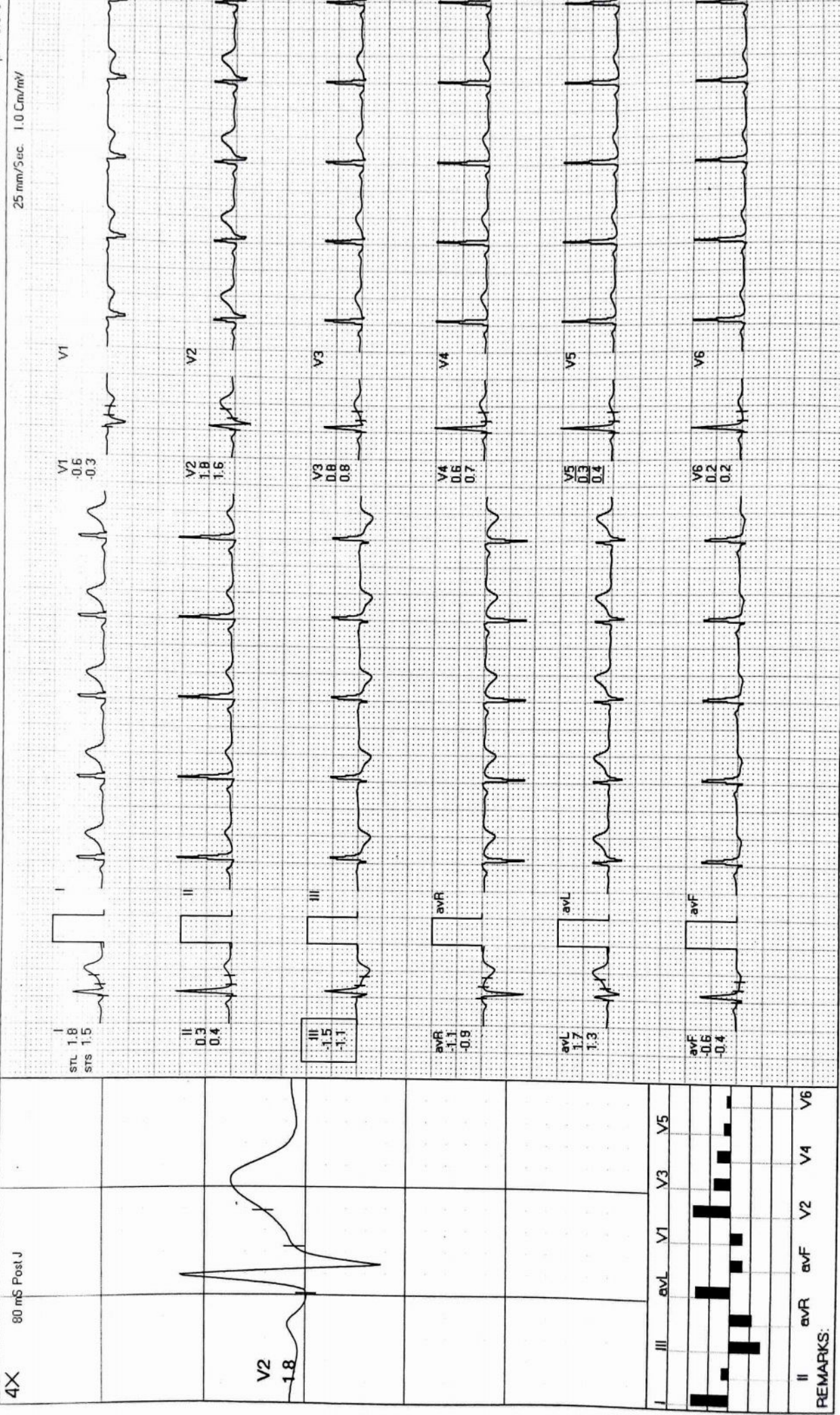
ExTime 00:00 0.0 Kmph 0.0%
25 mm/Sec. 1.0 Cm/mV



REMARKS:



Date: 09-11-2024 METS: 1.0/88 bpm 47% of THR BP: 110/70 mmHg Combined Medians/ BLC On/ Notch On/ HF 0.05 Hz/LF 35 Hz ExTime 00:00 0.0 Kmph 0.0%



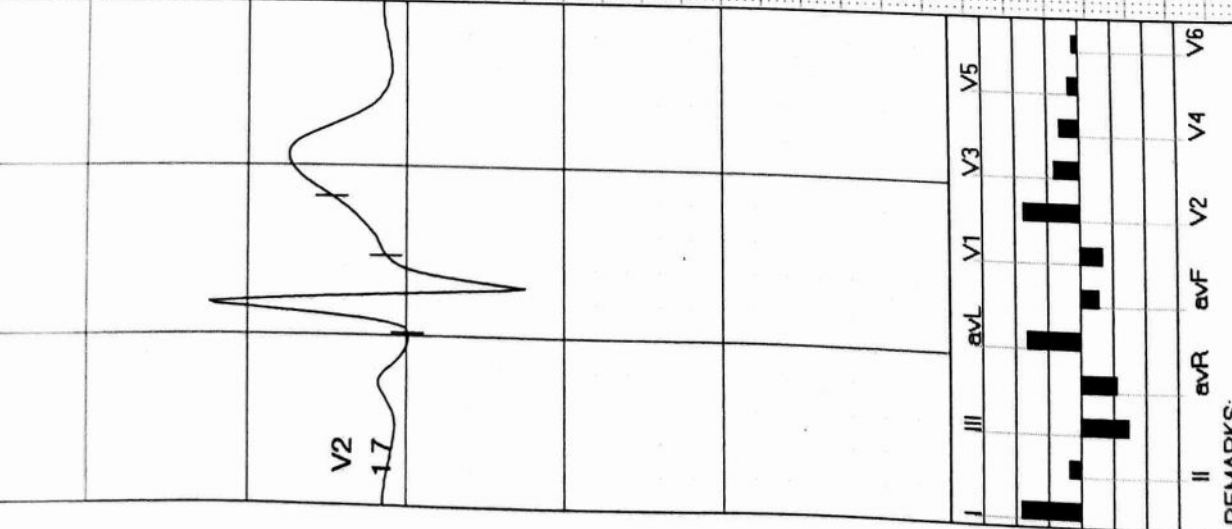
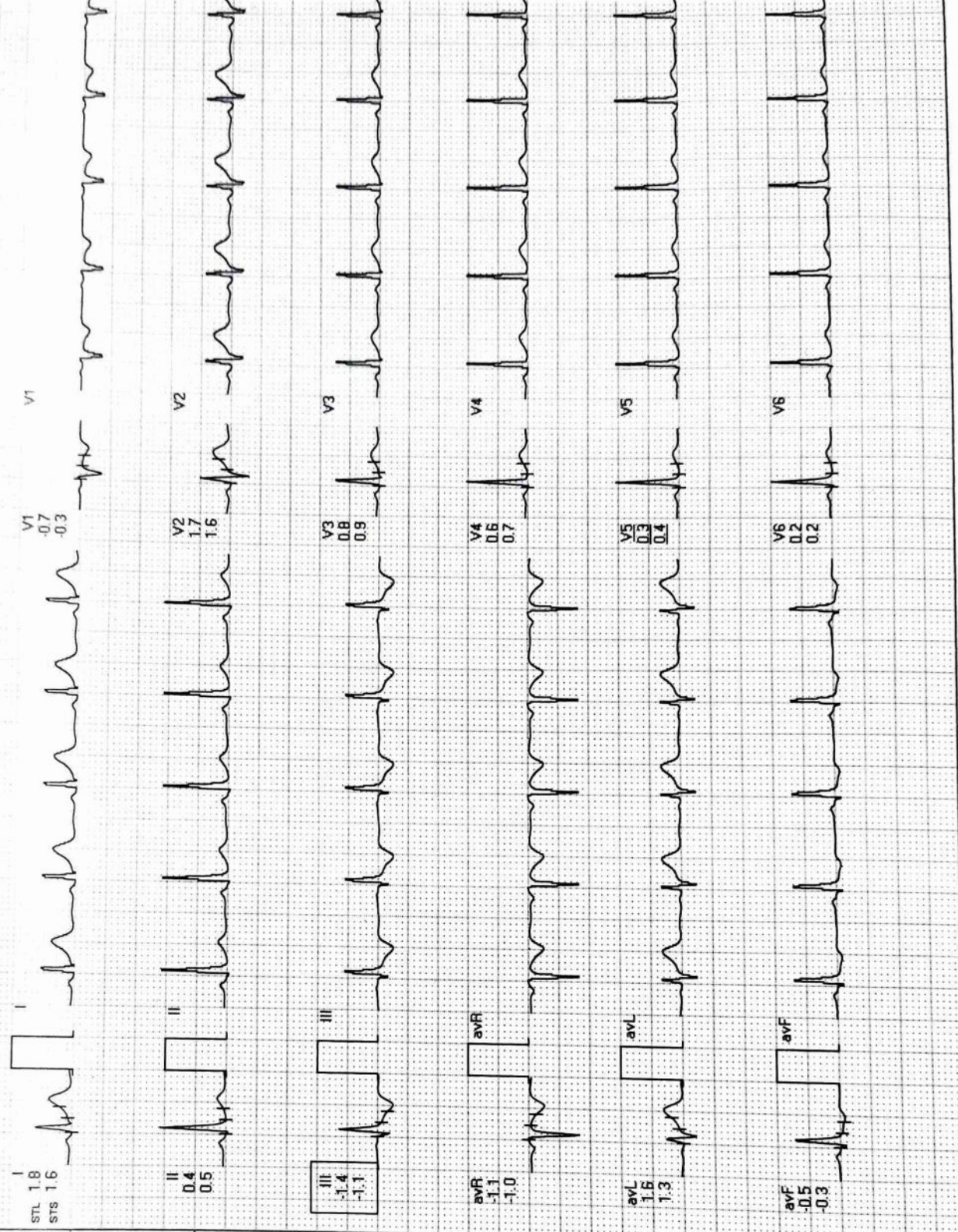
Date: 09-11-2024

METS: 1.0 / 88 bpm 47% of THR BP: 110/70 mmHg Combined Medians/BLC On/ HF 0.05 Hz/LF 35 Hz

4X

80 mS Post J

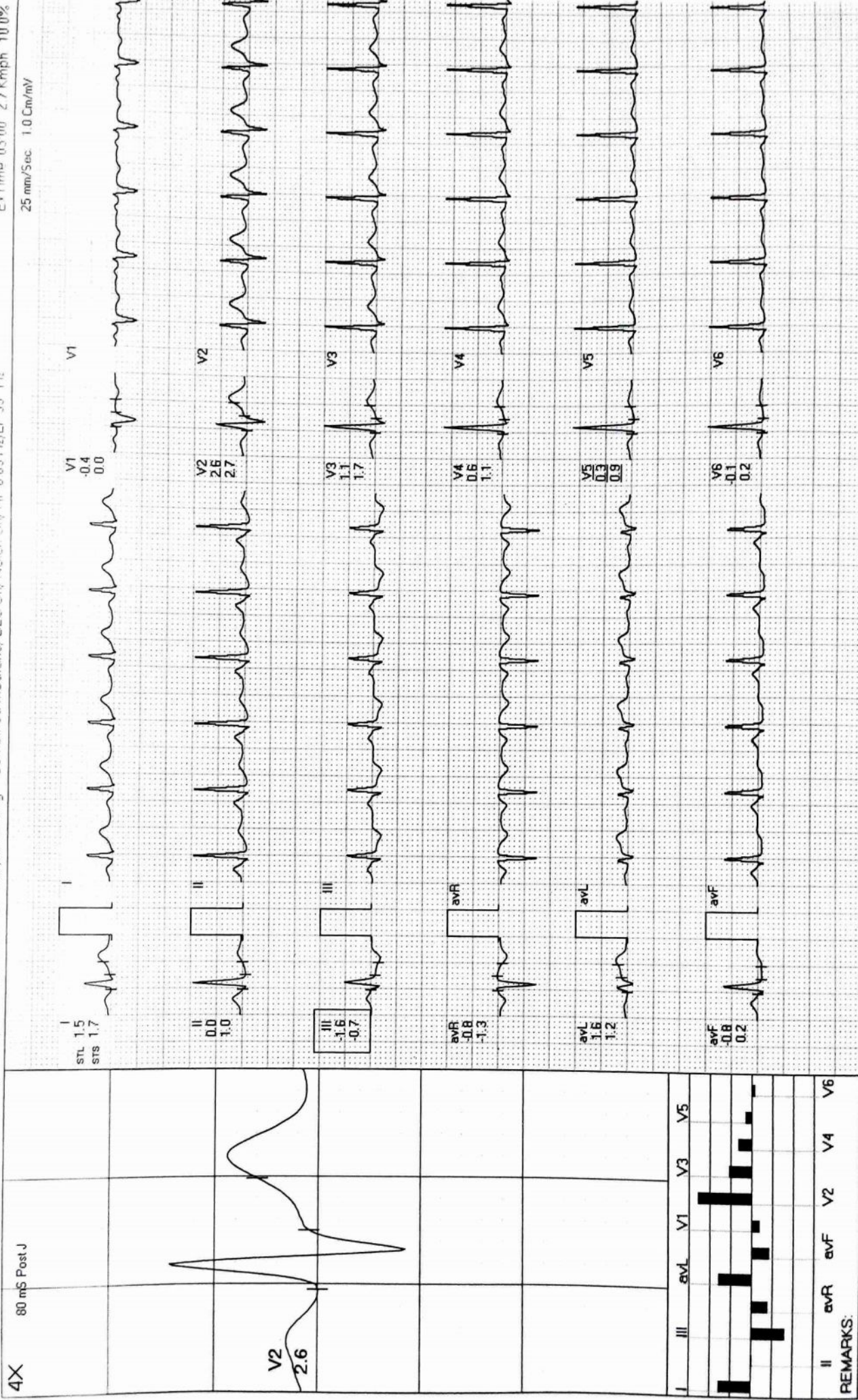
ExTime 00:00 0.0 Kmph 0.0%
25 mm/Sec 1.0 Cm/mV



REMARKS:



Date: 09-11-2024
 METS: 4.7/121 bpm 64% of THR BP: 122/80 mmHg Combined Medians/BLC On/Notch On/HF 0.05 Hz/LF 35 Hz
 ExTime: 03:00 2.7 Km/h 10.0%
 25 mm/Sec 1.0 Cm/mV



REMARKS:

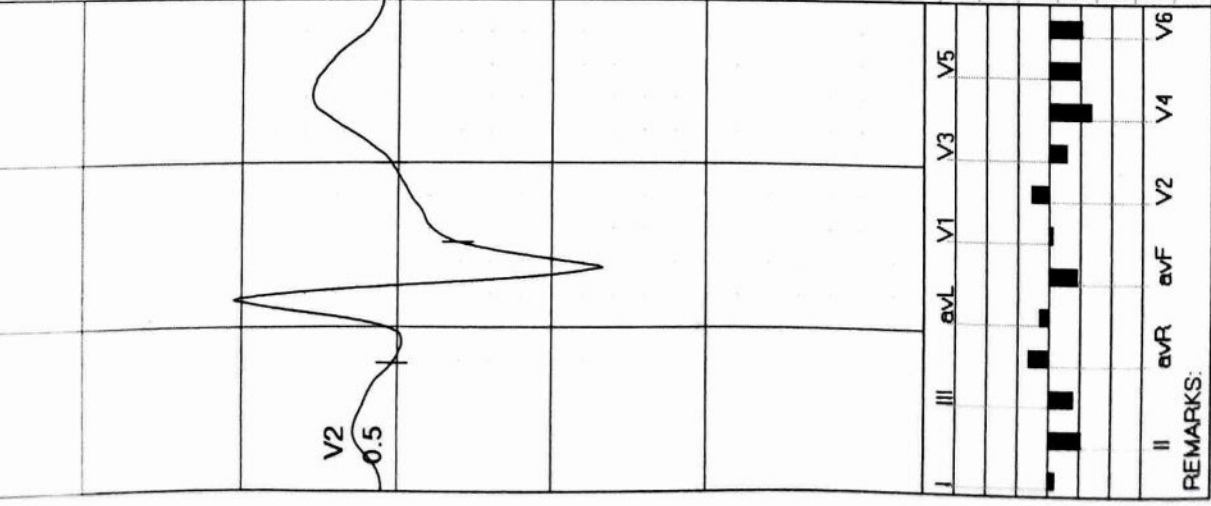
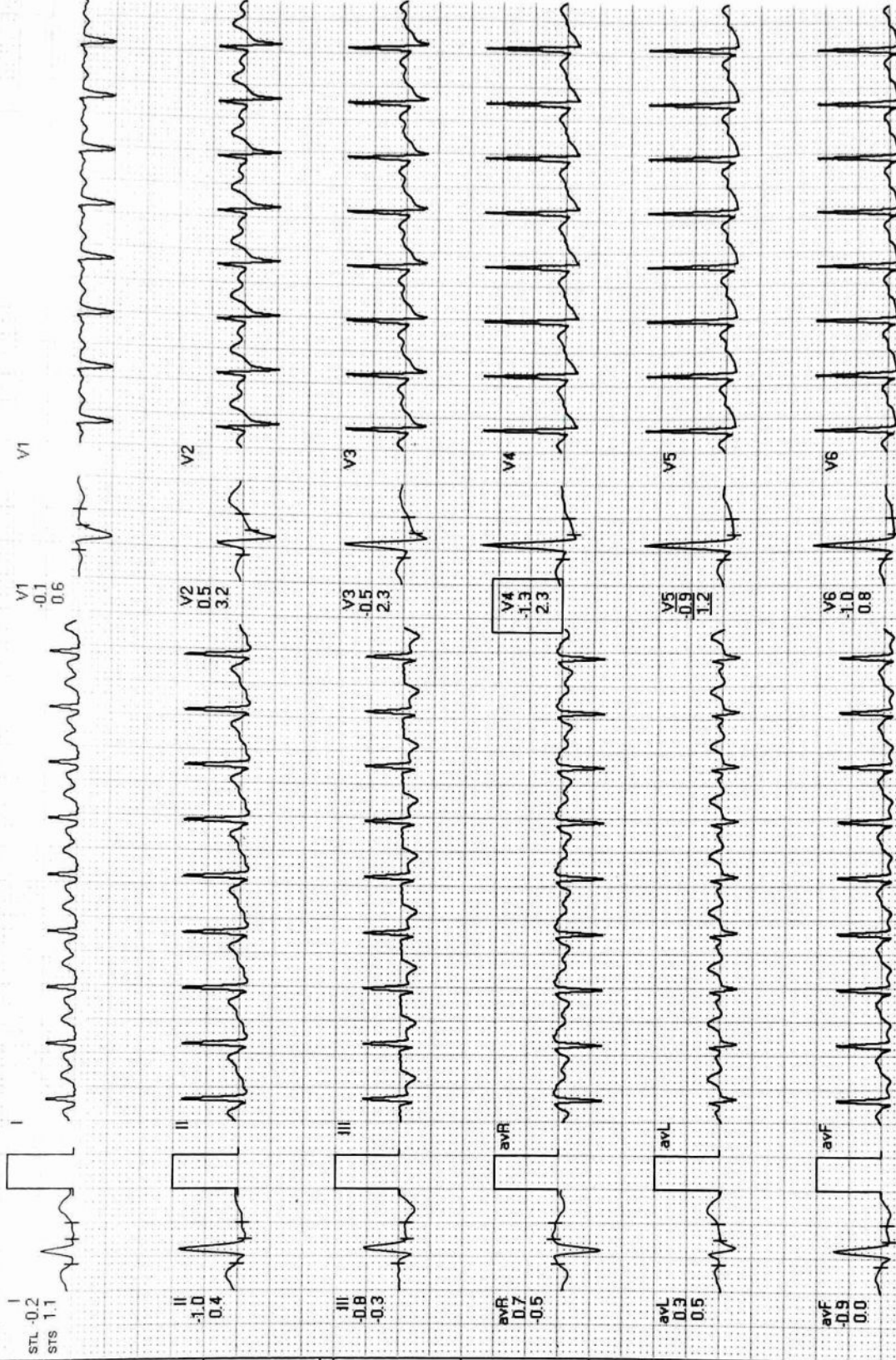
Date 09-11-2024

METS: 8.2/160 bpm 85% of THR BP 130/86 mmHg Combined Medians/ BLC On/Match On/ HF 0.05 Hz/LF 35 Hz

ExTime 07:05 5.5 Kmph, 14.0%

4X 60 mS Post J

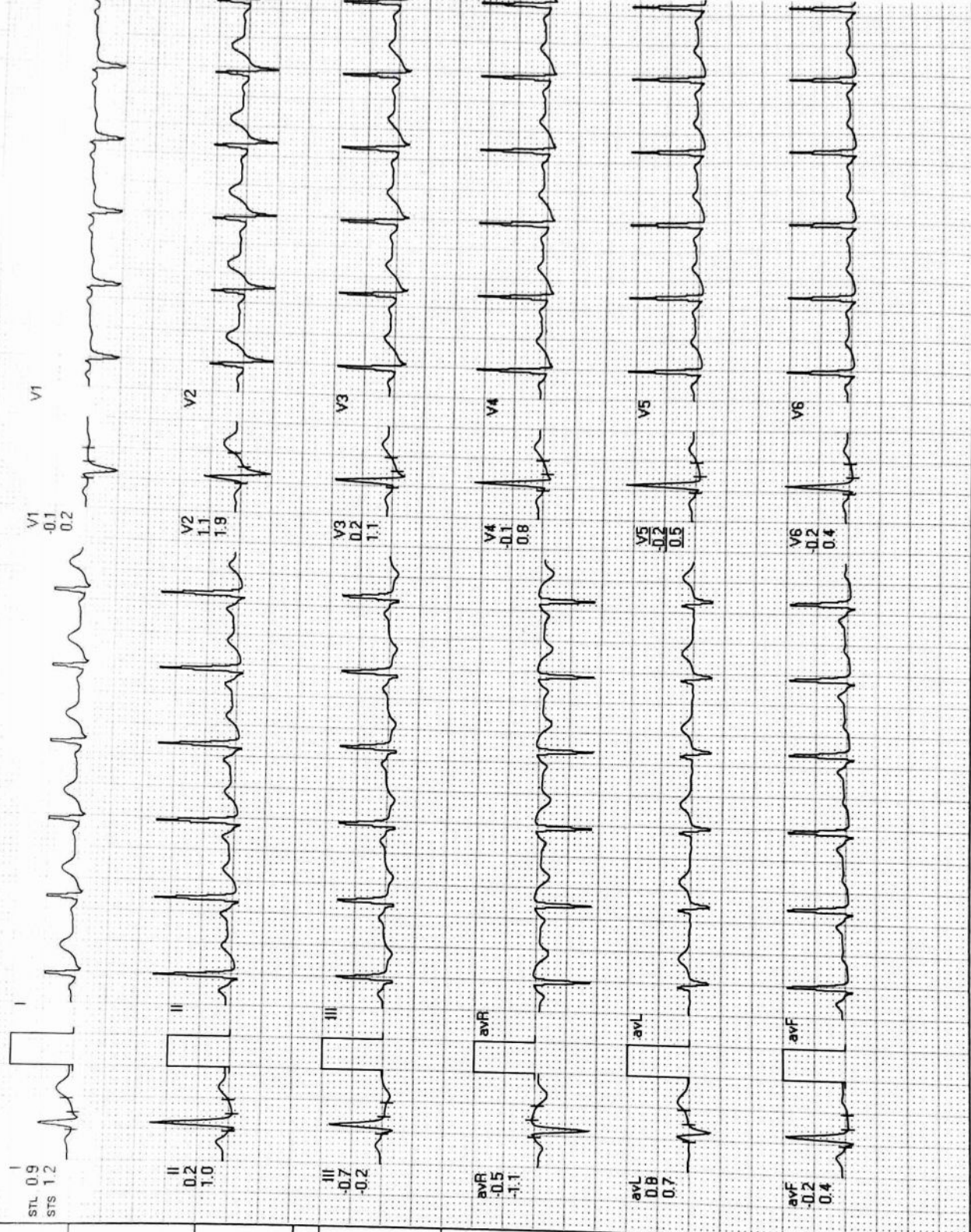
25 mm/Sec 1.0 Cm/mV



REMARKS:



Date 09-11-2024 METS: 1.0 / 109 bpm 58% of THR BP 120/80 mmHg Combined Medians / SLC On / Notch On / HF 0.05 Hz / LF 35 Hz
 4X 80 mS Post J EvrTime 07:05 0.0 Kmph 0.0%
 25 mm/Sec 1.0 Cm/mV



| Lead | STL | STS | STL | STS |
|------|------|------|------|-----|
| I | 0.9 | 1.2 | -0.1 | 0.2 |
| II | 0.2 | 1.0 | 1.1 | 1.9 |
| III | -0.7 | -0.2 | 0.2 | 1.1 |
| aVR | -0.5 | -1.1 | -0.1 | 0.8 |
| aVL | 0.8 | 0.7 | -0.2 | 0.5 |
| aVF | -0.2 | 0.4 | 0.2 | 0.4 |

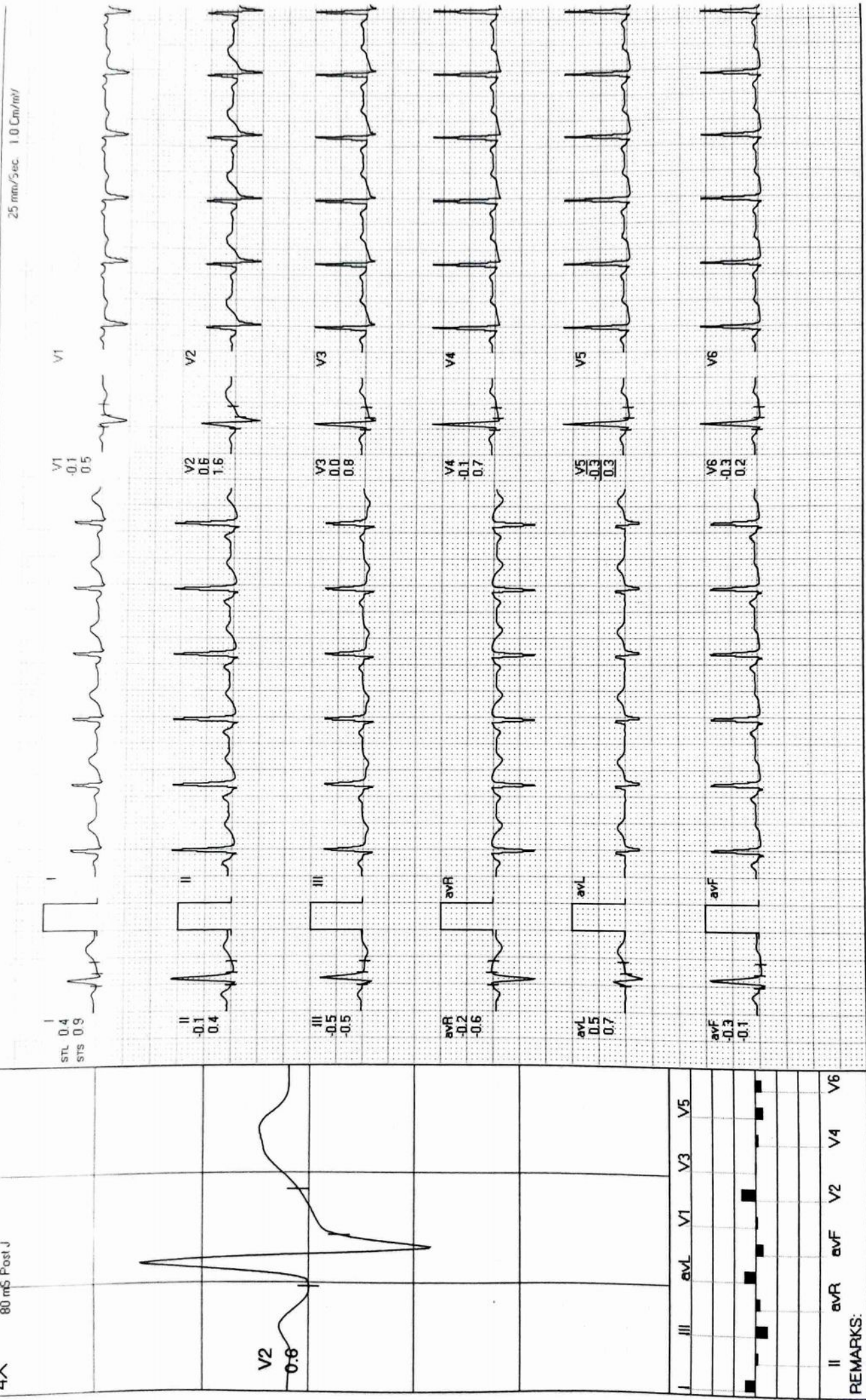
REMARKS:

Date 09-11-2024

METS: 1.0/106 bpm; 56% of THR BP: 118/90 mmHg Combined Medians/BLC On/Notch On/HF 0.05 Hz/LF 35 Hz

EvTime 07:05 0.0 Kmph 0.0%

4X 80 mS Post J



MODERN PATHOLOGY AND DIAGNOSTIC CENTER

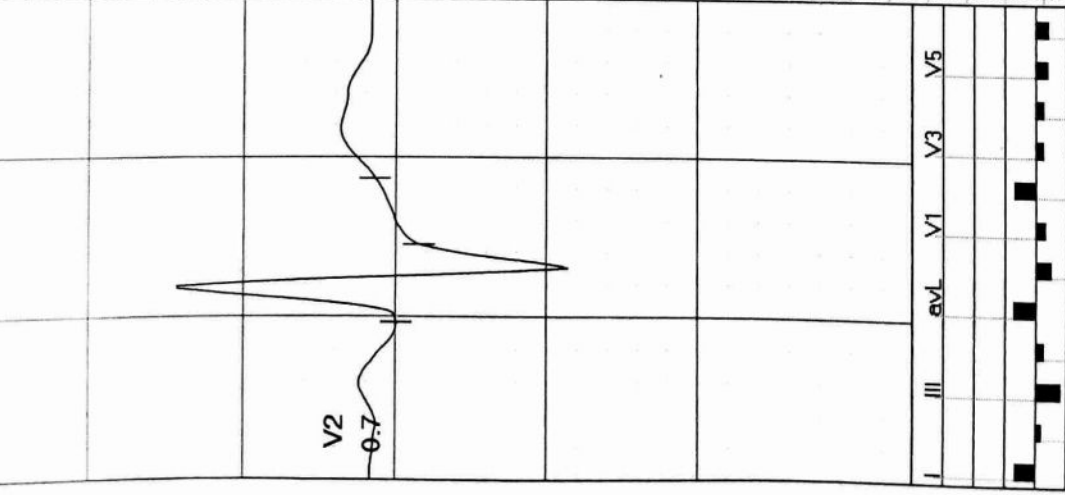
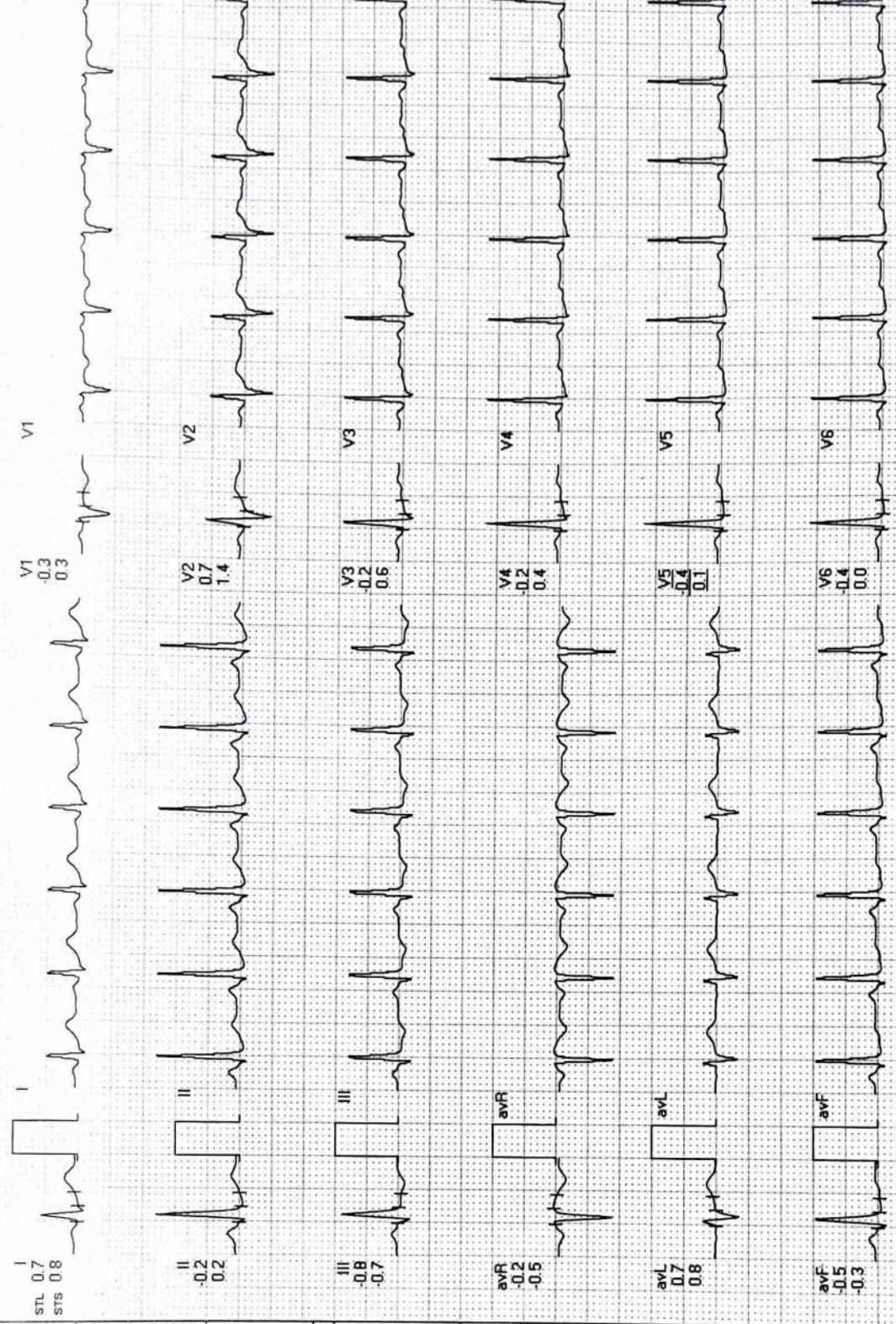
HANSRAJ SRIVASTAVA / 31 Yrs / M / 176 Cms / 93 Kg / HR : 109

Recovery(3:25)

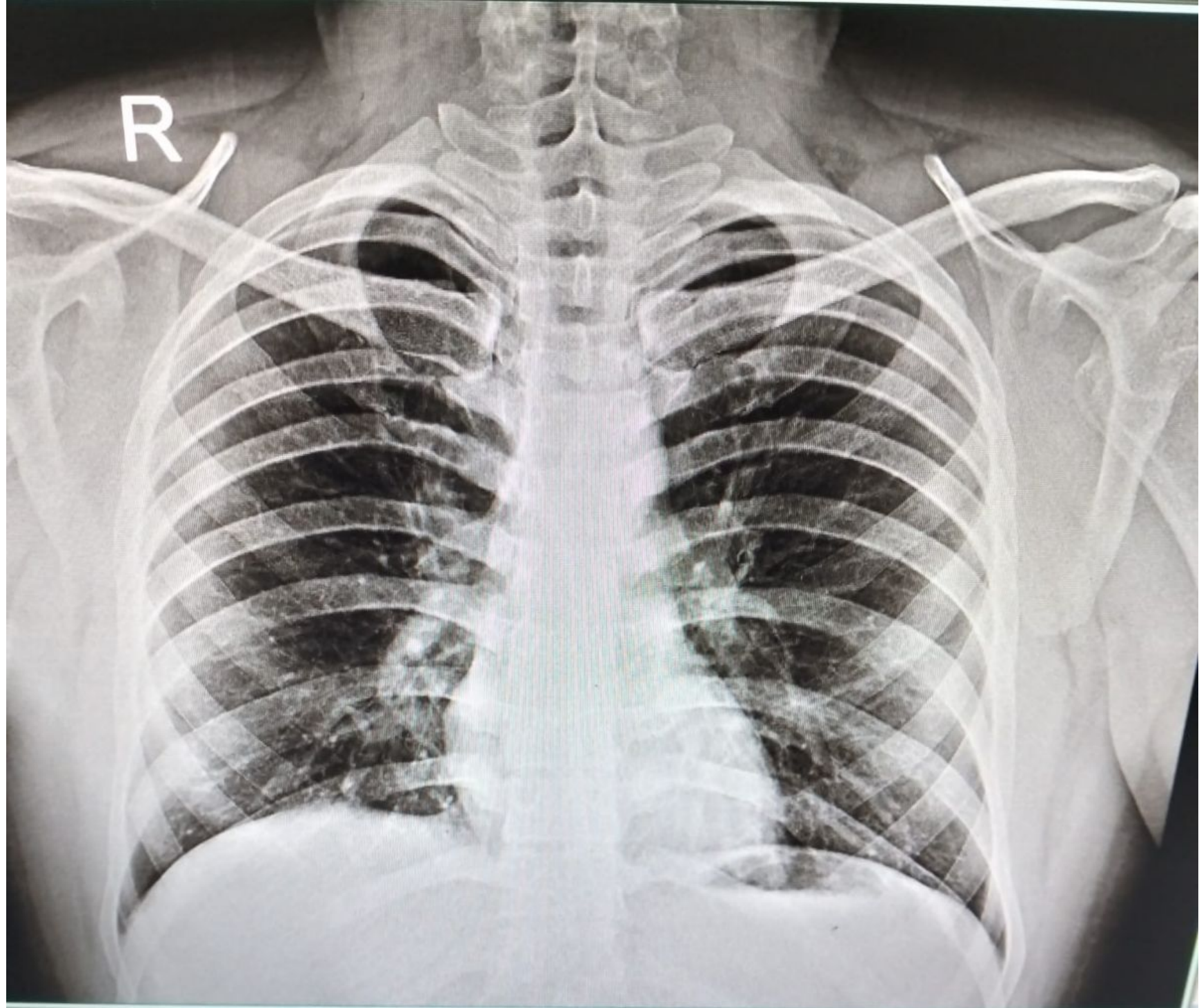
AGHPL

Date 09-11-2024 METS 1.0/109 bpm 58% of THR BP 118/80 mmHg Combined Medians/BLC On/Notch On/HF 0.05 Hz/LF 35 Hz

4X 80 m/s Post J 25 mm/5 sec 1.0 Cm/mV



REMARKS:



24110900280 MR HANSRAJ SRIVASTAVA 30YRS M CHEST PA SELF
09/11/2024 MODERN PATHOLOGY & ULTRASOUND CENTRE,UP