



# MEDICOVER

## HOSPITALS

### NAVI MUMBAI

**Name** : Mrs. CHAITALI MARUTI KUTE  
**Bill No.** : MCB54241101884

**Age /Sex** : 33 Yrs / FEMALE  
**UMR No.** : 542411000611

### LABORATORY REPORT : BIOCHEMISTRY

Parameters	Result	Reference Range	Units
<b>SERUM URIC ACID</b>			
( Bill Date : 09-Nov-2024 10:21 AM Result ID : RMI241106626)			
SERUM URIC ACID <i>uricase</i>	3.5	2.4-5.7	mg/dL
<b>BUN(BLOOD UREA NITROGEN)</b>			
( Bill Date : 09-Nov-2024 10:21 AM Result ID : RMI241106627)			
BUN (Blood Urea Nitrogen.) <i>Calculated</i>	5 *	7 - 21.0	mg/dL
<b>HBA1C (GLYCOSYLATED HAEMOGLOBIN)</b>			
( Bill Date : 09-Nov-2024 10:21 AM Result ID : RMI241106628)			
HBA1C <i>HPLC</i>	4.5	" Normal : < 5.7% Pre diabetic : 5.7 % - 6.5 % Diabetic : > 6.5 %	
<b>LIPID PROFILE</b>			
( Bill Date : 09-Nov-2024 10:21 AM Result ID : RMI241106629)			
TOTAL CHOLESTEROL <i>Enzymatic colorimetric</i>	133	Desirable :: < 200 mg/dL Borderline High :: 200 - 239 mg/dL High risk : > 240 mg/dL	mg/dL
HDL CHOLESTEROL <i>Homogeneous enzymatic colorimetric</i>	37	Low :: < 40 mg/dL High :: > 60 mg/dL	mg/dL
LDL CHOLESTEROL <i>Direct-Enzymatic colorimetric</i>	81	Very High : - > 190 mg/dL Optimal : - < 100 mg/dL Near Optimal : 100 - 129 mg/dL High : 160 - 189 mg/dL Borderline High:130-159 mg/dl	mg/dL
VLDL <i>Calculation</i>	16	2 - 30 mg/dL	mg/dL
SERUM TRYGLYCERIDES <i>Enzymatic colorimetric</i>	78	< 150 mg/dL Borderline High : 150 - 199 mg/dL High : 200 - 499 mg/dL	mg/dL





# MEDICOVER

HOSPITALS

NAVI MUMBAI

Name : Mrs. CHAITALI MARUTI KUTE  
Bill No. : MCB54241101884

Age / Sex : 33 YRS / FEMALE  
UMR No. : 542411000611

CHO/HDL RATIO  
*Calculation*

3.59 \*

Normal : - < 3.5  
High Risk : - > 5.0

LDL/HDL RATIO

2.19

## FBS (FASTING BLOOD GLUCOSE WITH URINE GLUCOSE)

( Bill Date : 09-Nov-2024 10:21 AM Result ID : RMI241106630)

FASTING BLOOD GLUCOSE  
*Hexokinase*

88

Normal Range : 70 - 99  
Impaired Glucose tolerance : 100 -125  
Diabetes Mellitus : >=126

mg/dL

FASTING URINE GLUCOSE

NIL

## SERUM CREATININE

( Bill Date : 09-Nov-2024 10:21 AM Result ID : RMI241106631)

CREATININE  
*Jaffe*

0.53 \*

0.6 - 1.2

mg/dL

## BUN / CREATININE RATIO

( Bill Date : 09-Nov-2024 10:21 AM Result ID : RMI241106632)

BUN / CREATININE RATIO  
*CALCULATED*

9.43 \*

10-20

## LFT(LIVER FUNCTION TEST)

( Bill Date : 09-Nov-2024 10:21 AM Result ID : RMI241106636)

TOTAL BILIRUBIN  
*DIAZO*

1.8 \*

<1.2

mg/dL

DIRECT BILIRUBIN  
*DIAZO*

0.6 \*

<=0.20

mg/dL

INDIRECT BILIRUBIN  
*Calculated*

1.2 \*

<=1.0

mg/dL

SGPT (ALT)  
*UV without P5P*

22

<=33

U/L

SGOT (AST)  
*UV without P5P*

25

<= 32

U/L

ALKALINE PHOSPHATASE (ALP)  
*PNPP, AMP Buffer - IFCC Ref.*

64

35 - 105

U/L

TOTAL PROTEINS  
*Biuret method*

7.2

6.0 - 8.0 g/dL

g/dL





# MEDICOVER

## HOSPITALS

### NAVI MUMBAI

<b>Name</b> : Mrs. CHAITALI MARUTI KUTE	<b>Age /Sex</b> : 23 YRS / FEMALE
<b>Bill No.</b> : MCB54241101884	<b>UMR No.</b> : 542411000611

SERUM ALBUMIN <i>Bromcresol Green (BCG)</i>	4.5	3.5 - 5.2 g/dL	g/dL
GLOBULINS <i>Calculated</i>	2.7	2.5 - 3.5 g/dL	g/dL
A/G RATIO <i>Calculation</i>	1.66	1.2 - 2.5	
GAMMA GLUTAMYL TRANSFERASE(GGT) <i>G-glutamyl-carboxy-nitroanilide-IFCC</i>	14	6-42	U/L

#### T3,T4 AND TSH


( Bill Date : 09-Nov-2024 10:21 AM Result ID : RMI241106637)

T3 <i>ECLIA</i>	125.0	70 - 204	ng/dL
T4 <i>ECLIA</i>	6.36	5.1 - 14.1	ug/dL
TSH(THYROID STIMULATING HORMONE) <i>ECLIA</i>	1.54	0.270 - 4.20	uIU/mL

#### PLBS (POST LUNCH BLOOD SUGAR WITH URINE SUGAR)

( Bill Date : 09-Nov-2024 10:21 AM Result ID : RMI241106881)

PLBS (POST LUNCH BLOOD GLUCOSE)	113
URINE SUGAR	NIL

  
DR. MEHROTRA VISHAL  
MD Pathology





**MEDICOVER**

<b>Name</b>	: Mrs. CHAITALI MARUTI KUTE	<b>Age /Sex</b>	: 33 Yrs / FEMALE
<b>Bill No.</b>	: MCB54241101884	<b>UMR No.</b>	: 542411000611

**HOSPITALS**


**NAVI MUMBAI**

**LABORATORY REPORT : BLOOD BANK**

Parameters	Result	Reference Range	Units
<b>BLOOD GROUPING AND RH</b>			
( Bill Date : 09-Nov-2024 10:21 AM      Result ID : RMI241106638)			
<b>BLOOD GROUP</b> <i>Automated microcolumn gel method</i>	<b>AB</b>		
<b>RH TYPE</b>	<b>NEGATIVE</b>		

**INTERPRETATION**

1. If Rh is Du positive it is best considered as Rh negative as recipient and Rh positive as donor. Proper Cross matching is recommended before transfusion.
2. In case of forward and reverse grouping discrepancy, clinical correlation and repeat sample analysis is recommended.
3. For Infants below 6 months only forward grouping is performed.
4. A sub-grouping is recommended after the age of 6 months.

  
**DR. MEHROTRA VISHAL**  
MD Pathology





# MEDICOVER

## HOSPITALS

### NAVI MUMBAI

<b>Name</b> : Mrs. CHAITALI MARUTI KUTE	<b>Age /Sex</b> : 33Y Y(s)/FEMALE
<b>Bill No.</b> : MCB54241101884	<b>UMR No.</b> : 542411000611

### LABORATORY REPORT : CLINICAL PATHOLOGY

Parameters	Result	Reference Range	Units
<b>CUE(COMPLETE URINE EXAMINATION)</b>			
( Bill Date : 09-Nov-2024 10:21 AM Result ID : RMI241106635)			
<b><u>PHYSICAL EXAMINATION</u></b>			
VOLUME	30 ML		ml
COLOUR	Pale Yellow	PALE YELLOW	
APPEARANCE	CLEAR	CLEAR	
<b><u>CHEMICAL EXAMINATION</u></b>			
DEPOSIT	ABSENT	ANSENT	
SPECIFIC GRAVITY	1.005	1.000 - 1.030	
<i>Bromthymol blue</i>			
PH	6.5	5.0 - 8.0	
<i>Bromthymol blue</i>			
PROTEIN	NIL	NIL (<15 mg/dL)	
<i>Tetra-bromophenol blue/Heat coagulation test</i>			
GLUCOSE	NIL	NIL (<25 mg/dL)	
<i>Glucose oxidase Peroxidase/Benedict?s test</i>			
UROBILINOGEN	NIL	NIL	
<i>Diazonium salt</i>			
KETONE	NIL	NIL (<5 mg/dL)	
<i>Sodium nitroprusside/Rothera?s test.</i>			
BILIRUBIN	NIL	NEGATIVE	
<i>Dipstick/Fouchets test</i>			
BILE SALT	NIL	NEGATIVE	
<i>Hays sulphur powder</i>			
BILE PIGMENT	NIL	NEGATIVE	
<i>Fouchet test</i>			
NITRITE	NIL	NEGATIVE	
<i>Sulfanilic acid</i>			





# MEDICOVER

## HOSPITALS

### NAVI MUMBAI

**Name** : Mrs. CHAITALI MARUTI KUTE  
**Bill No.** : MCB54241101884

**Age /Sex** : 33 Yrs / FEMALE  
**UMR No.** : 542411000611

<b>LEUCOCYTE ESTERASE</b>	NIL	NEGATIVE	
<b><u>MICROSCOPIC EXAMINATION</u></b>			
PUS CELLS	1-2	0 - 5 /hpf	
EPITHELIAL CELLS	1-2	0 - 5	hpf
RBC	NIL	0 - 5 /hpf	
CAST	NIL	NIL	
<i>Microscopy examination</i>			
CRYSTALS	NIL	NIL	
BACTERIA	NIL		
<i>Microscopic examination</i>			
YEAST	NIL		
<i>Microscopic examination</i>			
AMORPHOUS DEPOSITS	NIL		
<i>Microscopic examination</i>			
MUCUS THREAD	NIL		
<i>Microscopic examination</i>			

#### NOTE

Microscopic examination of urine is carried out on centrifuged urinary sediment.

Dr Neeta Shrivastava  
MBBS, MD, DNB ( Microbiology)





# MEDICOVER

## HOSPITALS

### NAVI MUMBAI

**Name** : Mrs. CHAITALI MARUTI KUTE  
**Bill No.** : MCB54241101884

**Age / Sex** : 33 Yrs / FEMALE  
**UMR No.** : 542411000611

### LABORATORY REPORT : HAEMATOLOGY

Parameters	Result	Reference Range	Units
<b>CBP(COMPLETE BLOOD PICTURE)</b>			
( Bill Date : 09-Nov-2024 10:21 AM Result ID : RMI241106633)			
R B C COUNT <i>Electrical Impedance</i>	5.20 *	3.8-4.8	10 <sup>12</sup> /L
HEMOGLOBIN <i>Photometric</i>	10.5 *	12.0 - 15.0	gms/dL
PCV/HCT <i>Calculated</i>	34.4 *	36 - 46	%
MCV <i>Calculated</i>	66.2 *	83 - 101	fl
MCH <i>Calculated</i>	20.2 *	27 - 32	pg
MCHC <i>Calculated</i>	30.5 *	31.5 - 34.5	g/dL
RDW(cv)	15.5 *	11.6 - 14.0 %	%
TLC (TOTAL LEUCOCYTE COUNT) <i>Impedance</i>	4.86	4.0 - 10.0	10 <sup>3</sup> /μl

### DIFFERENTIAL COUNT

NEUTROPHILS <i>DHSS/Microscopy</i>	59	40 - 80 %	
LYMPHOCYTES <i>DHSS/Microscopy</i>	33	20 - 40 %	
MONOCYTES <i>DHSS/Microscopy</i>	06	02 - 10 %	
EOSINOPHILS <i>DHSS/Microscopy</i>	02	00 - 06 %	
BASOPHILS <i>DHSS/Microscopy</i>	00	00 - 01 %	
PLATELET COUNT <i>Electrical Impedance</i>	266	150 - 400	10 <sup>3</sup> /μL





**MEDICOVER**

**HOSPITALS**

**NAVI MUMBAI**

**Name** : Mrs. CHAITALI MARUTI KUTE  
**Bill No.** : MCB54241101884

**Age /Sex** : 38 Y (s) FEMALE  
**UMR No.** : 542411000611

**RBC**

Mild anisocytosis moderate poikilocytosis. Microcytic hypochromic with ovalocytes, elliptocytes, tear drop cells and some target cells.

**WBC**

Normal morphology.

**PLATELETS**

Adequate in smear.

**NOTE**

Advised: Haemoglobin electrophoresis/ HPLC assay.

**ESR**

( **Bill Date** : 09-Nov-2024 10:21 AM **Result ID** : RMI241106634)

ESR 03 0 - 20 mm/1st hour  
MODIFIED WESTERGREN'S METHOD

  
DR. MEHROTRA VISHAL  
MD Pathology





<b>Patient ID:</b>	<b>542411000611</b>	<b>Patient Name:</b>	<b>CHAITALI MARUTI KUTE 33YRS</b>
<b>Age:</b>		<b>Sex:</b>	<b>F</b>
<b>Accession Number:</b>		<b>Modality:</b>	<b>US</b>
<b>Referring Physician:</b>	<b>DR.DMO</b>	<b>Study:</b>	<b>7SG ABDOMEN PELVIS</b>
<b>Study Date:</b>	<b>09-Nov-2024</b>		

### ULTRASOUND EXAMINATION OF ABDOMEN & PELVIS

The Liver is normal in size and shows a normal parenchymal reflectivity. No focal lesion is seen. The Hepatic veins appear normal. There is no evidence of any dilated IHBR. The portal vein appears normal.

The gall bladder is physiologically distended with normal wall thickness. There is no evidence of gallstones. C.B.D. is of normal caliber.

The Pancreas is normal in size and shows homogeneous reflectivity. There is no evidence of any calcification or ductal dilatation.

The spleen is normal in size and shows a homogeneous echotexture. There is no evidence of any focal lesion.

Both kidneys are normal in position and size. They show normal cortical reflectivity and cortico-medullary distinction.

The Right Kidney measures 10.8 x 4.5 cm.

The Left Kidney measures 10.4 x 6 cm.

There is no evidence of renal calculi, hydronephrosis, or mass noted.

There is no evidence of ascites or para aortic lymphadenopathy.

The Urinary bladder is adequately distended and shows normal wall thickness. No evidence of any intraluminal mass or calculi.

The uterus is Anteverted. It measures 7.7 x 3.1 x 3.6 cm.

The uterine myometrial echotexture is homogeneous. No focal lesion is seen.

The Endometrial thickness is 5.8 mm.

Both ovaries appear normal in size and show polycystic appearance.

The Right ovary measures 2.8 x 2.4 x 2.4 cm (Volume 8.8 cc).

The Left ovary measures 3.5 x 2.1 x 2.1 cm (Volume – 9.8 cc).

No evidence of any fluid collection in the pelvis.

<b>Patient ID:</b>	542411000611	<b>Patient Name:</b>	CHAITALI MARUTI KUTE 33YRS
<b>Age:</b>		<b>Sex:</b>	F
<b>Accession Number:</b>		<b>Modality:</b>	US
<b>Referring Physician:</b>	DR.DMO	<b>Study:</b>	7SG ABDOMEN PELVIS
<b>Study Date:</b>	09-Nov-2024		

**IMPRESSION:**

**Bilateral polycystic ovaries.**

*Hormonal correlation is required for further evaluation.*

*Y. Shah*

**Dr. Yogini Hetal Shah**  
MBBS, DNB, DMRD

Date: 09-Nov-2024 14:03:00



**MEDICOVER**  
HOSPITALS

NAVI MUMBAI

## 2D ECHO CARDIOGRAPHY WITH COLOR DOPPLER

<i>Name</i>	: Mrs. Chaitali Kuthe	Date:- 09/11/2024
<i>Age / Sex</i>	: 33 Yrs / Female	UMR No. 00611
<i>Referred By</i>	: Health Checkup	

### FINDINGS:

- No left ventricle regional wall motion abnormality.
- Normal left ventricle systolic function. LVEF = 60%.
- No left ventricle diastolic dysfunction.
- No mitral regurgitation.
- No aortic regurgitation. No aortic stenosis.
- Mild tricuspid regurgitation. No pulmonary hypertension.  
PASP = 25 mm Hg.
- No left ventricle clot / vegetation / pericardial effusion.
- Intact IAS and IVS.
- Normal left atrium and left ventricle dimensions.
- Normal right atrium and right ventricle dimensions.
- Normal right ventricle systolic function. No hepatic congestion.

### IMP:

- No RWMA.
- Mild TR. No PH.
- Normal LV and RV systolic function.

**DR. KESHAV KALE**  
DNB (Cardiology), MD (Medicine), MBBS  
PhD (Cardiology), MNAMS, LL.B (Law)  
FSCAI (USA), AFACC (USA), FESC (EU)  
Consultant & Interventional Cardiologist





**MEDICOVER**  
HOSPITALS

NAVI MUMBAI

**M-MODE MEASUREMENTS:**

LA	34	mm
AO root	29	mm
AO CUSP SEP	18	mm
LVID( s)	32	mm
LVID(d)	41	mm
IVS(d)	11	mm
LVPW(d)	11	mm
RVID(d)	29	mm
RA	31	mm
LVEF	60	%

	PEAK	MEAN	Vmax	Gradient of Regurgitation
MITRAL	N			Nil
AORTIC	7			Nil
TRICUSPID	25			Mild
PULMONERY	4.1			Nil



Rate 70 . Sinus rhythm.....normal P axis, V-rate 50- 99  
. Short PR interval..... PR <110ms  
PR 60 . Nonspecific T abnormalities, lateral leads.....T <-0.10mV, I aVL V5 V6  
QRSD 88 . Baseline wander in lead(s) III, aVL  
QT 410  
QTc 443

*WNR*  
*DR*

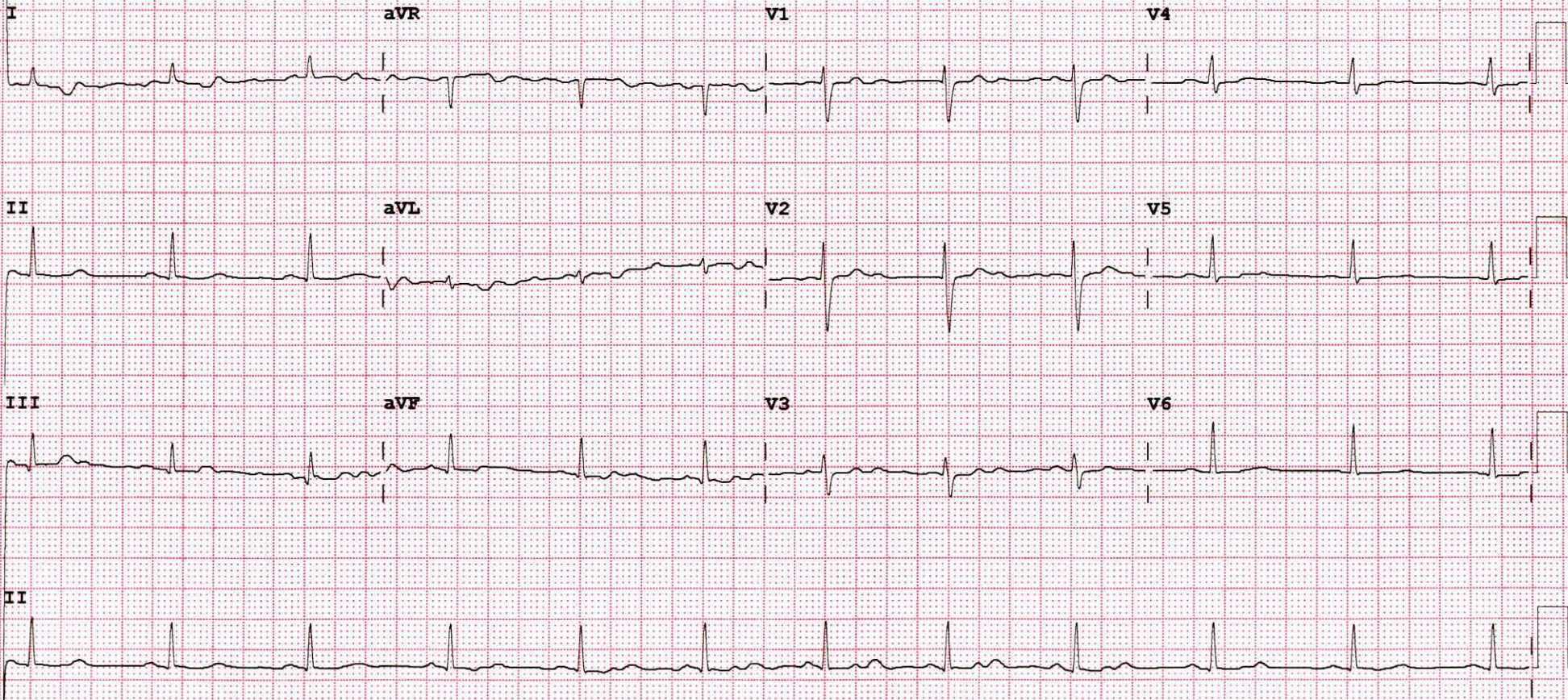
--AXIS--

P 40  
QRS 60  
T 87

- ABNORMAL ECG -

12 Lead; Standard Placement

Unconfirmed Diagnosis





# MEDICOVER HOSPITALS

## DEPARTMENT OF OPHTHALMOLOGY

NAVI MUMBAI

DATE: 9/11/24

PATIENT NAME: ~~Mr. Pranita~~ Mrs. Chaitali

AGE / SEX

33 / F

UMR NO: 54 2411 000611 kute

	RE	LE
VA (DISTANCE)	6/6	6/6
VA (NEAR)	N6	N6
COLOUR VISION	Color Normal	Normal

		SPHERE	CYLINDER	AXIS	VA
MRx	O D	Plano			6/6 N6
	O S	Plano			6/6 N6

### HISTORY :

No h/o HT/Dm/Thyroid  
No h/o ocular trauma/Allergy  
No h/o

### OCULAR FINDINGS :

(BE) - Ant seg wNL

Disc < 0.4  
0.4

### ADVICE:

Refresh Tears e/d q/d 1777 X 1 month

Mon-Fri - 11am to 2pm

AP  
CDR. ANUSHREE VANKAR





# MEDICOVER HOSPITALS

## MEDICAL HEALTH CHECK- UP ASSESMENT FORM

NAME : ~~Mr~~ / Mrs Chaitali Maruti kute DATE: 09/11/24

AGE : 33y

SEX: Male/  Female

NMU: ~~NMU000~~  
54241000611

DOCTOR'S NAME:

Health package.

TEMP :	<u>97.6</u>	<sup>o</sup> f	BP :	<u>100/60</u>	mmHg
PULSE :	<u>70</u>	b/m	HEIGHT :	<u>154</u>	cm
RR :	<u>20</u>	b/m	WEIGHT :	<u>52.6</u>	kg
SPO2 :	<u>100 %</u>	<u>PA</u>	HGT:	<u>—</u>	

REMARK:

Chaitali Kute, F, 33 ya =

C/o routine check up

O/E - SFT, Ca<sup>-1</sup>

- DC int ~~8~~ / 8

Adh,

- Scaling & polishing

- filling int

8 /

Dr. Binola Singh