



PANACEA HOSPITAL

B 36/44 F.K KABIR NAGAR, DURGAKUND
TOLLFREE NO-18001233070. Whatsapp No - 8795832852
www.piire.org
panaceaquery@gmail.com|panaceahospitalit@gmail.com



OP Slip

Print Date : 15-Nov-2024 11:36AM



UHID No	:- UD-24250004382	OP No	:- OP-24250013048	OP Date	:- 15 Nov 2024 11:36AM
Patient Name	:- Mr SHASHI KANT KUMAR	Age/Sex	:- 37 Y/Male	Mobile No	:- 8210539694
Father	:- BHANU CHAUDHARY	Department	:- OPHTHALMOLOGY		
Pay Type	:- Cr	Consultant	:- Dr SANTOSH VERMA (MBBS,MS)		
Token No	:- NOR. - 3	Paid	:- 0.00		
Patient Type	:- Normal				
Address	:- SANJHAULI ROHTAS -802220,BIHAR				

BP :- 110/70
 height :- 166
 Weight (kg) :- 67.2
 BMI :- 24.38

Rx

VA $\left\{ \begin{array}{l} 6/6 \\ 6/6 \end{array} \right.$

Near $\left\{ \begin{array}{l} NG \\ NG \end{array} \right.$

BE. fundus. CNV.

Locally SE.

1.6. Clear Eye - TOS.
OJD

Printed By : Ms. Anjali Prajapati
Created By : Ms. Anjali Prajapati

Page 1 of 1
Dr. SANTOSH VERMA
 MBBS, MS (Ophthalmologist)
 MCI Reg. No. 09-34327



PANACEA HOSPITAL

B 36/44 F.K KABIR NAGAR, DURGAKUND
TOLLFREE NO-18001233070. Whatsapp No - 8795832852
www.piire.org
panaceaquery@gmail.com|panaceahospital@gmail.com



OP Slip

Print Date : 15-Nov-2024 11:35AM



UHID No :- UD-24250004382	OP No :- OP-24250013045	OP Date :- 15 Nov 2024 11:34AM
Patient Name :- Mr SHASHI KANT KUMAR	Age/Sex :- 37 Y/Male	Mobile No :- 8210539694
Father :- BHANU CHAUDHARY	Department :- GENERAL MEDICINE	
Pay Type :- Cr	Consultant :- Dr Pallavi Mishra (MBBS,MD,MBBS)	
Token No :- NOR - 4	Paid/Bal :- 0.00 /1030.00	
Patient Type :- Normal		
Address :- SANJHAULI ROHTAS -802220,BIHAR		

BP :- 110/70
height :- 166
Weight (kg) :- 67.2
BMI :- 24.38

Rx

SpO2 - 98
NE - 34
WE - 96
PEFR - 400
PR - 87

Rx
tab Anti inferno 20
tab Rabonic - L OD
tab Nutripure B12 20

R/A Lmush

Dr. Pallavi Mishra
MBBS, MD (General Medicine)
MCI Reg. No. 52033

Printed By : Ms. Anjali Prajapati
Created By : Ms. Anjali Prajapati



PANACEA HOSPITAL

B 36/44 F.K KABIR NAGAR, DURGAKUND
TOLLFREE NO-18001233070. Whatsapp No - 8795832852
www.piire.org
panaceaquery@gmail.com|panaceahospitalit@gmail.com



OP Slip

Print Date : 15-Nov-2024 11:35AM



UHID No :- UD-24250004382	OP No :- OP-24250013046	OP Date :- 15 Nov 2024 11:35AM
Patient Name :- Mr SHASHI KANT KUMAR	Age/Sex :- 37 Y/Male	Mobile No :- 8210539694
Father :- BHANU CHAUDHARY	Department :- DENTAL	
Pay Type :- Cr	Consultant :- Dr SHRUTI MISHRA (AA)	
Token No :- NOR. - 5	Paid :- 0.00	
Patient Type :- Normal		
Address :- SANJHAULI ROHTAS -802220, BIHAR		

BP :- 110/70
 height :- 166
 Weight (kg) :- 67.2
 BMI :- 24.38

Rx (c => patient came for routine dental check up

O/E => stain / calculus - ++/++

P/O => Chronic gen gingivitis

SpO2 - 98
 NC - 34
 We - 96
 PEF - 400
 PR - 87

Shruti
Dr. SHRUTI MISHRA
 BDS, (DENTIST)
 MCI Reg. No. (A-09784)

Printed By : Ms. Anjali Prajapati
 Created By : Ms. Anjali Prajapati



PANACEA HOSPITAL

B 36/44 F.K KABIR NAGAR, DURGAKUND
TOLLFREE NO-18001233070. Whatsapp No - 8795832852
www.piire.org
panaceaquery@gmail.com|panaceahospitalit@gmail.com



OP Slip

Print Date : 15-Nov-2024 11:36AM



UHID No :- UD-24250004382	OP No :- OP-24250013047	OP Date :- 15 Nov 2024 11:35AM
Patient Name :- Mr SHASHI KANT KUMAR	Age/Sex :- 37 Y/Male	Mobile No :- 8210539694
Father :- BHANU CHAUDHARY	Department :- DERMATOLOGY	
Pay Type :- Cr	Consultant :- Dr DR ASHUTOSH MISHRA (MBBS,MD)	
Token No :- NOR. - 5	Paid :- 0.00	
Patient Type :- Normal		
Address :- SANJHAULI ROHTAS -802220,BIHAR		

BP :- 110/70
 height :- 166
 Weight (kg) :- 67.2
 BMI :- 24.38
 SpO2-98
 NC-34
 We-96
 PEFR-400
 PR-87

Rx

Rx (Hyperhydrosis lotion)
 . H:ft lotion → BID x 2 today

As
 P. Total 20 day
 20 day



Printed By : Ms. Anjali Prajapati
Created By : Ms. Anjali Prajapati

Facilities:

All clinical Biomedical & Hematology Investigations including Bone Marrow Examination
VPT, Podiascan & Complete Foot Care (First Time in Purvanchal)
All Hormonal Investigation by Chemiluminescent Method
Visceral Fat by (AB-140) Ambulatory BP Monitoring
CGMS & Insulin Pump Available
PFT, 2D-ECHO (Color Doppler), Holter, TMT, Cardiac-3 available
VIA, VILI, Colposcopy available
Special Endocrinological Investigation Protocols.

ISO 9001:2008 Certified

Mobile: 9389994334, 9554572190, 9453837595

**Panacea Pathology****Clinical Reference Lab**

Persistence, Preparedness and Precision
EQAS (CMC Vellore Attached) & IQAS System
पूर्वांचल की सर्वोत्तम गुणवत्ता वाली पैथोलॉजी

UHID No :- UD-24250004382 **Booking No/Date** :- 66 / 15-Nov-2024 01:18 PM
Patient Name :- Mr SHASHI KANT KUMAR **Age/Sex** :- 37 Y/M
Father :- BHANU CHAUDHARY **Reg No** :- 24250004382
Address :- SANJHAULI ROHTAS -802220, BIHAR **Mobile No** :- 8210539694
Consultant :- Dr ASHUTOSH MISHRA (MD(MEDICINE),IMS,BHU)

Investigations	Observations	Biological Ref. Interval	Unit
----------------	--------------	--------------------------	------

HAEMATOLOGY**CBC**

HAEMOGLOBIN <small>DefaultMethod / test Machine</small>	15.3	13.00 - 16.00	gm/dl
TLC <small>Methology / Carm</small>	6400	4000.00 - 11000.00	Cells/cumm.
DLC DIFFERENTIAL LEUCOCYTE COUNT			
NEUTROPHILS	38	40.00 - 75.00	%
LYMPHOCYTES	51	20.00 - 45.00	%
EOSINOPHILS	06	1.00 - 6.00	%
MONOCYTES	05	2.00 - 10.00	%
BASOPHILS	00	<1-2	%
PLATELET COUNT	1.78	1.50 - 4.10	lacs /cumm
PCV	46.9	33.00 - 42.00	%
RBC <small>Methology / Carm</small>	4.96	4.50 - 5.50	million/cumm
MCV(MEAN CELL VOLUME)	94.4	83.00 - 101.00	fl
MCH(MEAN CELL HAEMOGLOBIN)	30.9	27.00 - 32.00	pg
MCHC	32.7	31.50 - 35.00	gm%
RDW-CV	13.7	11.00 - 16.00	%
RDW-SD	52.6	37.00 - 57.00	fl

Consulting Pathologist
Dr. UMESH KUMAR
D.B.S. (Pathologist)
MCI Reg. No. 4413

Lab Technician

Timing : 24/7 hrs

This Report is not valid for medico legal purpose

Note: These tests have technical limitations. Clinico-pathological interpretation is necessary. In case of any disparity test may be repeated immediately.

Address : 36/44 FK Kabir Nagar, Durgakund, Varanasi – 221005

Email: dramishra@gmail.com, drpallaviojha@gmail.com Website: panaceahospital.org

Facilities:

All clinical Biomedical & Hematology Investigations including Bone Marrow Examination
 VPT, Podiascan & Complete Foot Care (First Time in Purvanchal)
 All Hormonal Investigation by Chemiluminescent Method
 Visceral Fat by (AB-140) Ambulatory BP Monitoring
 CGMS & Insulin Pump Available
 PFT, 2D-ECHO (Color Doppler), Holter, TMT, Cardiac-3 available
 VIA, VILI, Colposcopy available
 Special Endocrinological Investigation Protocols.

ISO 9001:2008 Certified
 Mobile: 9389994334, 9554572190, 9453837595



Panacea Pathology

Clinical Reference Lab

Persistence, Preparedness and Precision
 EQAS (CMC Vellore Attached) & IQAS System
 पूर्वांचल की सर्वोत्तम गुणवत्ता वाली पैथोलॉजी

UHID No :- UD-24250004382 **Booking No/Date** :- 66 / 15-Nov-2024 01:18 PM
Patient Name :- Mr SHASHI KANT KUMAR **Age/Sex** :- 37 Y/M
Father :- BHANU CHAUDHARY **Reg No** :- 24250004382
Address :- SANJHAULI ROHTAS -802220 , BIHAR **Mobile No** :- 8210539694
Consultant :- Dr ASHUTOSH MISHRA (MD(MEDICINE),IMS,BHU)

Investigations	Observations	Biological Ref. Interval	Unit
----------------	--------------	--------------------------	------

URINE EXAMINATION

URINE ROUTINE EXAMINATION

PHYSICAL EXAMINATION

QUANTITY	25		ml
COLOR <i>Methology</i>	STRAW	CLEAR YELLOW	
APPEARANCE <i>DefaultMethod</i>	CLEAR	CLEAR	

CHEMICAL EXAMINATION

SPECIFIC GRAVITY	1.010	1.01 - 1.03	
PH	5.0	4.60 - 8.00	
GLUCOSE	NIL	60.00 - 100.00	mg/dl
PROTEIN-	NIL		

MICROSCOPIC EXAMINATION

PUS CELLS	NIL	2.00 - 3.00	/HPF
RBCS (RED BLOOD CELLS)	NIL	4.50 - 5.50	/HPF
EPITHELIAL CELLS	01-02		/HPF
CASTS	ABSENT	ABSENT	
CRYSTALS	ABSENT	ABSENT	

Consulting Pathologist
Dr. UMESH KUMAR
 Dr. Umesh Kumar
 MBBS, MD (Pathologist)
 M.D. Pathology
 MCI Reg. No. 41413

Lab Technician

Timing : 24/7 hrs

This Report is not valid for medico legal purpose

Note: These tests have technical limitations. Clinico-pathological interpretation is necessary. In case of any disparity test may be repeated immediately.

Address : 36/44 FK Kabir Nagar, Durgakund, Varanasi – 221005

Email: dramishra@gmail.com, drpallaviojha@gmail.com Website: panaceahospital.org

Facilities:

All clinical Biomedical & Hematology Investigations including Bone Marrow Examination
VPT, Podiascan & Complete Foot Care (First Time in Purvanchal)
All Hormonal Investigation by Chemiluminescent Method
Visceral Fat by (AB-140) Ambulatory BP Monitoring
CGMS & Insulin Pump Available
PFT, 2D-ECHO (Color Doppler), Holter, TMT, Cardiac-3 available
VIA, VILI, Colposcopy available
Special Endocrinological Investigation Protocols.

ISO 9001:2008 Certified
Mobile: 9389994334, 9554572190, 9453837595



Panacea Pathology

Clinical Reference Lab

Persistence, Preparedness and Precision
EQAS (CMC Vellore Attached) & IQAS System
पूर्वांचल की सर्वोत्तम गुणवत्ता वाली पैथोलॉजी

UHID No :- UD-24250004382 **Booking No/Date** :- 66 / 15-Nov-2024 01:18 PM
Patient Name :- Mr SHASHI KANT KUMAR **Age/Sex** :- 37 Y/M
Father :- BHANU CHAUDHARY **Reg No** :- 24250004382
Address :- SANJHAULI ROHTAS -802220, BIHAR **Mobile No** :- 8210539694
Consultant :- Dr ASHUTOSH MISHRA (MD(MEDICINE),IMS,BHU)

Investigations	Observations	Biological Ref. Interval	Unit
----------------	--------------	--------------------------	------

HAEMATOLOGY

HBA1C -(BY GOLD STANDARD METHOD :HPLC)	5.1	Normal: 4.0 - 5.4 Prediabetic : 5.5 -6.3 Diabetes mellitus := 6.4	%
ESR	12.0	0.00 - 15.00	mm at 1 hr

IMMUNOLOGY

THYROID PROFILE (T3,T4,TSH)

T3	1.02	0.60 - 1.81	ng/ml
T4	8.2	4.50 - 10.90	ug/dl
TSH	2.67	0.39 - 6.10	uIU/mL

BIOCHEMISTRY

LFT (LIVER FUNCTION TESTS)

TOTAL BILIRUBIN	0.72	0.00 - 1.20	mg/dl
DIRECT BILIRUBIN	0.22	0.00 - 0.30	
INDIRECT BILIRUBIN	0.50	0.20 - 0.70	mg/dl
SGOT	21.0	2.00 - 31.00	U/L
SGPT	29.0	10.00 - 45.00	U/L
ALKALINE PHOSPHATASE	68.0	25.00 - 140.00	U/L
TOTAL PROTIENS	7.21	6.60 - 8.70	g/dl

Lab Technician

Timing : 24/7 hrs

This Report is not valid for medico legal purpose

Consulting Pathologist
Dr. UMESH KUMAR
Dr. Umesh Kumar
MBBS, MD (Pathologist)
M.D. Pathology
M.C. Reg. No. 41413

Note: These tests have technical limitations. Clinico-pathological interpretation is necessary. In case of any disparity test may be repeated immediately.

Address : 36/44 FK Kabir Nagar, Durgakund, Varanasi – 221005

Email: dramishra@gmail.com, drpallaviojha@gmail.com Website: panaceahospital.org

Facilities:

All clinical Biomedical & Hematology Investigations including Bone Marrow Examination
VPT, Podiascan & Complete Foot Care (First Time in Purvanchal)
All Hormonal Investigation by Chemiluminescent Method
Visceral Fat by (AB-140) Ambulatory BP Monitoring
CGMS & Insulin Pump Available
PFT, 2D-ECHO (Color Doppler), Holter, TMT, Cardiac-3 available
VIA, VILI, Colposcopy available
Special Endocrinological Investigation Protocols.

ISO 9001:2008 Certified
Mobile: 9389994334, 9554572190, 9453837595



Panacea Pathology

Clinical Reference Lab

Persistence, Preparedness and Precision
EQAS (CMC Vellore Attached) & IQAS System
पूर्वांचल की सर्वोत्तम गुणवत्ता वाली पैथोलॉजी

UHID No :- UD-24250004382 **Booking No/Date** :- 66 / 15-Nov-2024 01:18 PM
Patient Name :- Mr SHASHI KANT KUMAR **Age/Sex** :- 37 Y/M
Father :- BHANU CHAUDHARY **Reg No** :- 24250004382
Address :- SANJHAULI ROHTAS -802220 , BIHAR **Mobile No** :- 8210539694
Consultant :- Dr ASHUTOSH MISHRA (MD(MEDICINE),IMS,BHU)

Investigations	Observations	Biological Ref. Interval	Unit
ALBUMIN	4.10	3.50 - 5.20	gm%
GLOBULIN	3.11	1.50 - 3.60	gms/dl
A/G RATIO	1.31	2:1	RATIO
RFT (RENAL FUNCTION TESTS)			
SERUM CREATININE	0.79	0.60 - 1.60	mg/dl
URIC ACID	3.92	3.60 - 7.70	mg/dl
LIPID PROFILE			
TOTAL CHOLESTROL	164.0	Desirable : - < 200 mg/dL Borderline: - 200 - 239 mg/dL High : - > 240mg/dL	mg/dl
TRIGLYCERIDES	148.0	35.00 - 160.00	mg/dl
HDL CHOLESTROL	41.0	35.30 - 79.50	mg/dl
LDL CHOLESTROL	93.4	<130	mg/dl
VLDL	29.60	<40	mg/dl
CHOLESTROL/ HDL RATIO	4.00	<3.0 LOW RISK, 3.0-5.0 AVG RISK, >5.0 HIGH RISK	ratio
LDL/HDL RATIO	2.28	<3	ratio

BIOCHEMISTRY

BLOOD SUGAR FASTING

Lab Technician

Consulting Pathologist
Dr. UMESH KUMAR
Dr. Umesh Kumar
MBBS, MD (Pathologist)
M.D. Pathology
MCI Reg. No. 41443

Timing : 24/7 hrs

This Report is not valid for medico legal purpose

Note: These tests have technical limitations. Clinico-pathological interpretation is necessary. In case of any disparity test may be repeated immediately.

Address : 36/44 FK Kabir Nagar, Durgakund, Varanasi - 221005

Email: dramishra@gmail.com, drpallaviojha@gmail.com Website: panaceahospital.org

Facilities:

All clinical Biomedical & Hematology Investigations including Bone Marrow Examination
VPT, Podiascan & Complete Foot Care (First Time in Purvanchal)
All Hormonal Investigation by Chemiluminescent Method
Visceral Fat by (AB-140) Ambulatory BP Monitoring
CGMS & Insulin Pump Available
PFT, 2D-ECHO (Color Doppler), Holter, TMT, Cardiac-3 available
VIA, VILI, Colposcopy available
Special Endocrinological Investigation Protocols.

ISO 9001:2008 Certified
Mobile: 9389994334, 9554572190, 9453837595



Panacea Pathology

Clinical Reference Lab

Persistence, Preparedness and Precision
EQAS (CMC Vellore Attached) & IQAS System
पूर्वांचल की सर्वोत्तम गुणवत्ता वाली पैथोलॉजी

UHID No :- UD-24250004382 **Booking No/Date** :- 66 / 15-Nov-2024 01:18 PM
Patient Name :- Mr SHASHI KANT KUMAR **Age/Sex** :- 37 Y/M
Father :- BHANU CHAUDHARY **Reg No** :- 24250004382
Address :- SANJHAULI ROHTAS -802220 , BIHAR **Mobile No** :- 8210539694
Consultant :- Dr ASHUTOSH MISHRA (MD(MEDICINE),IMS,BHU)

Investigations	Observations	Biological Ref. Interval	Unit
GLUCOSE	90.0	60.00 - 100.00	mg/dl
PRE-DIABETICS(IMPAIRED FASTING TOLER)	-	100.00 - 125.00	mg/dl
DIABETICS	-	upto 126	mg/dl
TARGET IN DM	-	80.00 - 130.00	mg/dl

BIOCHEMISTRY

PPBS(POST PRANDIAL BLOOD SUGAR)

POST PRANDIAL BLOOD GLUCOSE(2 HR AFTER MEAL)	107.0	110.00 - 150.00	mg/dl
IGT(2 HR 75GM GLUCOSE)	-	140.00 - 199.00	mg/dl
DIABETES	-	upto200	mg/dl
TARGET IN DM	-	80.00 - 130.00	mg/dl

* END OF REPORT *

Consulting Pathologist

Dr. UMESH KUMAR
M.D., Pathology
MCI Reg. No. 41413

Lab Technician

Timing : 24/7 hrs

This Report is not valid for medico legal purpose

Note: These tests have technical limitations. Clinico-pathological interpretation is necessary. In case of any disparity test may be repeated immediately.

Address : 36/44 FK Kabir Nagar, Durgakund, Varanasi – 221005

Email: dramishra@gmail.com, drpallaviojha@gmail.com Website: panaceahospital.org



PANACEA HOSPITAL



A shelter for many hearts A Home for many lives

(An ISO 9001:2008 Certified Organisation)
Lab Attached with CMC Under EQAS Scheme

Dept. of Radiodiagnosis - 32 Slice CT Scan, 3D/4D USG, 2D ECHO, Colour Doppler, Intervention Procedures, Digital X-Ray

NAME: SHASHI KANT KUMAR
REF.DR.ASHUTOSH MISHRA(MD)

AGE/SEX: 37 YRS/MALE
DATE: 15/11/2024

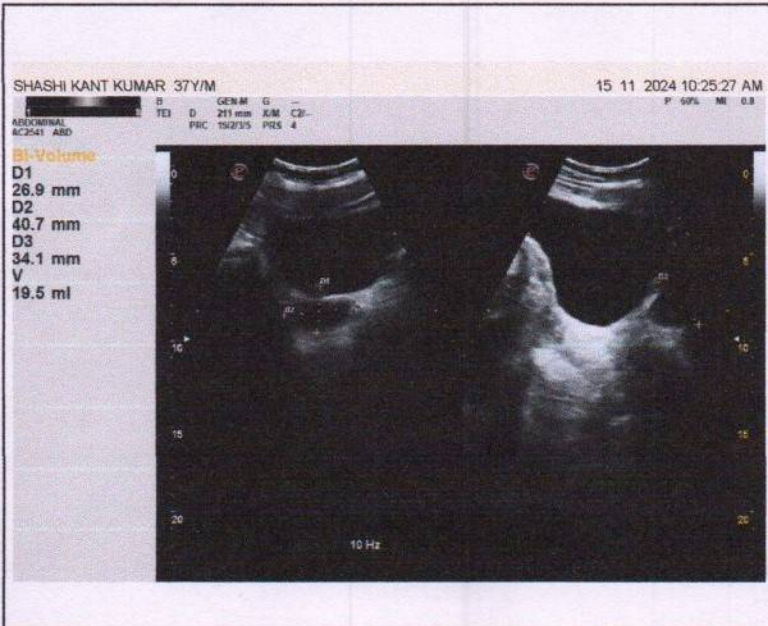
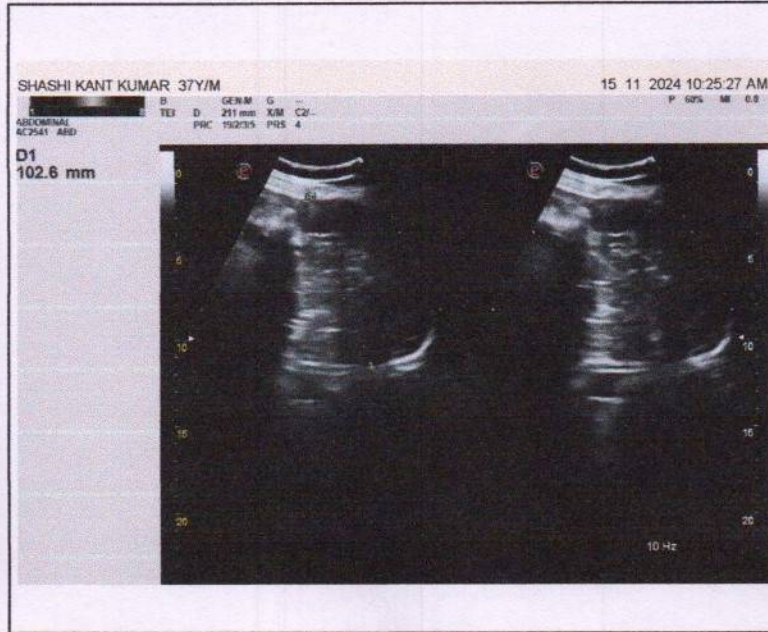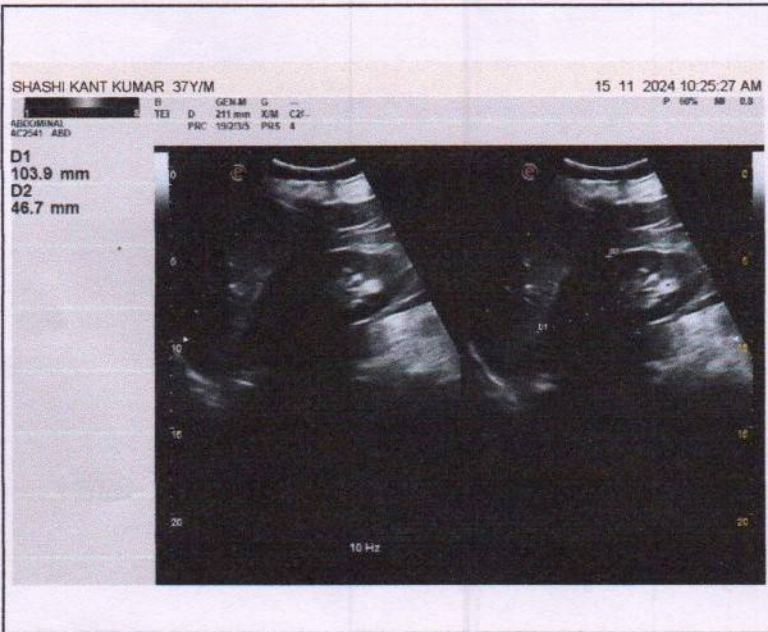
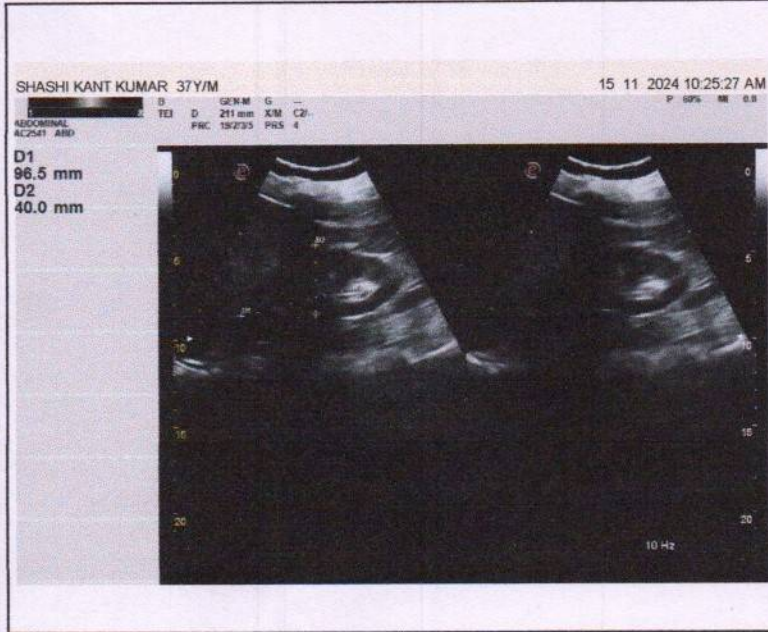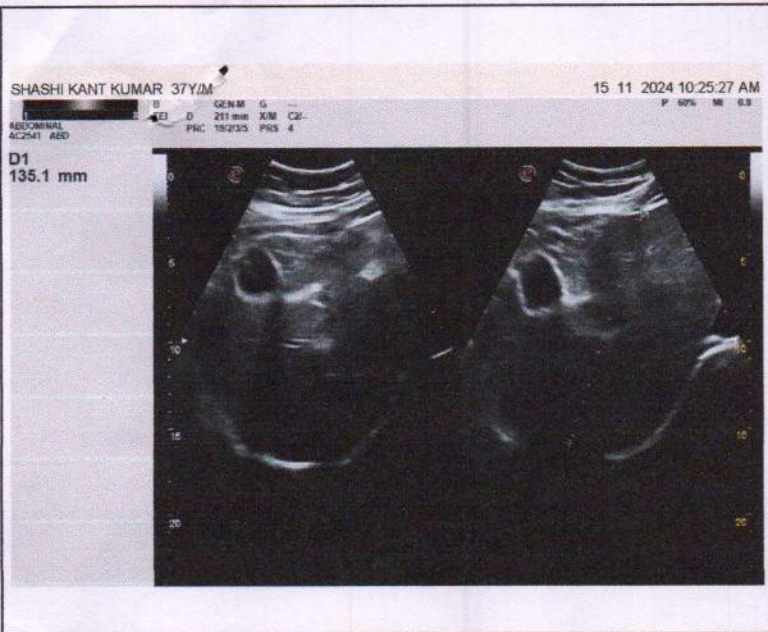
ULTRASOUND WHOLE ABDOMEN REPORT

<u>Liver:</u>	Normal in size(135mm), shape, & echogenicity. Intra & extra hepatic biliary radicals & vascular structures are normal. Margins are smooth and regular.
<u>Gall bladder:</u>	Normally distended with echo free lumen.
<u>Portal vein:</u>	Normal in course and caliber.
<u>CBD diameter:</u>	Visualized part normal in course & caliber.
<u>Pancreas:</u>	Normal in size, shape & echogenicity. Margins are smooth & regular. No diffuse/ focal lesion seen. Pancreatic duct not visualized.
<u>Spleen:</u>	Normal in size, shape & echogenicity. Margins are smooth & regular. No diffuse / focal lesion seen.
<u>Kidney:</u>	Both normal in size, shape echogenicity & position. Cortical-medullary differentiation is maintained. Pelvicalyceal system normal. No evidence of any calculus/mass lesion seen. No hydronephrosis/ hydroureter seen. No suprarenal mass lesion.
<u>Urinary bladder:</u>	Normally distended with normal wall thickness. No echogenic foci lumen or diverticula seen. Both VUJ appears normal. No evidence of calculus / mass lesion seen.
<u>Prostate:</u>	Normal in size(26X40X34mmVol19.5ml), shape & echogenicity.
<u>Others:</u>	No free fluid in peritoneal cavity. No free fluid in bilateral pleural cavity. No evidence of significantly enlarged retroperitoneal/ mesenteric lymph nodes noted.
<u>IMPRESSION: -</u>	NO OBVIOUS SONOLOGICAL ABNORMALITY SEEN.

Please correlate clinically and further investigations.

- Note: (1) This report is not valid for medico-legal purposes.
(2) In case of any discrepancy due typing error, please get it Rectified immediately.

Sonologist
Dr. Rahul Kumar Tiwari
MBBS, MD (Radio Diagnosis)
MCI Reg. No. 57557





PANACEA HOSPITAL



A shelter for many hearts A Home for many lives
 (An ISO 9001:2008 Certified Organisation)
 Lab Attached with CMC Under EQAS Scheme

Dept. of Radiodiagnosis - 32 Slice CT Scan, 3D/4D USG, 2D ECHO, Colour Doppler, Intervention Procedures, Digital X-Ray

NAME: SHASHI KANT KUMAR

AGE/SEX: 37YRS/MALE

REF. DR. DR. ASHUTOSH MISHRA (MD)


DATE: 15/11/2024


Echo - Cardiography

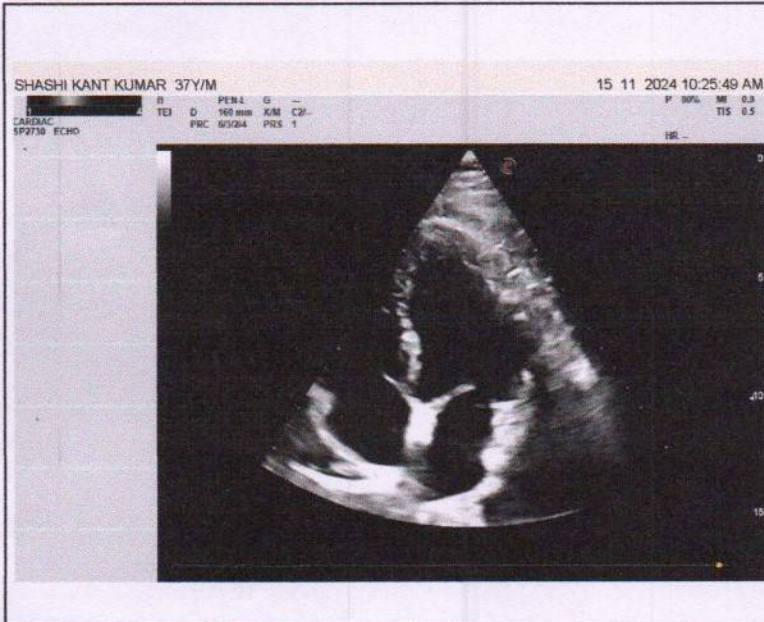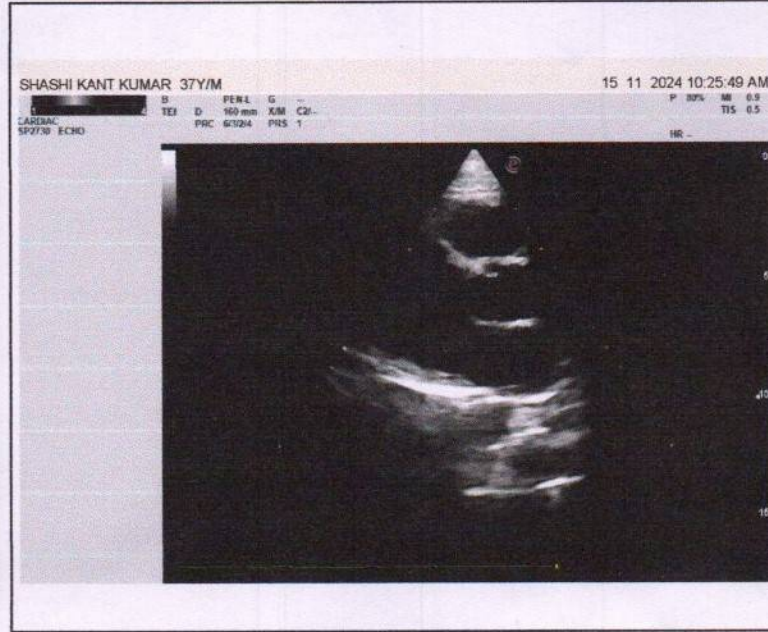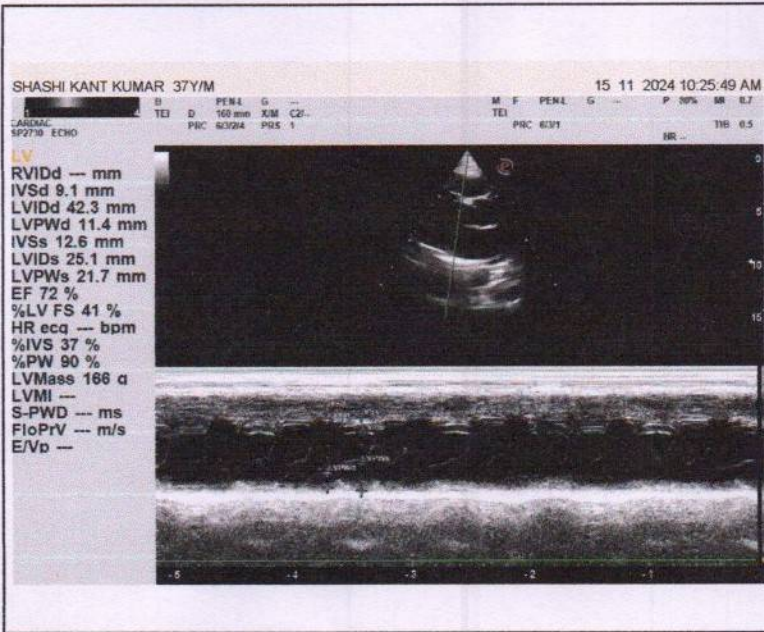
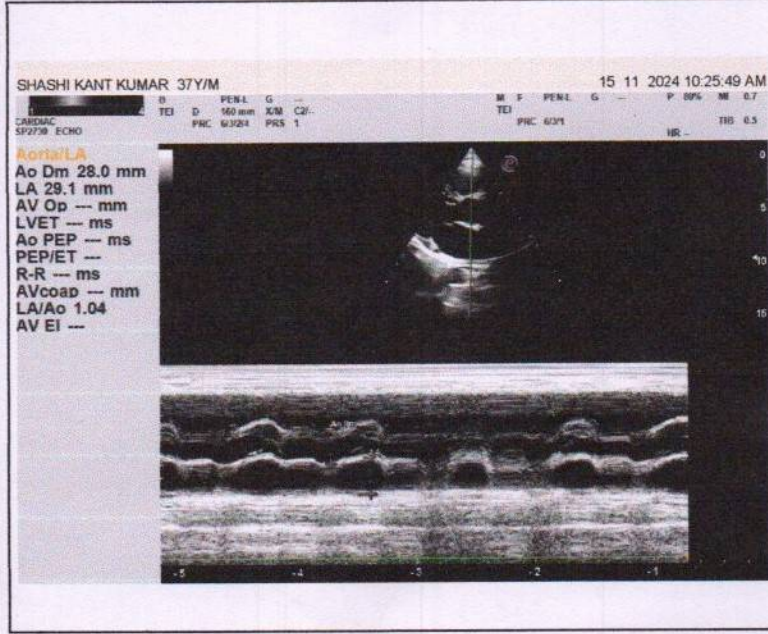
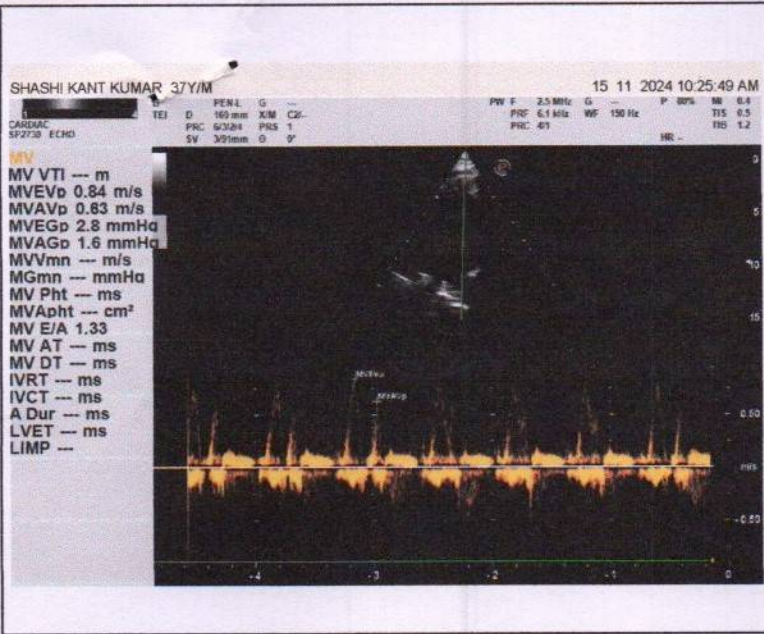
MITRAL VALVE Doppler	AML - normal morphology MV Flow - E - 0.8 A-0.8 E/A=1.33	PML - normal morphology MVA - 3.0 cm ² Mitral Regurgitation - No
TRICUSPID VALVE Doppler	Normal TV Flow - No	Tricuspid Regurgitation - No
PULMONARY VALVE Doppler	Normal PV Flow - No	Pulmonary Regurgitation - No
AORTIC VALVE Doppler	Trileaflet-No AV Flow - no	Aortic Regurgitation - No
MEASUREMENT	Aorta - 28.0 (20-38) mm IVS ed -9.1 (6-12) mm LVID ed -42.3 (35-55) mm LVPW ed - 11.6 (6-12) mm OA - 7 (> 5) mm	LA -29.1 (24-32) mm IVS es -12.6 (6-12) mm LVID es -25.1 (24-40) mm LVPW es - 21.7 (6-12) mm EPSS - 4 (< 9) mm

CONCLUSION All cardiac chamber dimensions are WNL
 No valvular abnormalities
 Good LV systolic function present Modified Simpson's method (4C, 2C) (LVEF-72%)
 No diastolic dysfunction present (E/A = 1.33)
 No pericardial effusion
 No RWMA
 Intact IAS / IV
 No PAH
 No intra cardiac mass /thrombus /vegetation

IMPRESSION **Normal Echocardiogram**


 Niraj Mishra
 Physician Assistant
 (PIIRE)


 Dr. Pallavi Mishra
 MBBS, MD (General Medicine), MCh (Echocardiography)
 Echocardiography Specialist, MIAE
 Non-invasive Cardiologist
 Women Cardiologist
 Diabetocardiologist
 MCI Reg. No. 52033





Call Now - 1800-123-3070

PANACEA HOSPITAL



A shelter for many hearts A Home for many lives
(An ISO 9001:2008 Certified Organisation)
Lab Attached with CMC Under EQAS Scheme

Dept. of Radiodiagnosis - 32 Slice CT Scan, 3D/4D USG, 2D ECHO, Colour Doppler, Intervention Procedures, Digital X-Ray

PATIENT NAME	SHASHI KANT KUMAR	AGE/SEX	37YRS/M
REF. BY DR.	DR. ASHUTSOH MISHRA	DATE	15/11/2024

X-RAY CHEST (AP VIEW)

- Lung fields show hazy opacities in both parahilar, basal zone with mild prominent brochopulmonary markings.
- Rest of the bilateral lung fields appear normal.
- Trachea and mediastinum appear normal in position.
- Both hila appear normal in size and are symmetrical.
- Transverse cardiac diameter is within normal limits.
- Both CP angles appear clear. Normal position and contour diaphragms noted.
- Bony rib cage and soft tissue shadows appear normal.

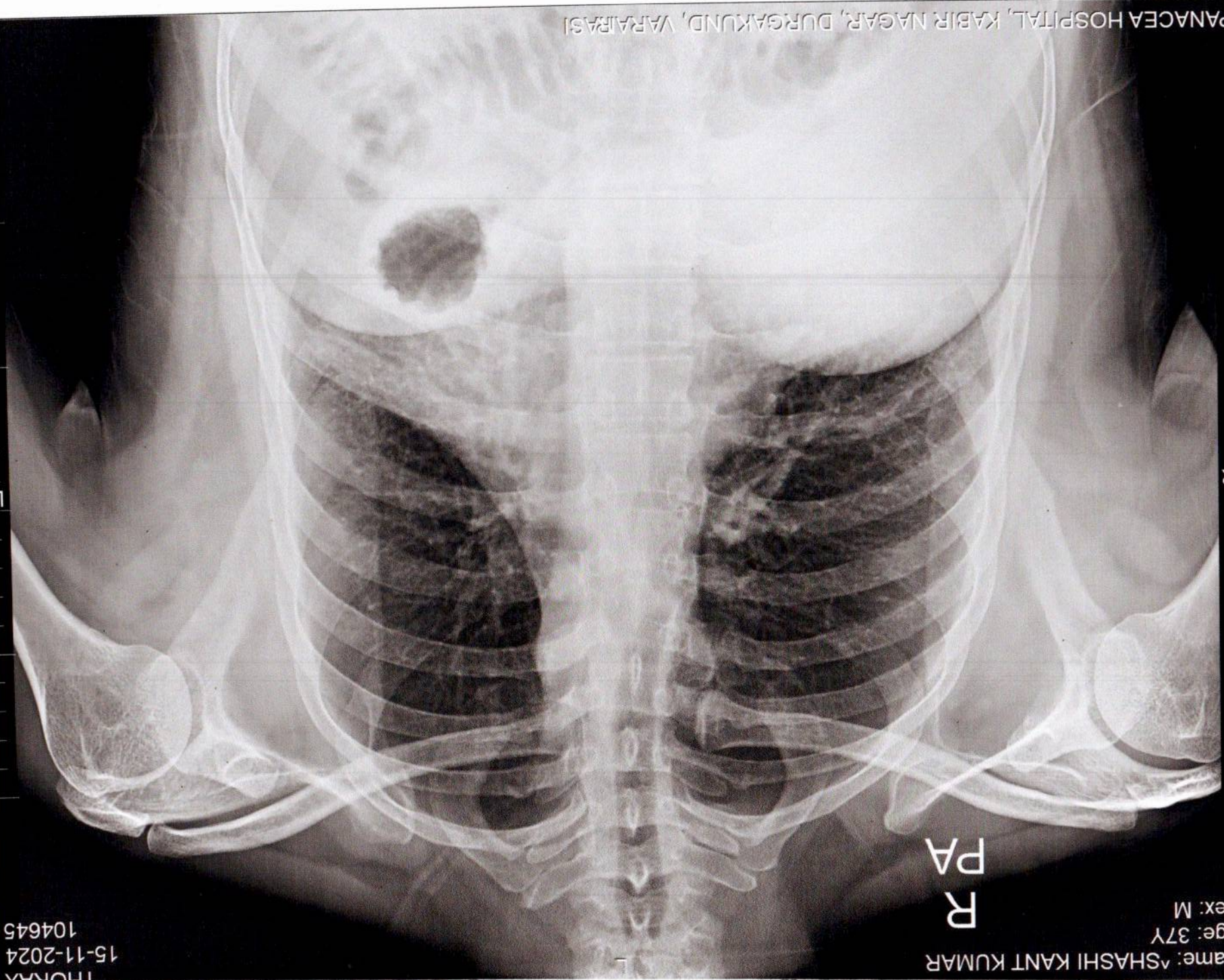
Thanks for reference.

Radiologist
Dr. Rahul Kumar Tiwari
MBBS, MD (Radio Diagnosis)
MCI Reg. No. 57557

Disclaimer: This report is not valid for Madicolegal or Judicial Purpose. Radiological diagnosis is solely interpretation of images produced by tissue & may not be always conclusive.

Address : B36/44 B4 Kabir Nagar (Near Sanjay Shiksha Niketan), Durgakund, Varanasi
Mobile : 9554572190 / 9453837595 / Recpn, 9389994334
Email : dramishra@gmail.com, drpallaviojha@gmail.com, Website : www.piire.org

PANACEA HOSPITAL, KABIR NAGAR, DURGAKUND, VARANASI



R

PA
R

Name: SHASHI KANT KUMAR
Age: 37Y
Sex: M

THORAX
15-11-2024
104645

20 cm

AUTO 10mm/mV

10mm/mV

10mm/mV

5mm/mV

I

aVR

V1

V4

II

aVL

V2

V5

III

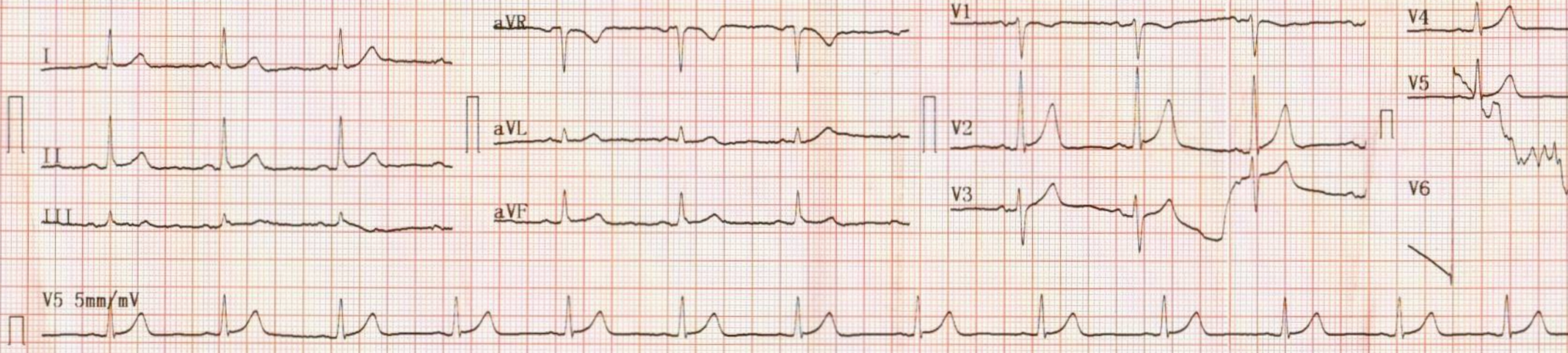aVF

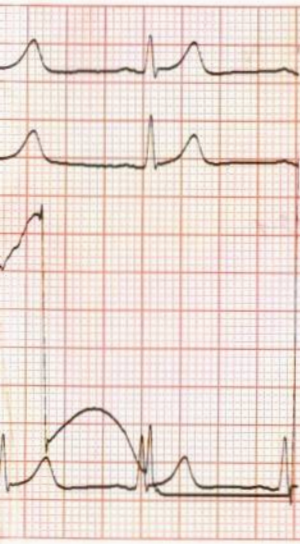
V3

V6

V5 5mm/mV

25mm/s AC50Hz+EMG35Hz+DFT





10mm/mV

I

II

III

aVR

25mm/s

10mm/mV

aVL

aVF

VI

V2

10mm/mV

V3

V4

V5

V6

2024-11-15 11:00

ID :
 Name : Shashi Kant Kumar
 Sex : M Age : 37
 Height : 166 Weight : 67.2kg
 SYS :
 DIA :

HR [bpm] : 95
 PR Interval [ms] : 271
 P Duration [ms] : 120
 QRS Duration [ms] : 71
 T Duration [ms] : 166
 QT/QTc [ms] : 332/417
 P/QRS/T Axis [deg] : 54.4/48.5/34.7
 R(V5)/S(V1) [mV] : 1.40/0.62
 R(V5)+S(V1) [mV] : 2.01

<< Conclusions >>

Cardiac electric axis normal;
 I AV block;
 Report need physician confirm

Dr. Poojati Misra
 MBBS, MD (General Medicine)
 MCI Reg. No. 52033

Physician _____